



Development and validation of a nomogram to predict pathological complete response in patients with locally advanced gastric adenocarcinoma treated with neoadjuvant chemotherapy in combination with PD-1 antibodies

Liang Li¹, Guanglong Chen¹, Emerson Y. Chen², Matthew R. Strickland³, Weijie Zhao¹, Jialin Zhang¹, Zhi Li¹

¹Department of General Surgery, The Affiliated Cancer Hospital of Zhengzhou University & Henan Cancer Hospital, Zhengzhou, China; ²Division of Hematology and Medical Oncology, Knight Cancer Institute, Oregon Health & Science University, Portland, OR, USA; ³Department of Medicine, Harvard Medical School and Massachusetts General Hospital, Boston, MA, USA

Contributions: (I) Conception and design: Z Li, L Li; (II) Administrative support: Z Li; (III) Provision of study materials or patients: G Chen, W Zhao, J Zhang; (IV) Collection and assembly of data: L Li, G Chen; (V) Data analysis and interpretation: L Li, W Zhao; (VI) Manuscript writing: All authors; (VII) Final approval of manuscript: All authors.

Correspondence to: Zhi Li, MD. Director of General Surgery, Professor of Treatment, Department of General Surgery, The Affiliated Cancer Hospital of Zhengzhou University & Henan Cancer Hospital, 127 Dongming Road, Zhengzhou 450008, China. Email: zlylizhi0316@zzu.edu.cn.

Background: Currently, the survival benefits of combining neoadjuvant chemotherapy with programmed death 1 (PD-1) antibody immunotherapy in advanced gastric adenocarcinoma remain controversial. Emerging evidence suggests that the survival benefits of neoadjuvant therapy in advanced gastric adenocarcinoma hinge upon the attainment of pathological complete response (pCR). Therefore, the prediction of pCR in patients undergoing neoadjuvant chemotherapy combined with PD-1 antibody immunotherapy holds significant importance and is beneficial for the individualized treatment of gastric cancer (GC) patients.

Methods: Clinical and pathological characteristics of patients with GC who received neoadjuvant chemotherapy combined with PD-1 inhibitor (camrelizumab) therapy and radical gastrectomy between January 2019 and December 2020 at the Affiliated Cancer Hospital of Zhengzhou University & Henan Cancer Hospital were retrospectively analyzed. A total of 52 patients were enrolled in the study, with all subjects assigned to the training set. The neoadjuvant regimen consisted of a combination of PD-1 inhibitor and fluorouracil analogues plus oxaliplatin, comprising two drugs. The patients were divided into a pCR group and a non-pCR group according to pCR occurrence. Multifactor logistic regression analysis was applied to determine the correlation between each factor and pCR. A prediction model was developed based on the results of the logistic regression analysis. The predictive performance of the model was evaluated using the receiver operating characteristic curves. Internal verification was completed via the bootstrapping method.

Results: The pCR was observed in 10 out of 52 patients (19.2%). The results of binary logistic regression multivariate analysis showed that cN stage [odds ratio (OR): 0.215; P=0.03], combined positive score (CPS) (OR: 6.364; P=0.026), and tumor diameter (OR: 0.112; P=0.026) were independent predictors of pCR. The nomogram prediction model for the pCR was plotted with a concordance index of 0.923 [95% confidence interval (CI): 0.8441–1].

Conclusions: Neoadjuvant chemotherapy combined with PD-1 antibodies may be the preferred option for patients with advanced gastric adenocarcinoma who have a small tumor diameter, no or few lymph node metastases, and high CPS. The presented nomogram model exhibits the potential to predict pCR in advanced gastric adenocarcinoma patients, showcasing satisfactory predictive performance and potentially facilitating the implementation of personalized treatment strategies.

Keywords: Advanced gastric adenocarcinoma; nomogram; pathological complete response (pCR); neoadjuvant chemotherapy plus programmed death 1 antibody (neoadjuvant chemotherapy plus PD-1 antibody)

Submitted Sep 06, 2023. Accepted for publication Nov 20, 2023. Published online Dec 08, 2023.

doi: 10.21037/jgo-23-751

View this article at: <https://dx.doi.org/10.21037/jgo-23-751>

Introduction

Background and objectives

Gastric cancer (GC) remains the most prevalent malignancy worldwide, with over one million new cases and 760,000 reported deaths in 2020 (equivalent to 1 in 13 global fatalities) (1). It ranks fifth globally in terms of incidence and fourth in mortality, with adenocarcinoma accounting for more than 95% of all GCs (1,2). Total neoadjuvant therapy (TNT) and neoadjuvant therapy hold great promise in reducing tumor staging, improving surgical outcomes, and providing novel approaches for long-term disease control (3). This treatment paradigm has resulted in improved surgical as well as downstream survival outcomes for select patients, however, median overall survival remains less than 5 years and more biologically-informed therapeutic strategies are needed (4).

A related study has shown that tumor cells promote tumor progression and metastasis by overexpressing cell-surface programmed death ligand 1 (PD-L1) or by inducing PD-L1 expression on immune cells, using the programmed death 1 (PD-1)/PD-L1 pathway to inhibit the body's immune response and further promote immune escape (5). This mechanism is currently believed to be a major factor in promoting tumor immune escape (6). Neoadjuvant chemoimmunotherapy involves the use of both chemotherapy and immunotherapy agents. Chemotherapy drugs are administered to target and kill cancer cells, while immunotherapy drugs enhance the body's immune response to fight against cancer. The immunotherapy approach involves the use of PD-1 monoclonal antibodies to obstruct the PD-1/PD-L1 pathway, thereby stimulating T cells and reinstating the body's antitumor immunity, thus preventing tumor cells from evading immune surveillance (7). The administration of PD-1 antibodies has been shown to be associated with an increase in the rate of pathological remission in patients with locally advanced gastric adenocarcinoma, facilitating the conversion of unresectable tumors into resectable ones. Moreover, its combination with chemotherapy and targeted therapy further augments the anti-tumor efficacy. PD-1/PD-L1 blockade represents a significant advancement for cancer therapy in recent years (8). The efficacy of neoadjuvant chemotherapy combined with PD-1 antibodies for advanced gastric adenocarcinoma remains a subject of debate.

Previous study has indicated that the survival benefit of neoadjuvant therapy is dependent on the pathological complete response (pCR) to both chemotherapeutic agents and PD-1 antibodies (9). pCR was chosen as the marker of high sensitivity to neoadjuvant therapy because it is a universal, objective and reproducible indicator that reflects the complete eradication of the tumor cells in the resected specimen after neoadjuvant therapy. It provides a reliable and accurate assessment of the effectiveness of neoadjuvant chemotherapy and is widely recognized as a valuable endpoint in clinical trials evaluating neoadjuvant treatment for gastric adenocarcinoma. Several clinical trials have

Highlight box

Key findings

- Neoadjuvant chemotherapy combined with programmed death 1 (PD-1) antibodies may be the preferred option for patients with advanced gastric adenocarcinoma with a small tumor diameter, no or few lymph node metastases, and high combined positive score.

What is known and what is new?

- The factors that impact the efficacy of neoadjuvant chemotherapy and PD-1 antibody combination therapy in gastric adenocarcinoma remain unclear.
- We conducted a comprehensive evaluation and analysis of the factors impacting pathological complete response (pCR) in patients with advanced gastric adenocarcinoma treated at our institution using a two-drug regimen combined with camrelizumab. Subsequently, we developed and validated a nomogram for predicting pCR in these patients.

What is the implication, and what should change now?

- The results of our analysis may improve outcomes of preoperative treatment for gastric cancer patients and serve as a foundation for future related studies. To further validate the accuracy of these findings, large-scale, multicenter, prospective studies should be conducted.

demonstrated that neoadjuvant chemotherapy and PD-1 antibodies is advantageous in reducing tumor stage and achieving pCR as compared to neoadjuvant chemotherapy alone, leading to improved radical resection rates (R0) (10). For resectable GC, neoadjuvant chemoimmunotherapy confers superior survival advantages compared to neoadjuvant chemotherapy (11). Furthermore, there is no increase in postoperative complications, and patients' quality of life is enhanced (12-15). Superior overall survival and progression-free survival are more likely to occur in patients who achieve pCR after neoadjuvant therapy. For nonresponders, PD-1 antibody and chemotherapy combination therapy offers no survival benefit, only toxicity and the risk of tumor progression during chemotherapy, which may prevent surgical resection. Therefore, pre-screening of patients with a propensity for pCR to neoadjuvant therapy is imperative in order to provide personalized treatment.

At present, the predictive factors determining the effectiveness of neoadjuvant chemotherapy combined with PD-1 antibody therapy in gastric adenocarcinoma remain unclear. Research indicates that the efficacy of immunotherapy may be influenced by factors such as tumor stage, tumor mutation burden (TMB), PD-1 expression, microsatellite instability (MSI), and immune cell infiltration (16-18). However, it should be noted that these factors are not deterministic and may vary depending on the tumor type and treatment approach. Therefore, the ability to predict pCR following neoadjuvant chemotherapy in combination with PD-1 antibody therapy has significant clinical implications for the personalized treatment of patients with advanced gastric adenocarcinoma.

Nomograms are widely regarded as a viable model type for predicting the likelihood of positive outcomes in individuals based on regression analysis (19), through which clinicians can conveniently predict endpoint events. Currently, there is no application of this predictive model in forecasting the efficacy of chemoimmunotherapy for gastric adenocarcinoma. In this study, we conducted an analysis of clinical and pathological data from patients with advanced gastric adenocarcinoma who underwent neoadjuvant chemotherapy and PD-1 antibody combination therapy. We also investigated the factors that influence pCR in gastric adenocarcinoma. The nomogram prediction model, in which multiple relevant factors were integrated, was developed and validated internally. The prediction model provided a more accurate evaluation and reference for predicting the clinical efficacy of neoadjuvant chemotherapy

plus PD-1 antibody therapy for patients with gastric adenocarcinoma. We present this article in accordance with the TRIPOD reporting checklist (available at <https://jgo.amegroups.com/article/view/10.21037/jgo-23-751/rc>).

Methods

Source of data

A retrospective study design was employed to collect clinical data from 52 patients with gastric adenocarcinoma who underwent neoadjuvant chemotherapy and PD-1 antibody (camrelizumab) combination therapy, as well as radical gastrectomy at the Affiliated Cancer Hospital of Zhengzhou University & Henan Cancer Hospital between January 2019 and December 2020.

Participants

The inclusion criteria were as follows: (I) T3/4N0/+ gastric and gastroesophageal junction adenocarcinoma assessed with computed tomography; (II) preoperative assessment revealing the absence of any unresectable factors, with the patient undergoing a minimum of 3–4 cycles of camrelizumab in combination with 2-drug chemotherapy (fluorouracil plus oxaliplatin); (III) absence of distant metastasis; (IV) undergoing radical gastrectomy with D2 lymph node dissection; (V) complete pathological and clinical data available; and (VI) relevant informed consent obtained prior to surgery. Meanwhile, the exclusion criteria were the following: patients who had undergone palliative resection or were unable to complete radical gastrectomy, as well as those with comorbidities such as mental and nervous system disorders that significantly impact cognitive function. The study was conducted in accordance with the Declaration of Helsinki (as revised in 2013). The study was approved by the Review Committee of the Affiliated Cancer Hospital of Zhengzhou University & Henan Cancer Hospital (No. 2021-499-002) and individual consent for this retrospective analysis was waived.

The clinical data collected from patients in this study included gender; age; cT stage; cN stage; tumor location; degree of differentiation; combined positive score (CPS) (PD-L1 IHC 22C3 pharmDx; Agilent, Santa Clara, CA, USA); levels of carcinoembryonic antigen (CEA), alpha fetoprotein (AFP), CA199, CA125, and CA724 biomarker; and tumor diameter (*Table 1*).

The treatment strategies for all patients were devised by a

Table 1 Patient characteristics and univariate analysis

Characteristics	Total (n=52)	Non-pCR (n=42)	pCR (n=10)	P value
Sex				0.137
Male	35	26	9	
Female	17	16	1	
Age (years)	57 [16]	58 [16]	57 [16]	0.836
CPS				0.007
<1	19	19	0	
1–10	26	19	7	
>10	7	4	3	
Clinical T stage				0.734
T3	29	24	5	
T4	23	18	5	
Clinical N stage				0.015
N0	15	10	5	
N1	15	10	5	
N2	15	15	0	
N3	7	7	0	
Tumor differentiation				0.179
Moderately to well differentiated	1	1	0	
Moderately differentiated	4	4	0	
Poorly to moderately differentiated	22	20	2	
Poor differentiation	25	17	8	
Tumor location				0.254
Cardia	31	25	6	
Fundus of stomach	4	2	2	
Stomach body	10	8	2	
Gastric antral	7	7	0	
Tumor diameter				0.014
<2.25 cm	18	11	7	
≥2.25 cm	34	31	3	
CEA				0.608
<4.7 ng/mL	45	37	8	
≥4.7 ng/mL	7	5	2	
CA199				0.12
<34 U/mL	45	38	7	
≥34 U/mL	7	4	3	

Table 1 (continued)

Table 1 (continued)

Characteristics	Total (n=52)	Non-pCR (n=42)	pCR (n=10)	P value
CA724				0.723
<6.9 U/mL	34	28	6	
≥6.9 U/mL	18	14	4	
CA125				0.999
<35 U/mL	47	38	9	
≥35 U/mL	5	4	1	
AFP				0.576
<25 ng/mL	48	38	10	
≥25 ng/mL	4	4	0	

Age is represented as the median [interquartile range]. The remaining variables are categorical and are represented by counts. pCR, pathological complete response; CPS, combined positive score; CEA, carcinoembryonic antigen; AFP, alpha-fetoprotein.

multidisciplinary team comprising physicians and surgeons. The regimen included at least 3 to 4 cycles of neoadjuvant chemo-immunotherapy. Neoadjuvant immunotherapy was camrelizumab (20), and neoadjuvant chemotherapy was a 2-drug regimen of a fluorouracil plus oxaliplatin. The regimen was as follows: (I) camrelizumab plus FOLFOX, including camrelizumab (200 mg, ivgtt, D1), oxaliplatin (85 mg/m²), and continuous intravenous injection of fluorouracil (2,800 mg/m²) over 48 h, every 2 weeks; (II) camrelizumab plus SOX, including camrelizumab (200 mg, ivgtt, d1), intravenous injection of oxaliplatin (130 mg/m²), and tegafur gimeracil oteracil potassium capsule (40–60 mg bid D1–D14) every 3 weeks; and (III) camrelizumab plus XELOX, including camrelizumab (200 mg, ivgtt, d1), oxaliplatin (130 mg/m²), and capecitabine (1,000 mg/m² bid D1–D14) every 3 weeks.

All enrolled patients underwent curative tumor resection, either total or subtotal gastrectomy, accompanied by D2 lymphadenectomy.

Outcome

All resected specimens were submitted to the pathology department and evaluated by the attending pathologist based on Ryan grading criteria (21). The absence of residual cancer cells in both the primary tumor and dissected regional lymph nodes (TRG0) was defined as pCR, while the presence of residual cancer cells in postoperative tissue [tumor regression grade (TRG) 1–3] was defined as non-pCR.

Predictors

The continuous variables examined in this study encompassed age, CPS, tumor diameter, and tumor markers. Patients were categorized into three groups (<1, 1–10, >10) based on the CPS cutoff value established in previous large-scale study of immunotherapy (22). Tumor markers were quantified in the peripheral venous blood of patients using the original reagent from the Roche E601 detection instrument. According to the instrument's reference values, cutoff values for CEA, CA125, CA199, CA724, and AFP were set to 4.7 ng/mL, 35 U/mL, 34 U/mL, 6.9 U/mL, and 25 ng/mL, respectively. In this study, the receiver operating characteristic (ROC) curve was generated using SPSS software (IBM Corp., Armonk, NY, USA), and the cutoff value corresponding to the maximum Youden index was identified as the optimal threshold for the tumor diameter (23). The final analysis revealed that the optimal cutoff value for tumor diameter was 2.25 cm.

Statistical analysis methods

The normality of continuous data was assessed through the Kolmogorov-Smirnov test. Parameters with a nonnormal distribution are expressed as the median with interquartile range (IQR) and were analyzed using appropriate nonparametric tests including the Mann-Whitney test or Kruskal-Wallis test. The chi-squared test was employed to analyze categorical variables. Variables that showed a

Table 2 Results of the multivariate analysis

Characteristics	OR	95% CI	P value
CPS	6.364	1.247–32.485	0.026
Clinical N stage	0.215	0.054–0.858	0.03
Tumor diameter	0.112	0.016–0.774	0.026

CPS, combined positive score; OR, odds ratio; CI, confidence interval.

significant difference ($P < 0.05$) in univariate analysis were included for further multivariate analysis. Binary logistic regression using the forward method was employed to conduct multivariate analysis of risk factors associated with pCR, while the Hosmer-Lemeshow test was used to assess model fit. A 2-tailed hypothesis test with a significance level of 0.05 was used (Table 2).

Nomogram construction

Based on the prognostic factors, a nomogram was formulated using the “survival” package in R studio version 4.2.3 software. Each predictor was displayed on a separate row in a plot, with varying numbers of points assigned to different levels of the predictor variable. The cumulative point axis was depicted at the end of the nomogram, with higher total points indicating a lower probability of achieving pCR. The predictive ability of the model was assessed using the Harrell concordance index (C-index). The C-index and 95% CIs were used to assess the predictive discrimination, and the range of values was from 0 to 1, with values closer to 1 indicating superior model discrimination. Internal verification was completed via the bootstrapping method, and the calibration curve of the nomogram was constructed to illustrate the correlation between predicted and observed outcomes.

Results

Participants

Based on the inclusion and exclusion criteria, a total of 52 patients diagnosed with gastric adenocarcinoma were enrolled in this study. There were 35 male and 17 female participants, with a median age of 57 years. The 52 patients were categorized into two groups based on TRG classification (10 pCR and 42 non-pCR). More than half of patients had tumor sites in the cardia ($n=31$, 60%). The

T3 stage ($n=29$, 56%) was the most prevalent, followed by the T4 stage ($n=23$, 44%). Poor differentiation ($n=25$, 48%) was the most common type of differentiation, followed by poorly to moderately differentiated ($n=22$, 42%), moderately differentiated ($n=4$, 8.0%), and moderately to well differentiated ($n=1$, 2.0%). Univariable associations between the clinical parameters and pCR are shown in Table 1. Clinical N stage, CPS, and tumor diameter exhibited statistically significant associations.

Multivariate logistic regression analysis

Multivariate analysis revealed that cN [odds ratio (OR): 0.215; 95% CI: 0.054–0.858], CPS (OR: 6.364; 95% CI: 1.247–32.485), and tumor diameter (OR: 0.112; 95% CI: 0.016–0.774) were independent predictors of pCR following neoadjuvant chemotherapy in combination with PD-1 antibody therapy (Table 2).

Construction of the nomogram

Nomogram prediction model for pCR after neoadjuvant chemotherapy and PD-1 antibody combination therapy was based on multifactorial analysis using R software (Figure 1). The corresponding scores were obtained by projecting each variable onto the “Points” axis and then aggregated to derive a total score that corresponded to the predicted outcome. The results of the ROC curve analysis and the C-index of the univariate nomogram prediction model were the following: cN =0.762, CPS =0.761, and diameter =0.719 (Figure 2A-2C). The multifactor nomogram model exhibited a high predictive accuracy, with a C-index value of 0.923 (Figure 2D). The analysis of the calibration curve demonstrated that the nomogram model evaluated in this study exhibited superior predictive ability for pCR following treatment with PD-1 antibody combined with chemotherapy (Figure 3).

Discussion

Neoadjuvant chemotherapy combined with PD-1 antibody immunotherapy has demonstrated a more complete and durable response compared to chemotherapy alone. As a result, it has the potential to become a standard treatment approach for resectable gastric adenocarcinoma (24). This approach aims to achieve tumor downstaging, volume reduction, and eradication of positive lymph nodes, ultimately improving patient prognosis (25,26). Clinical

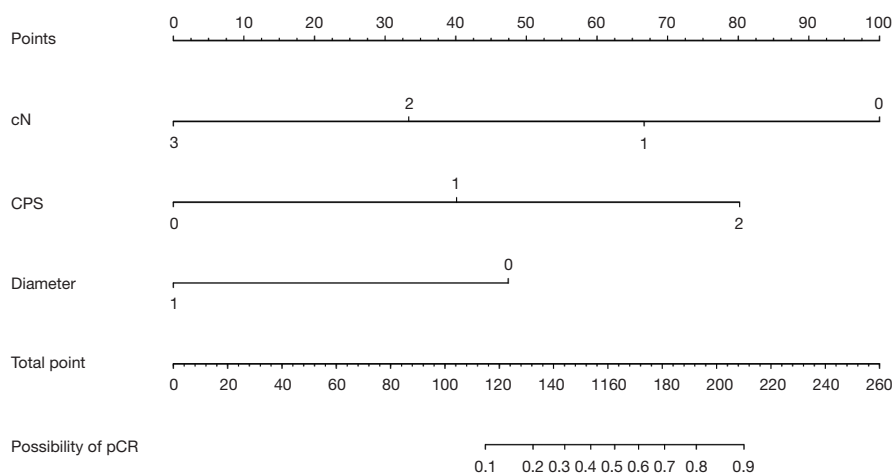


Figure 1 Nomogram for predicting pathological complete response with neoadjuvant chemotherapy and PD-1 antibody combination therapy. The clinical N stage axis was as follows: 0: no lymph node metastasis; 1: 1 or 2 lymph nodes involved; 2: 3 to 6 lymph nodes involved; and 3: more than 7 lymph nodes involved. The combined positive score axis was as follows: 0: CPS <1; 1: CPS 1–10; 2: CPS >10. The tumor diameter axis was as follows: 0: <2.25 cm; 1: \geq 2.25 cm. PD-1, programmed death 1; CPS, combined positive score; pCR, pathological complete response.

trials have shown that neoadjuvant PD-1 blockade plus chemotherapy neither delays the timing of surgery nor increases the rate of postoperative complications (16). Such therapy may also be better tolerated than triplet cytotoxic chemotherapy, which has higher risk of cytopenias and neuropathy.

The limitations in the efficacy of current immunotherapies, mainly involving immune checkpoint inhibitors, have emphasized the need to enhance our comprehension of combination therapeutic strategies for improving outcomes among patients who exhibit poor response to single-agent immunotherapy (27). To further enhance the efficacy of neoadjuvant therapy in patients with advanced gastric adenocarcinoma, multimodal treatment regimens incorporating neoadjuvant chemotherapy and PD-1 antibody immunotherapy prior to surgical resection are being increasingly employed (28). However, the choice of population for neoadjuvant chemotherapy in combination with PD-1 antibody therapy remains controversial.

pCR status reflects the sensitivity of tumor cells to preoperative treatment and represents a crucial indicator of the efficacy of combined treatment with PD-1 blockade. Achieving a pCR following neoadjuvant chemotherapy is strongly associated with prolonged survival and the possibility of undergoing radical surgery (29). Therefore, the ability to predict pCR can provide personalized prognostication as well as surrogate for clinical efficacy

in drug development of immune checkpoint inhibitors in the neoadjuvant setting. In this study, pCR was observed in 10 out of 52 patients (19.2%) who received neoadjuvant chemotherapy combined with PD-1 immunotherapy for advanced gastric adenocarcinoma. This pCR rate is higher than the reported range of 10.4% to 16.0% for neoadjuvant chemotherapy alone (30–32). The findings of this study demonstrate that the combination of PD-1 antibody and a 2-drug regimen chemotherapy can yield a comparable or possibly higher pCR rate for advanced gastric adenocarcinoma compared to neoadjuvant chemotherapy alone, providing a valuable opportunity for surgical resection treatment (33).

We evaluated and analyzed the factors that impact the efficacy of neoadjuvant chemotherapy with a 2-drug regimen combined with camrelizumab treatment at our institution and developed a nomogram prediction model. The multifactorial analysis of 52 clinical cases demonstrated significant associations between pCR rates and CPS, cN stage, and tumor diameter following neoadjuvant chemotherapy combined with PD-1 antibody treatment for gastric adenocarcinoma. CPS is being increasingly used as a reliable indicator of immunotherapy response in advanced gastric adenocarcinoma, owing to its high predictive value (34). CPS is calculated by percent of PD-L1 positive tumor and immune cells out of total viable tumor cells (35). In this study, CPS was positively correlated with pCR rate,

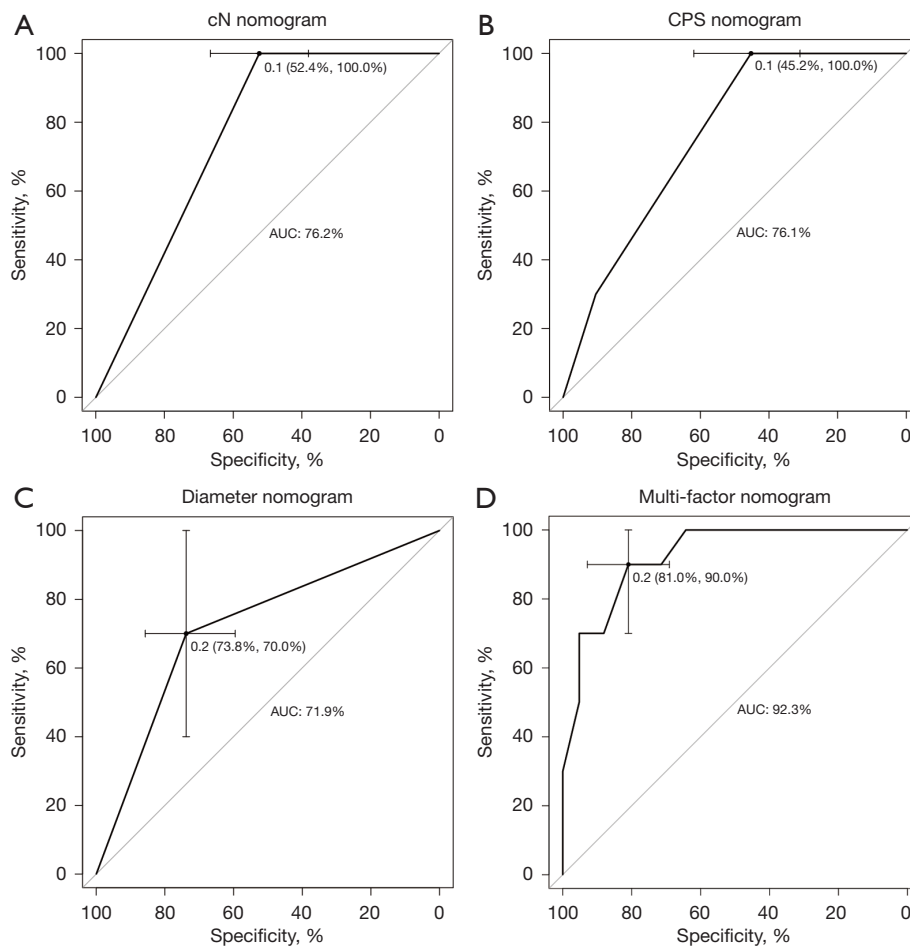


Figure 2 ROC curve for the nomogram model. (A) ROC curve for the cN nomogram model. (B) ROC curve for the CPS nomogram model. (C) ROC curve for the diameter nomogram model. (D) ROC curve for the multifactor nomogram model. ROC, receiver operating characteristic; CPS, combined positive score.

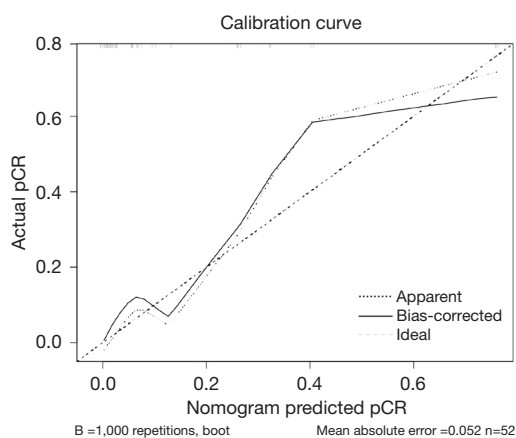


Figure 3 Calibration curve for the nomogram model. pCR, pathological complete response.

and the high-CPS (CPS >10) group was more sensitive to neoadjuvant chemotherapy combined with PD-1 antibody compared to the low-CPS group. Therefore, preoperative evaluation of CPS is a predictive value for patients with progressive GC (17). The results of the multifactorial regression analysis indicated that cN stage is significantly associated with pCR, likely it correlates with tumor burden and aggressiveness (36). Lymph node micrometastases may decrease the rate of pCR following neoadjuvant PD-1 blockade plus chemotherapy, thereby impacting the prognosis of patients with advanced GC. Therefore, precise evaluation of cN staging and identification of patients with low or no lymph node metastases for this regimen has an important prognostic role in evaluating patients for neoadjuvant chemo-immunotherapy (37).

Tumor size and tumor cell numbers have been considered important determinants of tumor response to treatment. Larger tumors may develop resistance through vascularization and cellular heterogeneity (36). The findings of this investigation revealed a negative correlation between tumor diameter and the rate of achieving pCR. The PD-1 antibody-based combination chemotherapy regimen may be the preferred treatment option for patients with advanced gastric adenocarcinoma with a small tumor diameter.

The PD-1/PD-L1 pathway plays a pivotal role in the pathogenesis of advanced gastric adenocarcinoma, as evidenced by relevant meta-analyses and multiple clinical trials highlighting its significance (6). PD-L1/PD-1 antibodies can be used safely in patients with GC and provide patients with sustained anti-cancer activity (15,24,38). Immunotherapy has the potential to stimulate a systemic immune response, which may help prevent the occurrence of tumor micrometastasis. The positive correlation between CPS and treatment outcome observed in this study is consistent with previous findings, such as those reported in the Keynote-059 phase II trial (39-41).

Our nomogram was constructed based on three easily assessable variables, namely cN stage, CPS and tumor diameter, making it more applicable in clinical settings. By comparing the C-index of the unifactorial model with that of the multifactorial model, it was observed that the predictive performance of the former was inferior to that of the latter. Therefore, all three variables in the nomogram model synergistically contribute to enhancing its discriminative ability. These three variables could also be used to enrich patient population for future studies testing neoadjuvant chemo-immunotherapy regimens. Combination therapies have become an important cornerstone in the treatment of gastric adenocarcinoma, and there are many ongoing clinical trials aimed at identifying new effective combinations of drugs. In the future, we can expect to see more personalized combination therapies that are tailored to the specific needs of each patient.

There are some limitations to this study. To begin, only a small group of individuals in Henan Province were examined, and the applicability of the findings to other neoadjuvant treatments is unknown. Moreover, the sample size was too small to allow for a division into a training and validation set. Additionally, a retrospective design and not a randomized controlled design was employed. Thus, these limitations may have a negative impact on the accuracy of the results obtained in this study. However, our findings

may nonetheless serve as a foundation for future related studies. To further validate the accuracy of these findings, large-scale, multicenter, prospective studies should be conducted.

Conclusions

Neoadjuvant chemotherapy combined with PD-1 antibodies may be the preferred option for patients with advanced gastric adenocarcinoma who have a small tumor diameter, no or few lymph node metastases, and high CPS. The presented nomogram model demonstrates the potential to predict pCR in advanced gastric adenocarcinoma patients, showcasing satisfactory predictive performance and potentially facilitating the implementation of personalized treatment strategies.

Acknowledgments

Funding: This work was supported by the Medical Science and Technology Project of Henan Province (grant Nos. 232102311077 and LHGJ20220198).

Footnote

Reporting Checklist: The authors have completed the TRIPOD reporting checklist. Available at <https://jgo.amegroups.com/article/view/10.21037/jgo-23-751/rc>

Data Sharing Statement: Available at <https://jgo.amegroups.com/article/view/10.21037/jgo-23-751/dss>

Peer Review File: Available at <https://jgo.amegroups.com/article/view/10.21037/jgo-23-751/prf>

Conflicts of Interest: All authors have completed the ICMJE uniform disclosure form (available at <https://jgo.amegroups.com/article/view/10.21037/jgo-23-751/coif>). The authors have no conflicts of interest to declare.

Ethical Statement: The authors are accountable for all aspects of the work in ensuring that questions related to the accuracy or integrity of any part of the work are appropriately investigated and resolved. The study was conducted in accordance with the Declaration of Helsinki (as revised in 2013). The study was approved by the Review Committee of the Affiliated Cancer Hospital of Zhengzhou

University & Henan Cancer Hospital (No. 2021-499-002) and individual consent for this retrospective analysis was waived.

Open Access Statement: This is an Open Access article distributed in accordance with the Creative Commons Attribution-NonCommercial-NoDerivs 4.0 International License (CC BY-NC-ND 4.0), which permits the non-commercial replication and distribution of the article with the strict proviso that no changes or edits are made and the original work is properly cited (including links to both the formal publication through the relevant DOI and the license). See: <https://creativecommons.org/licenses/by-nc-nd/4.0/>.

References

- Sung H, Ferlay J, Siegel RL, et al. Global Cancer Statistics 2020: GLOBOCAN Estimates of Incidence and Mortality Worldwide for 36 Cancers in 185 Countries. *CA Cancer J Clin* 2021;71:209-49.
- Ajani JA, D'Amico TA, Bentrem DJ, et al. Gastric Cancer, Version 2.2022, NCCN Clinical Practice Guidelines in Oncology. *J Natl Compr Canc Netw* 2022;20:167-92.
- Yang J, Grealley M, Strong VE, et al. Perioperative versus total neoadjuvant chemotherapy in gastric cancer. *J Gastrointest Oncol* 2023;14:1193-203.
- Japanese Gastric Cancer Treatment Guidelines 2021 (6th edition). *Gastric Cancer* 2023;26:1-25.
- Pardoll DM. Immunology beats cancer: a blueprint for successful translation. *Nat Immunol* 2012;13:1129-32.
- Zhao Y, Bai Y, Shen M, et al. Therapeutic strategies for gastric cancer targeting immune cells: Future directions. *Front Immunol* 2022;13:992762.
- Mittal D, Gubin MM, Schreiber RD, et al. New insights into cancer immunoediting and its three component phases--elimination, equilibrium and escape. *Curr Opin Immunol* 2014;27:16-25.
- Xie F, Xu M, Lu J, et al. The role of exosomal PD-L1 in tumor progression and immunotherapy. *Mol Cancer* 2019;18:146.
- Karagkounis G, Thai L, Mace AG, et al. Prognostic Implications of Pathological Response to Neoadjuvant Chemoradiation in Pathologic Stage III Rectal Cancer. *Ann Surg* 2019;269:1117-23.
- Li S, Yu W, Xie F, et al. Neoadjuvant therapy with immune checkpoint blockade, antiangiogenesis, and chemotherapy for locally advanced gastric cancer. *Nat Commun* 2023;14:8.
- Jeung HC, Moon YW, Rha SY, et al. Phase III trial of adjuvant 5-fluorouracil and adriamycin versus 5-fluorouracil, adriamycin, and polyadenylic-polyuridylic acid (poly A:U) for locally advanced gastric cancer after curative surgery: final results of 15-year follow-up. *Ann Oncol* 2008;19:520-6.
- Wan T, Zhang XF, Liang C, et al. The Prognostic Value of a Pathologic Complete Response After Neoadjuvant Therapy for Digestive Cancer: Systematic Review and Meta-Analysis of 21 Studies. *Ann Surg Oncol* 2019;26:1412-20.
- Fields RC, Strong VE, Gönen M, et al. Recurrence and survival after pathologic complete response to preoperative therapy followed by surgery for gastric or gastroesophageal adenocarcinoma. *Br J Cancer* 2011;104:1840-7.
- Kawazoe A, Shitara K, Boku N, et al. Current status of immunotherapy for advanced gastric cancer. *Jpn J Clin Oncol* 2021;51:20-7.
- Gu L, Chen M, Guo D, et al. PD-L1 and gastric cancer prognosis: A systematic review and meta-analysis. *PLoS One* 2017;12:e0182692.
- Tang X, Li M, Wu X, et al. Neoadjuvant PD-1 blockade plus chemotherapy induces a high pathological complete response rate and anti-tumor immune subsets in clinical stage III gastric cancer. *Oncoimmunology* 2022;11:2135819.
- Zurlo IV, Schino M, Strippoli A, et al. Predictive value of NLR, TILs (CD4+/CD8+) and PD-L1 expression for prognosis and response to preoperative chemotherapy in gastric cancer. *Cancer Immunol Immunother* 2022;71:45-55.
- Yoon HH, Jin Z, Kour O, et al. Association of PD-L1 Expression and Other Variables With Benefit From Immune Checkpoint Inhibition in Advanced Gastroesophageal Cancer: Systematic Review and Meta-analysis of 17 Phase 3 Randomized Clinical Trials. *JAMA Oncol* 2022;8:1456-65.
- Park SY. Nomogram: An analogue tool to deliver digital knowledge. *J Thorac Cardiovasc Surg* 2018;155:1793.
- Markham A, Keam SJ. Camrelizumab: First Global Approval. *Drugs* 2019;79:1355-61.
- Ryan R, Gibbons D, Hyland JM, et al. Pathological response following long-course neoadjuvant chemoradiotherapy for locally advanced rectal cancer. *Histopathology* 2005;47:141-6.
- Högner A, Moehler M. Immunotherapy in Gastric Cancer. *Curr Oncol* 2022;29:1559-74.

23. Hajian-Tilaki K. Receiver Operating Characteristic (ROC) Curve Analysis for Medical Diagnostic Test Evaluation. *Caspian J Intern Med* 2013;4:627-35.
24. Sharma P, Allison JP. The future of immune checkpoint therapy. *Science* 2015;348:56-61.
25. Salas-Benito D, Pérez-Gracia JL, Ponz-Sarvisé M, et al. Paradigms on Immunotherapy Combinations with Chemotherapy. *Cancer Discov* 2021;11:1353-67.
26. Tang Z, Wang Y, Liu D, et al. The Neo-PLANET phase II trial of neoadjuvant camrelizumab plus concurrent chemoradiotherapy in locally advanced adenocarcinoma of stomach or gastroesophageal junction. *Nat Commun* 2022;13:6807.
27. Yap TA, Parkes EE, Peng W, et al. Development of Immunotherapy Combination Strategies in Cancer. *Cancer Discov* 2021;11:1368-97.
28. Yuan Z, Cui H, Wang S, et al. Combining neoadjuvant chemotherapy with PD-1/PD-L1 inhibitors for locally advanced, resectable gastric or gastroesophageal junction adenocarcinoma: A systematic review and meta-analysis. *Front Oncol* 2023;13:1103320.
29. Wang T, Wang N, Zhou H, et al. Long-term survival results of patients with locally advanced gastric cancer and pathological complete response after neoadjuvant chemotherapy and resection. *Transl Cancer Res* 2020;9:529-35.
30. Koh YW, Park YS, Ryu MH, et al. Postoperative nodal status and diffuse-type histology are independent prognostic factors in resectable advanced gastric carcinomas after preoperative chemotherapy. *Am J Surg Pathol* 2013;37:1022-9.
31. Anderson E, LeVeé A, Kim S, et al. A Comparison of Clinicopathologic Outcomes Across Neoadjuvant and Adjuvant Treatment Modalities in Resectable Gastric Cancer. *JAMA Netw Open* 2021;4:e2138432.
32. Wang X, Li S, Sun Y, et al. The protocol of a prospective, multicenter, randomized, controlled phase III study evaluating different cycles of oxaliplatin combined with S-1 (SOX) as neoadjuvant chemotherapy for patients with locally advanced gastric cancer: RESONANCE-II trial. *BMC Cancer* 2021;21:20.
33. Al-Batran SE, Homann N, Pauligk C, et al. Effect of Neoadjuvant Chemotherapy Followed by Surgical Resection on Survival in Patients With Limited Metastatic Gastric or Gastroesophageal Junction Cancer: The AIO-FLOT3 Trial. *JAMA Oncol* 2017;3:1237-44.
34. Yamashita K, Iwatsuki M, Harada K, et al. Prognostic impacts of the combined positive score and the tumor proportion score for programmed death ligand-1 expression by double immunohistochemical staining in patients with advanced gastric cancer. *Gastric Cancer* 2020;23:95-104.
35. Panda A, Mehnert JM, Hirshfield KM, et al. Immune Activation and Benefit From Avelumab in EBV-Positive Gastric Cancer. *J Natl Cancer Inst* 2018;110:316-20.
36. MacGuill M, Mulligan E, Ravi N, et al. Clinicopathologic factors predicting complete pathological response to neoadjuvant chemoradiotherapy in esophageal cancer. *Dis Esophagus* 2006;19:273-6.
37. Becker K, Langer R, Reim D, et al. Significance of histopathological tumor regression after neoadjuvant chemotherapy in gastric adenocarcinomas: a summary of 480 cases. *Ann Surg* 2011;253:934-9.
38. Wu X, Gu Z, Chen Y, et al. Application of PD-1 Blockade in Cancer Immunotherapy. *Comput Struct Biotechnol J* 2019;17:661-74.
39. Bang YJ, Kang YK, Catenacci DV, et al. Pembrolizumab alone or in combination with chemotherapy as first-line therapy for patients with advanced gastric or gastroesophageal junction adenocarcinoma: results from the phase II nonrandomized KEYNOTE-059 study. *Gastric Cancer* 2019;22:828-37.
40. Kulangara K, Zhang N, Corigliano E, et al. Clinical Utility of the Combined Positive Score for Programmed Death Ligand-1 Expression and the Approval of Pembrolizumab for Treatment of Gastric Cancer. *Arch Pathol Lab Med* 2019;143:330-7.
41. Moehler M, Högner A, Wagner AD, et al. Recent progress and current challenges of immunotherapy in advanced/metastatic esophagogastric adenocarcinoma. *Eur J Cancer* 2022;176:13-29.

Cite this article as: Li L, Chen G, Chen EY, Strickland MR, Zhao W, Zhang J, Li Z. Development and validation of a nomogram to predict pathological complete response in patients with locally advanced gastric adenocarcinoma treated with neoadjuvant chemotherapy in combination with PD-1 antibodies. *J Gastrointest Oncol* 2023;14(6):2373-2383. doi: 10.21037/jgo-23-751