

Case Report

Management of intrathoracic leakage after radical total gastrectomy

Yonggang Lv, Shifang Yuan, Jun Yun, Qing Yao, Jianghao Chen, Jun Yi, Rui Ling, Ling Wang

Department of Vascular and Endocrine Surgery, First Affiliated Hospital, Fourth Military Medical University, Xi'an, PR China

ABSTRACT

Background Intrathoracic anastomotic leakage resulted from radical total gastrectomy with an end-to-side esophagojejunostomy are exclusively abdominal.

Case presentation We report the case of a 64-year-old male who underwent radical total gastrectomy and intraabdominal end-to-side esophagojejunostomy for gastric cardiac carcinoma. Anastomotic leakage to the thoracic cavity occurred which was confirmed by contrast radiography 18 days after the operation. The symptoms included coughing and fever, with elevated white blood cells over $10 \times 10^9/L$. Coughing and fever disappeared after successful sealing of the fistulous orifice with an endoscopically placed covered metallic stent with the applications of antibiotics and drainage of the pleural effusion. The patient was recovered and discharged from the hospital approximately two months after the occurrence of the leakage without any symptoms except intermittent esophageal reflux which could be resolved by treatment with cisapride, or by intaking less liquid food. The patient then received 4 cycles of adjuvant chemotherapy with regimen of FOLFOX4 (fluorouracil, leucovorin and oxaliplatin). Unfortunately, he died of a disease- or treatment- unrelated accident 5 months after the discharge.

Conclusion The thorough drainage combined with antibiotic treatment is able to eliminate empyema without the need for a specific thoracoscopy or thoracic surgery for patients with intrathoracic leakage.

Key Words:

Gastric cardiac carcinoma; intrathoracic leakage; management

J Thorac Dis 2010; 2: 180-184. DOI: 10.3978/j.issn.2072-1439.2010.02.03.11

Intrathoracic anastomotic leakage is often taken as a complication of thoracic surgery (1,2). On the other hand, almost all reported leakages resulted from radical total gastrectomy with an end-to-side esophagojejunostomy are abdominal. In 2008, there was a patient who underwent gastrectomy due to gastric cardiac carcinoma and developed an anastomotic leakage into thoracic cavity in our department. Here, we present this case along with the management experience.

Case report

A 64-year-old male patient was admitted to our department, because of epigastric discomfort for 4 years. Upper gastroendoscopy revealed that the dentate line almost disappeared, and an ulcer of 4 cm×3 cm was discovered under the dentate line in the lesser gastric curvature. Histopathological

examination under gastroscopy confirmed that the lesion was poorly differentiated ulcerative adenocarcinoma (Fig 1). Distant metastasis was excluded by computed tomography scan and ultrasonography. The patient underwent radical total gastrectomy with R0 lymphadenectomy by the Moynihan-type procedure (intraabdominal end-to-side esophagojejunostomy with Braun anastomosis). Histopathological examination of the dissected tumor and surrounding tissues, including 4 cm of esophagus, showed a negative margin, proved preoperative gastroscopic diagnosis and that among 22 excised lymphatic nodes, 5 were positive for metastasis. The tumor stage was T3N1M0.

The patient recovered 7 days after the surgery. However, he started to cough with a small amount of white sputa, and an elevated white blood cell count $10.96 \times 10^9/L$ with neutrophils being 82.4%. The body temperature was normal and there were no any other symptoms. A chest radiograph revealed a broadened mediastinum and bilateral reactive pleural effusion with a vague heart image (Fig 2). The patient was treated with cefazolin 2 g, *b.i.d.*, intravenous infusion, and the coughing was gradually alleviated, but persisted, with the white blood cell count increasing to $14.4 \times 10^9/L$ and neutrophils to 91.7%. However, on day 13, the body temperature increased to over 38°C the first time after the surgery. The white blood cell count was even higher ($16.09 \times 10^9/L$ with neutrophils being 91.7%) although the repeat radiograph showed slightly narrowed mediastinum

No potential conflict of interest.

Correspondence to: Ling Wang, MD. Department of Vascular and Endocrine Surgery, First Affiliated Hospital, Fourth Military Medical University, No. 17, Changle West Road, Xi'an 710032, Shaanxi Province, PR China. Tel & Fax: +86-29-84775267;. E-mail: prof.wangling@gmail.com.

Submitted June 1, 2010. Accepted for publication August 1, 2010.

Available at www.jthoracdis.com

ISSN: 2072-1439 © 2010 Journal of Thoracic Disease. All rights reserved.

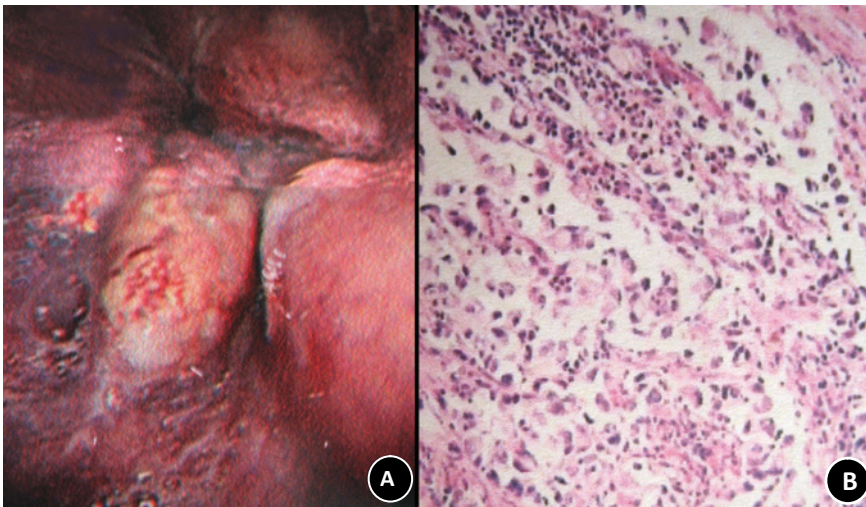


Fig 1. Histopathological diagnosis of a gastric cardiac adenocarcinoma: An ulcer of 4cm×3cm (A) under the dentate line, poorly differentiated adenocarcinoma (H&E staining×50) (B).

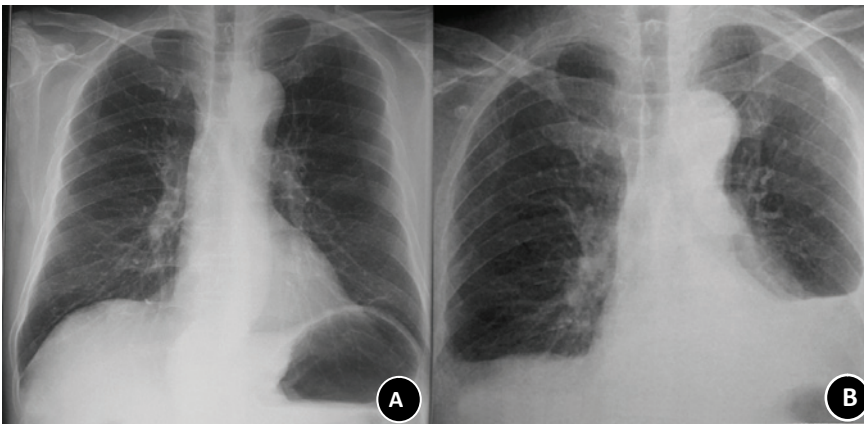


Fig 2. Comparison of the chest radiographs before (A) and 7 days after the surgery (B). In contrast to A, B reveals a corpulent mediastinum, vague costophrenic angles and heart shadow, which might be resulted from the anastomotic leakage into the mediastinum and subsequent bilateral reactive pleural effusion.

with little pleural effusion. Then, cefazolin was replaced with ceftriaxone (Rocephin, 2 g, *b.i.d.*, intravenous infusion) the next day. The patient could have a rest on day 19, but slight coughing and high temperature (about 38°C) and elevated white blood cell count ($> 10.0 \times 10^9/L$) remained.

In order to make a definite diagnosis of the cause for coughing, fever and the elevated white blood cell count, a contrast radiography was performed on day 18 after the surgery, which showed a leakage through which the contrast medium was leaked from the orifice of the anastomosis to the right thoracic cavity, with apparent right pleural effusion (Fig 3A, Fig 3B). In the meantime, pleural effusion cultures were carried out, and *Enterococcus faecium*, which was susceptible to vancomycin, was isolated.

On day 20, a pigtail catheter (1.5 mm in diameter) was percutaneously placed into the right thoracic cavity guided by ultrasonography for drainage of the pleural effusion (Fig 3C). On day 22, ceftriaxone was discontinued when the culture result was received. On day 23, the patient was treated with

vancomycin (0.5 g, *b.i.d.*, intravenous infusion) for 5 days, and then with Tienam (Imipenem/cilastatin, 1 g, *b.i.d.*, intravenous infusion) for 3 days. However, on day 28, the body temperature jumped to over 39°C, for the first time since the surgery, and reached 39.2°C. Fluconazole, 0.2 g, once per day, intravenous infusion, was administered empirically, and the temperature was controlled under 39°C, still around 38°C. On day 30, a larger chest tube (8 mm in diameter) was used to replace the small one, which effectively drained the pleural effusion. Two days later when the temperature and other conditions were stabilized, a pre-scheduled therapeutic upper endoscopy was performed, which showed a defect about 8mm×8mm in the right posterior of the anastomosis. During the endoscopy, a covered metallic stent (8 cm in length, 1.6-2.2 cm in diameter) was applied to seal the fistulous orifice (Fig 4A), and a nutrition tube was placed into the distal efferent loop to feed supplements. A follow up contrast radiography performed 9 days after the therapeutic endoscopy revealed complete sealing of the fistulae (Fig 5), and the temperature fell to normal. The patient gradually recovered

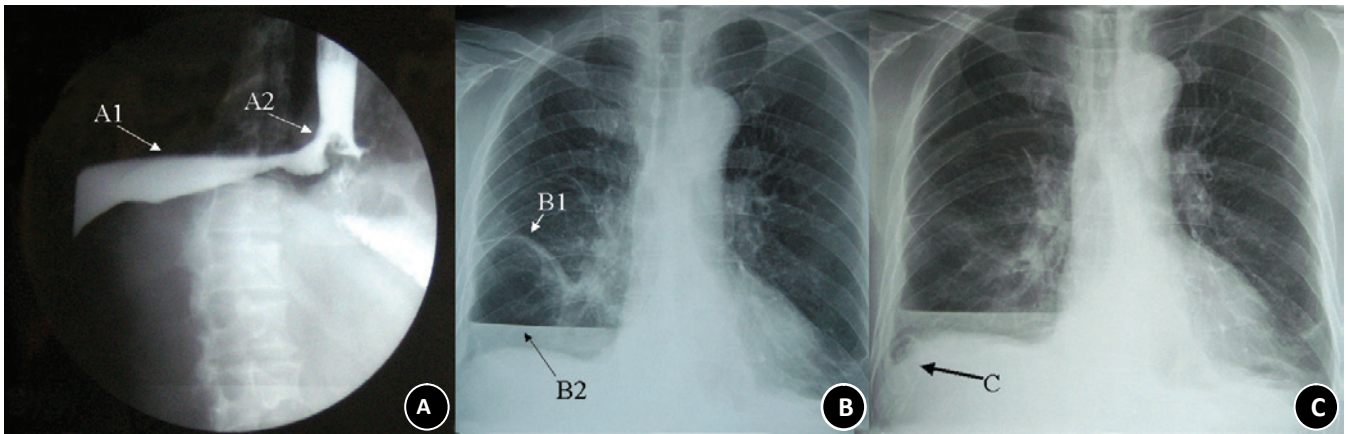


Fig 3. A contrast radiograph (A) and a plain radiograph (B) on day 18 after the operation, and a plain radiograph (C) on day 20 after the surgery. In the image A, the contrast medium (arrow A1) is traced from the orifice (arrow A2) into the right thoracic cavity. In image B, the right fissura interlobaris (arrow B1) is visible, and the fistulae fluid and contrast medium (arrow B2) accumulate in the right thoracic cavity. In image C, a drainage tube (arrow C) is percutaneously placed into the right thoracic cavity directed by ultrasonography.

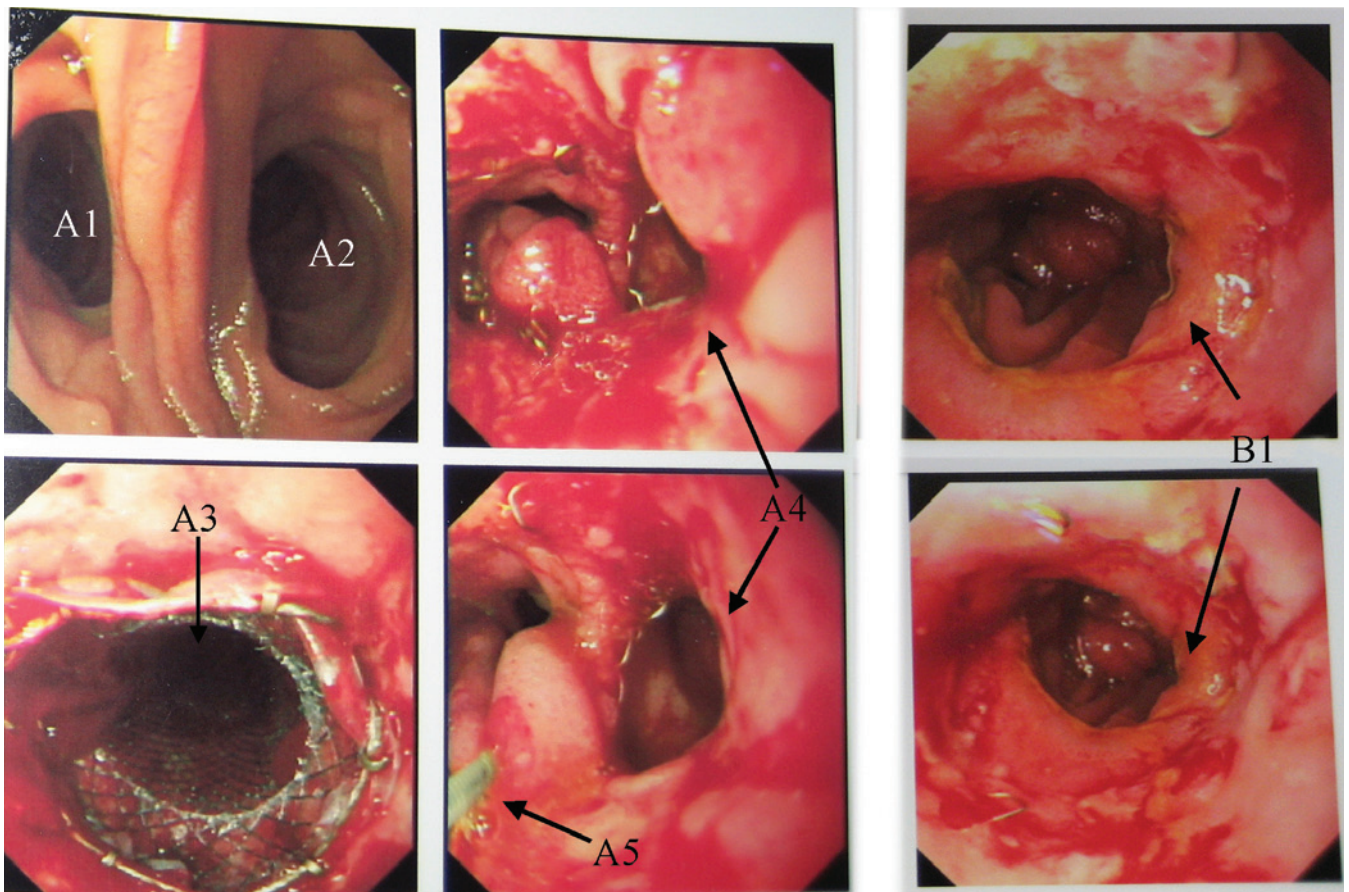


Fig 4. Gastroscopic procedures performed on days 32 (A) and 68 (B), respectively. Figure A shows that the efferent loop (A1) and afferent loop (A2) are unobstructive, a covered metallic stent (A3) about 8 cm in length which has been placed into the efferent loop, seals the fistula stoma (A4) to the thoracic cavity, together with a nutrition tube (A5) to the distal efferent loop, and figure B shows that the fistulae has been healed (B1) with the stent being retrieved.

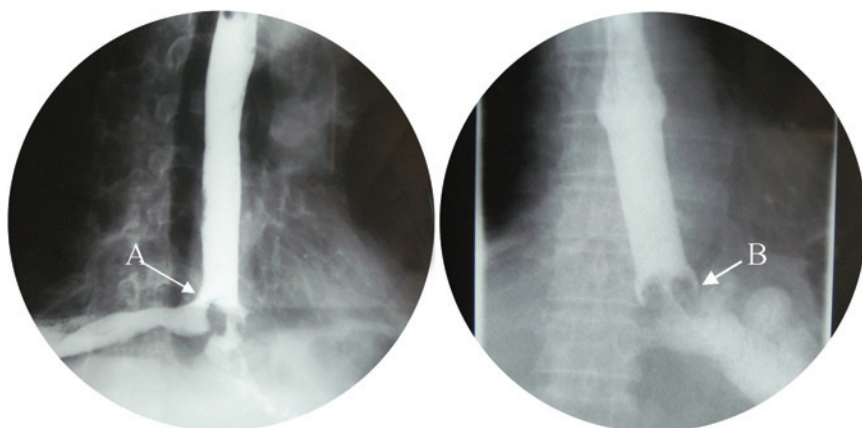


Fig 5. Contrast radiography performed on day 18 after the surgery (A), and on day 4 after insertion of the metallic stent (B). The fistula stoma is present in the image A (arrow A), but not seen in the same position in image B. In image B, since the horn shaped end of the stent (arrow B) does not exactly match with the jejunum, refluxed fluid enters the gap between the stent and jejunal wall. So, there was still a small amount of fluid observed to flow into the thoracic cavity when contrast radiography is dynamically monitored, although the fistula stoma is not seen in the static image.

without any symptoms and the white blood cell count decreased to $6.90 \times 10^9/L$. One month after the therapeutic endoscopy, the patient resumed to a semi-liquid diet. One week later, the stent was endoscopically removed with the fistulae being healed (Fig 4B), and the patient was discharged from the hospital without leakage management-related complications. Initially, the patients complained of intermittent episodes of reflux esophagitis, which could be resolved by treatment with cisapride, or by intaking less liquid food. The patient then received 4 cycles of adjuvant chemotherapy with regimen of FOLFOX4 (fluorouracil, leucovorin and oxaliplatin). Unfortunately, he died of a disease- or treatment- unrelated accident 5 months after the discharge.

Discussion

The diagnosis of anastomotic leakage into thoracic cavity was not primarily suspected and thus delayed because our initial attention was paid to the abdominal, not thoracic cavity, and the symptoms in the chest were not typical due to antibiotic treatment. Then, we speculated that a leakage of the anastomosis to the abdomen might have occurred. However, to our surprise, the contrast radiography revealed a leakage into the thoracic cavity. Having searched in six databases from their inception to December 2009: Medline, Embase, PubMed, Cochrane Central Register of Controlled Trials, Cochrane Database of Systematic Reviews, and Database of Abstracts of Review of Effectiveness, we could not find any previous report that describes an intraabdominally performed esophagojejunostomy with a subsequent leakage to the thoracic cavity.

Theoretically, we believe that this rare complication occurred because of the fact that the tumor was located at a high site of the stomach, and the operators had to drag down the esophagus during the surgical procedures in order to get a negative incision margin. After the surgery, the remnant esophagus was retracted back into the thoracic cavity, bringing the anastomosis to the

thoracic cavity as well. Subsequently, the leakage occurred due to the increased tension of the anastomosis and the possibility of ischemia. Therefore, surgeons must keep in mind that a transabdominal incision has a risk for thoracic leakage in cases who require radical incision and esophagojejunostomy, and a transthoracic incision or combined thoracoabdominal incision may be a safer and more appropriate option (3-6). Furthermore, a study of 285 patients with esophagojejunal anastomosis revealed that Orr-type Roux-en-Y reconstruction method was superior to the Moynihan-type in the case of the digestive reconstruction, since it needs shorter operation time, and more importantly, it effectively prevents reflux and thus improves postoperative quality of life (7-10).

Previous studies have suggested that in case of leakage, reoperation can be considered when the anastomotic stoma is large, but with a high mortality (2,11). In those patients who are unwilling or too weak to receive reoperation, the covered metallic stent is a method to save lives (1, 12-17). In our case, we successfully sealed the fistulous orifice with a covered metallic stent under upper endoscopy, and all leakage-related symptoms were resolved. However, it should be noticed that the esophageal reflux occurred in the patient after the surgery, but the symptoms could be resolved with cisapride or less liquid diet. Indeed, it was also observed that there was a small amount of fluid entering into the thoracic cavity when contrast radiography was dynamically monitored. These findings indicate that the lower end of the stent we used in this case might not be able to prevent the reflux of the intestinal fluid secreted from the intestines (Fig 5, Fig 6). Thus, drugs such as cisapride or avoidance of liquid diet are needed if the type of stent we used in our case is to be applied. Alternatively, a more "intellective" stent that can prevent the reflux needs to be invented to achieve a better performance.

Moynihan-type procedure is not an optimal option in patients with gastric cardiac carcinoma because of the esophageal reflux. A transthoracic or combined thoracoabdominal incision, but not

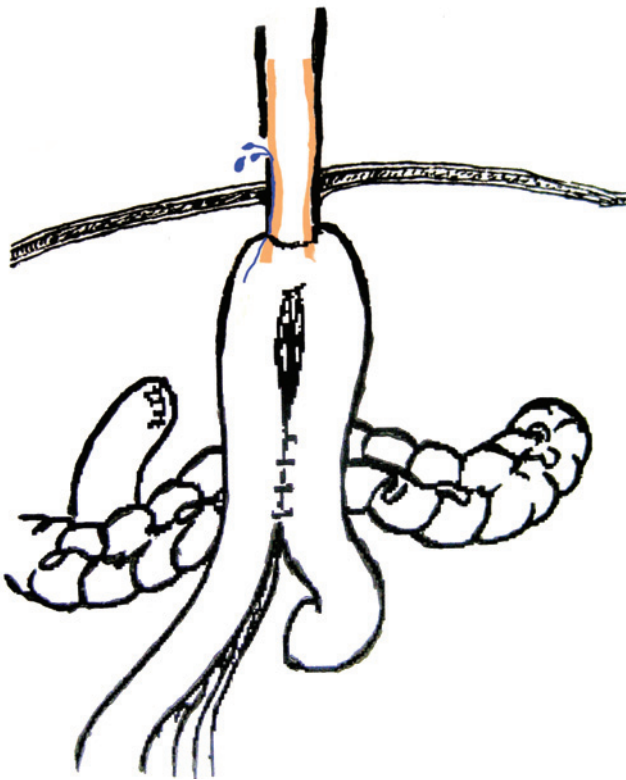


Fig 6. An illustration showing reflux of intestinal fluid into the thoracic cavity. The blue color indicates that the refluxed intestinal fluid could leak from the gap between the stent (brown color) and the jejunal wall to the thoracic cavity through the orifice.

an intraabdominal incision, i.e. Pinotti's operation, is advisable when the tumor is at a high site of the stomach; thorough drainage rather than thoracoscopically therapy or thoracotomy is enough to eliminate empyema in combination with antibiotics and effective sealing of the fistulae, and a covered retrievable metallic stent is an appropriate way to seal the fistulae, although further modifications of the stent are needed to make it more applicable.

In conclusion, the thorough drainage combined with antibiotic treatment is able to eliminate empyema without the need for a specific thoracoscopy or thoracic surgery for patients with intrathoracic leakage.

References

1. Profili S, Feo CF, Cossu ML, Scanu AM, Scognamillo F, Meloni F, et al. Effective management of intrathoracic anastomotic leak with covered self-expandable metal stents. Report on three cases. *Emerg Radiol* 2008;15:57-60.
2. Kakavoulis TN, Avgoustou CC, Koniaris HG, Penlidis PC. Subcutaneous esophagojejunal reconstruction in the management of esophagogastric anastomotic leak: a staged procedure. *Dis Esophagus* 2005;18:345-8.
3. Meyer L, Meyer F, Dralle H, Ernst M, Lippert H, Gastinger I, et al. Insufficiency risk of esophagojejunal anastomosis after total abdominal gastrectomy for gastric carcinoma. *Langenbecks Arch Surg* 2005;390:510-6.
4. Orringer MB, Marshall B, Iannettoni MD. Transhiatal esophagectomy: clinical experience and refinements. *Ann Surg* 1999;230:392-400.
5. Cicetti M, Corinaldesi F, Costantini PG, Stafoggia P, Tamburini A, Tinti A. 172 consecutive total gastrectomies for gastric cancer with Roux-en-Y loop reconstruction and without fistulization of the esophago-jejunal anastomosis. *Tumori* 2003;89:29-31. (in Italian)
6. Pesko P, Bjelovic M, Stojakov D, Sabljak P. Modified stapling technique of esophagojejunal anastomosis. *Dis Esophagus* 2002;15:303-4.
7. Wei HB, Wei B, Zheng ZH, Zheng F, Qiu WS, Guo WP, et al. Comparative study on three types of alimentary reconstruction after total gastrectomy. *J Gastrointest Surg* 2008;12:1376-82.
8. Ong AM, Tan CS, Foo MW, Kee TY. Gabapentin for intractable hiccups in a patient undergoing peritoneal dialysis. *Perit Dial Int* 2008;28:667-8.
9. Turkyilmaz A, Eroglu A. Use of baclofen in the treatment of esophageal stent-related hiccups. *Ann Thorac Surg* 2008;85:328-30.
10. Chang CC, Chang YC, Chang ST, Chang WK, Chang HY, Chen LC, et al. Efficacy of near-infrared irradiation on intractable hiccup in custom-set acupoints: evidence-based analysis of treatment outcome and associated factors. *Scand J Gastroenterol* 2008;43:538-44.
11. Lang H, Piso P, Stukenborg C, Raab R, Jähne J. Management and results of proximal anastomotic leaks in a series of 1114 total gastrectomies for gastric carcinoma. *Eur J Surg Oncol* 2000;26:168-71.
12. Babor R, Talbot M, Tyndal A. Treatment of upper gastrointestinal leaks with a removable, covered, self-expanding metallic stent. *Surg Laparosc Endosc Percutan Tech* 2009;19:e1-4.
13. Leers JM, Vivaldi C, Schäfer H, Bludau M, Brabender J, Lurje G, et al. Endoscopic therapy for esophageal perforation or anastomotic leak with a self-expandable metallic stent. *Surg Endosc* 2009;23:2258-62.
14. Schubert D, Scheidbach H, Kuhn R, Wex C, Weiss G, Eder F, et al. Endoscopic treatment of thoracic esophageal anastomotic leaks by using silicone-covered, self-expanding polyester stents. *Gastrointest Endosc* 2005;61:891-6.
15. Doniec JM, Schniewind B, Kahlke V, Kremer B, Grimm H. Therapy of anastomotic leaks by means of covered self-expanding metallic stents after esophagogastrectomy. *Endoscopy* 2003; 35:652-8.
16. Kwak HS, Lee JM, Jin GY, Han YM, Yang DH. Treatment of gastrojejunal anastomotic leak with a covered metallic stent. *Hepatogastroenterology* 2003;50:62-4.
17. Kauer WK, Stein HJ, Dittler HJ, Siewert JR. Stent implantation as a treatment option in patients with thoracic anastomotic leaks after esophagectomy. *Surg Endosc* 2008;22:50-3.