

Outcomes of patients undergoing surgery for thymic carcinoma: a single-center experience

Yusuke Nabe, Yoshinobu Ichiki, Yukiko Fukuichi, Masataka Mori, Yohei Honda, Masatoshi Kanayama, Akihiro Taira, Shinji Shinohara, Taiji Kuwata, Masaru Takenaka, Yasuhiro Chikaishi, Soichi Oka, Ayako Hirai, Yuko Tashima, Koji Kuroda, Naoko Imanishi, Kazue Yoneda, Fumihiko Tanaka

Second Department of Surgery, School of Medicine, University of Occupational and Environmental Health, Kitakyushu, Japan

Contributions: (I) Conception and design: Y Nabe, Y Ichiki, N Imanishi, K Yoneda, F Tanaka; (II) Administrative support: Y Fukuichi, S Oka, Y Tashima, K Kuroda; (III) Provision of study materials or patients: M Kanayama, M Takenaka; (IV) Collection and assembly of data: Y Honda, A Taira, T Kuwata; (V) Data analysis and interpretation: M Mori, S Shinohara, A Hirai; (VI) Manuscript writing: All authors; (VII) Final approval of manuscript: All authors.

Correspondence to: Yoshinobu Ichiki, MD, PhD. Second Department of Surgery, School of Medicine, University of Occupational and Environmental Health, 1-1 Iseigaoka, Yahatanishi-ku, Kitakyushu 807-8555, Japan. Email: y-ichiki@med.uoeh-u.ac.jp.

Background: Thymic carcinoma is uncommon, presents locally at an advanced stage, and behaves aggressively. The optimum treatment for advanced thymic carcinoma is controversial. We retrospectively reviewed our institutional experience with patients with thymic carcinoma.

Methods: We analyzed the clinical data of six patients who underwent total thymectomy for thymic carcinoma at our institution from 2006 to 2016. Variables analyzed included sex, age, histological classification, Masaoka staging, postoperative treatment, and recurrence.

Results: The clinical characteristics of the six patients with thymic carcinoma (median age, 56 years; five men and one woman) were as follows: squamous cell carcinoma (n=5); sarcomatoid carcinoma (n=1); Masaoka stages II (n=1), III (n=2), IVa (n=1), and IVb (n=2). Four patients underwent combined pulmonary resection (66.7%) as a component of en bloc resection due to suspicion of pulmonary invasion. Four patients (66.7%) received postoperative therapy, and complete resection was achieved for four patients. There were no perioperative deaths. One patient experienced a recurrence.

Conclusions: Complete resection for thymic cancer improved the prognosis of our patients, indicating that robust studies will be required to confirm our findings.

Keywords: Thymic carcinoma; surgery; oncology

Submitted Apr 10, 2018. Accepted for publication May 22, 2018.

doi: 10.21037/jtd.2018.06.36

View this article at: <http://dx.doi.org/10.21037/jtd.2018.06.36>

Introduction

Thymic carcinoma is rare (10–15% of thymic epithelial tumors), typically presents locally at an advanced stage, behaves aggressively, and lymphatic or distant metastases are frequent (1-3). Complete surgical resection is not always possible for patients with advanced-stage thymic carcinoma because of local regional invasion. Limited data are available concerning the outcomes of unusual patients after resection of thymic carcinoma judged potentially resectable,

with or without neoadjuvant treatment. We therefore retrospectively reviewed our institutions' experience with patients with thymic carcinoma.

Methods

Patients

Six patients with thymic carcinoma underwent surgical resection at our hospital from 2006 to 2016. We evaluated

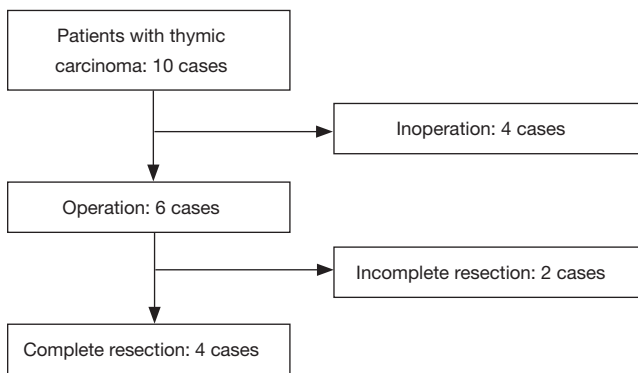


Figure 1 Study flow diagram of the patient population

Table 1 Characteristics of the operative patients

Characteristics	Value
Age, median [range], years	50 [40–60]
Gender, n	
Male	5
Female	1
Symptoms, n	
With	3
Without	3
Treatment (operation), n	
Complete resection	4
Incomplete resection	2
Pathological type, n	
Squamous cell carcinoma	5
Sarcomatoid carcinoma	1
Masaoka stage, n	
II	1
III	2
IVa	1
IVb	2

the association of outcomes with sex, age, histological classification, Masaoka staging, postoperative treatment, and recurrence. Perioperative death was defined as occurring within 30 days after resection. A complete resection, classified as R0, was defined as the pathological demonstration of negative tissue margins and assessment

by the surgeon that all detectable disease was removed. Our institution's ethics committee approved this study.

Patient follow-up

Patients' records were reviewed for preoperative symptoms, surgical procedures, and postoperative complications. The patients were examined at 1- or 3-month intervals for ≥ 5 years. To detect recurrence, we performed physical examinations, routine hematological analyses, chest radiography, computed tomography (CT) of the chest and upper abdomen, magnetic resonance imaging of the brain, and bone scintigraphy.

Results

Ten patients with thymic carcinoma underwent total thymectomy, four underwent curative resection, and none received preoperative induction therapy (Figure 1). The clinical characteristics of the six patients with thymic carcinoma (median age, 56 years; five men and one woman) were as follows: squamous cell carcinoma (n=5); sarcomatoid carcinoma (n=1); and Masaoka stages II (n=1), III (n=2), IVa (n=1), and IVb (n=2) (Table 1). A summary of the patients who underwent surgery is shown in Table 2. There was no perioperative death. Four patients underwent combined pulmonary resection (66.7%) as a component of *en bloc* resection due to suspicion of pulmonary invasion. Four patients (66.7%) received postoperative therapy, and complete resection was achieved for four patients. There were no perioperative deaths. One patient experienced a recurrence. We previously reported patient number 2 (4).

We performed complete resection of the thymic sarcomatoid carcinoma, which is extremely rare, through a total aortic arch replacement and left upper lobectomy. Our aggressive surgical procedure was very effective, and the patient remains recurrence-free 4 years after surgery.

Discussion

Thymic carcinoma is uncommon, presents locally at an advanced stage, and behaves aggressively. The optimum treatment for advanced thymic carcinoma is controversial. There are few reports of improved survival of patients who underwent complete resection to treat thymic carcinoma (1). For example, median survival is 24.9 months, and the 5-year survival rate is 42.3%, similar to the respective survival data

Table 2 Summary of the operative patients

Case	Age (years)	Gender	Combined	Resectability	Pathological type	Stage	Postoperative therapy	Observation period (months)	Recurrence	Survival
1	64	M	None	R0	Sq.	II	CRT	23	+	Alive
2	48	M	Lung, aorta, brachio. vein	R0	Sar.	III	None	48	-	Alive
3	56	M	Lung, pericardium	R0	Sq.	IVb	RT	33	-	Dead
4	40	M	None	R0	Sq.	IVb	None	92	-	Alive
5	63	M	Lung, brachio. vein, pericardium	R2	Sq.	III*	RT	62	Remained	Alive
6	56	F	Lung, pericardium	R2	Sq.	IVa*	RT	40	Remained	Dead

*, clinical stage. Sq., squamous cell carcinoma; Sar., sarcomatoid carcinoma; brachio. vein, brachiocephalic vein; CRT, chemoradiotherapy; RT, radiotherapy.

Table 3 A review of the literature

Ref. number	Number of patients	Number of CR (%)	OS at 5 years (%)	OS of CR cases at 5 years (%)	Prognostic factors
(6)	1,042	447 (42.9)	60	70	Resectability, postoperative RT
(7)	306	181 (59.2)	61	75	Masaoka stage, resectability
(8)	290	121 (41.7)	40	58	Gender, Masaoka stage

for 30–50% of patients with thymic carcinomas (5).

Complete resection is useful for treating thymic carcinoma, given the lack of efficacy of chemotherapy and radiotherapy. In present analysis, no patient who underwent complete resection died, and three of four patients remain recurrence-free. Although an inherent limitation of any study of thymic carcinoma is the small number of patients, our findings should nevertheless persuade oncologists to seriously consider offering their patients the option of complete resection.

Our review of the literature about the prognosis of thymic carcinoma is shown in *Table 3*. Ahmad *et al.* reported that postoperative radiotherapy for patients with thymic carcinoma improves survival (6). The four patients (66.7%) studied here who underwent radiotherapy after surgery did not experience recurrence or regrowth. Moreover, patient number 5 is alive without regrowth more than 5 years after incomplete resection (R2).

One patient with Masaoka stage III underwent total

thymectomy comprising resection of the lung, pericardium, and the left brachiocephalic vein. When postoperative radiotherapy was administered, regrowth was not observed. Therefore, postoperative radiotherapy may be effective when resection is incomplete.

The Masaoka stage has significant prognostic implications (6–8). Patients with advanced thymic carcinoma classified as Masaoka stages II–IV who undergo surgery are offered postoperative radiotherapy. Moreover, patients with thymic carcinoma who undergo incomplete resection are offered postoperative chemoradiotherapy. Here, our patient with Masaoka stage II thymic carcinoma underwent postoperative radiotherapy. Some studies report that incomplete surgical resection does not adversely affect long-term survival of patients who are administered postoperative cisplatin-based chemotherapy (9). Furthermore, other studies report that complete resection of a thymic carcinoma significantly increases survival (1,6,7,10,11). The present analyses demonstrate that complete resection

achieved improved outcomes.

Conclusions

We conclude that complete resection of thymic carcinoma improved survival outcomes and that oncologists should offer this treatment option to patients, particularly those with advanced disease.

Acknowledgements

None.

Footnote

Conflicts of Interest: The authors have no conflicts of interest to declare.

Ethical Statement: This study was approved by the ethics committee of University of Occupational and Environmental Health (No. H26-15).

References

1. Kondo K, Monden Y. Therapy for thymic epithelial tumors: a clinical study of 1,320 patients from Japan. *Ann Thorac Surg.* 2003;76:878-84; discussion 884-5.
2. Marx A, Rieker R, Toker A, et al. Thymic carcinoma: is it a separate entity? From molecular to clinical evidence. *Thorac Surg Clin* 2011;21:25-31. v-vi.
3. Ruffini E, Detterbeck F, Van Raemdonck D, et al. Thymic carcinoma: a cohort study of patients from the European society of thoracic surgeons database. *J Thorac Oncol* 2014;9:541-8.
4. Oka S, Taira A, Shinohara S, et al. Complete Resection of Thymic Sarcomatoid Carcinoma Through Total Aortic Arch Replacement. *Ann Thorac Surg* 2016;102:e557-9.
5. Eng TY, Fuller CD, Jagirdar J, et al. Thymic carcinoma: state of the art review. *Int J Radiat Oncol Biol Phys* 2004;59:654-64.
6. Ahmad U, Yao X, Detterbeck F, et al. Thymic carcinoma outcomes and prognosis: results of an international analysis. *J Thorac Cardiovasc Surg* 2015;149:95-100, 101.e1-2.
7. Hishida T, Nomura S, Yano M, et al. Long-term outcome and prognostic factors of surgically treated thymic carcinoma: results of 306 cases from a Japanese Nationwide Database Study. *Eur J Cardiothorac Surg* 2016;49:835-41.
8. Weksler B, Dhupar R, Parikh V, et al. Thymic carcinoma: a multivariate analysis of factors predictive of survival in 290 patients. *Ann Thorac Surg* 2013;95:299-303.
9. Hernandez-Ilizaliturri FJ, Tan D, Cipolla D, et al. Multimodality therapy for thymic carcinoma (TCA): results of a 30-year single-institution experience. *Am J Clin Oncol* 2004;27:68-72.
10. Tseng YL, Wang ST, Wu MH, et al. Thymic carcinoma: involvement of great vessels indicates poor prognosis. *Ann Thorac Surg* 2003;76:1041-5.
11. Yano M, Sasaki H, Yokoyama T, et al. Thymic carcinoma: 30 cases at a single institution. *J Thorac Oncol* 2008;3:265-9.

Cite this article as: Nabe Y, Ichiki Y, Fukuichi Y, Mori M, Honda Y, Kanayama M, Taira A, Shinohara S, Kuwata T, Takenaka M, Chikaishi Y, Oka S, Hirai A, Tashima Y, Kuroda K, Imanishi N, Yoneda K, Tanaka F. Outcomes of patients undergoing surgery for thymic carcinoma: a single-center experience. *J Thorac Dis* 2018;10(7):4283-4286. doi: 10.21037/jtd.2018.06.36