

Hemorrhage of a pancreatic metastasis from lung adenocarcinoma after osimertinib therapy

Kazuki Hayasaka¹, Satoshi Shiono¹, Naoki Yanagawa², Kei Yarimizu¹, Katsuyuki Suzuki¹, Makoto Endoh¹

¹Department of Thoracic Surgery, ²Department of Pathology, Yamagata Prefectural Central Hospital, Yamagata, Japan

Correspondence to: Satoshi Shiono. Department of Thoracic Surgery, Yamagata Prefectural Central Hospital, 1800, Ooazaoyagi, Yamagata 990-2292, Japan. Email: sshiono@ypch.gr.jp.

Submitted Feb 20, 2018. Accepted for publication Aug 15, 2018.

doi: 10.21037/jtd.2018.08.108

View this article at: <http://dx.doi.org/10.21037/jtd.2018.08.108>

Introduction

Osimertinib is an epidermal growth factor receptor tyrosine kinase inhibitor (EGFR-TKI). It is used as anti-cancer therapy in patients with EGFR-TKI sensitizing mutations and EGFR T790M mutations and is recommended for treatment of patients with EGFR T790M-positive advanced non-small cell lung cancer (NSCLC) after progression on first-line EGFR-TKIs or frontline treatment in EGFR mutation-positive (exon 19 deletion or L858R) advanced NSCLC (1,2). Common adverse effects of osimertinib are similar to other EGFR-TKIs and are generally mild in severity and reversible (1). Previous reports have suggested an association between gefitinib or erlotinib treatment and organ bleeding or tumor hemorrhage (3-8). But to date there have been no reports of a similar association between osimertinib and tumor hemorrhage. Herein, we report an unusual case of hemorrhage of a pancreatic metastasis from lung adenocarcinoma after osimertinib therapy.

Case presentation

A 73-year-old female non-smoker was referred to our hospital due to growing lung tumors despite gefitinib treatment. Seven years before admission, she received gefitinib treatment for lung adenocarcinoma in the right upper lobe with multiple lung metastases harboring EGFR mutations including exon 19 deletion and exon 21 L858R (clinical stage IV, TMN classification seventh edition) (9). Following gefitinib treatment, she had achieved a partial response for 6 years. However, at the time she was referred to our institution, chest computed tomography (CT) showed the regrowth of a solitary 2.2 cm lung nodule and

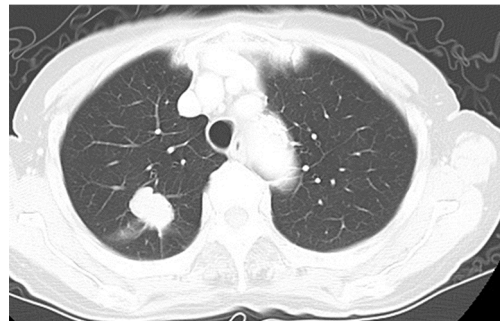

Figure 1 Chest computed tomography (CT) at the time when the patient was referred to our hospital. CT showed a solitary 2.2 cm lung nodule in the right upper lobe.

non-growing pure ground glass nodules in the right upper lobe (*Figure 1*). Whole body CT and positron emission tomography/CT did not show lymph node involvement or distant metastases.

She was diagnosed with lung cancer, ycT1bN0M0, stage IA, and underwent right upper lobectomy and systematic lymph node dissection. The pathological diagnosis was papillary adenocarcinoma, with elements of adenocarcinoma *in situ* and minimally invasive adenocarcinoma in the same lobe [pathological stage: ypT1b(m)N0M0, stage IA]. Notably, the EGFR T790M mutation was identified in the surgical specimen. After surgery, the patient was doing well and did not receive any adjuvant treatment because there were no evaluable diseases and osimertinib was not available at the time. Ten months after surgery, a brain metastasis developed and stereotactic radiation therapy was performed. Twenty-two months after surgery, contrast enhanced abdominal CT revealed a pancreatic tumor (*Figure 2A*)

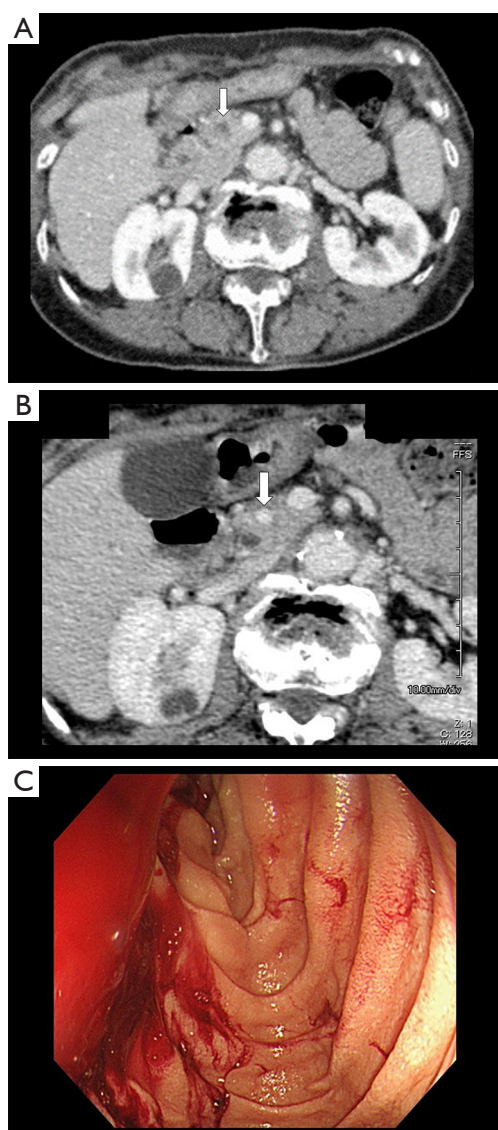


Figure 2 Image findings of the pancreatic metastasis from lung adenocarcinoma. Computed tomography (CT) demonstrated a pancreatic metastasis (white arrow) (A). Six months after administration of osimertinib, CT showed metastatic tumor regression and hemorrhage in the accessory pancreatic duct (white arrow) (B). Upper endoscopy showed active bleeding from the papilla of Vater (C).

and endoscopic ultrasound-guided fine needle biopsy identified the tumor as a pancreatic metastasis from lung adenocarcinoma containing the EGFR T790M mutation. She was treated with osimertinib at a daily dose of 80 mg, resulting in marked metastatic tumor regression.

Six months after administration of osimertinib, she

complained of upper abdominal pain and tarry stool. This patient did not have any comorbidities or receive any medication that may increase the risk of bleeding. Blood chemistry showed anemia without coagulopathy and the platelet count was in the normal range. Contrast enhanced abdominal CT revealed metastatic tumor regression and hemorrhage in the accessory pancreatic duct (Figure 2B). Upper endoscopy showed active bleeding from the papilla of Vater (Figure 2C). We suspected hemorrhage from the pancreatic metastasis and stopped osimertinib. Bleeding control by endoscope or angiographic embolization was difficult and the patient was therefore treated conservatively with multiple blood transfusions. Fortunately, the bleeding spontaneously stopped. The patient is still alive and has had no recurrent bleeding at 3 years after surgery but has had progression of the brain metastasis.

Discussion

The T790M mutation is one of the EGFR mutations that causes EGFR-TKI resistance. Based on the results of phase III clinical trials, osimertinib has been recommended for treatment of NSCLC patients with the T790M mutation whose disease has progressed on other EGFR-TKIs or frontline treatment in EGFR mutation-positive (exon 19 deletion or L858R) advanced NSCLC (1,2). The common adverse effects of osimertinib are similar to other EGFR-TKIs, and involve the skin (e.g., rash, dry skin, paronychia, and pruritus), gastrointestinal tract (e.g., diarrhea, nausea, and decreased appetite) and liver. Among the patients receiving osimertinib treatment, these events occur less often and milder in severity than those receiving other EGFR-TKIs (1,10).

EGFR-TKIs, including osimertinib, have only rarely been considered to increase the risk of organ bleeding. Some recent reports have described organ bleeding, such as diffuse alveolar hemorrhage, subdural hemorrhage, and gastrointestinal bleeding, and have suggested an association with gefitinib or erlotinib treatment (3-7). Yan *et al.* reported two cases of hemorrhage from brain metastases after gefitinib treatment for NSCLC; one case occurred 1 month after gefitinib combined with whole brain radiation therapy and the other case slowly developed hemorrhage within brain metastases after 8 months of gefitinib monotherapy (8). Although it is unclear if these reported hemorrhages were specifically due to EGFR-TKIs therapy, it is possible that EGFR-TKIs increase the risk of bleeding. In an *in vitro* study, Guillamo *et al.* reported that gefitinib had an antiangiogenic effect on tumor cells with the

EGFR mutation (11). Avascular necrosis or post-ischemic hemorrhage due to EGFR-TKIs therapy could explain the hemorrhage from metastatic tumors.

Gastrointestinal (GI) bleeding due to hemorrhage of pancreatic metastatic tumors from lung cancer is rare. Zheng *et al.* reported two cases of GI bleeding due to pancreatic metastasis of lung cancer (12). Both patients underwent surgical resection for lung adenocarcinoma and were diagnosed with pancreatic metastasis after they developed symptoms such as melena or epigastric pain. One patient could not receive chemotherapy, resulting in continuous GI bleeding and death due to respiratory failure, and another patient was treated with chemotherapy, which stopped the bleeding. These cases were different from our case in that the hemorrhagic pancreatic metastases were diagnosed before chemotherapy, suggesting that tumor growth might be associated with hemorrhage.

This case is uncommon in the point of the indolent EGFR mutant disease with a long disease progression free period. We chose surgery for the regrowth of the pulmonary nodule without EGFR-TKI treatment after biopsy for the following reasons: First, osimertinib treatment was not available when the regrowth of the pulmonary nodule was observed; Second, the regrowth of the lung nodule was limited at the right upper lobe and therefore we considered it as oligo-recurrence. The local treatment may be associated with better survival for oligo-recurrence patients (13). In the present case, we thought that the surgery was an acceptable therapeutic option. Furthermore, harboring the compound mutation of exon 19 deletion and exon 21 L858R is also uncommon. It was reported that the incidence of this compound mutation is 0.5% to 1.6% among EGFR mutation-positive lung adenocarcinoma (14,15) and the efficacy of EGFR-TKI may differ from single mutation (14-16).

To the best of our knowledge, this is the first published case of an association between hemorrhage from a pancreatic metastasis due to lung adenocarcinoma and osimertinib treatment. Although it is difficult to determine whether the hemorrhage was an adverse effect of osimertinib, we suspect that osimertinib may have contributed to the hemorrhage because recurrent bleeding was not observed after cessation of treatment. Physicians and patients should be aware that osimertinib may increase the risk of bleeding.

Acknowledgements

None.

Footnote

Conflicts of Interest: The authors have no conflicts of interest to declare.

Informed Consent: Written informed consent was obtained from the patient for publication of this case report and any accompanying images.

References

1. Mok TS, Wu YL, Ahn MJ, et al. Osimertinib or platinum-pemetrexed in EGFR T790M-positive lung cancer. *N Engl J Med* 2017;376:629-40.
2. Soria JC, Ohe Y, Vansteenkiste J, et al. Osimertinib in Untreated EGFR-Mutated Advanced Non-Small-Cell Lung Cancer. *N Engl J Med* 2018;378:113-25.
3. Ieki R, Saitoh E, Shibuya M. Acute lung injury as a possible adverse drug reaction related to gefitinib. *Eur Respir J* 2003;22:179-81.
4. Zhao CH, Liu RR, Lin L, et al. Diffuse alveolar hemorrhage after erlotinib with concurrent chemoradiotherapy in a patient with esophageal carcinoma. *Int J Clin Exp Med* 2014;7:4492-7.
5. Huang YJ, Liu SF, Wang CJ, et al. Exacerbated radiodermatitis and bilateral subdural hemorrhage after whole brain irradiation combined with epidermal growth factor receptor tyrosine kinase inhibitors for brain metastases in lung cancer. *Lung Cancer* 2008;59:407-10.
6. Kim JH, Kim HS, Choi JS, et al. Bilateral subdural hemorrhage as a possible adverse event of gefitinib in a patient with non-small cell lung cancer. *Lung Cancer* 2009;64:121-3.
7. Bai H, Liu Q, Shi M, et al. Erlotinib and gefitinib treatments of the lung cancer in an elderly patient result in gastrointestinal bleeding. *Pak J Med Sci* 2013;29:1278-9.
8. Yan DF, Yan SX, Yang JS, et al. Hemorrhage of brain metastasis from non-small cell lung cancer post gefitinib therapy: Two case reports and review of the literature. *BMC Cancer* 2010;10: doi: 10.1186/1471-2407-10-49.
9. Goldstraw P, Crowley J, Chansky K, et al. The IASLC Lung Cancer Staging Project: proposals for the revision of the TNM stage groupings in the forthcoming (seventh) edition of the TNM Classification of malignant tumours. *J Thorac Oncol* 2007;2:706-14.
10. Jänne PA, Yang JC, Kim DW, et al. AZD9291 in EGFR inhibitor-resistant non-small-cell lung cancer. *N Engl J Med* 2015;372:1689-99.

11. Guillamo JS, de Bouard S, Valable S, et al. Molecular mechanisms underlying effects of epidermal growth factor receptor inhibition on invasion, proliferation, and angiogenesis in experimental glioma. *Clin Cancer Res* 2009;15:3697-704.
12. Zheng Y, Gao Q, Fang W, et al. Gastrointestinal bleeding due to pancreatic metastasis of non-small cell lung cancer: A report of two cases and a literature review. *Oncol Lett* 2015;9:2041-5.
13. Niibe Y, Hayakawa K. Oligometastases and oligo-recurrence: the new era of cancer therapy. *Jpn J Clin Oncol* 2010;40:107-11.
14. Peng L, Song Z, Jiao S. Comparison of uncommon EGFR exon 21 L858R compound mutations with single mutation. *Onco Targets Ther* 2015;8:905-10.
15. Kim EY, Cho EN, Park HS, et al. Compound EGFR mutation is frequently detected with co-mutations of actionable genes and associated with poor clinical outcome in lung adenocarcinoma. *Cancer Biol Ther* 2016;17:237-45.
16. Kohsaka S, Nagano M, Ueno T, et al. A method of high-throughput functional evaluation of EGFR gene variants of unknown significance in cancer. *Sci Transl Med* 2017;9.

Cite this article as: Hayasaka K, Shiono S, Yanagawa N, Yarimizu K, Suzuki K, Endoh M. Hemorrhage of a pancreatic metastasis from lung adenocarcinoma after osimertinib therapy. *J Thorac Dis* 2018;10(9):E686-E689. doi: 10.21037/jtd.2018.08.108