

# Nuss technique in pectus excavatum: a mono-institutional experience

Hans K. Pilegaard

Department of Cardiothoracic and Vascular Surgery, Institute of Clinical Medicine, Aarhus University Hospital, Denmark

Correspondence to: Hans K. Pilegaard. Department of Cardiothoracic and Vascular Surgery, Institute of Clinical Medicine, Aarhus University Hospital, Skejby, Palle Juul-Jensens Boulevard 99, DK-8200 Aarhus N, Denmark. Email: pilegaard@dadlnet.dk.

**Background:** Pectus excavatum (PE) is the most common anomaly of the anterior chest wall. Prior PE was corrected by a modified Ravitch operation, but since Nuss published his minimal technique in 1998, most surgeons have preferred this technique.

**Methods:** Since 2001 the modified Nuss procedure has routinely been used for correction of more than 1,500 patients at Aarhus University Hospital. In the time period between January 1, 2011 and January 31, 2015, 675 patients have been corrected. The median age was 16 years (range, 11-58 years). All patients had preoperatively an epidural catheter and the operations were done in general anaesthesia. The postoperative pain treatment was planned for 4-5 weeks and the patients were routinely seen in the outpatient clinic 6 weeks after surgery and the bars removed after 3 years.

**Results:** Four hundred-and-fifty patients had one bar, 216 patients with two bars and nine patients with three bars inserted. The median length of the bar was 10 inch. The median duration of the operation was 29 minutes. The median postoperative stay was 3 days. No death, cardiac perforation or deep infection occurred and only 5% of the patients experienced a complication.

**Conclusions:** The Nuss procedure should still be considered in the treatment of PE. To my opinion, it should be the choice for correction of PE. The short bar should be used to achieve the best stability of the system, to obtain a good cosmetic result, a reduced dysfunction motion of the chest wall and an increased cardiac performance.

**Keywords:** Nuss procedure; modification; short bar; pectus excavatum (PE)

Submitted Feb 18, 2015. Accepted for publication Mar 27, 2015.

doi: 10.3978/j.issn.2072-1439.2015.04.07

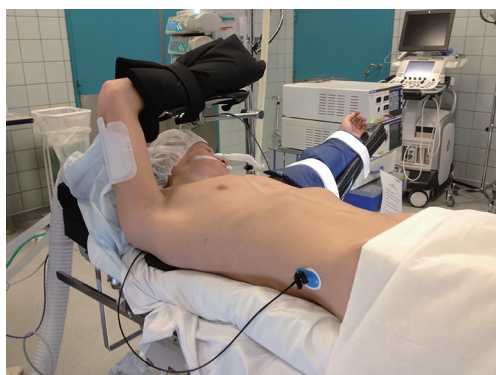**View this article at:** <http://dx.doi.org/10.3978/j.issn.2072-1439.2015.04.07>

## Background

Pectus excavatum (PE) is the most common anomaly of the anterior chest wall with an incidence of 1 in 3-400 living born males and 4-6 times more frequent in males. A family history is seen in 40% of the cases. It was described for the first time in 1594 by Bauhinus (1). The first attempt to correct it was done in 1911 by the German surgeon Ludwig Meyer, but the modern era of correction did not start until 1949 where Ravitch published his first paper (2). Several modifications were subsequent published and the modified Ravitch was the standard technique for correction of PE

until the work by Nuss concerning minimal invasive repair of pectus excavatum (MIRPE) was presented in 1998 (3). Today more and more surgeons have changed to this technique even though new methods have been proposed such as the non-invasive vacuum bell (4).

The Nuss procedure has the advantage of avoiding big incisions, resection of cartilages and it is a quick operation in experienced hands. It was from the beginning restricted to children and adolescents because it was thought that the chest wall in adults was too rigid to be remodeled by a metal bar behind the sternum; but with the growing experience the technique is used in even quite old patients.



**Figure 1** Patient position on the table.

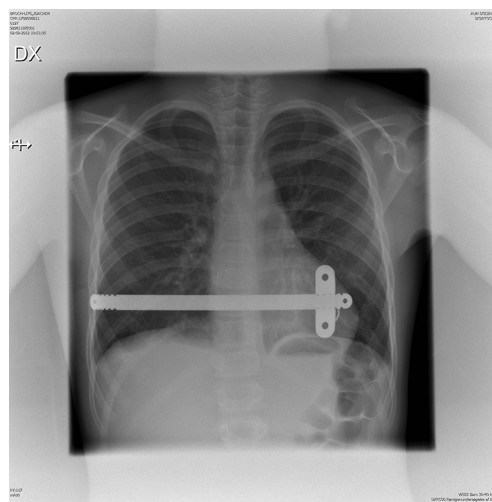
## Methods

Since 2001 the Nuss procedure has been used routinely in our department of cardiovascular and thoracic surgery at Aarhus University Hospital. Until the 1<sup>st</sup> of February 2015, 1,508 patients have undergone correction of PE. This paper deals with the patients operated from 1 January 2011 until 31 January 2015. The surgical technique and evaluation of the patients have been uniform in this time period. Correction has been made in 675 patients, 571 males and 104 females which give a ratio of 6/1. The median age was 16 years (range, 11-58 years). All patients were seen preoperatively in the outpatient clinic by the same surgeon, who also did all the corrections. The indications were the complaints about the cosmetic appearance and/or a story of an impaired cardiac performance. A clinical examination was done and only if this raised suspicion about the heart or lungs a CT-scan of the chest or an echocardiography was done. The Haller index was not used routinely as an indication for surgery. The following data have prospectively been recorded.

### *The surgical technique*

Our modified Nuss technique with the use of shorter bars has previously been published (5-7), but there has been some modifications since.

Prior to general anaesthesia an epidural thoracic catheter is placed. The patient is routinely intubated with a single lumen tube, and only in situations such as redo or previous intrathoracic surgery a double lumen tube is used. The patient is placed on the back to the right side on the table and with the right arm in front of the head to ensure free movement of the thoracoscope (*Figure 1*). The scope is



**Figure 2** Showing the asymmetric position of the bar.

inserted from the right lateral side around the level of the nipple to allow free view both cranially and caudally inside the chest. The deepest point is identified and the entry/exit points of the bar are marked on the skin. They should be just medially to the highest areas of the excavation. Then a template is used to make a model of how the chest is intended to look after correction. Due to debending of the bar after insertion, the bar should be bended some more: 1-2 cm. The tunnel under the sternum is done guided by the scope and it is very important that the tip of the introducer is in close contact with the chest wall to avoid lesions to the heart. The length of the incisions needed for introducing the bar are around 2 cm. All bars are normally stabilized on the left side. The stabilizer secures that this end of the bar has a basement of two ribs. The bar is placed asymmetrically on the chest to be sure that the right end also has a basement of two ribs (*Figure 2*). The stabilizer is fixed to the bar either by a steel wire surrounding the bar or by bending the end, which works like a lock. No additional sutures are used to fixate the bar.

If one bar is not enough to give a good cosmetic correction, 1-2 bars more are implanted. In many cases an additional bar might be implanted through the same incisions.

X-ray is routinely done the second day after surgery and prior if the patient demonstrates symptoms of respiratory nature (8).

Antibiotics are given intravenously for 3 days. The pain medication consists of epidural catheter the first 2 days. Morphine is given the first two weeks and NSAID and

**Table 1** Distribution of number of bars

Number of bars	Number of patients [%]
1	450 [67]
2	216 [32]
3	9 [1]

**Table 2** Number of bars in different age groups

Items	Patients number [%]		
	<18 years	18-29 years	≥30 years
Bar number			
One bar	340 [75]	96 [61]	14 [22]
Two bar	114 [25]	60 [38]	42 [67]
Three bar	0	2 [1]	7 [1]
Total number	454	158	63

paracetamol 4 and 5 weeks postoperatively, respectively.

The patient is seen in the outpatient clinic 6 weeks after surgery for clinical evaluation with an X-ray and then after 3 years for removal of the implanted system. If the patients need further visits they call or mail the department.

There are some restrictions to the patient for the first 6 weeks. It is not allowed to: carry heavy weight, 2 kg in front of the body or 5 kg on the shoulders, bike, rotate the upper body more than 15° and sleeping should be done on the back.

For all 3 years heavy contact sport such as American football, rugby, ice-hockey and some self-defense sports should be avoided.

## Results

The median age of the patients was 16 years (range, 11-58 years). The number of bars used in the patients is shown in *Table 1* and the distribution related to the age of the patient is shown in *Table 2*. The median length of the bars was 10 inch (range, 8-14 inch) and the distribution is shown in *Table 3*. The median duration of the surgical procedure was 29 minutes (range, 12-140 minutes), and only 5% of the operations lasted more than 60 minutes.

The median postoperative stay was 3 days (range, 1-14 days), and the distribution is shown in *Table 4*. The patient who stayed 14 days also underwent concomitant cardiac surgery. In the last year of the time period 60% of the patients were discharged the second day after

**Table 3** Number of bar sizes

Length	Number
8"	2
9"	138
10"	371
11"	280
12"	30
13"	17
14"	1

**Table 4** Length of postoperative stay

Days	Number
1	2
2	242
3	385
≥4	46

correction.

No deaths or cardiac lesions have occurred.

No deep infections were seen and the complications are shown in *Table 5*.

## Discussion

The indication for surgical correction of PE is in 90% of published papers cosmetic complaints from the patient concerning the abnormal shape of the anterior chest wall (9). It has been published in several papers that the quality of life increases significantly after correction of a PE (10-12).

The modified Ravitch needs a long incision either vertical or horizontal in the anterior chest wall, resection of cartilages which often leads to ossification of the new cartilage, which might cause a more rigid chest wall. In most cases a posterior support is needed either a metal bar or a meche. The shape will often be more flat. The vacuum bell is a prolonged external treatment, where the patient wears the bell every day for 1 up to several hours for a time period up to 36 months. The excavation will normally not be completely repealed (13).

The patients' physical performance increases significantly (10,12,14-17) and this corresponds to the findings from the Aarhus-group, who has shown that before surgery the cardiac performance is reduced to 80% of expected and 3 years after correction the patients perform equivalent

Table 5 Complications	
Complications	Number
Bar rotation	9
Dislocation	2
Fractura sterni	1
Evolving of PC	3
Pneumonia	2
Removal of stabilizer—pain	5
Sternotomi	1
One more bar	3
Removal before time—pain	3
Pneumothorax which needed drainage	2
PC, pectus carinatum.	

to an age-matched group (15-17). The compression of the right ventricle of the heart disappears, which causes a significant improvement of the right ventricular function (18). The dysfunction of the chest wall motion disappears after surgery and the chest volume increases, which increases the contribution of the chest wall to respiration (19,20). It is therefore important to correct the shape of the chest as close as possible to normal anatomy both to get the best cosmetic result for the patient but also to increase the physical performance of the patient as much as possible. This is done by using the Nuss procedure.

The optimal age for the procedure is still discussed. When Nuss published the first paper the median age was 6 years and none of the patients were above 15 years. Today the median age is 14 years and the preference is now in the beginning of the puberty (21), but if the PE is severe the correction is done in younger patients. Park *et al.* from Korea recommend correction before the age of 5 and is not afraid of recurrence even though the bar is removed before puberty (22). Since we have found that the influence on the heart is reversible even at high age we do not correct patients before puberty. Preferentially the females should have a demarcation of the breasts in order to place the incisions in a defined sulcus inframammalis.

The number of bars has been discussed. The initial technique prescribed relatively long bars and seroma was seen in 2-3% of the patients. With the use of the short bar we have not had any seroma formation. The stabilizer is placed very close to the hinge point avoiding the small movements that might cause mechanical irritation and thereby seroma. Two bars are used more often today and the complication rate has not increased. In many cases two

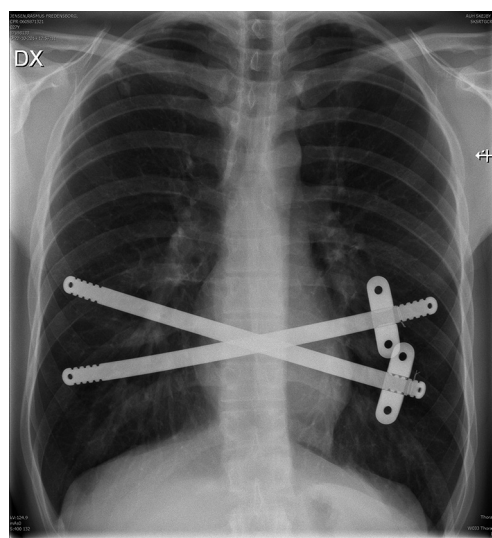


Figure 3 Crossed bars.

bars might be inserted through the same incisions. If the excavation is short the two bars may be crossed to give the best support under the deepest point (Figure 3).

The pain is often described as a major problem in the Nuss procedure. We think that the use of the epidural catheter is a must to give the patient the least pain in the first postoperative days, and we have not seen any persistent complication related to this treatment. Good information about the postoperative course and what the patient may expect have also done that the median stay has decreased to 3 days and that 60% of the patients today are discharged from the hospital on the second postoperative day. The use of more than one bar may probably cause less pain according to the paper of Nagaso *et al.* (23).

With the high volume we have shown that the complication rate is reduced to a very low number as shown in Table 5. No deaths have occurred and there has not been any perforation of the heart, which is the most feared complication. Also the rotation problems have been reduced by using the short bar with the stabilizer close to the hinge point and only very few dislocations (bar moves to side) have occurred.

## Conclusions

The Nuss procedure should still be considered in the treatment of PE. To my opinion it should be the choice for correction of PE. The short bar should be used to achieve the best stability of the system, to obtain a good cosmetic result, a reduced dysfunction motion of the chest wall and

an increased cardiac performance.

## Acknowledgements

*Disclosure:* Consultant at Biomet. The author declares no conflict of interest.

## References

1. Robicsek F, Watts LT. Surgical correction of pectus excavatum. How did we get here? Where are we going? *Thorac Cardiovasc Surg* 2011;59:5-14.
2. Ravitch MM. The Operative Treatment of Pectus Excavatum. *Ann Surg* 1949;129:429-44.
3. Nuss D, Kelly RE Jr, Croitoru DP, et al. A 10-year review of a minimally invasive technique for the correction of pectus excavatum. *J Pediatr Surg* 1998;33:545-52.
4. Haecker FM, Mayr J. The vacuum bell for treatment of pectus excavatum: an alternative to surgical correction? *Eur J Cardiothorac Surg* 2006;29:557-61.
5. Pilegaard HK, Licht PB. Early results following the Nuss operation for pectus excavatum--a single-institution experience of 383 patients. *Interact Cardiovasc Thorac Surg* 2008;7:54-7.
6. Pilegaard HK, Licht PB. Routine use of minimally invasive surgery for pectus excavatum in adults. *Ann Thorac Surg* 2008;86:952-6.
7. Pilegaard HK. Extending the use of Nuss procedure in patients older than 30 years. *Eur J Cardiothorac Surg* 2011;40:334-7.
8. Knudsen MR, Nyboe C, Hjortdal VE, et al. Routine postoperative chest X-ray is unnecessary following the Nuss procedure for pectus excavatum. *Interact Cardiovasc Thorac Surg* 2013;16:830-3.
9. Krasopoulos G, Goldstraw P. Minimally invasive repair of pectus excavatum deformity. *Eur J Cardiothorac Surg* 2011;39:149-58.
10. Kelly RE Jr, Cash TF, Shamberger RC, et al. Surgical repair of pectus excavatum markedly improves body image and perceived ability for physical activity: multicenter study. *Pediatrics* 2008;122:1218-22.
11. Krasopoulos G, Dusmet M, Ladas G, et al. Nuss procedure improves the quality of life in young male adults with pectus excavatum deformity. *Eur J Cardiothorac Surg* 2006;29:1-5.
12. Jacobsen EB, Thastum M, Jeppesen JH, et al. Health-related quality of life in children and adolescents undergoing surgery for pectus excavatum. *Eur J Pediatr Surg* 2010;20:85-91.
13. Haecker FM. The vacuum bell for conservative treatment of pectus excavatum: the Basle experience. *Pediatr Surg Int* 2011;27:623-7.
14. O'Keefe J, Byrne R, Montgomery M, et al. Longer term effects of closed repair of pectus excavatum on cardiopulmonary status. *J Pediatr Surg* 2013;48:1049-54.
15. Lesbo M, Tang M, Nielsen HH, et al. Compromised cardiac function in exercising teenagers with pectus excavatum. *Interact Cardiovasc Thorac Surg* 2011;13:377-80.
16. Tang M, Nielsen HH, Lesbo M, et al. Improved cardiopulmonary exercise function after modified Nuss operation for pectus excavatum. *Eur J Cardiothorac Surg* 2012;41:1063-7.
17. Maagaard M, Tang M, Ringgaard S, et al. Normalized cardiopulmonary exercise function in patients with pectus excavatum three years after operation. *Ann Thorac Surg* 2013;96:272-8.
18. Gürkan U, Aydemir B, Aksoy S, et al. Echocardiographic assessment of right ventricular function before and after surgery in patients with pectus excavatum and right ventricular compression. *Thorac Cardiovasc Surg* 2014;62:231-5.
19. Redlinger RE Jr, Kelly RE, Nuss D, et al. Regional chest wall motion dysfunction in patients with pectus excavatum demonstrated via optoelectronic plethysmography. *J Pediatr Surg* 2011;46:1172-6.
20. Redlinger RE Jr, Wootton A, Kelly RE, et al. Optoelectronic plethysmography demonstrates abrogation of regional chest wall motion dysfunction in patients with pectus excavatum after Nuss repair. *J Pediatr Surg* 2012;47:160-4.
21. Kelly RE, Goretsky MJ, Obermeyer R, et al. Twenty-one years of experience with minimally invasive repair of pectus excavatum by the Nuss procedure in 1215 patients. *Ann Surg* 2010;252:1072-81.
22. Park HJ, Sung SW, Park JK, et al. How early can we repair pectus excavatum: the earlier the better? *Eur J Cardiothorac Surg* 2012;42:667-72.
23. Nagaso T, Miyamoto J, Kokaji K, et al. Double-bar application decreases postoperative pain after the Nuss procedure. *J Thorac Cardiovasc Surg* 2010;140:39-44, 44.e1-2.

**Cite this article as:** Pilegaard HK. Nuss technique in pectus excavatum: a mono-institutional experience. *J Thorac Dis* 2015;7(S2):S172-S176. doi: 10.3978/j.issn.2072-1439.2015.04.07