

Removal of metallic foreign body in heart by minimally invasive procedure under the guidance of transesophageal echocardiography and transthoracic echocardiogram

Hong Qian^{1*}, Haibo Song^{2*}, Yajiao Li³, Chunling Jiang²

¹Department of Cardiovascular Surgery, ²Department of Anesthesiology, ³Department of Cardiology, West China Hospital of Sichuan University, Chengdu 610041, China

*These authors contributed equally to this work.

Correspondence to: Chunling Jiang. Department of Anesthesiology, West China Hospital of Sichuan University, Guoxue Road 37#, Wuhou Qu, Chengdu 610041, China. Email: jiang_chunling@yahoo.com.

Abstract: Penetrating cardiac injury, caused by intracardiac foreign bodies, presents a big challenge to surgeons for that it is difficult to exactly locate the intracardiac foreign bodies due to the continuous movement of heart. We present the case of successful removal of two self-inflicted intramyocardial needles by minimally invasive procedures. Under the guidance of transesophageal echocardiography (TEE) and transthoracic echocardiogram (TTE), left mini-anterolateral thoracotomy was performed and the needles were located and removed. The patient was discharged from hospital 5 days after surgery without any complications. In our case, the TTE and TEE provide valuable informations on the choice of surgical procedure, which avoids opening the chest and use of cardiopulmonary bypass (CPB).

Keywords: Intracardiac foreign bodies; minimally invasive procedure; transesophageal echocardiography (TEE); transthoracic echocardiogram (TTE)

Submitted Jul 27, 2015. Accepted for publication Nov 05, 2015.

doi: 10.3978/j.issn.2072-1439.2015.11.28

View this article at: <http://dx.doi.org/10.3978/j.issn.2072-1439.2015.11.28>

Introduction

Self-inflicted intracardiac foreign bodies are rarely seen in clinical practice. It is a highly life-threatening trauma, with high incidence of dying from hemorrhagic shock or pericardial tamponade before arriving at hospital (1). Penetrating cardiac injury presents a big challenge to surgeons for that it is difficult to exactly locate the intracardiac foreign bodies due to the continuous movement of heart (2,3). Here, we present a case of removal of two intramyocardial needles in a young man by mini-invasive surgical procedures under the guidance of transesophageal echocardiography (TEE) and transthoracic echocardiogram (TTE), which avoids opening the chest and use of cardiopulmonary bypass (CPB).

Case presentation

A 34-year-old man was admitted into the emergency department of our hospital, complaining chest pain for 2 days. After closer questioning, the patient admitted that he self-inflicted two sewing needles into his left parasternal region. Detailed questioning revealed a history of depression and self-mutilation, without history of illegal drug use. The patient appeared depressive but his vital signs were stable. There was no pathology on physical examinations. Further examinations were performed. Routine blood test and electrocardiogram were normal. There was no sign of entry wounds on his chest wall. A chest X-ray radiograph showed two linear metallic densities. One was in the left lower chest wall and the other one was within the cardiac silhouette

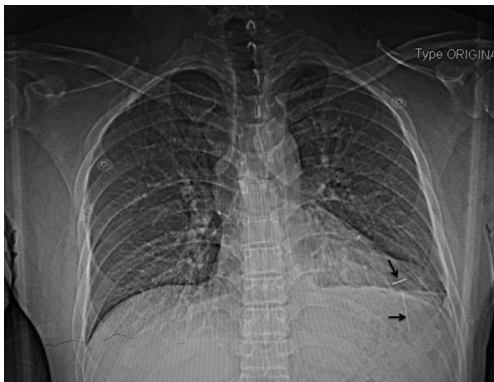

Figure 1 Chest X-ray revealed two needles (arrows) in the chest.

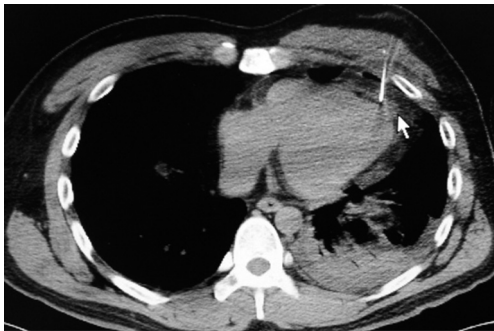


Figure 2 Computerized tomographic scan showed the first needle was in the left ventricular myocardium.

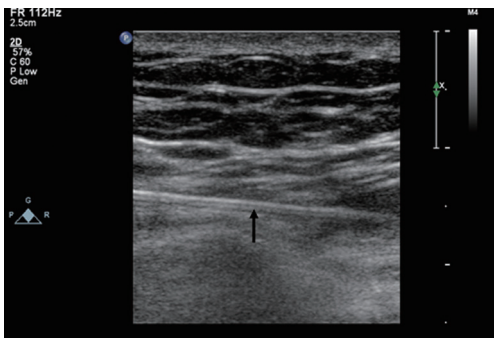


Figure 3 Transthoracic echocardiography showed one needle (arrow) was inserted through the chest wall into the pericardial space.

(Figure 1). A computed tomography (CT) scan of the chest showed one of the two linear metallic densities in the left ventricular myocardium and small pericardial fluid (Figure 2).

Since the needles were not visible or palpable through the skin, a surgical plan was made to remove the needles

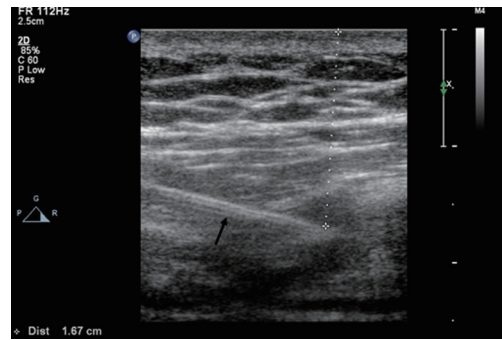


Figure 4 Transthoracic echocardiography revealed the second needle (arrow) in the left ventricular myocardium without extension into the ventricular cavity.

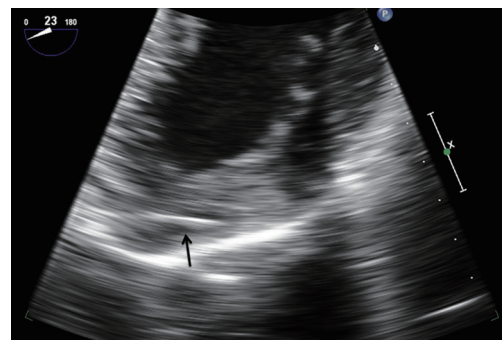

Figure 5 Intraoperative transesophageal echocardiography showed the second needle (arrow) was in the left ventricular myocardium in mid esophageal four-chamber view.

in a hybrid operating room. A preoperative TTE was performed and both needles were identified. One needle was inserted through the chest wall into the pericardial space (Figure 3) and the second needle was inserted into the left ventricular myocardium (Figure 4). Since the patient is stable, anesthesia was induced as usual with opioids, propofol, and a muscle relaxant and maintained with controlled ventilation with oxygen and sevoflurane through the cuffed endotracheal tube. TEE was then performed and found that the second needle was inside the left ventricular myocardium without infiltration into the left ventricular cavity (Figure 5).

Based on above findings, left mini-anterolateral thoracotomy was performed with the heart beating. The needle in the chest wall was easily removed from intercostal muscles. However, the second needle in the left ventricular myocardium was invisible from the surface of the heart.

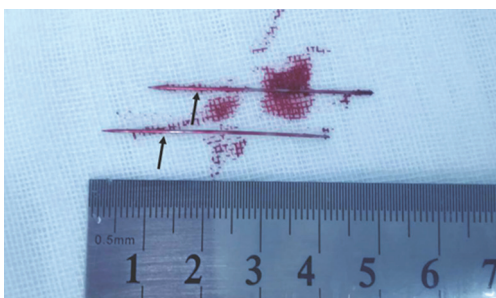


Figure 6 The removed two needles (arrows) from the heart.

A comprehensive TEE examination was performed and the best view to locate the needle from TEE was the mid esophageal four-chamber view. In order to accurately locate the needle, surgeons pressed the tip of the forceps on the probable point of the needle. The tip of the forceps and the needle could be seen on the TEE simultaneously. Then, the needle was removed uneventfully and TEE confirmed that no significant changes in cardiac function after the procedure. Both needles were 4.0 cm in length and 0.25 mm in thickness (*Figure 6*). Although the whole procedure was on a beating heart, the CPB was kept on standby. No severe bleeding was observed and the operation was successful. The patient was discharged from hospital 5 days after surgery without any complications.

Discussion

This is a rare case of penetrating cardiac injury caused by sewing needles. Patients with foreign bodies completely embedded in the myocardium usually are asymptomatic (4). However, the needles have a tendency to migrate through the tissue leading to serious complications. Thus, early removal of the needles was recommended to prevent further damages to heart. However, there was no consensus on the surgical procedures for removal of metallic foreign body in heart.

Several case reports of foreign bodies inside the heart were reported in literatures. However, most were performed after opening the chest with or without CPB (4-6). To the best of our knowledge, we reported here the first case of removing foreign bodies inside the heart by the left mini-antrolateral thoracotomy without CPB. Most notably, TEE and TTE offer great value for the determination of surgical procedures and successful removal of the two intramyocardial needles.

Traditionally, preoperatively localization of foreign bodies can be accomplished by chest radiology including

fluoroscopy, X-rays and CT scan, and TTE or TEE. Nevertheless, in consideration of a needle's tendency to migrate, intraoperative echocardiography or fluoroscopy is recommend to facilitate locating the needle's exact position (5,7). Whereas, chest fluoroscopy involves a higher exposure to radiation than a standard chest X-ray. In comparison, real time echocardiography, beyond the advantage of no ionizing radiation, allows for the direct visualization of peri and intracardiac structures and assessing cardiac function. It is reported that TTE provides information regarding the size, location, and mobility of foreign bodies with almost 100% sensitivity (8). However, in our case, TTE was unable to exactly localize the second needle, which was completely penetrated into the left ventricular myocardium. In recent years, with the introduction of TEE into clinics, it is a highly efficient diagnostic tool to assess the foreign bodies in heart, especially in the right and posterior regions of the heart (9). Importantly, an intraoperative TEE could significantly alter surgical procedures of chest trauma (10). Furthermore, an intraoperative TEE is a favorable imaging tool in assessing functional and structural damage before and after surgical procedures. Chand *et al.* (11) reported a case of removal of a sewing needle in the left ventricular muscle with the guidance of TEE. However, they opened the chest and induced a short period of fibrillary arrest to decrease the movement of the myocardium, without CPB.

In our case, we think that the TTE and TEE provide valuable information on the choice of surgery. TTE and TEE locate the position of the foreign body, which avoids opening the chest and use of CPB. Importantly, a left mini-antrolateral thoracotomy prevented further injury to surrounding structures during removal of the needles. In conclusion, TEE serves as a very useful mini-invasive diagnostic tool in terms of determining the location of the foreign body and guidance of surgical procedures.

Acknowledgements

None.

Footnote

Conflicts of Interest: The authors have no conflicts of interest to declare.

References

1. Gungor H, Duygu H, Yildiz BS, et al. A remnant sewing

- needle in the right ventricle as a cause of chest pain. *Clin Cardiol* 2010;33:E23-5.
2. Glinz W. Chest trauma: diagnosis and management. Berlin: Springer Science & Business Media, 2012.
 3. Wang X, Zhao X, Du D, et al. Management of metallic foreign bodies in the heart. *J Card Surg* 2012;27:704-6.
 4. Datta G, Sarkar A, Mukherjee D. A foreign body in the heart. *Arch Cardiovasc Dis* 2011;104:684-5.
 5. Mandegar MH, Ali Yousefnia M, Rayatzadeh H, et al. Intramyocardial sewing needle extracted one year after insertion. *Interact Cardiovasc Thorac Surg* 2006;5:742-3.
 6. Liu H, Juan YH, Wang Q, et al. Foreign body venous transmigration to the heart. *QJM* 2014;107:743-5.
 7. Inoue T, Iemura J, Saga T. Delayed cardiac tamponade caused by self-inserted needles. *Can J Cardiol* 2003;19:306-8.
 8. Actis Dato GM, Arslanian A, Di Marzio P, et al. Posttraumatic and iatrogenic foreign bodies in the heart: report of fourteen cases and review of the literature. *J Thorac Cardiovasc Surg* 2003;126:408-14.
 9. Aguirre MA, Trousdale D, John A, et al. The use of transesophageal echocardiography in determining the structural and functional impact of traumatic intracardiac foreign bodies. *Anesth Analg* 2008;107:1155-7.
 10. Mollod M, Felner JM. Transesophageal echocardiography in the evaluation of cardiothoracic trauma. *Am Heart J* 1996;132:841-9.
 11. Chand AR, Sarju R, Kumar SV, Singh WG. Removal of a foreign body from the heart under transesophageal echocardiographic guidance. *J Cardiothorac Vasc Anesth* 2013;27:321-2.

Cite this article as: Qian H, Song H, Li Y, Jiang C. Removal of metallic foreign body in heart by minimally invasive procedure under the guidance of transesophageal echocardiography and transthoracic echocardiogram. *J Thorac Dis* 2015;7(11):E560-E563. doi: 10.3978/j.issn.2072-1439.2015.11.28