

Video-assisted thoracic surgery left upper lobectomy with systematic lymphadenectomy

Xue Pan¹, Yan Zhang², Xiangnan Li², Dengyan Zhu², Chunyang Zhang², Jia Zhao², Wei Li¹

¹The Nursing College of Zhengzhou University, Zhengzhou 450052, China; ²Department of Thoracic Surgery, The First Affiliated Hospital of Zhengzhou University, Zhengzhou 450052, China

Correspondence to: Yan Zhang. Department of Thoracic Surgery, The First Affiliated Hospital of Zhengzhou University, No.1, Jianshe Road, Zhengzhou 450052, China. Email: zhangyan3483@163.com.

Abstract: A 62-year-old woman was referred to the Thoracic Surgery Department after computed tomography (CT) revealed a 1.0 cm × 1.1 cm mass peripherally in the left upper lobe with spicular formation during her routine medical examination. The nature of the mass was confirmed to be adenocarcinoma by transpercutaneous lung biopsy. No metastasis or contraindication for surgery was found. Video-assisted thoracic surgery (VATS) left upper lobectomy with systematic lymphadenectomy was performed. Total surgery time was 80 min and blood loss was 50 mL. Postoperative pathological exam suggested adenocarcinoma, without evidence of lymph node metastasis in any station (T1aN0M0 stage IA). The patient was discharged home on the 10th postoperative day.

Keywords: Video-assisted thoracic surgery (VATS); lobectomy; lung cancer

Submitted Nov 23, 2015. Accepted for publication Nov 30, 2015.

doi: 10.3978/j.issn.2072-1439.2015.12.46

View this article at: <http://dx.doi.org/10.3978/j.issn.2072-1439.2015.12.46>

Introduction

Video-assisted thoracic surgery (VATS) lobectomy is an acceptable alternative and seems equivalent to open lobectomy in terms of complications and oncological value. Its advantages compared to thoracotomy are less surgical injury, decreased postoperative pain, fewer postoperative pulmonary complications, shorter hospital stay, improved quality of life, and improved delivery of adjuvant chemotherapy, with a comparable long-term survival rate. VATS has become a routine procedure for stage I and II lung cancers.

Here, we report our technique of totally thoracoscopic left upper lobectomy with systematic lymph nodes dissection for a 62-year-old woman with left upper lobe carcinoma at the Thoracic Surgery Department of Zhengzhou University. The video demonstrates our thinking and surgical process (*Figure 1*).

Case presentation

A 62-year-old woman was referred to the Thoracic Surgery

Department after computed tomography (CT) revealed a 1.0 cm × 1.1 cm mass peripherally in the left upper lobe with spicular formation during her routine medical examination. The nature of the mass was confirmed to be adenocarcinoma by transpercutaneous lung biopsy. No metastasis was found by positron emission tomography/computed tomography (PET-CT) or brain magnetic resonance imaging (MRI) preoperatively. She had no other comorbidities. Before the operation, the pulmonary function test, blood gas analysis, cardiac evaluation and basic examinations were within normal limits. The patient was clinically staged as IA (T1aN0M0) and was qualified for VATS lobectomy. So, we decided to operate the patient using VATS left upper lobectomy with systematic lymph node dissection.

Surgical technique

The patient was positioned in the lateral decubitus position with the bed flexed to increase the intercostal space. The operation was conducted under general anesthesia with

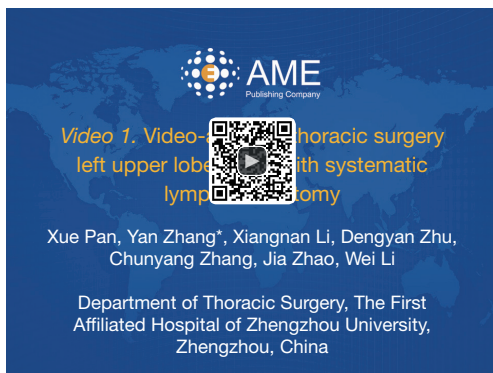


Figure 1 Video-assisted thoracic surgery left upper lobectomy with systematic lymphadenectomy (1).

Available online: <http://www.asvide.com/articles/743>

double-lumen endotracheal intubation. The camera port (1.0 cm in diameter) was placed in the 7th intercostal space of the mid-axillary line. The utility port (2.0 cm in length) was placed in the 4th intercostal space on the left anterior axillary line. The auxiliary port (1.0 cm in length) was placed in the 9th intercostal space on the left posterior axillary line. An incision protection retractor was attached to each port. No rib spreader was used and the whole procedure was controlled on the monitor. The doctor and the camera holder stand in the ventral side of the patient during the process of operation.

Sequential dissection (i.e., left superior pulmonary vein-left upper lobe bronchus-branches of left pulmonary arteries-crack) was applied. First, the thoracic cavity was explored. There were no pleural effusion, or pleural nodules observed. The lesion was located in the left upper lobe peripherally.

The left upper lobe vein was first cut off with a vascular (white cartridge) 60 mm long endostapler (ECR60W, JJMC, USA), followed by the left upper lobe bronchus which was stapled and cut off with a thick tissular (green cartridge) 60 mm long endostapler (ECR60G, JJMC, USA). After partial separation of the fissure, the branches of the upper lobe pulmonary artery was also cut off with a ECR60W. Subsequently, the left upper lobe was dissected and cut together with three standard tissular (blue cartridge) 60 mm long endostaplers (ECR60B, JJMC, USA). Finally, the left upper lobe was placed into a protective bag and removed from the thoracic cavity.

Further, the group 10 lymph nodes were dissected, and the left phrenic nerve, left vagus nerve, and recurrent nerve were exposed to facilitate the dissection of the group 5 lymph nodes. The left lower lobe was retracted forward and the

left vagus nerve and esophagus were dissociated from the group 7 lymph nodes to expose the bilateral main bronchus. These lymph nodes were dissected from the junction of the inferior pulmonary vein and the right main bronchus to the carina, after which they were dissociated from the left main bronchus and removed. The group 9 lymph nodes and the group 11 lymph nodes were also removed.

Leak testing was conducted following the anastomosis, in which no leakage was detected up to an airway pressure of 30 cmH₂O (2.94 kPa). Two 26F chest tubes were placed, and the incisions were closed. Total surgery time was 80 min and blood loss was 50 mL. The chest tube was removed on the 5th postoperative day. Postoperative CT scan was performed to observe the healing of the anastomotic stoma. Postoperative pathological exam suggested adenocarcinoma, without evidence of lymph node metastasis in any station (T1aN0M0 stage IA). The patient was discharged home on the 10th postoperative day.

Discussion

Satisfying double-lumen intubation was the foundation of the successful operation. Completely collapse of the lung on the operation side was in favor of hilum of lung exposure. The surgical incision was selected according to the patient's habit and specific situation, such as body shape and lung lump position. In our surgery, two ports were created at 4th (2.0 cm) and 9th (1.0 cm) intercostal spaces, with the observation port in the 7th intercostal space, which provided a clear field of operation and was convenient for handling the vessels and bronchial lymph nodes.

The treatment of pulmonary vessel was the most crucial and complicated step of thoracoscopic lobectomy. The advantage of vessel treatment with instrument was that it did not take too long for blood vessel free, as long as stapler anvil could be inserted. Traditionally, lung vein was firstly treated, and then the bronchus and lung artery followed by the lung laceration at last when operating VATS left upper lobectomy. However, there could be a risk of undesired injury to the trunk of the left pulmonary artery when removing the upper lobe bronchus. And in most cases, one of the bronchial arteries is located between the left upper bronchus and the pulmonary artery trunk, and this bronchial artery should be dealt with before the left upper bronchus to avoid bleeding. So, the first bronchial arteries of the pulmonary artery trunk was treated before the left upper bronchus in our surgery for the purpose of less bleeding and definite structural exposure.

Acknowledgements

None.

Footnote

Conflicts of Interest: The authors have no conflicts of interest to declare.

Cite this article as: Pan X, Zhang Y, Li X, Zhu D, Zhang C, Zhao J, Li W. Video-assisted thoracic surgery left upper lobectomy with systematic lymphadenectomy. *J Thorac Dis* 2015;7(12):2386-2388. doi: 10.3978/j.issn.2072-1439.2015.12.46

References

1. Pan X, Zhang Y, Li X, et al. Video-assisted thoracic surgery left upper lobectomy with systematic lymphadenectomy. *Asvide* 2015;2:165. Available online: <http://www.asvide.com/articles/743>