Letter to the Editor

Resection of an anterior apical tumor invading the ventral first rib: a less invasive lateral thoracotomy approach

Noriaki Sakakura, Suguru Shirai, Takeo Nakada, Yusuke Takahashi, Hiroaki Kuroda

Department of Thoracic Surgery, Aichi Cancer Center Hospital, Nagoya, Japan

Correspondence to: Noriaki Sakakura. Department of Thoracic Surgery, Aichi Cancer Center Hospital, 1-1 Kanokoden, Chikusa-ku, Nagoya 464-8681, Japan. Email: nsakakura@aichi-cc.jp.

Submitted Jan 20, 2022. Accepted for publication Mar 09, 2022.
doi: 10.21037/jtd-22-84
View this article at: https://dx.doi.org/10.21037/jtd-22-84

This brief report accompanying a short video presents a less invasive approach to lateral thoracotomy for resection of anterior apical lung malignancies infiltrating into the ventral first rib. Using only the anterior part of the skin incision in the hook approach, the incision was elongated to the clavicle midline to expose the ventral half of the first rib and thoracic outlet (*Figure 1*).

Surgical approaches to lung malignancies invading the superior sulcus vary and are mainly distinguished on the basis of anterior (ventral) and posterior (dorsal) approaches. For tumors invading the dorsal aspect of the first rib, the well-known posterior approaches (1,2) are typically chosen without hesitation. To expose more of the entire first rib, the "hook approach" (3,4) can be useful wherein the anterior skin incision of the posterior approach curves up to the cranial side of the nipple. With these approaches, however, the muscles around the scapula are extensively cut. Conversely, for tumors invading the ventral aspect of the first rib, the optimal surgical approach is controversial. Among surgical procedures for lung malignancies in the anterior/ventral thorax to superior sulcus, the anterior trap-door approach (5), anterior transcervical-thoracic approach (6), and transmanubrial osteomuscular sparing approach (TMA) (7) are famous. A combination of two approaches involving TMA initially, followed by patient placement in the lateral decubitus position would be a common practice. A modification of TMA by lowering the transverse section of the sternum caudally to the second intercostal space is an alternative (8).

We demonstrate the procedure in a patient with lung pleomorphic carcinoma infiltrating into the left ventral first rib (*Video 1*). The patient was a 68-year-old man initially presenting with chest pain and blood sputum. He had a 6 cm left lung tumor which was radiologically diagnosed as cT3N0–1M0 stage IIB–IIIA non-small cell lung cancer. His history was significant for the treatment of myocardial infarction and cerebral aneurysm, and his health status was fragile. Induction chemoradiotherapy was difficult. Although surgery was considered marginally feasible, various approaches were considered for excising the ventral first rib.

The patient was placed in the right lateral decubitus position with the arm raised and a large exposure around the left axilla through the anterior chest. Only the ventral skin incision of the hook approach through the cranial side of the nipple was used, and the incision was elongated up to the midline of the clavicle to expose the ventral half of the first rib and thoracic outlet. The pectoralis major muscle was spared, and the pectoralis minor and serratus anterior muscles were dissected to expose the bony thorax. The chest was opened at the third intercostal space; then, the third and second ribs were cut along the skin incision line. Initially, the first rib infiltrated by the tumor was untouched, while the left upper lobectomy was proceeded. Next, the costoclavicular ligament and subclavius muscle were cut; then, the ventral aspect of the first rib was gently separated from the sternum and clavicle. After the subclavian vein was spared and the anterior scalene muscle was cut, the ventral aspect of the thoracic outlet and the peripheral part of the subclavian artery were identified. Finally, en bloc resection of the first rib infiltrated by the tumor and the left upper lobe, and ND2a-1 were successfully achieved. Here, no thoracic outlet structures were involved, except for the first rib. For closure, the second and third ribs were firmly fixed

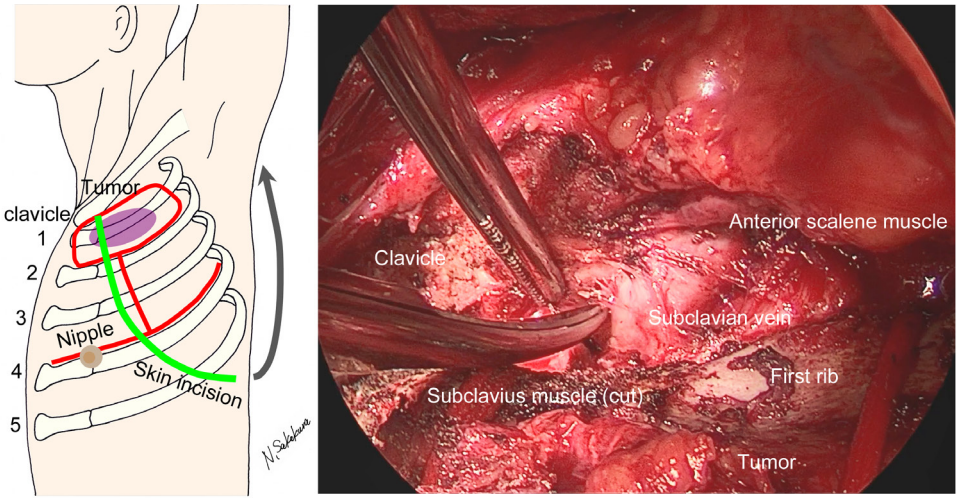

Figure 1 Schema (left) of the skin incision (green) and bony thoracotomy (red) and a key finding (video still frame, right). If the view is inadequate, the incision can be extended dorsally around the subscapularis angle to the shoulder (gray arrow), so as to convert to the hook approach. The photograph shows the ventral aspect of the thoracic outlet and dissection around the left subclavian vein after cutting the subclavius muscle. The first rib is taped at ventral and midline portions.

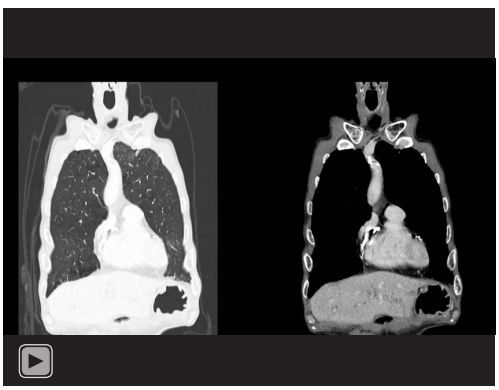

Video 1 A less invasive lateral thoracotomy approach for the resection of the anterior apical tumor invading the ventral first rib (duration: 5 min 59 s). Using only the anterior part of the skin incision in the hook approach through the cranial side of the nipple, the incision was elongated up to the midline of the clavicle to expose the ventral half of the first rib and thoracic outlet. Despite being a relatively less invasive procedure, the necessary surgical view can be obtained around the anterior thoracic outlet and the subclavian vein is sufficiently accessible. This video image is published with the patient's consent.

using rib pins. Pathologically, a complete resection was attained, and the patient was diagnosed with pT3N2M0 stage IIIB pleomorphic carcinoma with invasion of the rib cortex and metastasis to the mediastinal and hilar lymph nodes (#5, #12u). Although his postoperative course was uneventful and he had no restriction in shoulder function, adjuvant treatment was difficult as expected. At 7 months postoperatively, however, multiple distant metastases to the bone and the liver were discovered. Thereafter, the patient received the best supportive care.

For surgical approaches in anterior apical lung malignancies, the combination of TMA and posterolateral approach, Masaoka technique, hook approach, and hemiclamshell thoracotomy are possible choices, but these procedures may be highly invasive in some cases. The procedure presented herein provides an appropriate view of the ventral first rib and thoracic outlet as well as the intrathorax, is less invasive and easy to perform, and is, thus, a possible procedural option to resect anterior apical lesions infiltrating into the ventral first rib without severe neurovascular involvement. This method is considered to be a slight modification of the vertical muscle-sparing/splitting thoracotomy (9). Despite the relatively small incision and preservation of most skeletal muscles, the necessary surgical view can be obtained around the anterior thoracic outlet, and the subclavian vein is sufficiently accessible. If more manipulation of the vessels or nerves is needed, the more rigorous, conventional mediastinal procedures, such as TMA, should be chosen. Note this approach may provide a slightly limited view for lymph node dissection of the subcarinal zone.

Currently, minimally invasive procedures are significantly advancing as thoracoscopic and robotic surgeries are widely performed. Nonsurgical treatments are also rapidly developing. Alternatively, open thoracotomy is less frequently performed, and unusual types of thoracotomies are also becoming less frequent. Nevertheless, reliable techniques for open procedure remain important. Although the modification presented herein is minor, and it can be intimidating to comment on the classic and well-studied surgical treatment of anterior apical tumors, we hope that this report and the video prompt further discussion on open thoracotomy and help daily practice.

Acknowledgments

Funding: None.

Footnote

Provenance and Peer Review: This article was a standard submission to the journal. The article was sent for external peer review.

Peer Review File: Available at https://jtd.amegroups.com/article/view/10.21037/jtd-22-84/prf

Conflicts of Interest: All authors have completed the ICMJE uniform disclosure form (available at https://jtd.amegroups.com/article/view/10.21037/jtd-22-84/coif). The authors have no conflicts of interest to declare.

Ethical Statement: The authors are accountable for all aspects of the work in ensuring that questions related to the accuracy or integrity of any part of the work are appropriately investigated and resolved. All procedures performed in the study were in accordance with the ethical standards of the institutional and national research committees and with the Helsinki Declaration (as revised in 2013). Written informed consent was obtained from the patient for publication of this manuscript and any accompanying images. A copy of the written consent is available for review by the editorial office of this journal.

References

1. Chardack WM, Maccallum JD. Pancoast syndrome due to bronchiogenic carcinoma: successful surgical removal and postoperative irradiation; a case report. J Thorac Surg 1953;25:402-12.
2. Shaw RR, Paulson DL, Kee JL. Treatment of Superior Sulcus Tumor by Irradiation Followed by Resection. Ann Surg 1961;154:29-40.
3. Niwa H, Masaoka A, Yamakawa Y, et al. Surgical therapy for apical invasive lung cancer: different approaches according to tumor location. Lung Cancer 1993;10:63-71.
4. Tatsumura T, Sato H, Mori A, et al. A new surgical approach to apical segment lung diseases, including carcinomas and inflammatory diseases. J Thorac Cardiovasc Surg 1994;107:32-6.
5. Masaoka A, Ito Y, Yasumitsu T. Anterior approach for tumor of the superior sulcus. J Thorac Cardiovasc Surg 1979;78:413-5.
6. Grunenwald D, Spaggiari L. Transmanubrial osteomuscular sparing approach for apical chest tumors. Ann Thorac Surg 1997;63:563-6.
7. Dartevelle PG, Chapelier AR, Macchiarini P, et al. Anterior transcervical-thoracic approach for radical resection of lung tumors invading the thoracic inlet. J Thorac Cardiovasc Surg 1993;105:1025-34.
8. Sakakura N, Nakada T, Takahashi Y, et al. An extended modification of transmanubrial osteomuscular sparing approach: salvage resection for recurrent superior sulcus lung cancer after definitive chemoradiotherapy. J Thorac Dis 2021;13:417-9.
9. Sakakura N, Mizuno T, Arimura T, et al. Design variations in vertical muscle-sparing thoracotomy. J Thorac Dis 2018;10:5115-9.

Cite this article as: Sakakura N, Shirai S, Nakada T, Takahashi Y, Kuroda H. Resection of an anterior apical tumor invading the ventral first rib: a less invasive lateral thoracotomy approach. J Thorac Dis 2022;14(4):1296-1298. doi: 10.21037/jtd-22-84

