



Extracorporeal life support in thoracic emergencies—a narrative review of current evidence

Anne Willers^{1,2^}, Silvia Mariani^{1^}, Jos M. Maessen^{1,3}, Roberto Lorusso^{1,3^}, Justyna Swol^{4^}

¹Cardiovascular Research Institute Maastricht (CARIM), Maastricht, The Netherlands; ²Department of General Surgery, Catharina Ziekenhuis Eindhoven, Eindhoven, The Netherlands; ³Department of Cardio-Thoracic Surgery, Heart & Vascular Center, Maastricht University Medical Center (MUMC), Maastricht, The Netherlands; ⁴Department of Respiratory Medicine, Paracelsus Medical University, Nuremberg, Germany

Contributions: (I) Conception and design: All authors; (II) Administrative support: A Willers; (III) Provision of study materials or patients: A Willers, S Mariani, J Swol, R Lorusso; (IV) Collection and assembly of data: A Willers, J Swol, S Mariani, R Lorusso; (V) Data analysis and interpretation: All authors; (VI) Manuscript writing: All authors; (VII) Final approval of manuscript: All authors.

Correspondence to: Anne Willers. Department of General Surgery, Catharina Ziekenhuis Eindhoven, Michelangelolaan 2, 5623 EJ, Eindhoven, The Netherlands. Email: annewillers@live.com.

Background and Objective: Resuscitative therapies for respiratory and cardiac failure are lifesaving and extended by using extracorporeal life support (ECLS) as mechanical circulatory support (MSC). This review informs the debate to identify the life-threatening thoracic emergencies in which patients may be cannulated for ECLS support.

Methods: An advanced search was performed in PubMed, Embase, Google Scholar, and references query, assessed in June 2022, identified 761 records. Among them, 74 publications in English were included in the current narrative review.

Key Content and Findings: ECLS is an additional tool for organ support in life-threatening thoracic emergencies. It provides bridging to recovery or to decision about destination as definitive therapy, intervention, or surgery. Non-traumatic emergencies include mediastinal mass, acute lung injury (ALI), aspiration, embolisms, acute and chronic heart failure. However, based on the current evidence, trauma, and especially blunt thoracic trauma, is one of the main indications for ECLS use in thoracic emergencies, among others in chest wall fractures, blunt and penetrating lung injuries. ECLS use is always individualized to patient's needs, injury pattern and kind of organ failure, circulatory arrest inclusive, depending on if respiratory or cardiac and circulatory support is needed. Further, ECLS offers the possibility for fast volume resuscitation and rewarming, thus preventing the lethal of trauma: hypothermia, hypoperfusion and acidosis. Anticoagulation may be omitted for some hours or days. Interdisciplinary cooperation between the intensivists, surgeons, anesthesiologists, emergency medical services, an appropriately organized and trained staff, equipment resources and logistical planning are essential for successful outcomes.

Conclusions: ECLS use in selected life-threatening thoracic emergencies is increasing. The summarized findings appeal to policymakers, and we hope that our summary of recommendations may impact clinical practice and research.

Keywords: Thoracic emergencies; extracorporeal life support (ECLS); extracorporeal membrane oxygenation (ECMO); hemorrhage; trauma

Submitted Sep 20, 2022. Accepted for publication Mar 30, 2023. Published online Apr 04, 2023.

doi: [10.21037/jtd-22-1307](https://doi.org/10.21037/jtd-22-1307)

View this article at: <https://dx.doi.org/10.21037/jtd-22-1307>

[^] ORCID: Anne Willers, 0000-0002-6376-9517; Silvia Mariani, 0000-0002-2238-1399; Roberto Lorusso, 0000-0002-1777-2045; Justyna Swol, 0000-0002-2903-092X.

Introduction

Background

The early pioneering cardiopulmonary bypass (CPB) technology (1), besides the application to perform planned cardiac surgery operations to treat acquired or congenital heart diseases, was used as temporary life support for patients with acute cardiac or respiratory failure. In 1972, a severe injured patient suffered several thoracic emergencies, among others including transection of thoracic aorta, as well multiple pelvic and lower limb fractures, after being struck by a motor vehicle (2,3). Four days later, he developed worsening acute respiratory distress syndrome (ARDS). On his sixth postoperative day, the first successful use of extracorporeal life support (ECLS), with a peripheral veno-arterial (V-A) configuration using a Bramson membrane heart-lung machine, was performed and continued for a total of 75 hours (3,4).

Rationale and knowledge gap

Over the last five decades, the use of ECLS has increased exponentially. ECLS provides temporary support of circulation and/or gas exchange bridging to recovery or to decision about destination as definitive therapy, intervention, or surgery. Historically, ECLS in trauma was considered as contraindication, due to coagulopathies and hemorrhage, difficulties in prone positioning, and need for further interventions and surgery (5,6). Due to advances in hemostatic resuscitation, percutaneous vascular cannula insertion, centrifugal pump technologies, and improvements in membrane oxygenators, there has been significant improvement in ECLS management and broadened indications for its use. However, its use in the trauma population remained controversial for a long time (6,7). An outcome analysis from Extracorporeal Life Support Organization (ELSO) registry showed that less than 1% of the adult ELSO registry population is diagnosed with a traumatic injury (6). In this cohort, thoracic injury was the most common diagnosis. The survival rates, comparable to other non-trauma groups, was reported by 70% at decannulation and 61% at hospital discharge (6). In parallel, the evidence for beneficial outcomes in hemorrhagic patients supported with ECLS is increasing (8). The benefits of hemodynamic support may outweigh the increased risk of bleeding since anticoagulation free protocols have been established thereby reducing or

even preventing anticoagulation-related bleeding worsening due to ECLS application and support (8). Early stabilization with ECLS might prevent or overcome the vicious circle of the lethal triad of trauma: hypothermia, hypoperfusion and acidosis, causing coagulopathy (8-10).

ARDS is the most common, non-traumatic indication for respiratory support on ECLS. CESAR trial published in 2009, was the randomized study which compared ECLS with conventional treatment and highlighted the importance of involving specialized units, lung-protective ventilation, indicating ECLS as a valuable option in refractory respiratory failure (11). The results of EOLIA study brought further results suggesting a possible superior clinical advantage of ECLS used for respiratory support over conventional measures, particularly when extracorporeal membrane oxygenation (ECMO) is used early. Conventional therapies, including prone positioning, had a high failure rate, necessitating rescue ECLS. Even if the mortality at day 60 in ECLS 44/124 (35%) *vs.* control group 57/125 (46%) was not significant (12), based on the previous evidence ECLS is a well-established organ support and becoming a standard practice. The Bayesian analysis of EOLIA stated that ECLS did prove to be superior to conventional therapy and, therefore, is now a well-established and accepted organ support in lung failure and ARDS, as also shown in the coronavirus disease 2019 (COVID-19) period (13). The outcomes of veno-venous (V-V) ECLS in patients with severe COVID-related ARDS showed similar results as patients with non-COVID-related ARDS (14).

Respiratory and cardiac failure are commonly seen in the out-of-hospital scene, emergency department (ED), intensive care unit (ICU), and operating room (OR). Initial resuscitative therapies for these conditions are lifesaving and nowadays extended by using ECLS and mechanical circulatory support (MSC) techniques.

Objective

This review addresses the application of ECLS in the life-threatening thoracic emergencies. The new developed classification of trauma and non-trauma categories in thoracic emergencies in which patients may be cannulated for ECLS support is also presented. We present this article in accordance with the Narrative Review reporting checklist (available at <https://jtd.amegroups.com/article/view/10.21037/jtd-22-1307/re>).

Description and classification of thoracic emergencies

Respiratory and/or cardiac failure are common due to trauma or non-traumatic underlying diseases. They may also result in circulatory, distributive, or obstructive and hypovolemic shock. ECLS is an additional, advanced tool for lung and/or heart organ support and does not represent the treatment of the underlying disease. Mostly used application modes of ECLS are V-V and V-A. V-V ECLS is aimed for respiratory support in which cardiovascular function is not severely compromised. V-A ECLS targets supporting cardiac or combined cardiopulmonary failure. Another support option for combined cardiopulmonary failure is V-A-venous hybrid mode (V-AV), which included V-A and V-V support (15). Regarding the definition and classification of thoracic emergencies with potential use of ECLS, the list of the newly categorized patterns and indications are shown in *Table 1*.

Methods

An advanced search of PubMed, Embase, and Google Scholar through their databases using the following Medical Subject Headings (MeSH) terms: “extracorporeal membrane oxygenation” AND “wounds and injuries” OR “wounds, nonpenetrating” OR “wounds, penetrating” OR “crush injuries” OR “hypothermia” OR “burns” OR “mediastinal mass” and free terms: “extracorporeal life support” OR “ECLS” OR “ECMO” AND “thoracic emergency” OR “blunt trauma” OR “penetrating trauma” OR “combat” OR “critical airway” OR “REBOA” assessed in June 2022, identified 761 records. From those, 74 publications in English language were analyzed. Reference lists of assessed full texts were screened for further relevant studies (16).

We included prospective and retrospective cohort studies, cross-sectional studies, case-control studies, case series and case reports. Studies reporting on use of any type of ECLS in thoracic, lung and cardiac trauma, hemorrhage, combat and burn thoracic injuries, and airways emergencies were considered eligible (*Table 2*). Available evidence was summarized using narrative review methodology.

Mediastinal mass

Mediastinal masses are often initially asymptomatic. The late symptoms of the appear usually from either mass effects on adjoining structures, or paraneoplastic effects.

Enlargement of mediastinal structures can cause severe respiratory impairment due to compression of the trachea and/or main bronchi. The stenosis of trachea and superior vena cava obstruction are secondary to compression from an enlarged mediastinal mass. Airway stents may provide effective and timely relief in patients with central airway obstruction. But severe, life-threatening respiratory failure may occur during such interventions. Thus, V-V ECLS is usually recommended in patients suffering severe hypoxemia and/or hypercapnia during invasive mechanical ventilation with exacerbating the risks of the mechanical ventilation induced lung injury (VILI). When committing an immunosuppressed patient to ECLS, patient selection and timing of initiation of these supports are the key considerations. ECLS use in immunocompromised patients with ARDS is increasing with 5% to 31% of patients receiving ECMO in recent studies. Because encouraging rates for hospital and long-term survival of immunocompromised patients in ICUs have been described, these patients are more likely to receive invasive therapies, also ECLS. Regarding the choice to perform ECLS or not, mainly due to possible complications of ECLS, as severe bleeding, the intensivists must take into account the future benefits of these patient.

Currently, ECLS may also be used as a protective bridging before, during and after interventions and procedures as among others, during induction chemotherapy and bronchoscopy intervention with stent placement preventing life-threatening deterioration. It leads to a paradigm shift in the pulmonary research.

Early V-V ECLS cannulation for respiratory support may improve survival in patients with mediastinal mass malignancies causing trachea obstruction and severe respiratory impairment. As configuration, femoro-femoral V-V cannulation is recommended as it enables stable blood flow avoiding the complications of superior vena cava obstruction.

ECLS in V-A configuration is used as a rescue management of anterior mediastinal masses with extrinsic compression on the airways and mediastinal vessels as well as during an emergent peri-arrest setting (17-20).

Tracheobronchial emergencies

The tracheobronchial tree plays a key role in ventilation. Any trauma, disruption or obstruction on these structures may be life-threatening and their treatment challenging, as in tracheal stenosis, tracheomalacia, tracheal tumors,

Table 1 Classification of thoracic emergencies (trauma and non-trauma, cardiac, parenchymal)

Organs or region	Trauma	Non-trauma
Respiratory		
Chest wall	Ribs, sternum, spine cord fractures	Chest wall tumor mass, compression, bleeding
Lung parenchyma	Contusion	ALI
	Post trauma ARDS	Atelectasis
	Penetrating injuries	Hemorrhagic condition (anticoagulants, coagulopathies due to hematological or rheumatological underlying disease)
	Bleeding	
Pleural	Pneumothorax	Tension- or spontaneous pneumothorax
	Tension- or hemopneumothorax	Hemopneumothorax (post-interventional complication)
Tracheobronchial system	Tracheal or bronchial rupture	Compression due to cervical mass (lymphoma, goiter)
	Difficult airway intubation	Trachea- or bronchial fistulas
	Aspiration (blood, stomach content)	Tracheal cannula dislocation
		Difficult airway intubation
		Aspiration (fluids, blood, stomach content, meconium in newborns)
Others	Burns, blast, and inhalation injury	Anterior mediastinal mass
	Drowning	
	Avalanche injury	
Cardiac		
Cardiac organ	Penetrating heart or great vessels injury	Chronic or acute heart failure due to underlying disease
	Aortic rupture or dissection	Cardiogenic shock
	Contusio cordis, luxatio cordis	Aortic dissection
Circulatory	Hemorrhagic shock (penetrating injury or bleeding coagulopathy)	Circulatory arrest
	Traumatic air embolism (due to long bone fracture)	Embolism (pulmonary artery embolism, amnion fluid embolism, air embolism)
Others		
Mediastinal	Esophageal rupture	Compression due to mediastinal tumor mass (lymphoma, retrosternal goiter)
	Trachea-esophageal fistula	Boerhaave syndrome (spontaneous esophageal rupture)
Hypothermia	Due to drowning or avalanche injury	Accidental
	Due to traumatic bleeding coagulopathy	Post-surgery
		Due to bleeding coagulopathy

ALI, acute lung injury; ARDS, acute respiratory distress syndrome.

iatrogenic tracheal injuries and foreign body aspiration. In these cases, emergency tracheostomy or coniotomy, cross field jet ventilation, direct cannulation of the distal trachea and small-bore endotracheal tubes can be employed (21). In several circumstances conventional ventilation is impossible.

In such situation, ECLS may provide adequate oxygenation without the need for endotracheal intubation (22). This allows for an adequate respiratory support while performing surgery to restore the airway anatomy.

Iatrogenic tracheal injuries are a rare but life-threatening

Table 2 Summary of proceeding the database search for related publications

Items	Specification
Date of search	June 2022
Databases and other sources searched	PubMed, EMBASE, Google Scholar
Search terms used	MeSH: “extracorporeal membrane oxygenation”, “wound and injuries”, “wounds, nonpenetrating”, “wounds, penetrating”, “crush injuries”, “hypothermia”, “burns”, “mediastinal mass” Free terms: “extracorporeal life support”, “ECLS”, “ECMO”, “thoracic emergency”, “blunt trauma”, “penetrating trauma”, “combat”, “critical airway”, “REBOA”
Timeframe of studies	1958–June 2022
Inclusion and exclusion criteria	Studies reporting on use of any type of ECLS in thoracic trauma, cardiac trauma, thoracic hemorrhage, combat and burn thoracic injuries, and airways emergencies were considered eligible Randomized clinical trials, controlled before-and-after studies, prospective and retrospective cohort studies, cross-sectional studies, case-control studies, case series and case reports. Conference abstracts, books, articles not written in English, and animal studies were excluded
Selection process	All the authors (AW, SM, JS, RL, JM) conducted the literature search and assessed the selected articles for inclusion. Consensus was reached when all the authors agreed on all studies

MeSH, Medical Subject Headings; ECLS, extracorporeal life support; ECMO, extracorporeal membrane oxygenation; REBOA, resuscitative endovascular balloon occlusion of the aorta.

complication of endotracheal intubation. Moreover, in 0.8% of blunt thoracic trauma victims, tracheobronchial injuries occur (23). Although a conservative approach is advised where possible, there are some cases which require surgical intervention (24). In distal airway ruptures, an endotracheal double lumen tube may prevent air leakage, tension pneumothorax or pneumomediastinum occluding the injured site. One-lung ventilation might be necessary but not sufficient for safe oxygenation (25,26). In such situations, a V-V ECLS can be used for respiratory support during surgery and post-operatively (24,27-31). V-V ECMO has been used during intraoperatively even for more complex procedures such as the repair of a tracheoesophageal fistula (32).

Further example of a critical airway condition foreign body aspiration. These patients can deteriorate fast due to asphyxia. Removing the foreign body with bronchoscopy is necessary but the bronchoscopy itself can cause intermittent complete airway occlusion due to manipulation in the main airways, aggravating the respiratory distress. V-V ECLS can support the respiratory system during the intervention, while extraction of the foreign body is performed (25).

Chest trauma and parenchymal injury

Thoracic trauma accounts for 20–25% of all trauma-

related deaths (33-35). Thoracic injuries may include injuries to the airways, lungs, or parts of the cardiovascular system. The pathophysiologic mechanisms of a thoracic injury are multiple and include thoracic bone injuries, tracheobronchial injuries, pulmonary contusions or lacerations, pneumothorax and pleural effusion, acute airway obstruction, barotrauma, or restrictive intra-thoracic spaces (36). Overall, the survival of patients with thoracic trauma depends on the extent of injury and the techniques of support (37). Trauma itself and surgery in trauma patients require volume and blood products administration and can cause systemic inflammation and an increase of vascular permeability in alveolar capillaries. This results in fluid shifts, edema forming and alveolar damage, leading to decreased gas exchange and eventually to acute lung injury (ALI) and ARDS (35,38). Furthermore, ventilator-associated pneumonia (VAP) is a frequent complication. ARDS requires protective lung ventilation with low tidal volumes and safe positive end-expiratory pressure (PEEP) limits. In all these cases, ECLS could be an option to minimize the ventilatory settings when standard and advanced ventilation are failing and protective ventilation is required (35). ECLS initiation and cannulation strategy should be carefully chosen in thoracic trauma patients since several injuries may limit the insertion of a cannula through the traditional ways (36). Overall, V-V ECLS is the most

used ECLS configuration for respiratory support while V-A ECLS is chosen in case of respiratory and circulatory support. In case of concomitant lung and right heart failure, a temporary right ventricular assist device with oxygenator (OxyRVAD) might be considered.

Results of ECLS use in chest trauma patients have been reported as positive by several small studies (39-41). Guirand *et al.* demonstrated that V-V ECMO was even associated with higher survival compared to conventional mechanical ventilation (41), mirroring the results of much larger studies performed in ARDS patients (42-45).

Prolonged mechanical ventilation (defined previously as longer than 7 days) was considered a relative contraindication for ECLS a decade or two decades ago, e.g., as an exclusion criterium for the CESAR trial (11). This exclusion criterium was chosen based on the rare use of lung protective ventilation in ICUs, and the frequent lung damage due to baro- and volu-trauma. On the other hand, the EOLIA trial, although known as “negative trial”, showed that the conventional management (including prone positioning) had a high failure rate, necessitating “rescue” ECLS cannulation (12). Thus, based on the ELSO guidelines and available literature, prolonged ventilation is not considered as an ECLS contraindication anymore (46,47).

Transfusion-related ALI (TRALI), ARDS, and VAP may also lead to severe lung failure with life threatening complications, thus ECLS in chest trauma and parenchymal lung injury should be carefully considered. However, based on the current evidence, trauma, and especially blunt thoracic trauma is one of the main indications for ECLS in thoracic emergencies. Trauma patients are younger than non-trauma patients, and they have less comorbidities. In large cohort studies, the outcomes of trauma patients supported on ECLS are comparable to non-trauma patients, and not worse than them (6,48).

Thoracic penetrating injuries and hemorrhagic shock

Most penetrating injuries include direct damage to the intercostal or mammary arteries, pleura or lung tissue (34) and can be managed non-operatively with thorax drainage and conventional resuscitation techniques (35). However, in 10–15% of cases, an operative management is necessary. The main cause of morbidity and mortality in these patients is the hemorrhagic shock which is the second most frequent cause of death in trauma patients after nervous system

injuries (49). Hemorrhagic shock and hemothorax can be a result of penetrating injury due to laceration of the intercostal or mammary arteries, thoracic spine arteries, lung parenchyma, great vessels, thoracic aorta, and the heart (*Figure 1*).

Hemorrhagic shock after thoracic injury is managed by volume resuscitation and mass transfusion (8,34). Mass transfusion may lead to TRALI as well. The pathophysiology of TRALI is quite similar to ARDS (50). Multiple cases of V-V ECLS has been reported successful to support patients with TRALI where conventional treatment was not sufficient (51-54).

Historically, bleeding has been considered a contraindication (8,55,56). However, due to the systematic review performed by Willers *et al.* (8). ECLS for temporary circulatory support in refractory hemorrhagic shock is feasible based on tailored devices and adequate patient management. However, ECLS is not designed for bleeding control and it should not be considered as such “therapy”. ECLS provides circulatory support that allows clinicians to gain time and bridge the patient to an appropriate medical, surgical, or interventional strategy for bleeding control, transfusions and coagulation supporting agents. Furthermore, new strategies and devices allows for a safer ECLS management in terms of anticoagulation (55).

ECLS might be indicated to support adequate tissue perfusion after the hemorrhagic shock, provide massive and quick transfusions, reduce systemic hypoxia and acidosis and prevent or treat hypothermia (8). Through these mechanisms, ECLS plays a pivotal role preventing or overcoming the vicious cycle of coagulopathy in hemorrhagic shock patients (57). Management of bleeding control, (surgical or interventional), transfusions and coagulation supporting agents is a separate strategy.

Aortic injuries

A direct penetrating injury or a complete transection of the aorta may cause exsanguination with pre-hospital death in 90% and 44% mortality of patients who make it to the emergency or OR (58). An aortic injury due to a blunt chest trauma is not always immediately lethal. Shearing forces due to rapid acceleration and deceleration on the aorta in blunt trauma may cause aortic dissection, typically at the ligamentum arteriosum where the aorta arch is fixed (59-61). Similarly, partial thickness injuries cause contained hematomas in the aortic walls. Patients with aortic injury need emergency surgery on CPB. However, these patients

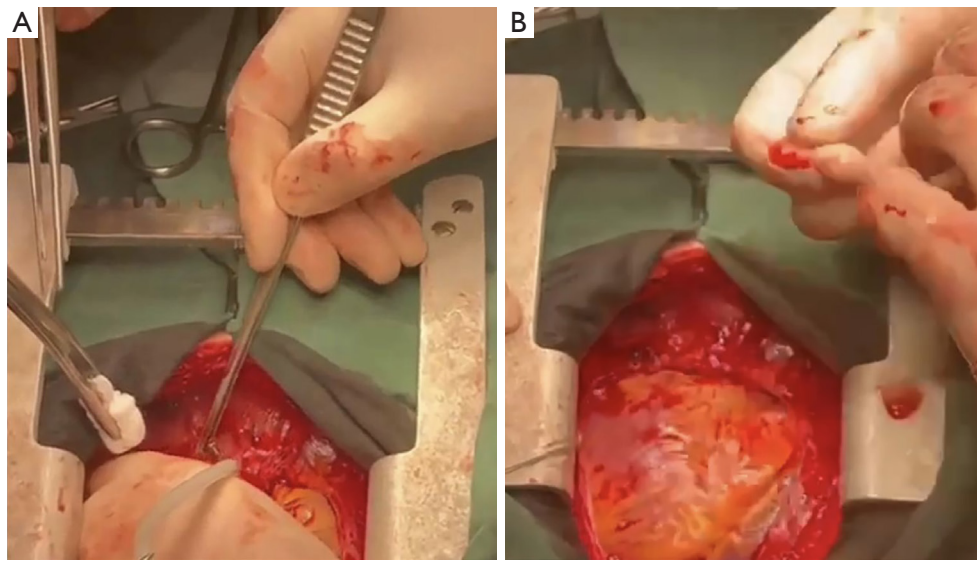


Figure 1 Projectile penetrating myocardium resulting in heart injury. (A) Splinter found in penetrating myocardial injury after combat injury in Ukraine. *In situ* corpus alienum pointed out by the forceps. (B) The corpus alienum is extracted from the patients, pointed out by the surgeon. With courtesy of Stepan Maruniak, MD, CCP, Department of Extracorporeal Methods of Treatment, Heart Institute Ministry of Health of Ukraine, Bratyslawka Str. 5A, 02166 Kyiv, Ukraine.

may rapidly deteriorate in the ED, aortic dissection may be misdiagnosed and/or cardiac surgery may not be available in every hospital. In such conditions, ECLS may be considered as a bridge to surgery and circulatory support but the evidence for ECLS in aortic injury is very scarce and controversial (15).

V-A ECLS is a potential option for refractory cardiogenic shock and cardiac arrest because it quickly improves hemodynamics and can be initiated rapidly. The most feared complication is the injury of the dissection membrane during the cannulation. In selected cases, the resuscitative endovascular balloon occlusion of the aorta (REBOA) might be required to control the massive hemorrhage from major vessels (62). Deployment of REBOA in the supra-diaphragmatic location (Zone I) allows for control of lower torso/abdominal or lower extremity bleeding. Zone II implies the placement of a REBOA between the celiac trunk and the renal arteries. Zone III involves REBOA placement below the renal arteries but proximal to the iliac bifurcation. ECLS can be applied also in combination with REBOA and a selective aortic arch perfusion (SAAP) to restore the circulation of the upper body in case of concomitant cardiac arrest or profound shock (63). In these cases, SAAP is a technique that combines thoracic aortic occlusion with a large-lumen balloon occlusion catheter inserted via a

femoral artery and positioned between the left subclavian artery and diaphragm. The SAAP catheter lumen allows for extracorporeal perfusion with flow limited to the upper body to allow for adequate control of the hemorrhagic focus while maintaining the perfusion of the upper body. Although the concept of SAAP has been extensively evaluated in preclinical studies, its clinical use has not yet been described (63).

Emergency preservation and resuscitation (EPR) is a novel approach to the management of patients who have suffered a cardiac arrest from trauma such as in case of major thoracic hemorrhage or penetrating cardiac injury (63). This technique involves rapid cooling of the body and a period of circulatory arrest to allow for surgical hemostasis and a subsequent rewarming phase through ECLS. Profound hypothermia is induced by large-volume cold fluid infusion into the thoracic aorta and blood drainage from the right atrial appendage. Surgical hemostasis is then achieved under ECLS. This technique is currently under clinical investigation (64).

Blunt thoracic trauma

Based on the current evidence, trauma, and especially blunt thoracic trauma, is one of the main indications for

ECLS use in thoracic emergencies. Indeed, the use of ECLS in trauma is broadly increasing (6,15,57,65,66). Blunt thoracic trauma is often caused by high-energy trauma with compression, deceleration or inertial forces due to falls, motor vehicle collisions or by direct forces from assault. Blunt trauma forces on the thorax often cause rib fractures, resulting in higher mortality and risk for pneumonia, especially in elderly patients. An extensive trauma including four or more rib fractures increases the risk for ICU admission, intubation and ventilation (34). Furthermore, a high-energy impact on the thorax can cause pulmonary contusions, damage to lung parenchyma, alveolar lacerations and hemorrhage, followed by edema. This clinical picture can lead to ALI or ARDS (23,34), and to a ventilation-perfusion mismatch that will eventually result in shunting. In these cases, ECLS can be indicated to provide respiratory support as bridge to recovery (23). V-V ECLS is the first choice in case of good cardiac function, due to its lower bleeding risks. Overall, promising outcomes of V-V ECLS in trauma-related hypoxemia are reported, even when emergency surgery is performed (39,67-69).

Previous studies report a survival rate of almost 75–80% in thoracic blunt trauma supported by ECLS. V-V ECLS is the most often ECLS configuration used. Damage control surgery or invasive measurements were performed in 15–30% and hemorrhagic complications are reported between 29% of the cases, mostly at the surgical site and cannula site (39,70).

Cardiac trauma and traumatic cardiac arrest

Cardiac arrest caused by trauma is associated to a low survival rate, with a high incidence of permanent neurologic disability in survivors (71). The etiology of traumatic cardiac arrest can be categorized in three main groups: penetrating injuries, blunt injuries and hemorrhage-induced traumatic cardiac arrest (63,72).

Penetrating injury of the heart is nowadays rare in European countries. This kind of injury is one of the possible indications for ECLS, e.g., as bridging to surgery in case of hemorrhagic shock (*Figure 1A,1B*). Penetrating trauma is associated with better outcome than blunt mechanisms, but the location of the injury greatly affects survival (63). Indeed, some studies report a 94% pre-hospital mortality in patients with penetrating cardiac injury (23) and chances of survival to the hospital are reported between 6–19.3% (34). In most cases, survival depends on the rapidity of the patient transfer to a cardiac

surgery center (73). Active bleeding and tamponade are the reason for severe hemodynamic instability in both penetrating and blunt injuries. Secondary myocardial contusion, myocardial stunning and/or infarction further complicate the clinical picture with acute heart failure. In these cases, the surgical control of the hemorrhage and the tamponade decompression are the treatment of choice. Simultaneously, V-A ECLS can provide adequate organs perfusion, rapid cooling of the body in case a circulatory arrest is required, therapeutic hypothermia and left ventricular unloading.

Blunt cardiac injuries include a wide range of clinical presentations, from ECG abnormalities to myocardial rupture and cardiogenic shock (23). In vehicle collisions, between 20–76% of death at scene is caused by blunt cardiac injuries (34) which usually include myocardial bruises, septal rupture with or without valvular injury, coronary artery injury and free wall ruptures. These injuries can result in direct congestive heart failure, myocardial infarctions and tamponade. Also arrhythmias can occur due to blunt chest trauma (34). When the cardiac function is not sufficient, an intra-aortic balloon pump can help to unload the left ventricle (23). However, unloading the left ventricle does not always secure sufficient cardiac function to maintain adequate tissue perfusion. In cases where cardiac function is significantly reduced, tissue perfusion must be supported with chronotropic and inotropic medications. ECLS can further support patients with deteriorated heart function whenever medical support is not sufficient (74). Indeed, patients with rupture of major vessels or cardiac rupture, cardiac arrest or valvular injury after blunt chest trauma have been successfully supported with ECLS (73,75-79).

Combat injuries

Recent years have witnessed a growing interest in the use of ECLS in military settings (80). Major traumas in battlefields are caused by explosions and are associated with inhalation, burn and blast injuries. There are four major types of blast injuries: direct tissue damage from pressurized waves, secondary injuries from penetrating wounds from projectiles, tertiary injuries from blunt or penetrating trauma caused by blast winds, and quaternary injuries including burns, radiation, and inhalation injuries (81). Soldiers exposed to explosions are thus at risk for multiple trauma injuries, including pulmonary injury. Blast lung injuries evolve to ARDS in 3–14% of patients sustaining primary blast injuries, associated with confined spaces

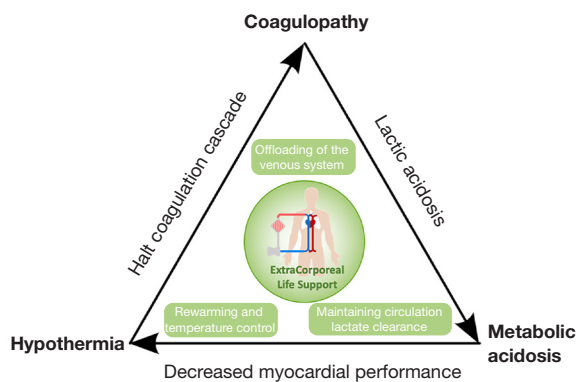


Figure 2 The triad of hypothermia, acidosis and coagulopathy causing further bleeding in hemorrhagic shock. ECLS used during the cardiopulmonary failure can restore the lethal triad characterized by metabolic acidosis, coagulopathy and hypothermia. ECLS, extracorporeal life support.

(82,83). Trauma patients in combat settings could benefit from fast respiratory and circulatory stabilization with ECLS so to allow a safer transport to a treatment facility. Literature reports few successful cases where interventional lung assists systems (iLA) were implanted to secure oxygenation during air transport as bridge to further treatments (84-86). Similarly, ECLS has been applied in ARDS after blast lung injury (87). Moreover, interfacility transport of patients submitted to ECLS has been improved and has proven to be safe and effective (88), supporting the growing role of ECLS as clinical approach for combat injuries (89). However, specialized teams are necessary to provide safe use of ECLS circuits and due to environmental factors, the use of ECLS on combat scenes is still very challenging.

Burn injuries

Burn and smoke inhalation injuries result in overwhelming inflammation activation with intra alveolar and intra bronchial damage with edema and hemorrhage. As a result, the lung compliance decreases, and alveolar gas exchange deteriorates. Finally, pulmonary shunting occurs, and hypoxemic respiratory failure can develop (90,91). Inhalation injury and sepsis leading to ARDS, multi-organ failure and shock have driven burn-related morbidity and mortality with 60% total body surface area involvement being a predictor of negative outcomes (92,93). Overall mortality of patients with burn inhalation injuries is reported between 16% and 85% in pediatric patients and

90% in the overall population (94,95). Successful use of ECLS in major burn injuries, with secondary ARDS, has been reported (90,96-103). Survival rates in these reports ranged between 28% and 87% (90,100,104). Nevertheless, limited evidence is reported. No large cohorts have been described and evidence of successful use of ECLS is only based on case series or case reports which might be biased and overestimate the survival rate of this specific patient group.

Benefits of ECLS in trauma patients

Trauma patients are conventionally treated with fluid resuscitation, ventilatory support and chest tube drainage. In cases of traumatic cardiorespiratory arrest, survival decreases to 17% (105). ECLS used during the cardiopulmonary failure can restore the lethal triad characterized by metabolic acidosis, coagulopathy and hypothermia (106) (Figure 2). ECLS may quickly restore the circulatory volume allowing for a resuscitation of 4L within 30 minutes with the use of normal to large size cannulas. With resuscitation and continuous cardiac support, circulation is restored and can therefore correct the metabolic acidosis. Furthermore, accidental hypothermia can be corrected with central rewarming via ECLS. Whenever there is cerebral injury, ECLS can be used in blood cooling to protect the cerebral tissue. By reversing hypothermia, coagulopathy can be reversed as well (57).

Limitations of ECLS in trauma patients

There are still concerns to the use of ECLS in trauma patients. First, by reversing hypothermia, coagulopathy can be prevented. But the use of ECLS, with foreign body cannulas and surfaces and the use of systemic anticoagulation, may promote the development of coagulopathy. In addition, the specific concern in trauma patients is further exsanguination during ECLS. In the past few years, the knowledge and experience with the use of ECLS has been expanding rapidly. ECLS systems have been improved with heparin bonding and modifications in the systemic anticoagulation management have been developed, decreasing the incidence of bleeding complications (35,57). A systematic review of patient with pre-existent hemorrhage, showed good outcomes of ECLS support with a survival rate of 82.3%. Only 26% of patients developed bleeding complications. Multiple solutions to minimize the risk of further bleeding, include an initial heparin-free

period, lower heparin targets or clamping of the tube in pulmonary bleeding (8). However, anticoagulation strategies and timing of ECLS initiation in trauma patients are still controversial (107).

Further research is needed to improve the use of ECLS in trauma. However, a low number of trauma patients submitted to ECLS complicates this. Most papers are case series of small cohorts. Research on prediction of survival is therefore difficult. Adding a trauma addendum to the previously mentioned ELSO registry, could contribute to further research.

Conclusions

ECLS use in thoracic emergencies is increasing. The summarized findings appeal to policymakers, and we hope that our summary of recommendations may impact clinical practice and research. ECLS use is always individualized to patient's needs, injury pattern and kind of organ failure, circulatory arrest inclusive, depending on if respiratory or cardiac and circulatory support is needed. It is recommended to adjust anticoagulation targets to patients' condition. Anticoagulation may be omitted for some hours or days. Daily, routine oxygenator checks are obligatory. ECLS is an additional tool for organ support and cannot be understood as a treatment of the underlying disease. ECLS provides bridging to recovery or to decision about destination as definitive therapy, intervention, or surgery. Interdisciplinary cooperation between the intensivists, surgeons, anesthesiologists, emergency medical services, an appropriately organized and trained staff, equipment resources and logistical planning are essential for successful outcomes.

Acknowledgments

We thank Dr. Maruniak Stepan, CCP (Department of Extracorporeal Methods of Treatment, Heart Institute Ministry of Health of Ukraine) for providing us with the figures of penetrating heart injury with consent.

Funding: None.

Footnote

Provenance and Peer Review: This article was commissioned by the Guest Editor (Ilhan Inci) for the series "Extracorporeal Life Support in Thoracic Surgery" published in *Journal of Thoracic Disease*. The article has

undergone external peer review.

Reporting Checklist: The authors have completed the Narrative Review reporting checklist. Available at <https://jtd.amegroups.com/article/view/10.21037/jtd-22-1307/rc>

Conflicts of Interest: All authors have completed the ICMJE uniform disclosure form (available at <https://jtd.amegroups.com/article/view/10.21037/jtd-22-1307/coif>). The series "Extracorporeal Life Support in Thoracic Surgery" was commissioned by the editorial office without any funding or sponsorship. RL is consultant for Medtronic (Minneapolis, MN, USA), Getinge and LivaNova (London, UK); Advisory Board Member of Eurosets (honoraria paid as research funding) and Xenios. The authors have no other conflicts of interest to declare.

Ethical Statement: The authors are accountable for all aspects of the work in ensuring that questions related to the accuracy or integrity of any part of the work are appropriately investigated and resolved.

Open Access Statement: This is an Open Access article distributed in accordance with the Creative Commons Attribution-NonCommercial-NoDerivs 4.0 International License (CC BY-NC-ND 4.0), which permits the non-commercial replication and distribution of the article with the strict proviso that no changes or edits are made and the original work is properly cited (including links to both the formal publication through the relevant DOI and the license). See: <https://creativecommons.org/licenses/by-nc-nd/4.0/>.

References

1. Gibbon JH Jr. Application of a mechanical heart and lung apparatus to cardiac surgery. *Minn Med* 1954;37:171-85; passim.
2. Hill JD, O'Brien TG, Murray JJ, et al. Prolonged extracorporeal oxygenation for acute post-traumatic respiratory failure (shock-lung syndrome). Use of the Bramson membrane lung. *N Engl J Med* 1972;286:629-34.
3. Featherstone PJ, Ball CM. The early history of extracorporeal membrane oxygenation. *Anaesth Intensive Care* 2018;46:555-7.
4. Hill JD. John H. Gibbon, Jr. Part I. The development of the first successful heart-lung machine. *Ann Thorac Surg* 1982;34:337-41.
5. Della Torre V, Robba C, Pelosi P, et al. Extra corporeal

- membrane oxygenation in the critical trauma patient. *Curr Opin Anaesthesiol* 2019;32:234-41.
6. Swol J, Brodie D, Napolitano L, et al. Indications and outcomes of extracorporeal life support in trauma patients. *J Trauma Acute Care Surg* 2018;84:831-7.
 7. Swol J, Cannon JW, Napolitano LM. ECMO in trauma: What are the outcomes? *J Trauma Acute Care Surg* 2017;82:819-20.
 8. Willers A, Swol J, Kowalewski M, et al. Extracorporeal Life Support in Hemorrhagic Conditions: A Systematic Review. *ASAIO J* 2021;67:476-84.
 9. Shenkman B, Budnik I, Einav Y, et al. Model of trauma-induced coagulopathy including hemodilution, fibrinolysis, acidosis, and hypothermia: Impact on blood coagulation and platelet function. *J Trauma Acute Care Surg* 2017;82:287-92.
 10. Gando S, Hayakawa M. Pathophysiology of Trauma-Induced Coagulopathy and Management of Critical Bleeding Requiring Massive Transfusion. *Semin Thromb Hemost* 2016;42:155-65.
 11. Peek GJ, Mugford M, Tiruvoipati R, et al. Efficacy and economic assessment of conventional ventilatory support versus extracorporeal membrane oxygenation for severe adult respiratory failure (CESAR): a multicentre randomised controlled trial. *Lancet* 2009;374:1351-63.
 12. Combes A, Hajage D, Capellier G, et al. Extracorporeal Membrane Oxygenation for Severe Acute Respiratory Distress Syndrome. *N Engl J Med* 2018;378:1965-75.
 13. Goligher EC, Tomlinson G, Hajage D, et al. Extracorporeal Membrane Oxygenation for Severe Acute Respiratory Distress Syndrome and Posterior Probability of Mortality Benefit in a Post Hoc Bayesian Analysis of a Randomized Clinical Trial. *JAMA* 2018;320:2251-9.
 14. Ramanathan K, Shekar K, Ling RR, et al. Extracorporeal membrane oxygenation for COVID-19: a systematic review and meta-analysis. *Crit Care* 2021;25:211.
 15. Swol J, Belohlávek J, Brodie D, et al. Extracorporeal life support in the emergency department: A narrative review for the emergency physician. *Resuscitation* 2018;133:108-17.
 16. Wohlin C. Guidelines for snowballing in systematic literature studies and a replication in software engineering. In: *Proceedings of the 18th International Conference on Evaluation and Assessment in Software Engineering*. 2014:1-10.
 17. Au V, Marsh B, Benkwitz C. Resection of a Posterior Mediastinal Mass in a 4-Year-Old Child Complicated by Difficult Airway Management and Emergent Use of Extracorporeal Membrane Oxygenation. *Semin Cardiothorac Vasc Anesth* 2020;24:349-54.
 18. Kodja K, Liu Y, Ghodsizad A, et al. Use of venovenous extracorporeal membrane oxygenation for resection of a large paratracheal mass causing critical tracheal stenosis: A case report. *J Card Surg* 2021;36:367-70.
 19. Oyake M, Suenobu S, Miyawaki M, et al. Airway Emergencies Due to Anterior Mediastinal T-Lymphoblastic Lymphoma Managed With Planned Extracorporeal Membrane Oxygenation and Endotracheal Stent: A Case Report and Literature Review. *Cureus* 2022;14:e21799.
 20. Leow L, Sampath HK, Yong KJ, et al. Rescue extracorporeal membrane oxygenation for massive anterior mediastinal masses. *J Artif Organs* 2021;24:450-7.
 21. Eadington T, Oommen K. The role of extracorporeal membrane oxygenation in thoracic surgery—a narrative review. *Shanghai Chest* 2022;6:22.
 22. Kim SH, Song S, Kim YD, et al. Outcomes of Extracorporeal Life Support During Surgery for the Critical Airway Stenosis. *ASAIO J* 2017;63:99-103.
 23. Round JA, Mellor AJ. Anaesthetic and critical care management of thoracic injuries. *J R Army Med Corps* 2010;156:145-9.
 24. Hawkins RB, Thiele EL, Huffmyer J, et al. Extracorporeal membrane oxygenation for management of iatrogenic distal tracheal tear. *JTCVS Tech* 2020;4:389-91.
 25. Hoetzenecker K, Klepetko W, Keshavjee S, et al. Extracorporeal support in airway surgery. *J Thorac Dis* 2017;9:2108-17.
 26. O'Malley TJ, Yost CC, Prochno KW, et al. Extracorporeal life support and cardiopulmonary bypass for central airway surgery: A systematic review. *Artif Organs* 2022;46:362-74.
 27. Antonacci F, De Tisi C, Donadoni I, et al. Venovenous ECMO during surgical repair of tracheal perforation: A case report. *Int J Surg Case Rep* 2018;42:64-6.
 28. Go PH, Pai A, Larson SB, et al. Repair of iatrogenic tracheal injury in acute respiratory failure with venovenous extracorporeal membrane oxygenation. *Perfusion* 2021;36:100-2.
 29. Al-Thani H, Ahmed K, Rizoli S, et al. Utility of extracorporeal membrane oxygenation (ECMO) in the management of traumatic tracheobronchial injuries: case series. *J Surg Case Rep* 2021;2021:rjab158.
 30. Ballouhey Q, Fesseau R, Benouaich V, et al. Management of blunt tracheobronchial trauma in the pediatric age group. *Eur J Trauma Emerg Surg* 2013;39:167-71.
 31. Suh JW, Shin HJ, Lee CY, et al. Surgical Repair of a

- Traumatic Tracheobronchial Injury in a Pediatric Patient Assisted with Venoarterial Extracorporeal Membrane Oxygenation. *Korean J Thorac Cardiovasc Surg* 2017;50:403-6.
32. van Drumpt AS, Kroon HM, Grüne F, et al. Surgery for a large tracheoesophageal fistula using extracorporeal membrane oxygenation. *J Thorac Dis* 2017;9:E735-8.
 33. Khandhar SJ, Johnson SB, Calhoun JH. Overview of thoracic trauma in the United States. *Thorac Surg Clin* 2007;17:1-9.
 34. Bernardin B, Troquet JM. Initial management and resuscitation of severe chest trauma. *Emerg Med Clin North Am* 2012;30:377-400, viii-ix.
 35. Mulder L, Keelan S, Kang D, et al. Early Use of Extracorporeal Membrane Oxygenation after Penetrating Thoracic Trauma. *Am Surg* 2018;84:e416-7.
 36. Ramin S, Charbit J, Jaber S, et al. Acute respiratory distress syndrome after chest trauma: Epidemiology, specific physiopathology and ventilation strategies. *Anaesth Crit Care Pain Med* 2019;38:265-76.
 37. Van Way CW 3rd. Advanced techniques in thoracic trauma. *Surg Clin North Am* 1989;69:143-55.
 38. Ochiai R. Mechanical ventilation of acute respiratory distress syndrome. *J Intensive Care* 2015;3:25.
 39. Ried M, Bein T, Philipp A, et al. Extracorporeal lung support in trauma patients with severe chest injury and acute lung failure: a 10-year institutional experience. *Crit Care* 2013;17:R110.
 40. Bonacchi M, Spina R, Torracchi L, et al. Extracorporeal life support in patients with severe trauma: an advanced treatment strategy for refractory clinical settings. *J Thorac Cardiovasc Surg* 2013;145:1617-26.
 41. Guirand DM, Okoye OT, Schmidt BS, et al. Venovenous extracorporeal life support improves survival in adult trauma patients with acute hypoxemic respiratory failure: a multicenter retrospective cohort study. *J Trauma Acute Care Surg* 2014;76:1275-81.
 42. Robba C, Ortu A, Bilotta F, et al. Extracorporeal membrane oxygenation for adult respiratory distress syndrome in trauma patients: A case series and systematic literature review. *J Trauma Acute Care Surg* 2017;82:165-73.
 43. Fortenberry JD, Meier AH, Pettignano R, et al. Extracorporeal life support for posttraumatic acute respiratory distress syndrome at a children's medical center. *J Pediatr Surg* 2003;38:1221-6.
 44. Lee HK, Kim HS, Ha SO, et al. Clinical outcomes of extracorporeal membrane oxygenation in acute traumatic lung injury: a retrospective study. *Scand J Trauma Resusc Emerg Med* 2020;28:41.
 45. Bosarge PL, Raff LA, McGwin G Jr, et al. Early initiation of extracorporeal membrane oxygenation improves survival in adult trauma patients with severe adult respiratory distress syndrome. *J Trauma Acute Care Surg* 2016;81:236-43.
 46. Giani M, Maggiolini D, Ambrosetti L, et al. Prolonged Noninvasive Respiratory Support Before Intubation Is Associated With Increased Duration of Extracorporeal Membrane Oxygenation. *ASAIO J* 2023;69:e118-20.
 47. Olivier PY, Ottavy G, Hoff J, et al. Prolonged time from intubation to cannulation in VV-ECMO for COVID-19: does it really matter? *Crit Care* 2021;25:385.
 48. Ull C, Schildhauer TA, Strauch JT, et al. Outcome measures of extracorporeal life support (ECLS) in trauma patients versus patients without trauma: a 7-year single-center retrospective cohort study. *J Artif Organs* 2017;20:117-24.
 49. Sauaia A, Moore FA, Moore EE, et al. Epidemiology of trauma deaths: a reassessment. *J Trauma* 1995;38:185-93.
 50. Semple JW, Rebetz J, Kapur R. Transfusion-associated circulatory overload and transfusion-related acute lung injury. *Blood* 2019;133:1840-53.
 51. Kuroda H, Masuda Y, Imaizumi H, et al. Successful extracorporeal membranous oxygenation for a patient with life-threatening transfusion-related acute lung injury. *J Anesth* 2009;23:424-6.
 52. Kojima T, Nishisako R, Sato H. A patient with possible TRALI who developed pulmonary hypertensive crisis and acute pulmonary edema during cardiac surgery. *J Anesth* 2012;26:460-3.
 53. Lee AJ, Koyyalamudi PL, Martinez-Ruiz R. Severe transfusion-related acute lung injury managed with extracorporeal membrane oxygenation (ECMO) in an obstetric patient. *J Clin Anesth* 2008;20:549-52.
 54. Plotkin JS, Shah JB, Lofland GK, et al. Extracorporeal membrane oxygenation in the successful treatment of traumatic adult respiratory distress syndrome: case report and review. *J Trauma* 1994;37:127-30.
 55. Willers A, Arens J, Mariani S, et al. New Trends, Advantages and Disadvantages in Anticoagulation and Coating Methods Used in Extracorporeal Life Support Devices. *Membranes (Basel)* 2021;11:617.
 56. Willers A, Swol J, Buscher H, et al. Longitudinal Trends in Bleeding Complications on Extracorporeal Life Support Over the Past Two Decades-Extracorporeal Life Support Organization Registry Analysis. *Crit Care Med*

- 2022;50:e569-80.
57. Arlt M, Philipp A, Voelkel S, et al. Extracorporeal membrane oxygenation in severe trauma patients with bleeding shock. *Resuscitation* 2010;81:804-9.
 58. Hunt JP, Baker CC, Lentz CW, et al. Thoracic aorta injuries: management and outcome of 144 patients. *J Trauma* 1996;40:547-55; discussion 555-6.
 59. Parmley LF, Mattingly TW, Manion WC. Penetrating wounds of the heart and aorta. *Circulation* 1958;17:953-73.
 60. Parmley LF, Mattingly TW, Manion WC, et al. Nonpenetrating traumatic injury of the aorta. *Circulation* 1958;17:1086-101.
 61. Schulman CI, Carvajal D, Lopez PP, et al. Incidence and crash mechanisms of aortic injury during the past decade. *J Trauma* 2007;62:664-7.
 62. Thrailkill MA, Gladin KH, Thorpe CR, et al. Resuscitative Endovascular Balloon Occlusion of the Aorta (REBOA): update and insights into current practices and future directions for research and implementation. *Scand J Trauma Resusc Emerg Med* 2021;29:8.
 63. Manning JE, Rasmussen TE, Tisherman SA, et al. Emerging hemorrhage control and resuscitation strategies in trauma: Endovascular to extracorporeal. *J Trauma Acute Care Surg* 2020;89:S50-8.
 64. Tisherman SA, Alam HB, Rhee PM, et al. Development of the emergency preservation and resuscitation for cardiac arrest from trauma clinical trial. *J Trauma Acute Care Surg* 2017;83:803-9.
 65. Ahmad SB, Menaker J, Kufera J, et al. Extracorporeal membrane oxygenation after traumatic injury. *J Trauma Acute Care Surg* 2017;82:587-91.
 66. Amos T, Bannon-Murphy H, Yeung M, et al. ECMO (extracorporeal membrane oxygenation) in major trauma: A 10 year single centre experience. *Injury* 2021;52:2515-21.
 67. Dagod G, Ramin S, Solovei L, et al. A combined management with vv-ECMO and independent lung ventilation for asymmetric chest trauma. *Gen Thorac Cardiovasc Surg* 2021;69:902-5.
 68. Whittaker D, Edmunds C, Scott I, et al. Rib fracture fixation in a patient on veno-venous ECMO for severe blunt thoracic trauma. *Ann R Coll Surg Engl* 2021;103:e269-71.
 69. Cordell-Smith JA, Roberts N, Peek GJ, et al. Traumatic lung injury treated by extracorporeal membrane oxygenation (ECMO). *Injury* 2006;37:29-32.
 70. Jacobs JV, Hoof NM, Robinson BR, et al. The use of extracorporeal membrane oxygenation in blunt thoracic trauma: A study of the Extracorporeal Life Support Organization database. *J Trauma Acute Care Surg* 2015;79:1049-53; discussion 1053-4.
 71. Martin SK, Shatney CH, Sherck JP, et al. Blunt trauma patients with prehospital pulseless electrical activity (PEA): poor ending assured. *J Trauma* 2002;53:876-80; discussion 880-1.
 72. Teeter W, Haase D. Updates in Traumatic Cardiac Arrest. *Emerg Med Clin North Am* 2020;38:891-901.
 73. Yoann L, Erwan F, Nicolas N, et al. Extracorporeal life support in a severe blunt chest trauma with cardiac rupture. *Case Rep Crit Care* 2013;2013:136542.
 74. Misselbrook GP, Hameed SM, Garraway N, et al. VA-ECMO as a salvage strategy for blunt cardiac injury in the context of multisystem trauma. *BMJ Case Rep* 2021;14:e241034.
 75. Huh U, Song S, Chung SW, et al. Is extracorporeal cardiopulmonary resuscitation practical in severe chest trauma? A systematic review in single center of developing country. *J Trauma Acute Care Surg* 2017;83:903-7.
 76. Kudo S, Tanaka K, Okada K, et al. Extracorporeal cardiopulmonary resuscitation for blunt cardiac rupture. *Am J Emerg Med* 2017;35:1789.e1-2.
 77. Restrepo-Córdoba MA, Hernández-Pérez FJ, Gómez-Bueno MF, et al. Post-traumatic ventricular septal defect: a rare indication for extracorporeal membrane oxygenation as a bridge to transplant. *Cardiovasc Diagn Ther* 2017;7:85-8.
 78. Lambrechts DL, Wellens F, Vercoetere RA, et al. Early stabilization of traumatic aortic transection and mitral valve regurgitation with extracorporeal membrane oxygenation. *Tex Heart Inst J* 2003;30:65-7.
 79. Pasquier M, Sierro C, Yersin B, et al. Traumatic mitral valve injury after blunt chest trauma: a case report and review of the literature. *J Trauma* 2010;68:243-6.
 80. Read MD, Nam JJ, Biscotti M, et al. Evolution of the United States Military Extracorporeal Membrane Oxygenation Transport Team. *Mil Med* 2020;185:e2055-60.
 81. Mansky R, Scher C. Thoracic trauma in military settings: a review of current practices and recommendations. *Curr Opin Anaesthesiol* 2019;32:227-33.
 82. Boutillier J, Deck C, Magnan P, et al. A critical literature review on primary blast thorax injury and their outcomes. *J Trauma Acute Care Surg* 2016;81:371-9.
 83. Leibovici D, Gofrit ON, Stein M, et al. Blast injuries: bus versus open-air bombings--a comparative study of injuries in survivors of open-air versus confined-space explosions. *J Trauma* 1996;41:1030-5.

84. Bein T, Osborn E, Hofmann HS, et al. Successful treatment of a severely injured soldier from Afghanistan with pumpless extracorporeal lung assist and neurally adjusted ventilatory support. *Int J Emerg Med* 2010;3:177-9.
85. Zimmermann M, Philipp A, Schmid FX, et al. From Baghdad to Germany: use of a new pumpless extracorporeal lung assist system in two severely injured US soldiers. *ASAIO J* 2007;53:e4-6.
86. Bein T, Zonies D, Philipp A, et al. Transportable extracorporeal lung support for rescue of severe respiratory failure in combat casualties. *J Trauma Acute Care Surg* 2012;73:1450-6.
87. Mohamed MAT, Maraqa T, Bacchetta MD, et al. The Feasibility of Venovenous ECMO at Role-2 Facilities in Austere Military Environments. *Mil Med* 2018;183:e644-8.
88. Tipograf Y, Liou P, Oommen R, et al. A decade of interfacility extracorporeal membrane oxygenation transport. *J Thorac Cardiovasc Surg* 2019;157:1696-706.
89. Macku D, Hedvicak P, Quinn JM, et al. Prehospital Medicine and the Future Will ECMO Ever Play a Role? *J Spec Oper Med* 2018;18:133-8.
90. Ainsworth CR, Dellavolpe J, Chung KK, et al. Revisiting extracorporeal membrane oxygenation for ARDS in burns: A case series and review of the literature. *Burns* 2018;44:1433-8.
91. Asmussen S, Maybauer DM, Fraser JF, et al. Extracorporeal membrane oxygenation in burn and smoke inhalation injury. *Burns* 2013;39:429-35.
92. Pierre EJ, Zwischenberger JB, Angel C, et al. Extracorporeal membrane oxygenation in the treatment of respiratory failure in pediatric patients with burns. *J Burn Care Rehabil* 1998;19:131-4.
93. Thompson KB, Dawoud F, Castle S, et al. Extracorporeal Membrane Oxygenation Support for Pediatric Burn Patients: Is It Worth the Risk? *Pediatr Crit Care Med* 2020;21:469-76.
94. Dries DJ. Extracorporeal Membrane Oxygenation in Pediatric Burns: Worth a Closer Look. *Pediatr Crit Care Med* 2020;21:500-1.
95. Jones SW, Williams FN, Cairns BA, et al. Inhalation Injury: Pathophysiology, Diagnosis, and Treatment. *Clin Plast Surg* 2017;44:505-11.
96. Hsu PS, Tsai YT, Lin CY, et al. Benefit of extracorporeal membrane oxygenation in major burns after stun grenade explosion: Experience from a single military medical center. *Burns* 2017;43:674-80.
97. Rasmussen J, Erdogan M, Loubani O, et al. Successful Use of Extracorporeal Membrane Oxygenation Therapy in Patients With 80% Full Thickness Burns. *J Burn Care Res* 2021;42:345-7.
98. Hebert S, Erdogan M, Green RS, et al. The Use of Extracorporeal Membrane Oxygenation in Severely Burned Patients: A Survey of North American Burn Centers. *J Burn Care Res* 2022;43:462-7.
99. Patton ML, Simone MR, Kraut JD, et al. Successful utilization of ECMO to treat an adult burn patient with ARDS. *Burns* 1998;24:566-8.
100. Eldredge RS, Zhai Y, Cochran A. Effectiveness of ECMO for burn-related acute respiratory distress syndrome. *Burns* 2019;45:317-21.
101. Chiu YJ, Ma H, Liao WC, et al. Extracorporeal membrane oxygenation support may be a lifesaving modality in patients with burn and severe acute respiratory distress syndrome: Experience of Formosa Water Park dust explosion disaster in Taiwan. *Burns* 2018;44:118-23.
102. Starr BW, Bennett S, Chang PH, et al. ECMO Therapy in a Patient with Extensive Burns, Inhalation Injury, and Blunt Chest Trauma. *Am Surg* 2020;86:e40-2.
103. Szentgyorgyi L, Shepherd C, Dunn KW, et al. Extracorporeal membrane oxygenation in severe respiratory failure resulting from burns and smoke inhalation injury. *Burns* 2018;44:1091-9.
104. Soussi S, Gallais P, Kachatrian L, et al. Extracorporeal membrane oxygenation in burn patients with refractory acute respiratory distress syndrome leads to 28 % 90-day survival. *Intensive Care Med* 2016;42:1826-7.
105. Huber-Wagner S, Lefering R, Qvick M, et al. Outcome in 757 severely injured patients with traumatic cardiorespiratory arrest. *Resuscitation* 2007;75:276-85.
106. Rossaint R, Cerny V, Coats TJ, et al. Key issues in advanced bleeding care in trauma. *Shock* 2006;26:322-31.
107. Wang C, Zhang L, Qin T, et al. Extracorporeal membrane oxygenation in trauma patients: a systematic review. *World J Emerg Surg* 2020;15:51.

Cite this article as: Willers A, Mariani S, Maessen JM, Lorusso R, Swol J. Extracorporeal life support in thoracic emergencies—a narrative review of current evidence. *J Thorac Dis* 2023;15(7):4076-4089. doi: 10.21037/jtd-22-1307