

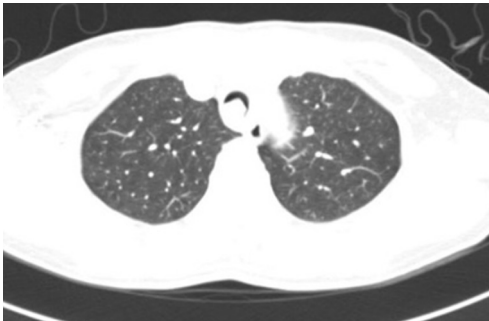
## Erratum to Non-intubated resection and reconstruction of trachea for the treatment of a mass in the upper trachea

doi: 10.21037/jtd.2016.04.35

View this article at: <http://dx.doi.org/10.21037/jtd.2016.04.35>

Erratum to: J Thorac Dis 2016;8:594-599

In the article that appeared on Page 594-599 of the March 2016 Issue of the Journal of Thoracic Disease (1), *Figure 1* is incorrect and should have been as shown below.



**Figure 1** Preoperative CT showed that a mass was located inside the upper trachea at the entrance to the rib cage and blocked the tracheal lumen; emphysema in the mediastinal area could be observed. CT, computed tomography.

The publisher regrets the error.

### References

1. Liu J, Li S, Shen J, et al. Non-intubated resection and reconstruction of trachea for the treatment of a mass in the upper trachea. J Thorac Dis 2016;8:594-9.

**Cite this article as:** Erratum to Non-intubated resection and reconstruction of trachea for the treatment of a mass in the upper trachea. J Thorac Dis 2016. doi: 10.21037/jtd.2016.04.35