

CASE REPORT

Postoperative radiotherapy for residual tumor of primary mediastinal carcinoid teratoma

Lingli Tu^{1*}, Lan Sun^{1,2*}, Yu Zhou¹, Youling Gong¹, Jianxin Xue¹, Jun Gao³, You Lu¹, Yongsheng Wang¹

¹Department of Thoracic Oncology, Cancer Center, West China Hospital, Sichuan University, Chengdu, China; ²Department of Oncology, People's hospital of Bishan County, Bishan, ChongQing, China; ³Department of Pathology, West China Hospital, Sichuan University, Chengdu, China

ABSTRACT

A 36-year-old woman had presented with dry cough for 2 months. Thoracic computed tomography (CT) scan showed a 12 cm × 8 cm × 5 cm mass in the anterior mediastinum. Due to intimately involving the aortic arch, tumor was removed incompletely. Residual tumor remained approximate 2 cm × 3 cm × 4 cm. Histologic diagnosis was a mature cystic teratoma containing a carcinoid. Subsequently, radiotherapy (RT) was administrated on residual tumor for a total dose of 50 Gy at 2 Gy/d fraction in 25 fractions. At 2-year follow-up, the patient had stable disease. In conclusion, adjuvant radiotherapy with 50 Gy is an effective approach for residual tumor of mediastinal carcinoid teratoma.

KEY WORDS

Teratoma; carcinoid; mediastinum; residual tumor; radiotherapy

J Thorac Dis 2013;5(2):E61-E64. doi: 10.3978/j.issn.2072-1439.2012.11.11

Introduction

Teratomas are germ cell tumors commonly containing multiple cell types derived from different germ layers. Cystic teratoma is defined as a benign, well-differentiated cystic lesion, occurring in sequestered midline occasionally. Carcinoid tumor is considered as a neuroendocrine tumor with uncertain malignant potential. The main treatment of these tumors is complete surgical resection. However, it's difficult if intrathoracic structures are intimately involved with the tumor (1). Thus, more approaches should be performed. Generally, salvage surgery is considered as the main treatment option for residual tumor. Radiotherapy is a good alternative option as well. However, there is little evidence for benefit from adjuvant chemotherapy.

In our case, a mediastinal carcinoid teratoma, which involved the aortic arch, was removed incompletely. To our knowledge, there were only 4 published articles to date reporting this rare tumor (2-5). Of these, residual diseases were not reported. Thus, we herein report a case of mediastinal carcinoid teratoma for this

rare residual tumor with an effective radiation treatment at 2-year follow-up.

Case report

A 36-year-old woman had dry cough last for 2 months. Thoracic CT scan found an abnormal mass in the anterior mediastinum (Figure 1A,B). Tumor biomarkers (CEA, CA153, CA125, AFP and beta-hCG) were all within normal ranges. Patient was assessed to be suitable for operation (ECOG score =1). Thoracotomy was undergone with a sharp and blunt dissection. In the operation, a cystic mass, 12 cm × 8 cm × 5 cm, was found in the anterior mediastinum. The mass which involved the aortic arch was removed incompletely. The residual tumor was reported approximate 2 cm × 3 cm × 4 cm. Histological diagnosis was mature mediastinal cystic teratoma containing a carcinoid (Figure 2). Immunohistochemistry showed carcinoid cells were immunopositive for CgA, Syn and NSE (Figure 3). Subsequently, adjuvant treatment with 6MV conventional intensity-modulated radiation therapy (IMRT) regimen was administrated on it for a total dose of 50 Gy at 2 Gy/d fraction in 25 fractions. At 2-year follow-up, the residual tumor was stable (Figure 1C,D). There is no evidence of disease progression found by routine examinations. Now the patient is kept under observation only with slight dry cough.

Discussion

Teratomas differentiate from various germ lines and could recapitulate any tissue of the body, including hair, teeth, skin,

*Lan Sun and Lingli Tu contributed equally to this work.

Corresponding to: Dr. Yongsheng Wang. Department of Thoracic Oncology, Cancer Center, West China Hospital, Sichuan University, Chengdu 610041, China. Email: wangys75@gmail.com.

Submitted Oct 23, 2012. Accepted for publication Nov 27, 2012.
Available at www.jthoracdis.com

ISSN: 2072-1439

© Pioneer Bioscience Publishing Company. All rights reserved.

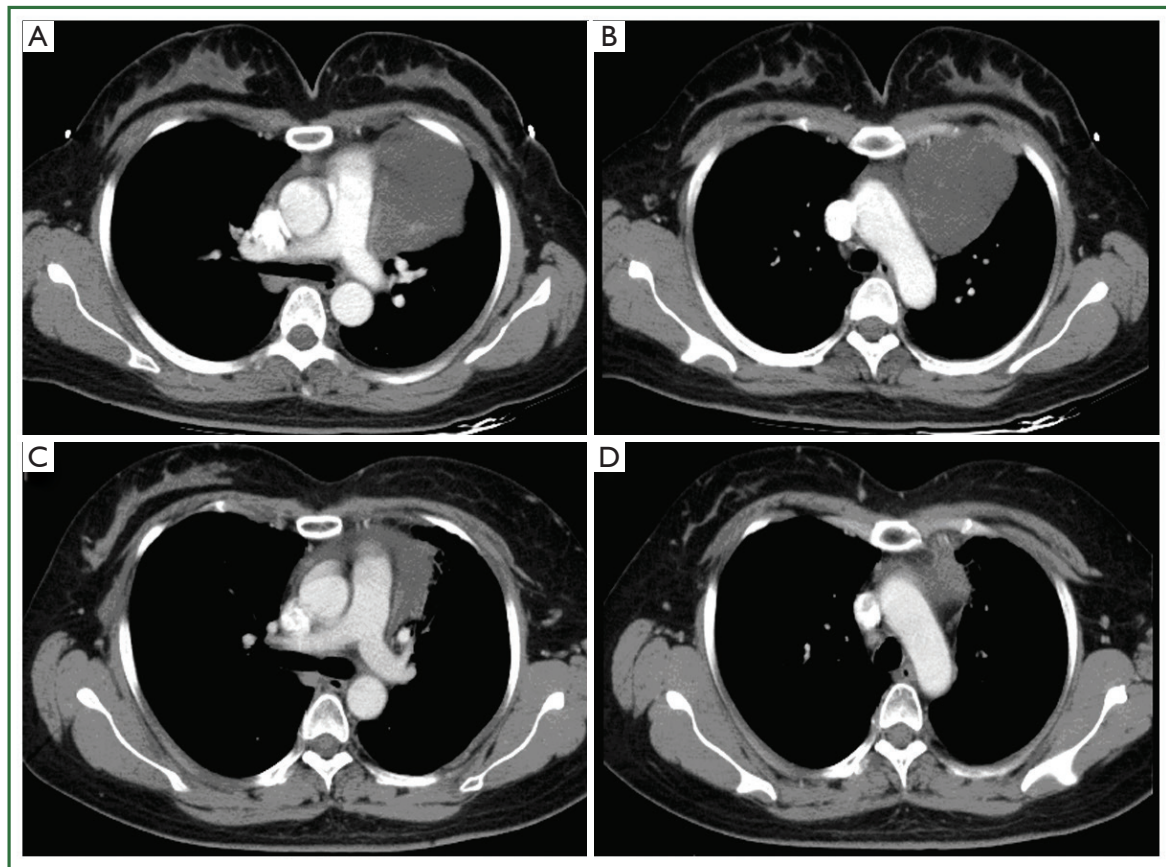


Figure 1. Thoracic CT revealed a primary mediastinal tumor before surgery (A, B), and a stable residual tumor (C, D) at 2-year follow-up.

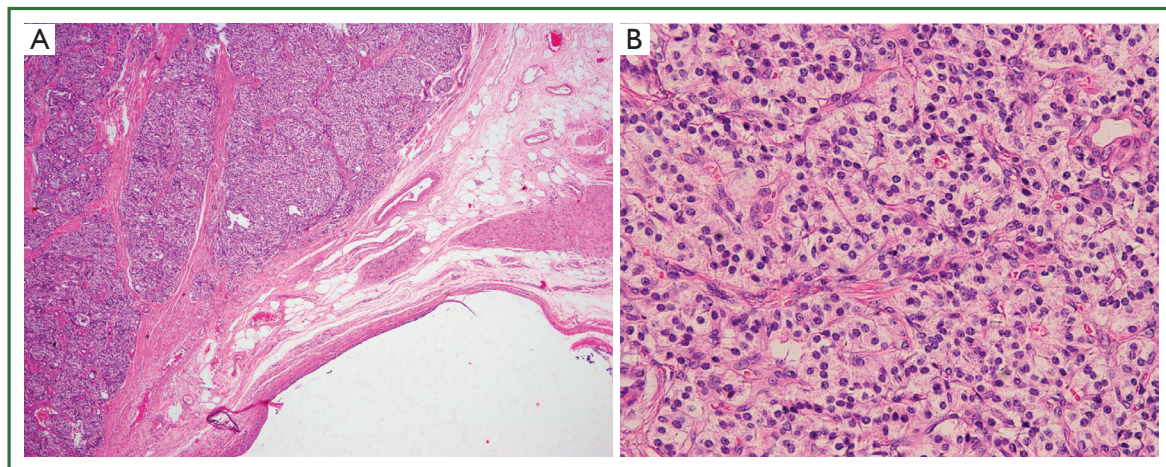


Figure 2. Mature mediastinal cystic teratoma containing a carcinoid (H&E). A carcinoid was disposed by a cystic mass containing mature epithelial, muscular, vascular and nervous tissues (A, $\times 40$). Moreover, carcinoid cells were presented to be monomorphic with uniform nuclei, conspicuous nucleoli and scanty cytoplasm (B, $\times 400$).

muscle, fat and so on. Mature teratoma is often considered as a benign lesion without metastatic potential. However, malignant transformation of mature teratoma is rarely occurred in 1-3% cases (6), including transformation to sarcoma (7), adenocarcinoma (8), squamous cell carcinoma (9) and carcinoid tumor.

Malignant degeneration to carcinoid tumor is usually midline or paraxial, including ovary (10), testis (11), presacrum (12), retroperitoneum (13) and mediastinum (2-5).

Carcinoid tumor is generally considered to be a low-grade malignancy distributed throughout the body, including

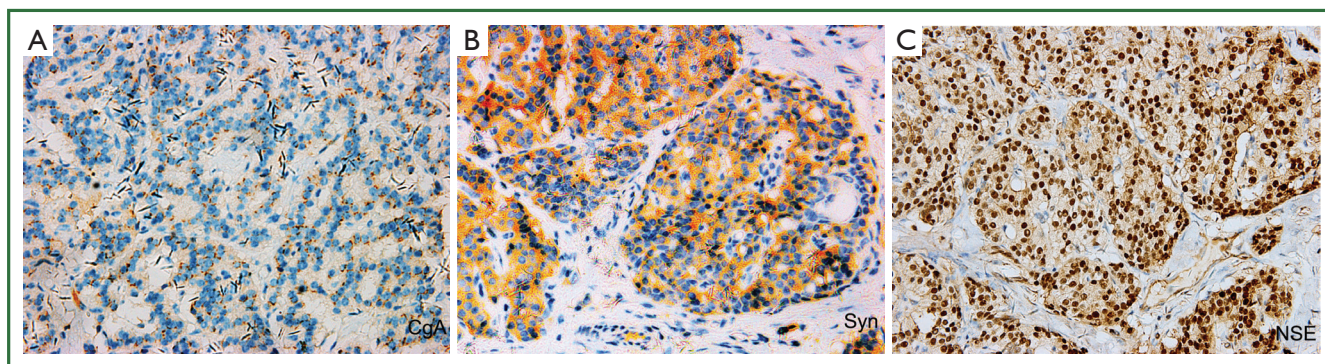


Figure 3. Carcinoid cells were immuno-positive for CgA, Syn and NSE ($\times 400$). Abbreviations: CgA, chromogranin A; Syn, synaptophysin; NSE, neuron-specific enolase.

gastrointestinal tract (54.5%), lung and bronchus (30.1%), pancreas (2.3%), ovarian (1.2%), biliary (1.1%), head and neck (0.4%) and the other tissues (9.7%) (14). Generally, carcinoid tumor could display carcinoid syndrome including flushing, diarrhea and abdominal cramps. However, in this case, our patient didn't have obvious carcinoid syndrome. It's reported that an 82-year-old man who had a progressive carcinoid tumor rapidly died after admission (15). Thus, as a neuroendocrine tumor with potentially unfavorable outcome, carcinoid tumor requires more aggressive approach (16).

A carcinoid arised from a mature teratoma in mediastinum is extremely rare. Up to date, there are only 4 such cases described in world literatures (2-5). Of these, carcinoid tumors arised from slowly growing mediastinal teratomas. No residual tumor was reported. To our knowledge, it is the first case about this rare residual tumor at 2-year follow-up. In this case, our patient presented with an anterior mediastinal mass. Due to the anatomic location, we had removed it incompletely. In previous study, it's usually chemoresistant (5). Second surgical procedure is recommended (17). However, radiotherapy is an effective approach as well (18). Thus, postoperative radiotherapy for residual tumor has been performed in this case subsequently. As experienced from our hospital, radiation treatment with 50 Gy is effective to achieve long-term local control. Now this patient is alive 2 years after surgery. In conclusion, we suggest that adjuvant radiotherapy with 50 Gy is an effective approach for residual tumor of mediastinal carcinoid teratoma.

Acknowledgements

Disclosure: The authors declare no conflict of interest.

References

- Dulmet EM, Macchiarini P, Suc B, et al. Germ cell tumors of the mediastinum. A 30-year experience. *Cancer* 1993;72:1894-901.
- Hsu JS, Kang WY, Chou SH, et al. Mature cystic teratoma in the anterior mediastinum containing a carcinoid. *J Thorac Imaging* 2006;21:60-2.
- Lancaster KJ, Liang CY, Myers JC, et al. Goblet cell carcinoid arising in a mature teratoma of the mediastinum. *Am J Surg Pathol* 1997;21:109-13.
- Rudnicka L, Papla B, Malinowski E. Mature cystic teratoma of the mediastinum containing a carcinoid. A case report. *Pol J Pathol* 1998;49:309-12.
- Gupta P, Singh S, Yadava K, et al. Typical carcinoid arising in mature teratoma of anterior mediastinum. *Asian Cardiovasc Thorac Ann* 2012;20:80-2.
- Guney N, Sayilgan T, Derin D, et al. Primary carcinoid tumor arising in a mature cystic teratoma of the ovary: a case report. *Eur J Gynaecol Oncol* 2009;30:223-5.
- Manivel C, Wick MR, Abenzo P, et al. The occurrence of sarcomatous components in primary mediastinal germ cell tumors. *Am J Surg Pathol* 1986;10:711-7.
- Morinaga S, Nomori H, Kobayashi R, et al. Well-differentiated adenocarcinoma arising from mature cystic teratoma of the mediastinum (teratoma with malignant transformation). Report of a surgical case. *Am J Clin Pathol* 1994;101:531-4.
- Arioz DT, Tokyol C, Sahin FK, et al. Squamous cell carcinoma arising in a mature cystic teratoma of the ovary in young patient with elevated carbohydrate antigen 19-9. *Eur J Gynaecol Oncol* 2008;29:282-4.
- Sens MA, Levenson TB, Metcalf JS. A case of metastatic carcinoid arising in an ovarian teratoma. Case report with autopsy findings and review of the literature. *Cancer* 1982;49:2541-6.
- Miliauskas JR. Carcinoid tumor occurring in a mature testicular teratoma. *Pathology* 1991;23:72-4.
- Stringer DA, Sprigg A, Kerrigan D, et al. Malignant carcinoid within a recurrent sacrococcygeal teratoma in childhood. *Can Assoc Radiol J* 1990;41:105-7.
- Yamasaki T, Yagihashi Y, Shirahase T, et al. Primary carcinoid tumor arising in a retroperitoneal mature teratoma in an adult. *Int J Urol* 2004;11:912-5.
- Maggard MA, O'Connell JB, Ko CY. Updated population-based review of carcinoid tumors. *Ann Surg* 2004;240:117-22.
- Okano Y, Inayama M, Hatakeyama N, et al. Autopsy case of rapid progressive atypical carcinoid of the lung discovered with multiple nodular shadows. *J Med Invest* 2008;55:142-6.

16. Squeff FA, Gerace ES, Saad Júnior R, et al. Mediastinal teratoma with malignant degeneration. *J Bras Pneumol* 2008;34:631-4.
17. Petrella F, Leo F, Veronesi G, et al. "Salvage" surgery for primary mediastinal malignancies: is it worthwhile? *J Thorac Oncol* 2008;3:53-8.
18. Schnirer II, Yao JC, Ajani JA. Carcinoid--a comprehensive review. *Acta Oncol* 2003;42:672-92.



Cite this article as: Tu L, Sun L, Zhou Y, Gong Y, Xue J, Gao J, Lu Y, Wang Y. Postoperative radiotherapy for residual tumor of primary mediastinal carcinoid teratoma. *J Thorac Dis* 2013;5(2):E61-E64. doi: 10.3978/j.issn.2072-1439.2012.11.11