



Modified open-thoracotomy-view approach in robotic-assisted thoracoscopic lung resection

Keisei Tachibana[^], Jun Miura[^], Yoshifumi Hirata, Kazuharu Suda, Kohei Hashimoto, Ryota Tanaka, Haruhiko Kondo

Department of Thoracic and Thyroid Surgery, Kyorin University School of Medicine, Tokyo, Japan

Contributions: (I) Conception and design: K Tachibana, J Miura, Y Hirata; (II) Administrative support: R Tanaka, K Hashimoto, H Kondo; (III) Provision of study materials or patients: K Tachibana, K Hashimoto, R Tanaka; (IV) Collection and assembly of data: K Tachibana, Y Hirata, K Suda; (V) Data analysis and interpretation: K Tachibana, J Miura, R Tanaka; (VI) Manuscript writing: All authors; (VII) Final approval of manuscript: All authors.

Correspondence to: Keisei Tachibana, MD, PhD. Department of Thoracic and Thyroid Surgery, Kyorin University School of Medicine, 6-20-2 Shinkawa, Mitaka, Tokyo 181-0004, Japan. Email: k-tachibana@ks.kyorin-u.ac.jp.

Abstract: Robotic-assisted thoracoscopic surgery (RATS) is widely performed in thoracic surgery. The open-thoracotomy-view approach (OTVA) is one approach in RATS lung resection. OTVA is a good surgical approach that provides the same field of view as that with open thoracotomy and allows active participation of the assistant. However, the OTVA has certain limitations compared with other approaches, such as difficulty placing a robotic arm in the lower intercostal space, the assistant port is positioned further from the hilum, and CO₂ insufflation is required. We have made some modifications to the OTVA by placing one of the robotic arms in the lower intercostal space, which enhances the operability for the surgeon without the need for CO₂ insufflation. Additionally, by positioning the assistant port between the robotic arms, the assistant is closer to the hilum, and there is no requirement for a closed port owing to the absence of CO₂ insufflation, resulting in improved performance by the assistant. Therefore, for the assistant to perform well, it is necessary to make modifications to the OTVA to widen the typically narrow space between the robotic arms. We performed lung resection using our modified 4-port 3-arm OTVA method in 20 patients from June 2022 to July 2023. Although we have not used our modified OTVA in a large number of cases, we have not observed critical issues to date. In this report, we introduce our modified OTVA as an option in RATS for lung resection.

Keywords: Robotic-assisted thoracoscopic surgery (RATS); robotic open-thoracotomy-view approach (robotic OTVA); robotic lung resection

Submitted Oct 29, 2023. Accepted for publication Dec 29, 2023. Published online Feb 19, 2024.

doi: 10.21037/jtd-23-1653

View this article at: <https://dx.doi.org/10.21037/jtd-23-1653>

Introduction

Minimally invasive surgeries, such as video-assisted thoracoscopic surgery (VATS) and robotic-assisted thoracoscopic surgery (RATS) have been widely adopted in thoracic surgery. In Japan, approximately 80% of all thoracic surgeries are performed using minimally

invasive techniques (1). Recently, RATS has rapidly gained popularity, and various facilities have implemented different port placements (2-7). A common approach involves placing a port in the lower intercostal space and using four robotic arms to perform a look-up technique (2-4). This method is considered similar to solo surgery, as it minimizes the

[^] ORCID: Keisei Tachibana, 0000-0003-1398-3037; Jun Miura, 0000-0002-8230-1629.

role of the assistant. In 2021, Sakakura *et al.* introduced the robotic open-thoracotomy-view approach (OTVA), which uses vertical port placement and a confronting monitor set-up (8). The authors also reported their method focusing on segmentectomy procedures (9) and also described it focusing on possible emergency rollout procedures (10). This robotic surgical technique provides a view similar to that with open thoracotomy, and uses three robotic arms and one assistant port. The OTVA provides a surgical view that closely resembles that of traditional thoracotomy, resulting in enhanced visualization of the cranial hilum, including the cranial side of the truncus superior pulmonary artery. However, as the surgery is performed with a three-arm robotic system, surgical assistance, such as countertraction by an assistant, is important. This makes the OTVA a good surgical procedure, both technically and educationally, as active participation by the assistant in the operation is necessary. However, despite the advantages of the OTVA, the placement of the assistant caudal to the three robotic arms creates a challenge when adapting to the assistant's role, mainly owing to the increased distance between the assistant and the hilum. Moreover, while using a robotic stapler with long joints from a lower port could improve operability, it is challenging to set up a lower port considering the aforementioned issue. Based on our own experience, this could pose difficulties using the robotic stapler effectively. Additionally, CO₂ insufflation is necessary to create sufficient space within the thoracic cavity, which

requires the placement of a closed port, such as an accessory port (e.g., Alnote Lapsingle[®], AL-LS-51-1318; Alfresa Pharma Corporation, Osaka, Japan). This can cause the assistant to experience stress during tool exchanges throughout the procedure. Furthermore, specialized tools such as the AirSeal[®] system (ConMed Corporation, Utica, NY, USA) are essential for performing CO₂ insufflation, resulting in increased costs. To address these challenges, we have developed a modified OTVA that aims to overcome these issues. We present this article in accordance with the SUPER reporting checklist (available at <https://jtd.amegroups.com/article/view/10.21037/jtd-23-1653/rc>).

Preoperative preparations and requirements

Material and methods

The study was conducted in accordance with the Declaration of Helsinki (as revised in 2013). This study was approved by the Ethics Committee of Kyorin University School of Medicine (No. H26-103). All study participants provided informed consent. We performed our modified OTVA method at the Kyorin University Hospital, which is an advanced treatment hospital from June 2022 to July 2023. We retrospectively reviewed 20 patients who were diagnosed as having lung cancer and lesions that were strongly suspected as lung cancer. During this period, the selection criteria were limited to patients with lung cancer up to stage IIA and without lymph node metastasis based on the eighth tumour-node-metastasis classification system. Postoperative complications were evaluated using the Clavien-Dindo classification. Patient characteristics and surgical outcomes of the 20 patients who underwent modified OTVA were shown in the *Table 1*.

Preoperative preparations

The console surgeon was a board-certified thoracic surgeon who had completed certificate training from Intuitive Medical Inc. (Sunnyvale, CA, USA) on the da Vinci System as a console surgeon, and the assistant was a surgeon who held assistant certification from the same organization.

Patients were positioned in either the conventional right or left lateral decubitus position and underwent general anesthesia with double-lumen intubation. Before the start of the surgery, the anesthesiologist administered a paravertebral block by percutaneously injecting 0.5% levobupivacaine hydrochloride for intraoperative analgesia.

Highlight box

Surgical highlights

- The modified open-thoracotomy-view approach (OTVA) is a favorable approach both technically and educationally for performing robotic-assisted lung resection.

What is conventional and what is novel/modified?

- With the conventional OTVA, the assistant port is traditionally positioned caudal to the three robotic arms, and CO₂ insufflation is necessary.
- By placing the assistant port between the robotic arms, the port is closer to the hilum, resulting in improved performance by the assistant. Furthermore, by placing one of the robotic arms in the lower intercostal space, operability is not compromised even without CO₂ insufflation. The operability of the robotic stapler is also enhanced.

What is the implication, and what should change now?

- The port becomes more accessible for the assistant to operate, leading to improved maneuverability for the surgeon as well.

Table 1 Characteristics and surgical outcomes of the 20 patients who underwent modified OTVA

Parameter	Value
Age, years, median [range]	71 [54–83]
Sex (male/female)	12/8
Preoperative diagnosis	
Lung cancer (c-stage 0/IA1/IA2/IA3/IB/IIA)	20 (0/9/9/0/1/1)
Surgical procedure (lobectomy/segmentectomy)	15/5
Right upper/middle/lower lobectomy	6/1/4
Right S6/S8/basal segmentectomy	1/2/1
Left upper/lower lobectomy	1/3
Left upper division segmentectomy	1
Node dissection	
ND0/ND1/ND2a-1/ND2a-2	1/7/10/2
Operating time, min, median [range]	
Total time	213 [132–267]
Console time	149 [88–206]
Blood loss volume, mL, median [range]	10 [0–84]
Conversion to open surgery	0
Morbidity (Clavien-Dindo classification)	2
Atelectasis (Grade 2)	1
Arrhythmia (Grade 2)	1
Postoperative course, days, median [range]	
Chest tube removal	1 [1–5]
Postoperative hospital stay	6 [4–12]
Histology	
Primary lung cancer (adenocarcinoma)	19
pT status (Tis/T1mi/T1a/T1b/T1c/T2a/T2b/T3/T4)	0/3/4/9/1/1/0/0/1
pN status (N0/N1/N2)	19/0/0
p-stage (0/IA1/IA2/IA3/IB/IIA/IIB/IIIA)	0/7/9/1/1/0/0/1
Benign lesion	1

OTVA, open-thoracotomy-view approach, ND, node dissection.

Step-by-step description

System and monitor setting

The system and monitor settings are basically the same as those reported by Sakakura *et al.* (8,9). We perform RATS using the da Vinci Xi[®] Surgical System (Intuitive Surgical

Inc., Sunnyvale, CA, USA). Regardless of the operative side, the patient cart is rolled in from the patient's left cranial side. Among the four robotic arms, arm 1 remains unused and is positioned towards the patient's cranial side. Arm 2 is placed on the patient's cranial side and is intended for operation by the console surgeon's left hand. Arm 3 accommodates the 30° robotic camera, while arm 4 is situated on the patient's caudal side, to be operated by the console surgeon's right hand.

The first assistant stands on the patient's left side and retracts the lungs and other intrathoracic structures and suctions blood, while the second assistant stands on the patient's right side and is primarily responsible for the docking procedure and instrument exchange.

Two monitors are positioned facing each other on either side of the patient. The left-side monitor, used by the second assistant, displays the same image as that on the surgeon's console. In contrast, the right-side monitor, used by the first assistant, displays an inverted image of the surgeon's console view. These arrangements allow the console surgeon and the two assistants to naturally obtain the same views, as in open thoracotomy.

Port placement

For right-sided surgeries, we place three robotic ports and one assistant port on the posterior axillary line. For surgeries involving the right upper lobe, we place two 8-mm robotic ports (robotic arms 2 and 3) and one 12-mm robotic port (robotic arm 4) at the third, fifth, and eighth intercostal spaces along the posterior axillary line, respectively. Additionally, we place an assistant port (LAP PROTECTOR FF0504 Mini-mini[®]; Hakko Corporation, Nagano, Japan) on the anterior axillary line at the fifth intercostal space (*Figure 1A*). For right middle or lower lobe resections, we lower the ports by one intercostal space. For surgeries involving the left upper lobe, we place three robotic ports along the anterior axillary line at the third, fifth, and eighth intercostal spaces, respectively, and we place an assistant port on the posterior axillary line at the seventh intercostal space (*Figure 1B*). For left lower lobe resections, we lower the ports by one intercostal space. The first assistant is able to perform assistance maneuvers in the upper intercostal spaces by being positioned between robotic arms 3 and 4. Additionally, moving arm 4 downwards does not affect the first assistant's ability to operate. Robotic staplers with long joints can be inserted through the lower ports for improved maneuverability and

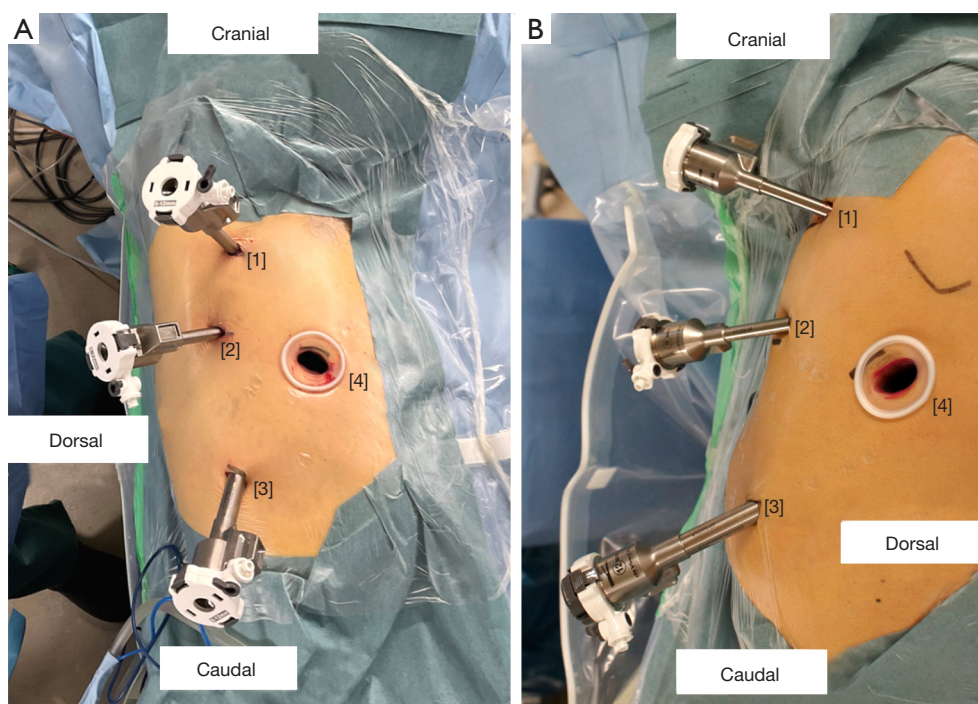


Figure 1 Port placements for right-sided (A) and left-sided (B) surgeries. These figures show the port placements for upper lobe resections. For right middle or lower lobe resections, we lower the ports by one intercostal space. A [1]: arm 2, 3rd intercostal space, 8-mm robotic port; [2]: arm 3, 5th intercostal space, 8-mm robotic port; [3]: arm 4, 8th intercostal space, 12-mm robotic port; [4]: assistant port, 5th intercostal space, 30-mm open port. B [1]: arm 2, 3rd intercostal space, 8-mm robotic port; [2]: arm 3, 5th intercostal space, 8-mm robotic port; [3]: arm 4, 8th intercostal space, 12-mm robotic port; [4]: assistant port, 7th intercostal space, 30-mm open port.

the ability to staple at various angles. The assistant port is the open type, and we use a protector that allows for easy insertion and removal of multiple instruments, reducing the first assistant's operational stress. Moreover, positioning the assistant port in the upper intercostal spaces allows for rapid conversion to open thoracotomy and provides proximity to the hilum. As the first assistant is positioned between robotic arms 3 and 4, it is important to ensure enough space in this area; lowering the patient clearance of the robotic arms can help create more space (Figure 2). In cases of emergencies such as bleeding, it is possible to conversion to open thoracotomy by connecting the assistant port and the robotic port.

Surgical view

Compared with the look-up technique from the lower intercostal spaces, the OTVA provides a superior cranial view owing to the high position of the camera port. For example, in right upper lobectomy, the cranial view of the

upper pulmonary vein and the truncus superior pulmonary artery is good, enabling safe surgery (Figure 3A). The anterior view of the pulmonary hilum during left upper lobectomy also provides satisfactory visualization (Figure 3B). The posterior view is also satisfactory when using a 30° robotic camera and switching between the up and down views (Figure 3C). When stapling between the right upper and middle lobes, a smooth dissection is achievable using a robotic stapler through the port in the lower intercostal space (Figure 3D). The Video shows an external perspective of the surgical scene as well as an intrathoracic view of right upper lobectomy performed using RATS by the modified OTVA method (Video 1).

Postoperative considerations and tasks

We have performed RATS using the modified OTVA method in 20 cases, with no cases requiring conversion to open thoracotomy. Surgical and console times, and blood loss, were not excessive, and the procedure was performed

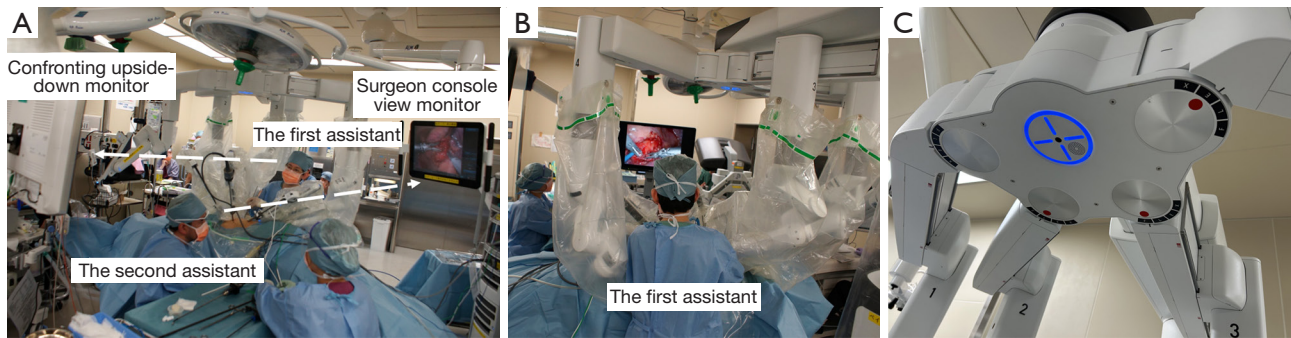


Figure 2 Confronting monitor set-up and the position of robotic arms. The left-side monitor, used by the second assistant, displays the same image as that on the surgeon's console. In contrast, the right-side monitor, used by the first assistant, displays an inverted image of that on the surgeon's console view. Dashed arrow: assistant's line of sight (A). The patient clearance function is crucial to ensure sufficient space between the robotic arms for optimal first assistant performance (B). On the basis of our experience, we recommend positioning robotic arm 2 on the patient cart as "L", arm 3 as "F", and arm 4 as "E" (C).

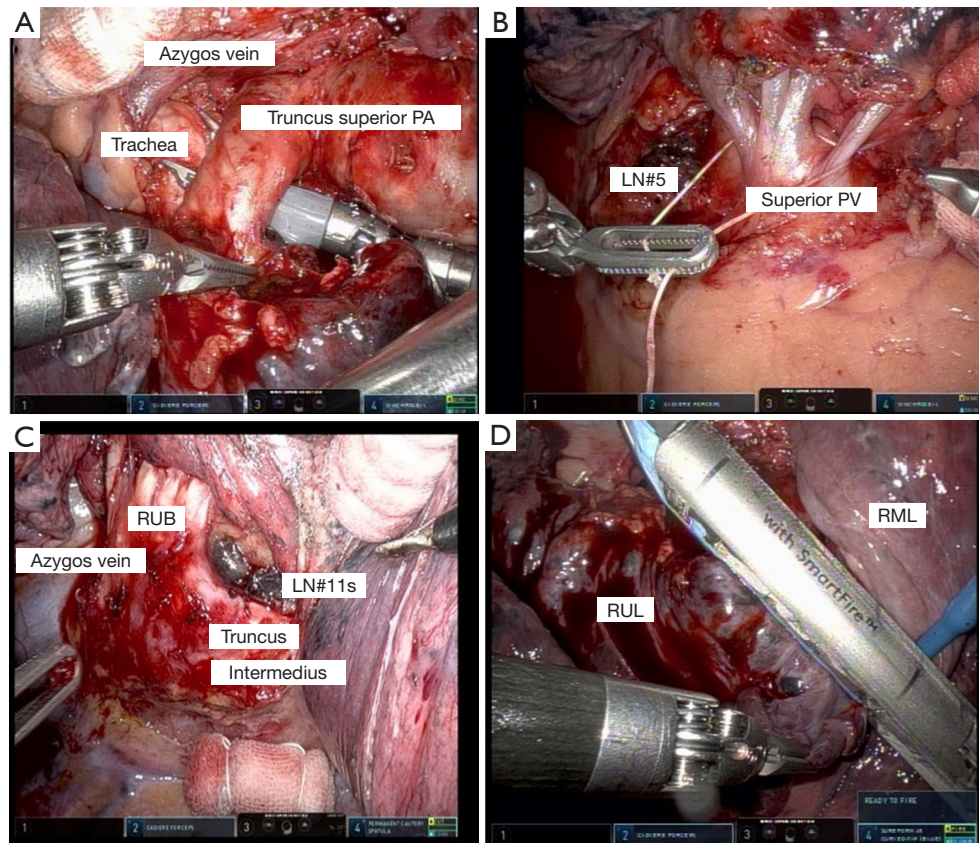
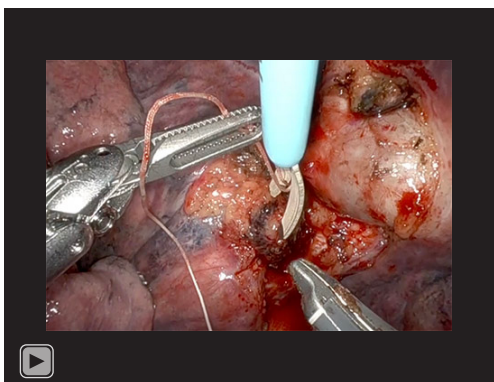


Figure 3 Surgical view. The left side of all images are of the cranial side of the thorax. (A) Right hilar view around the truncus superior pulmonary artery during right upper lobectomy. (B) Left hilar view around the superior pulmonary vein during left upper lobectomy. (C) Dorsal view of the right upper bronchus and the 11s lymph nodes. (D) Dissection between the upper and middle lobes using a robotic stapler. PA, pulmonary artery; PV, pulmonary vein; LN, lymph node; RUB, right upper bronchus; RUL, right upper lobe; RML, right middle lobe.



Video 1 Right upper lobectomy by the modified robotic open-thoracotomy-view approach. In the view of the surgical field from an external perspective, the second assistant is exchanging instruments, while the first assistant is applying countertraction within the thoracic cavity. The first assistant is positioned between robotic arms 3 and 4, ensuring adequate space for operation. In the intrathoracic view, right upper lobectomy is performed by modified robotic open-thoracotomy-view approach. All robotic stapler operations are performed smoothly without stress or complications. The final view is that after right upper lobectomy and lymph node dissection.

successfully in each case (*Table 1*). Postoperative monitoring was performed in accordance with standard post-pulmonary resection management, including continuous monitoring of electrocardiography, oxygen saturation, arterial blood pressure monitoring, and chest tube drainage under continuous suction at -10 cmH₂O until the following day. Chest X-ray images were obtained daily for the first 3 days postoperatively to confirm satisfactory lung expansion and the absence of air leaks, bleeding, or chylothorax, as well as to ensure that daily drainage from the chest tube was <200 mL. Once these criteria were met, the chest tube was removed. Blood tests were performed on the first and third postoperative days. Patients were followed-up in the outpatient clinic approximately 3 weeks after discharge and 3–6-months thereafter.

Tips and pearls

We offer the following tips and pearls when performing the modified OTVA method to ensure that both the console surgeon and the first assistant can focus on the surgery without experiencing stress. For the console surgeon, it is especially important to position robotic arm 4 so that it

can be operated by the console surgeon's right hand in the subcostal area to improve operability. For the first assistant, it is crucial to lower the robotic arms' patient clearance and widen the distance between the arms to ensure an adequate workspace. Main different points from the method of Sakakura *et al.* (8,9) is that the first assistant is placed between arms 3 and 4 and that CO₂ insufflation is not used.

Discussion

The OTVA is a good robotic surgical technique that can be performed with the same view as that with open thoracotomy. Furthermore, our modified OTVA results in less stress for the first assistant and is easier to perform compared with the traditional OTVA.

Currently, VATS and RATS are performed worldwide, but the methods vary depending on the facility and various innovations. In our institution, we have been performing three-port VATS, and the technique has been standardized. RATS has advantages over conventional thoracoscopic surgery, such as a magnified view and three-dimensional visualization through the robotic camera, and the multi-jointed functions of the instruments. When we introduced RATS, we initially performed the conventional look-up method from the lower intercostal space, which has been reported by various authors including Ninan and Dylewski (2), and Cerfolio *et al.* (3,4). These are traditional methods and familiar to many surgeons. However, we found that using this approach required five ports, namely four ports for the robotic arms and an assistant port, which was not superior to minimally invasive VATS. Additionally, we determined that the view from the cranial side was poor when viewed from the lower intercostal port. Funai *et al.* (7). reported a four-port RATS technique, which is also considered a viable approach. However, in their method, the robotic camera and assistant port are inserted through the same incision, which may limit the operability for the assistant. We decided to introduce the OTVA developed by Sakakura *et al.* (8), as we believed that this approach would allow us to leverage the advantages of RATS while reducing the number of ports, and also because we could apply our experience with VATS. We were able to evolve this OTVA method further to match our facility's needs.

In RATS for lung resection, the use of CO₂ insufflation is more common. The advantage of CO₂ insufflation is the expansion of the working space within the thoracic cavity. Basically, compared to the conventional look-up method,

the robotic ports and target structures can be close in this horizontal thoracotomy-view type approach, the surgeons may occasionally feel it difficult to view the lungs from a full distance, particularly when cutting the lung parenchyma. Thus, conventional OTVA requires CO₂ insufflation, which necessitates the placement of closed-type ports. However, the necessity of opting for a closed-type port may lead to increased costs and potential reduction in the activity of the assistant due to the added complexity of tool insertion. In our modified OTVA approach, we do not use CO₂ insufflation, leading to a decrease in the working space within the thoracic cavity. However, the increased activity of the assistant provides a good operative field, compensating for the reduced working space. Certainly, when the working space is insufficient, there may be an option in some cases, such as smaller body size patients to use CO₂ insufflation. Fortunately, we performed the modified OTVA method on 20 cases without CO₂ insufflation, and there were no particular difficulties reported during the procedures. Furthermore, positioning arm 4 in the lower intercostal space helps improve operability even in small surgical spaces. Additionally, it is safer and easier for the first assistant to operate at a position as close to the hilum as possible. In conventional OTVA, it is necessary to place the assistant port in the lower intercostal space owing to the placement of the robotic arms. We believed that placing the first assistant between robotic arms 3 and 4 could solve this problem. This also allows robotic arm 4 to be positioned lower, which is advantageous when using robotic staplers with long joints. In our modified OTVA, it is crucial to ensure sufficient space between robotic arms 3 and 4 for the first assistant to operate without stress. Therefore, the patient cart should roll in from the slightly cranial dorsal side of the patient. Lowering the robotic arms' patient clearance to increase the distance between robotic arms 3 and 4 helps avoid obstructing the first assistant's view.

The modified OTVA has several limitations. First, this is a developing technique and is currently primarily performed in a single institution. Second, the procedure requires a confronting upside-down monitor and two surgical assistants. Third, currently, the implementation of the modified OTVA is challenging with surgical systems other than da Vinci Xi[®] Surgical System (Intuitive Surgical Inc.), limiting its widespread adoption. Despite these limitations, we performed RATS using our modified OTVA in 20 patients without conversion to open thoracotomy in any case.

Conclusions

Our modified OTVA leverages the advantages of RATS while simultaneously reducing the number of ports compared with conventional RATS. This approach not only capitalizes on the benefits provided by robotic-assisted techniques but also facilitates active participation of the first assistant during the surgical procedure. As a result, the modified OTVA method is an emerging technically and educationally superior approach. Our modified OTVA method can be considered an optional approach in RATS lung resection. We were able to perform the surgery without critical issues regarding surgical time, console time, or blood loss. We plan to accumulate more cases to further demonstrate the effectiveness of this method.

Acknowledgments

We thank Jane Charbonneau, DVM, from Edanz (<https://jp.edanz.com/ac>) for editing a draft of this manuscript.

Funding: None.

Footnote

Reporting Checklist: The authors have completed the SUPER reporting checklist. Available at <https://jtd.amegroups.com/article/view/10.21037/jtd-23-1653/rc>

Peer Review File: Available at <https://jtd.amegroups.com/article/view/10.21037/jtd-23-1653/prf>

Conflicts of Interest: All authors have completed the ICMJE uniform disclosure form (available at <https://jtd.amegroups.com/article/view/10.21037/jtd-23-1653/coif>). The authors have no conflicts of interest to declare.

Ethical Statement: The authors are accountable for all aspects of the work in ensuring that questions related to the accuracy or integrity of any part of the work are appropriately investigated and resolved. This study was performed in accordance with the Declaration of Helsinki (as revised in 2013) and was approved by the Ethics Committee of Kyorin University School of Medicine (No. H26-103). All study participants provided informed consent.

Open Access Statement: This is an Open Access article

distributed in accordance with the Creative Commons Attribution-NonCommercial-NoDerivs 4.0 International License (CC BY-NC-ND 4.0), which permits the non-commercial replication and distribution of the article with the strict proviso that no changes or edits are made and the original work is properly cited (including links to both the formal publication through the relevant DOI and the license). See: <https://creativecommons.org/licenses/by-nc-nd/4.0/>.

References

1. Committee for Scientific Affairs, The Japanese Association for Thoracic Surgery, Shimizu H, et al. Thoracic and cardiovascular surgeries in Japan during 2018 : Annual report by the Japanese Association for Thoracic Surgery. *Gen Thorac Cardiovasc Surg* 2021;69:179-212.
2. Ninan M, Dylewski MR. Total port-access robot-assisted pulmonary lobectomy without utility thoracotomy. *Eur J Cardiothorac Surg* 2010;38:231-2.
3. Cerfolio RJ, Bryant AS, Skylizard L, et al. Initial consecutive experience of completely portal robotic pulmonary resection with 4 arms. *J Thorac Cardiovasc Surg* 2011;142:740-6.
4. Cerfolio RJ, Ghanim AF, Dylewski M, et al. The long-term survival of robotic lobectomy for non-small cell lung cancer: A multi-institutional study. *J Thorac Cardiovasc Surg* 2018;155:778-86.
5. Yamazaki K, Toyokawa G, Shoji F, et al. A novel technique for robotic-assisted lobectomy for lung cancer: the anterior approach. *Interact Cardiovasc Thorac Surg* 2020;30:328.
6. Haruki T, Kubouchi Y, Takagi Y, et al. Comparison of medium-term survival outcomes between robot-assisted thoracoscopic surgery and video-assisted thoracoscopic surgery in treating primary lung cancer. *Gen Thorac Cardiovasc Surg* 2020;68:984-92.
7. Funai K, Kawase A, Takanashi Y, et al. Improved complete portal 4-port robotic lobectomy for lung cancer: Hamamatsu Method KAI. *J Thorac Dis* 2023;15:1482-5.
8. Sakakura N, Nakada T, Shirai S, et al. Robotic open-thoracotomy-view approach using vertical port placement and confronting monitor setting. *Interact Cardiovasc Thorac Surg* 2021;33:60-7.
9. Sakakura N, Nakada T, Takahashi Y, et al. Three-Arm Robotic Lung Resection via the Open-Thoracotomy-View Approach Using Vertical Port Placement and Confronting Monitor Setting: Focusing on Segmentectomy. *J Pers Med* 2022;12:1771.
10. Sakakura N, Nakada T, Shirai S, et al. Emergency rollout and conversion procedures during the three-arm robotic open-thoracotomy-view approach. *Interact Cardiovasc Thorac Surg* 2022;34:1045-51.

Cite this article as: Tachibana K, Miura J, Hirata Y, Suda K, Hashimoto K, Tanaka R, Kondo H. Modified open-thoracotomy-view approach in robotic-assisted thoracoscopic lung resection. *J Thorac Dis* 2024;16(2):1488-1495. doi: 10.21037/jtd-23-1653