

Video-Assisted Thoracic Surgery Lobectomy: Results in Lung Cancer

Jesús Loscertales, Florencio Quero Valenzuela, Miguel Congregado, Rafael Jiménez Merchán, Gregorio Gallardo Varela, Ana Trivino Ramírez, Sergio B. Moreno Merino, Fernando Cózar Bernal.

Department of General and Thoracic Surgery, University Hospital Virgen Macarena, Seville, Spain.

ABSTRACT **Background** The application of video-assisted thoracic surgery (VATS) in major pulmonary resections is still far from routine in most hospitals, even though the safety and technical feasibility of the procedure have by now been amply demonstrated. This paper reports on the surgical technique used by the authors for VATS lobectomy, on their experience of the procedure and on the results obtained.

Methods A retrospective study was performed of all patients undergoing VATS lobectomy at the our Thoracic Surgery Department between 1993 and 2009. The clinical records of all patients were reviewed, and the following variables were noted for purposes of analysis: patient age and sex; clinical diagnosis; staging; date of surgery; type of surgery; conversion to conventional surgery and grounds for conversion; duration of surgery; intraoperative, postoperative and long-term complications; postoperative stay, final diagnosis and staging; and death rates.

Results A total of 349 VATS lobectomies were performed over the study period (292 men, 57 women; mean age 59.7). The aetiology was non-small-cell lung carcinoma (NSCLC) in 313 patients and benign processes in 26; four patients had carcinoid tumours, and a further six required lobectomy due to metastases. The overall conversion rate was 9.4%. Mean duration of lobectomy was 148 minutes, and median duration 92 minutes. Mean postoperative stay was 3.9 days. The morbidity rate was 12.89%, mostly involving minor complications. Perioperative mortality was 1.43%. There were no intraoperative deaths. The overall five-year survival rate for patients with NSCLC was 80.1%.

Conclusions VATS lobectomy is a safe and technically-viable procedure that meets oncological criteria for lung-cancer surgery. Major pulmonary resection using VATS should be considered the procedure of choice for a number of benign processes and for early-stage bronchogenic carcinoma (T1-T2 N0 M0).

KeyWords: Video-assisted thoracic surgery; VATS; lung cancer; thoracoscopy; minimally invasive surgical procedures; lobectomy

J Thorac Dis 2010; 2: 29–35.

The first thoracoscopy was performed in 1910, when Hans Christian Jacobaeus inserted a rigid cystoscope into the pleural cavity (1); since then, the technique has undergone far-reaching changes that could not have been foreseen by the earliest practitioners. Major advances both in endoscopic material and in visualisation techniques, together with the use of single-lung ventilation, enabled Landreneau et al to lay the technical and strategic foundations for modern video-assisted thoracic surgery (VATS) in 1992 (2).

Over the last fifteen years, major pulmonary section using VATS has been shown to be both safe and technically-feasible, and to offer a number of advantages over conventional surgery (3,4,5,6,7). Nevertheless, its adoption as a standard technique is

proving slow; VATS is not routinely performed in most hospitals, and tends to be used mainly in highly-specialised centres.

Recent reviews of the outcomes obtained in large patient series highlight the importance of training surgeons in this complex technique (5,6). Our Department has been performing major pulmonary resections by VATS since 1993, making it one of the pioneering groups in Europe.

The Department also runs a twice-yearly training programme in advanced thoracoscopic surgery at the MINIMALLY INVASIVE SURGERY CENTRE JESUS USON in Cáceres (Spain) www.ccmijesususon.com.

Available data suggest that the proportion of lobectomies performed using VATS in Spain is still very small, even below the European average, although widespread interest has been expressed in the adoption of this technique in the country's leading hospitals.

The present paper reports on the VATS lobectomy technique in use at this institution, on the surgeons' experience with the technique and on the outcomes obtained over a 16-year period.

Material and methods

This descriptive, retrospective review included all patients un-

Supporting Foundations: None

Address reprint requests to: J. Loscertales, MD, Professor. Hospital Universitario Virgen Macarena, Avda. Dr. Fedriani 1, Sevilla 41071, Spain. Tel: 34-955008085; Fax: 34-954372734. E-mail: jloscert@us.es

Submitted Feb 5, 2010. Accepted for publication Feb 25, 2010.

Available at www.jthoracdis.com

dergoing VATS lobectomy at the Thoracic Surgery Department, between 1993 and 2009. The clinical records of all patients - drawn from the Hospital archive - were entered into the Unit database (Microsoft ® Office Access) for statistical analysis using the software package SPSS 13.0 for Windows.

The following variables were analysed: patient age and sex; clinical diagnosis; clinical staging; pathological staging; date of surgery; conversion to conventional surgery and grounds for conversion; duration of surgery; intraoperative and perioperative morbidity and mortality; and actuarial 5-year survival rates.

Inclusion criteria

At this Department, VATS lobectomy has become the procedure of choice for the treatment of early-stage non-small cell bronchogenic carcinoma (NSCBC) and of a number of benign processes. Since March 1993, several indications have been modified and expanded, and - more importantly - the number of contraindications has been reduced. The current indications for VATS lobectomy are:

1. Tumour size < 5 cm, although, like other authors, our team has successfully resected tumours greater than 6 cm (10, 17).

2. Peripheral location, i.e. over 1 cm from the fissure and over 3 cm from the lobar carina. This is a relative criterion, since lobectomies can safely be performed less than 1 cm from the fissure; small series of successful sleeve VATS lobectomies have been reported (13).

3. Stage I, N0, although this is not a totally exclusive criterion; metastatic intrapulmonary or mediastinal lymph nodes detected intraoperatively do not necessarily contraindicate resection, although they may make it difficult.

4. Open fissures, although for certain lobectomies (e.g. right upper), this is not absolutely essential.

Exclusion criteria or contraindications for VATS lobectomy have varied over the years, becoming less restrictive as the Unit's experience has grown. They currently include chest wall invasion, tumour infiltration beyond the fissure, invasion of the pericardium or diaphragm, and neoadjuvant radiotherapy or chemotherapy; the latter is also relative, since VATS lobectomy has been shown to be safe and technically viable in patients receiving induction chemotherapy (21,22), although it might hinder dissection.

Surgical technique:

The patient is placed in the lateral decubitus position, and selective intubation is used in all cases. Three entry-port incisions are made to introduce 12 mm trocars: one in the seventh or eighth intercostal space (depending on patient thorax configuration) in the midaxillary line, for the camera; a second just below the scapular vertex in the sixth or seventh intercostal space; and the third in the third or fourth intercostal space in the anterior axillary line. Having confirmed the viability of the technique, an anterior minithoracotomy

approximately 4-5 cm long is placed over the fifth intercostal space, without rib spreading, for the insertion of surgical instruments and dissection of vessels and bronchi. The surgeon stands facing the patient, with the principal nurse beside him. Two assistants are placed behind the patient; the more caudally-located of the two operates the camera (Fig.1).

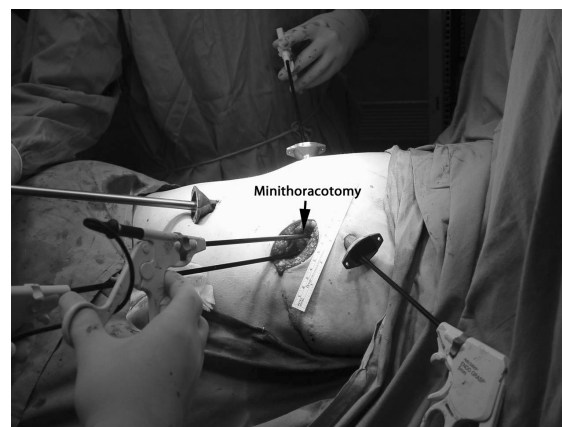


Fig.1 The incisions for our approach to video-assisted thoracic surgical lobectomy.

Exploratory videothoracoscopy is performed to rule out any unforeseen causes of inoperability (e.g. pleural carcinomatosis with no pleural effusion) (10,18,34), and to check tumor size and the absence of fissure invasion. The presence of pleural adhesions or small hilar lymph-node swellings is not considered a contraindication for VATS resection.

Anatomical pulmonary resection using VATS entails the individual dissection, stapling and sectioning of the pulmonary vein, pulmonary arteries and bronchi. The superior pulmonary veins are dissected and sectioned prior to artery dissection; this is not essential in the case of the inferior pulmonary veins. Systematic dissection of mediastinal lymph nodes is routinely performed, as in conventional open surgery; the number of lymph nodes removed is similar in our experience to that of conventional surgery (Fig. 2,3,4).

Results

A total of 349 VATS lobectomies were performed between March 1993 and December 2009. The ratio of male to female patients was 6:1 (292:57). Mean age was 59.7 (range 12-84, mean 63; median 61). A total of 313 cases were diagnosed as non-small cell bronchogenic carcinoma (NSCBC); clinical and pathological stages are shown in Table 1. Twenty-six patients had benign processes (e.g. pulmonary sequestration, cystic adenomatoid malformation, bronchiectasis), 4 patients had carcinoid tumors and 6 patients required lobectomy due to metastases that ruled out wedge resection. The number of patients undergoing each type of lobectomy is shown in Table 2; right upper lobectomy was by far the most common type.

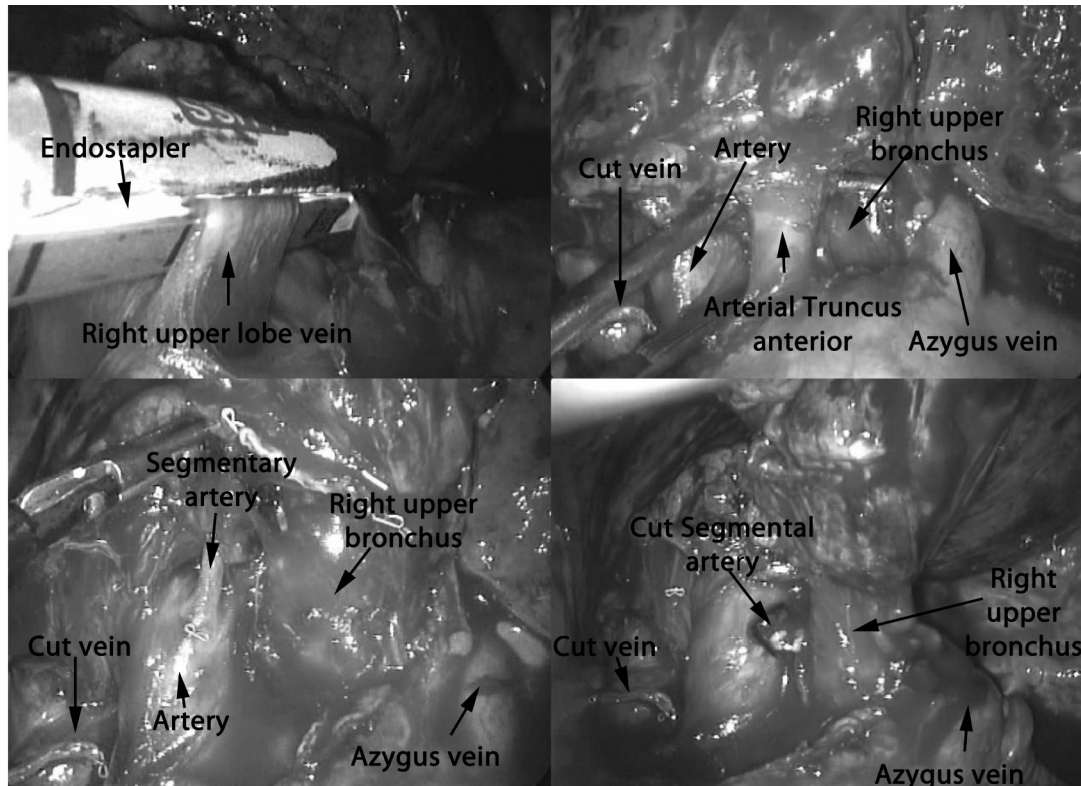


Fig.2 Dissection and stapling of upper lobe pulmonary vein and anterior arterial trunk in the right upper lobectomy

During this period, 22 VATS pneumonectomies were also performed; these are not included, in order to ensure a more uniform sample. There are very few indications for VATS pneumonectomy, and the operation itself - more than the VATS technique - would increase morbidity/mortality, as in open surgery.

Conversion to conventional surgery was more frequent in the early, learning years. The overall conversion rate was 9.4% (n = 33), due to heavy bleeding in 13 cases - always stopped prior to conversion - and to technical difficulties (e.g. extensive and/or very firm adhesions, calcified lymph nodes) in 19 cases. One further patient was converted due to invasion of the pulmonary artery (confirmed after vein sectioning). Mean duration of lobectomy was 148 minutes, but the median duration was 92 minutes, since the procedure was slower at first than in later years.

Mean postoperative stay was 3.9 days. The morbidity rate was 12.8 %, mostly involving minor complications (the most common being air leak lasting longer than four days), as shown in Table 3. Perioperative mortality (i.e. up to 30 days post-surgery) was 1.43% (2 cases of sepsis and 1 case each of acute myocardial infarction, pneumonia and cardiorespiratory failure). There were no intraoperative deaths.

The actuarial 5-year survival rate for patients with NSCBC was 80.1%. During follow-up, three patients displayed mediastinal recurrence (despite the removal of mediastinal lymph glands from all patients), one developed cerebral and costal metastases three months post-surgery, two developed metachronic tumours 23 and 48 months postsurgery, respectively; three patients displayed

same-lung recurrence. There were seven cases of brain metastasis and seven of multiple metastases.

Discussion

The American College of Chest Physicians, in its evidence-based clinical practice guidelines, suggests that "In patients with stage I NSCLC who are considered appropriate candidates for thoroscopic anatomic lung resection (lobectomy or segmentectomy), the use of video-assisted thoracic surgery by surgeons experienced in these techniques is an acceptable alternative to open thoracotomy" (13). Yet at present few centres consider this to be the procedure of choice for the treatment of early-stage lung cancer.

Over the last few years, a large number of case reviews have been published strongly suggesting that patients undergoing VATS lobectomy experience less postoperative pain, reduced chest tube time, fewer perioperative complications and shorter hospital stays than those undergoing conventional surgery (3,4,6,7,10,17,18,19,30,32,44,46,48,50,51,52,53). Other reported advantages over open surgery include improved quality of life, particularly in the first year (46), and reduced immunological aggression, evident in lower IL-6 and PCR levels compared to open surgery (15,18,44). Other authors also report fewer delayed or reduced doses of chemotherapy in patients receiving adjuvant chemotherapy (21).

VATS lobectomy should therefore be the therapeutic approach of choice in patients with early-stage NSCLC.

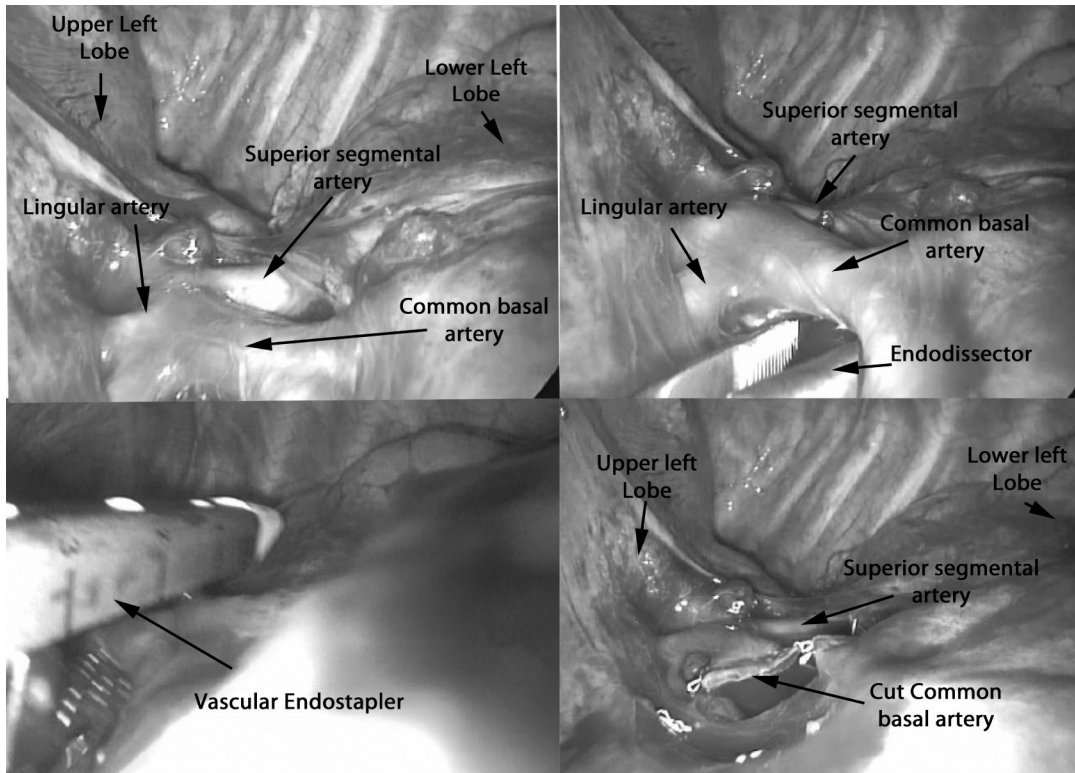


Fig.3 Arterial dissection for stapling the vessel in the left lower lobectomy.

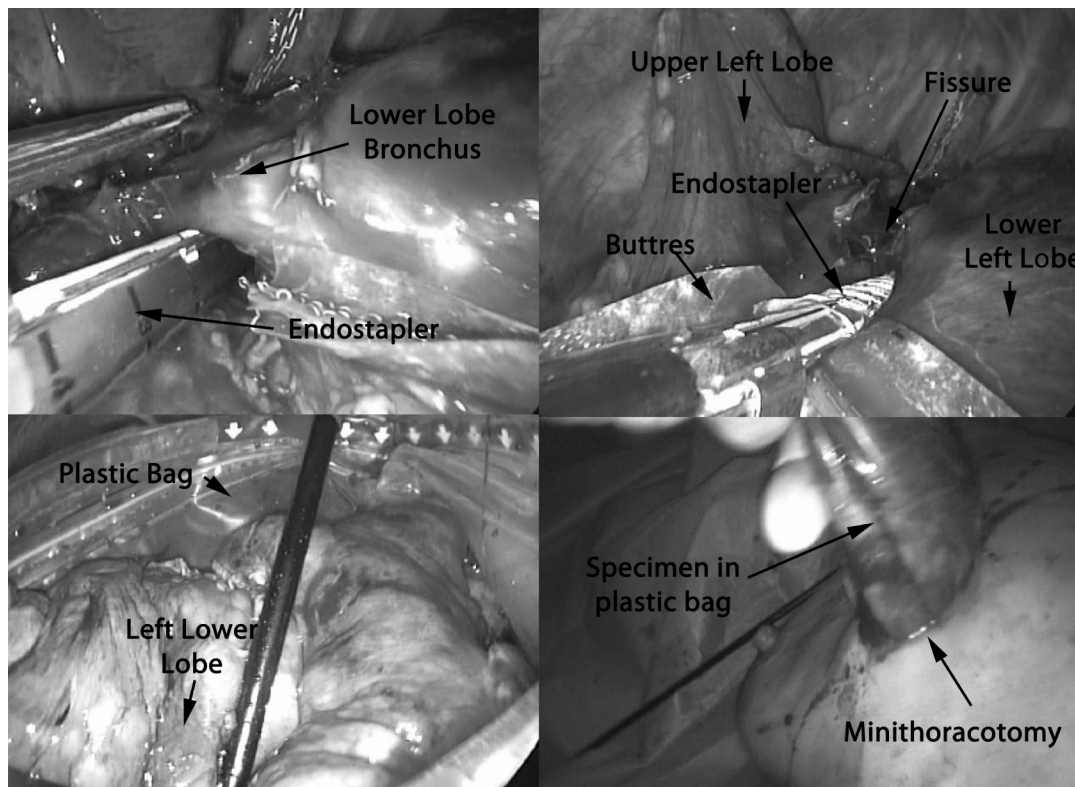


Fig.4 The endostapler across a lower lobe bronchus and completion of the remaining fissure and stapling. The lobe going into the bag for removal.

In this series, there were no intraoperative deaths, and perioperative mortality in the 349 patients undergoing major pulmonary resection using VATS was very low (1.43%), a finding also reported for other large series (3, 4, 5, 7, 17).

Although the learning curve has to an extent been rightly

blamed for increased morbidity and mortality in this type of surgery (7), this should no longer happen, since the technique is becoming increasingly standardized and detailed, and can be taught and practiced at specialist training centers until thorough mastery is achieved. There is no single standard technique for VATS lobecto-

Table 1 Preoperative and pathological stages of lung cancers resected using video-assisted thoracic surgery

Stages	Clinical	Pathologic
IA	44.2%	37.7%
IB	52.6%	54.2%
IIA	0.92%	2.5%
IIB	2.3%	5.6%

Table 2 Major lung resections performed using VATS (1993-2009)

Right (n=219)	Left (n=130)
Right upper lobectomy: 116	Left upper lobectomy: 70
Medial lobectomy: 21	Left lower lobectomy: 60
Right lower lobectomy: 54	
Upper bilobectomy: 12	
Lower bilobectomy: 16	

VATS: Videoassisted Thoracic Surgery

Table 3 Morbidity after video-assisted major lung resections

Complication	No
Prolonged air leakage	12
Atelectasis	8
Apical air space	6
Pneumonia	3
Hemothorax	3
Atrial fibrillation	3
Cardiorespiratory failure	4
Myocardial infarction	2
Cerebrovascular accident	2
Wound infection	1
Bronchial fistula	1
TOTAL	45 (12.8%)

my, but variations between schools tend to be very minor. The greatest differences relate to the number and placement of trocars and the minithoracotomy, the position of the surgeon behind or facing the patient, and the use of a 0° versus 30° optic (49).

Most surgeons perform an anatomical dissection of vascular and bronchial structures, respecting the surgical and oncological principles of conventional thoracotomy.

Although Lewis and Caccavale reported excellent results in 1998 using simultaneous stapling with no individual dissection, the present authors feel that this technique should only be used when technically required (32). At this department, the technique has only been used once, to perform a left lower lobectomy in a high-risk tetraplegic patient with a T1N0M0 bronchogenic carcinoma, displaying a totally open fissure, but with the vein dissected isolated. The rate of conversion to conventional surgery was 9.4%; the rate was naturally higher in the early, learning years. Similar results are

reported by other authors, including Shaw et al (47). The mean duration of surgery is another variable which has decreased as surgeons become more familiar with VATS resection; median surgery time is currently 92 minutes, a figure rather lower than that noted by other authors (30,40).

Survival rates for VATS patients appear to be similar to, or better than, those reported for conventional surgery. Sugi et al reported a 5-year survival rate of 90% for VATS lobectomy, compared with 85% for conventional lobectomy (39). Nevertheless, these results must be viewed with a degree of caution, due to a possible implicit bias at patient selection. The 5-year survival rate for the present series was 80.1% for patients with N NSCLC; this figure is slightly higher than the 77% reported by McKenna et al and the 78% observed by Onaitis et al (7,45).

Despite the lack of evidence based on large-scale randomized studies comparing videothoroscopic procedures with conventional surgery the authors firmly believe that if VATS surgery is properly performed, with resection of mediastinal lymph nodes (50,51,52,41), and meets oncological criteria for lung cancer surgery, long-term survival should not be affected by the choice of surgical approach. Watanabe et al reported that the number of lymph nodes removed following VATS lobectomy was similar to that of conventional surgery (36).

To conclude, VATS lobectomy should be the treatment of choice for early-stage NSCLC (T1-T2N0-M0), and also for certain benign pathologies, although further prospective, randomized studies are required to confirm the evidence provided by the large patient series published to date.

References

- Jacobaeus HC. Ueber die Möglichkeit die Zystoskopie bei Untersuchung seroser Hohlräume anzuwenden. *Munch Med Wochenschr* 1910;57:2090-2.
- Landreneau RJ, Mack MJ, Hazelrigg SR, Dowling RD, Acuff TE, Magee MJ, et al. Video-assisted thoracic surgery: basic technical concepts and intercostal approach strategies. *Ann Thorac Surg* 1992;54:800-7.
- Roviaro G, Varoli F, Vergani C, Maciocco M. State of the art in thoracoscopic surgery: a personal experience of 2000 videothoroscopic procedures and an overview of the literature. *Surg Endosc* 2002;16:881-92.
- Gharagozloo F, Tempesta B, Margolis M, Alexander EP. Video-assisted thoracic surgery lobectomy for stage I lung cancer. *Ann Thorac Surg* 2003;76:1009-15.
- Solaini L, Prusciano F, Bagioni P, Di Francesco F, Basilio Poddie D. Video-assisted thoracic surgery major pulmonary resections. Present experience. *Eur J Cardiothorac Surg* 2001;20:437-42.
- Shiraishi T, Shirakusa T, Miyosi T, Hiratsuka M, Yamamoto S, Iwasaki A. A completely thoracoscopic lobectomy/segmentectomy for primary lung cancer: technique, feasibility, and advantages. *Thorac Cardiovasc Surg* 2006;54:202-207.
- McKenna RJ, Houck W, Fuller CB. Video-assisted thoracic surgery lobectomy: experience with 1,100 cases. *Ann Thorac Surg* 2006;81:421-6.
- Ferguson J, Walker W. Developing a VATS lobectomy programme-can VATS lobectomy be taught? *Eur J Cardiothorac Surg* 2006;29:806-9.
- Daniels LJ, Balderson SS, Onaitis MW, D'Amico TA. Thoracoscopic lobectomy: a safe and effective strategy for patients with stage I lung cancer. *Ann Thorac Surg* 2002;74:860-4.
- Loscertales J, Jimenez-Merchan R, Arenas Linares C, Giron-Arjona JC, Congre-

- gado-Loscertales M. The use of video-assisted thoracic surgery in lung cancer: evaluation of resectability in 296 patients and 71 pulmonary exeresis with radical lymphadenectomy. *Eur J Cardiothorac Surg* 1997;12:892-7.
11. Landreneau RJ, Hazelrigg SR, Mack MJ, Dowling RD, Burke D, Gavlick J, et al. Postoperative pain-related morbidity: video-assisted thoracic surgery versus thoracotomy. *Ann Thorac Surg* 1993;56:1285-9.
 12. Congregado M, Jimenez R, Loscertales J. Resezioni polmonary maggiore. In: Lavini C, Ruggiero C, Morandi U, editors. *Chirurgia toracica videoassistita*. Milan: Springer-Verlag; 2006. p. 55-67.
 13. Mahtabifard A, Fuller CB, McKenna RJ. Video-assisted thoracic surgery sleeve lobectomy: a case series. *Ann Thorac Surg* 2008;85:S729-32.
 14. McKenna Jr RJ. Video-Assisted thoracic surgery for wedge resection, lobectomy, and pneumonectomy. In: Shields TW, Locicero J, Ponn RB, Rusch VW, editors. *General thoracic surgery*, 6th ed. Philadelphia: Lippincott Williams & Wilkins; 2005.
 15. Yim AP, Wan S, Lee TW, Arifi AA. VATS lobectomy reduces cytokine responses compared with conventional surgery. *Ann Thorac Surg* 2000;70:243-7.
 16. Cattaneo SM, Park BJ, Wilton AS, Seshan VE, Bains MS, Downey RJ, et al. Use of video-assisted thoracic surgery for lobectomy in the elderly results in fewer complications. *Ann Thorac Surg* 2008;85:235-6.
 17. Congregado M, Merchan RJ, Gallardo G, Ayarra J, Loscertales J. Video-assisted thoracic surgery (VATS) lobectomy: 13 years' experience. *Surg Endosc* 2008;22:1852-7.
 18. Loscertales J, Jimenez-Merchan R, Congregado M, Ayarra FJ, Gallardo G, Trivino A. Video-assisted surgery for lung cancer. State of the art and personal experience. *Asian Cardiovasc Thorac Ann*. 2009;17:313-26.
 19. Nagahiro I, Andou A, Aoe M, Sano Y, Date H, Shimizu N. Pulmonary function, postoperative pain, and serum cytokine level after lobectomy: a comparison of VATS and conventional procedure. *Ann Thorac Surg* 2001;72:362-5.
 20. Tschernko EM, Hofer S, Bieglmayer C, Wissner W, Haider W. Early postoperative stress: video-assisted wedge resection/lobectomy vs conventional axillary thoracotomy. *Chest* 1996;109:1636-42.
 21. Petersen RP. Thoracoscopic lobectomy facilitates the delivery of adjuvant chemotherapy after resection for non-small cell lung cancer. *Ann Thorac Surg* 2007;83:1245-50.
 22. Petersen RP, Pham D, Toloza EM, Burfeind WR, Harpole DH Jr, Hanish SI, et al. Thoracoscopic lobectomy: a safe and effective strategy for patients receiving induction therapy for non-small cell lung cancer. *Ann Thorac Surg* 2006;82:214-9.
 23. Congregado M, Jimenez R, Loscertales J. Resezioni polmonary Maggiore. In: Lavini C, Ruggiero C, Morandi U, editors. *Chirurgia toracica videoassistita*. Milano: Springer-Verlag; 2006. p. 155-67.
 24. Weissberg D, Schachner A. Video-assisted thoracic surgery-state of the art. *Ann Ital Chir* 2000;71:539-43.
 25. Hermansson U, Konstantinov IE, Aren C. Video-assisted thoracic surgery (VATS) lobectomy: the initial Swedish experience. *Semin Thorac Cardiovasc Surg* 1998;10:285-92.
 26. Rothenberg SS. Experience with thoracoscopic lobectomy in infants and children. *J Pediatric Surg* 2003;38:102-4.
 27. Koren JP, Bocage JP, Geis WP, Caccavale RJ. Major thoracic surgery in octogenarians: the video-assisted thoracic surgery (VATS) approach. *Surg Endosc* 2003;17:632-5.
 28. Cano I, Anton-Pacheco JL, Garcia A, Rothenberg S. Video-assisted thoracoscopic lobectomy in infants. *Eur J Cardiovasc Surg* 2006;29:997-1000.
 29. Walker WS. Video-assisted thoracic surgery (VATS) lobectomy: Edinburgh experience. *Semin Thorac Cardiovasc Surg* 1998;10:291-5.
 30. Kaseda S, Aoki T, Hangai N, Shimizu K. Better pulmonary function and prognosis with video-assisted thoracic surgery than with thoracotomy. *Ann Thorac Surg* 2000;70:1644-6.
 31. Nomori H, Ohtsuka T, Horio H, Naruke T, Suemasu K. Difference in the impairment of vital capacity and 6-minute walking after a lobectomy performed by thoracoscopic surgery, an anterior limited thoracotomy, an anteroaxillary thoracotomy, and a posterolateral thoracotomy. *Surg Today* 2003;33:7-12.
 32. Lewis RJ, Caccavale RJ. Video-assisted thoracic surgical non-rib spreading simultaneously stapled lobectomy (VATS(n)SSL). *Semin Thorac Cardiovasc Surg* 1998;10:332-9.
 33. Stammberger U, Steinacher C, Hillinger S, Schmid RA, Kinsbergen T, Weder W. Early and long-term complaints following video-assisted thoracoscopic surgery: evaluation in 173 patients. *Eur J Cardiothorac Surg* 2000;18:7-11.
 34. Jimenez Merchá n R, Congregado Loscertales M, Gallardo Valera G, Triviño Ramirez A, Ayarra Jarne J, Loscertales J. Exploratory videothoracoscopy and videopericardioscopy in the definitive staging and assessment of resectability of lung cancer. *Arch Bronconeumol*. 200;45:435-41.
 35. Craig SR, Leaver HA, Yap PL, Pugh GC, Walker WS. Acute phase responses following minimal access and conventional thoracic surgery. *Eur J Cardiothorac Surg* 2001;20:455-63.
 36. Watanabe A, Koyanagi T, Ohsawa H, Mawatari T, Nakashima S, Takahashi N, et al. Systematic node dissection by VATS is not inferior to that through an open thoracotomy: a comparative clinicopathologic retrospective study. *Surgery* 2005;138:510-7.
 37. Sollitto F, De Palma A, Lopez C, Loizzi M. Minimally invasive thoracic surgery versus standard surgery. *Ann Ital Chir* 2003;74:299-307.
 38. Roviato G, Varoli F, Vergani C, Nucca O, Maciocco M, Grignani F. Long-term survival after videothoracoscopic lobectomy for stage I lung cancer. *Chest* 2004;126:725-32.
 39. Sugi K, Kaneda Y, Esato K. Video-assisted thoracoscopic lobectomy achieves a satisfactory long-term prognosis in patients with clinical stage IA lung cancer. *World J Surg* 2000;24:27-30.
 40. Walker WS, Cadispoli M, Soon SY, Stamenkovic S, Carnochan F, Pugh G. Long-term outcomes following VATS lobectomy for non-small cell bronchogenic carcinoma. *Eur J Cardiothorac Surg* 2003;23:397-402.
 41. Sagawa M, Sato M, Sakurada A, Matsumura Y, Endo C, Handa M, et al. A prospective trial of systematic nodal dissection for lung cancer by video-assisted thoracic surgery: can it be perfect? *Ann Thorac Surg* 2002;73:900-4.
 42. Iwasaki A, Shirakusa T, Shiraiishi T, Yamamoto S. Results of video-assisted thoracic surgery for stage I/II non-small cell lung cancer. *Eur J Cardiothorac Surg* 2004;26:158-64.
 43. Walker WS, Leaver HA. Immunologic and stress responses following video-assisted thoracic surgery and open pulmonary lobectomy in early stage lung cancer. *Thorac Surg Clin* 2007;17:241-9.
 44. Nakajima J, Takamoto S, Kohno T, Ohtsuka T. Costs of videothoracoscopic surgery versus open resection for patients with lung carcinoma. *Cancer* 2000;89:2497-501.
 45. Onaitis MW, Petersen RP, Balderson SS, Toloza E, Burfeind WR, Harpole DH Jr, et al. Thoracoscopic lobectomy is a safe and versatile procedure: experience with 500 consecutive patients. *Ann Surg* 2006;244:420-5.
 46. Demmy TL, Nwogu C. Is video-assisted thoracic surgery lobectomy better? Quality of life considerations. *Ann Thorac Surg* 2008;85:S719-28.
 47. Shaw JP, Dembitzer FR, Wisnivesky JP, Little VR, Weiser TS, Yun J, et al. Video-assisted thoracoscopic lobectomy: state of the art and future directions. *Ann Thorac Surg* 2008;85:705-9.
 48. Landreneau RJ, Mack MJ, Hazelrigg SR, Naunheim K, Dowling RD, Ritter P, et al. Prevalence of chronic pain following pulmonary resection by thoracotomy or video-assisted thoracic surgery. *J Thorac Cardiovasc Surg* 1994;107:1079-85.
 49. Shigemura N, Yim AP. Variation in the approach to VATS lobectomy: effect on the evaluation of surgical morbidity following VATS lobectomy for the treatment of stage I non-small cell lung cancer. *Thorac Surg Clin* 2007;17:233-9.
 50. Kirby T, Mack M, Landreneau J, Rice W. Lobectomy: video-assisted thoracic surgery versus muscle-sparing thoracotomy-A randomized trial. *Thorac Cardiovasc Surg* 1995;109:997-1001.
 51. Yan TD, Black D, Bannon PG, McCaughan BC. Systematic review and meta-analysis of randomized and nonrandomized trials on safety and efficacy of video-assisted thoracic surgery lobectomy for early-stage non-small-cell lung cancer.

- cer. *J Clin Oncol* 2009;27:2553-62.
52. Swanson SJ, Herndon JE 2nd, D'Amico TA, Demmy TL, McKenna RJ Jr, Green MR, et al. Video-assisted thoracic surgery lobectomy: report of CALGB 39802-a prospective, multi-institution feasibility study. *J Clin Oncol* 2007;25:4993-7.
53. Christopher Q. Cao, Stine Munkholm-Larsen, Tristan D. Yan. True video-assisted thoracic surgery for early-stage non-small cell lung cancer. *J Thorac Dis* 2009;1:34-8.