



Lung abscess: the non-conservative management: a narrative review

Walid Hadid^{1,2^}, Giulia Maria Stella^{3,4}, Ashish P. Maskey¹, Rabih I. Bechara⁵, Shaheen Islam⁶

¹Division of Pulmonary, Critical Care, Sleep Medicine and Interventional Pulmonary, University of Kentucky, Lexington, KY, USA; ²Community Health Network, Section of Interventional Pulmonary, Heart and Vascular Hospital, Indianapolis, IN, USA; ³Department of Internal Medicine and Medical Therapeutics, University of Pavia Medical School, Pavia, Italy; ⁴Cardiothoracic and Vascular Department, Unit of Respiratory Diseases, IRCCS Policlinico San Matteo, Pavia, Italy; ⁵Section of Interventional Pulmonology, Atrium Health Wake Forest Baptist, Wake Forest School of Medicine, Winston-Salem, NC, USA; ⁶Division of Pulmonary, Critical Care and Sleep Medicine, Georgia Medical College at Augusta University, Augusta, GA, USA

Contributions: (I) Conception and design: W Hadid; (II) Administrative support: None; (III) Provision of study materials or patients: None; (IV) Collection and assembly of data: W Hadid; (V) Data analysis and interpretation: W Hadid, AP Maskey; (VI) Manuscript writing: All authors; (VII) Final approval of manuscript: All authors.

Correspondence to: Walid Hadid, MD. Assistant Professor, Division of Pulmonary, Critical Care, Sleep Medicine and Interventional Pulmonary, University of Kentucky, Lexington, KY, USA; Interventional Pulmonologist, Community Health Network, Section of Interventional Pulmonary, Heart and Vascular Hospital, 7250 Clearvista Dr Ste 355, Indianapolis, IN 46256, USA. Email: whadid70@yahoo.com.

Background and Objective: Systemic antibiotics are the best treatment options for lung abscesses. However, up to 37% of lung abscesses do not respond to antibiotics and may require additional interventions. Percutaneous transthoracic tube drainage (PTTD), endoscopic catheter drainage (ECD) and surgical resection are additional options available when first line therapy with systemic antibiotics are unsuccessful. In this narrative review, we summarize all available interventional procedures, techniques, complications, safety, and contraindications.

Methods: A literature search was performed using Medline/PubMed from January 1980 to October 2023. Key words: “lung abscess”, “pulmonary abscess”, “endoscopic drainage”, “percutaneous drainage”, “tube drainage”. Pediatric patients were excluded from this study.

Key Content and Findings: PTTD and ECD are fairly safe procedures. Performing PTTD or ECD without delay may shorten the duration of hospital stay. This may lower the burden on health care. Moreover, draining abscesses may relieve discomfort in the clinical symptoms associated with abscesses. The primary factor in choosing ECD over PTTD is the location of the abscess, and the presence of a bronchial airway leading to the abscess for successful ECD. ECD has lower rate of complications and mortality; and similar success rate compared to PTTD. While mortality has been reported with PTTD, ECD appears to be safer according to present data.

Conclusions: PTTD and ECD are safe procedures, with low complication rates. ECD has a lower complication rate than PTTD does.

Keywords: Lung abscesses; pulmonary abscess; tube drainage; percutaneous lung abscesses drainage

Submitted Oct 08, 2023. Accepted for publication Apr 12, 2024. Published online May 28, 2024.

doi: 10.21037/jtd-23-1561

View this article at: <https://dx.doi.org/10.21037/jtd-23-1561>

[^] ORCID: 0000-0002-1713-8095.

Introduction

Lung abscesses result from lung infection and necrosis of the lung parenchyma as the body tries to contain the spread of infection. Conservative management with systemic antibiotics is the standard treatment for lung abscess with a success rate in the range from 63–67% (1,2). While conservative medical management with antibiotics is the first step and the gold standard, aggressive management with invasive procedures is now considered for those unresponsive to systemic antibiotics when they fail to achieve successful resolution of clinical symptoms.

The primary etiology of lung abscess is an important factor for antibiotic treatment failure. In cases of endobronchial obstruction due to tumor or foreign body impaction, or in cavitary lesions due to malignancy or vasculitis, the abscess may not respond to systemic antibiotics as expected. Inappropriate choice of antibiotics, failure to add antifungal agents or shorter duration of antibiotic treatment, are other possible causes of treatment failure. This is commonly seen with unusual microorganisms, such as *Mycobacterium tuberculosis*, atypical mycobacteria, fungi, and other uncommon bacteria, especially in immunocompromised patients. Moreover, any abscess greater than 6 cm in diameter is less likely to respond to antibiotics and frequently requires additional drainage procedures (2,3). There is a higher likelihood of treatment failure when treated with antibiotics alone in immunocompromised patients, abscess with underlying malignancy, advanced age, decreased level of consciousness, or infection with certain organisms, such as *Klebsiella pneumoniae*, *Pseudomonas aeruginosa*, and *Staphylococcus aureus* (4). Despite systemic antibiotic treatment, persistent clinical symptoms, or presence of radiologic evidence of active abscess, warrant a more definitive therapy with invasive procedures and, ultimately surgery. If a patient continues to experience deterioration of clinical symptoms even after 7–14 days of intravenous antibiotic treatment, aspiration of the abscesses or evaluation for possible surgical resection or decortication is suggested (5) (Figure 1). In rare cases, drainage is performed more than 2 months after starting antibiotics (6).

For decades, surgical resection remained the treatment of choice for lung abscesses that do not respond to conservative medical management using antibiotics. Additional treatment options have been developed over the past few decades. Percutaneous transthoracic tube drainage (PTTD) and, more recently, endoscopic catheter drainage (ECD) have been offered as effective alternatives to surgery.

Despite the fact that ECD and PTTD have been

performed for decades, providers are still hesitant to consider PTTD and ECD as an effective option and to perform that on time, mostly because of concerns about its safety profile and complication risks. Additionally, there are no specific guidelines to assist clinicians choose between these procedures.

Even with a modest number of existing literatures on PTTD and ECD, we were not able to locate a comprehensive review comparing the utility, morbidity and mortality risks of ECD and PTTD. The objective of this narrative review is to review existing literature and provide evidence-based recommendations, to help health care providers make informed decision to manage refractory lung abscess with appropriate procedures and the steps needed to achieve clinical and radiological improvement (Figure 2). This review includes the indications, contraindications, safety, and potential complications of each management option in the treatment of lung abscesses refractory to antibiotics. We present this article in accordance with the Narrative Review reporting checklist (available at <https://jtd.amegroups.com/article/view/10.21037/jtd-23-1561/rc>).

Methods

We performed a Medline/PubMed search using the key words, “lung abscess”, “pulmonary abscess”, “endoscopic drainage”, “percutaneous drainage”, “tube drainage”. Search phrase included “endoscopic drainage AND percutaneous drainage AND tube drainage AND lung abscess OR pulmonary abscess”. The search was limited all publications in English for the period between January 1980 and October 2023 (Table 1). Search filter included case reports, clinical study, original research, clinical trial, meta-analysis and systematic review, observational study, randomized controlled study and reviews. The search resulted in 4,104 articles. We excluded all animal studies and pediatric patients, narrowing down to 3,003 articles. Articles were further screened using the titles and key words and resulted in 43 articles. All abstracts and full text publications were reviewed, and articles that were lacking quality data or enough information to extract about the procedure were excluded. Final review included 36 articles (Figure 2) as well as additional articles were seen on references and showed to be important to this review. The search strategies are summarized in Table 1.

ECD of lung abscesses

The largest study by Herth *et al.* (6) included 42 patients

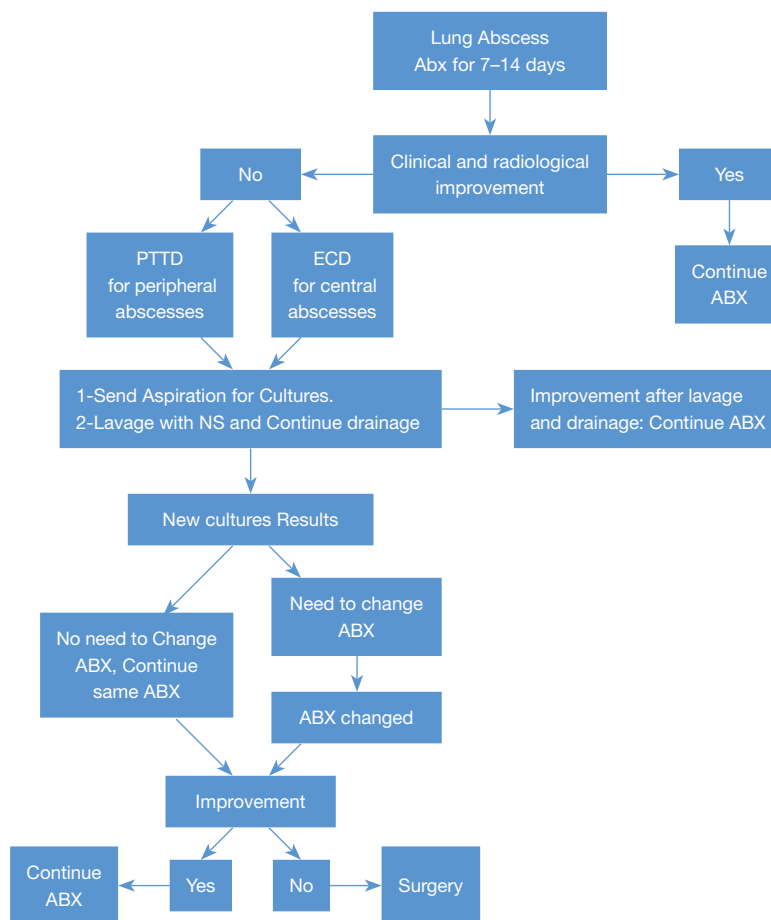


Figure 1 Approach to lung abscesses after failing to respond to antibiotics. ABX, antibiotics; PTTD, percutaneous transthoracic tube drainage; ECD, endoscopic catheter drainage; NS, normal saline.

with lung abscess who did not respond adequately to systemic antibiotics. Drainage catheters of sizes 7 French (F) or larger (pigtail catheter, 90 cm in length) were introduced over the guidewire into the abscess cavities using a flexible bronchoscope trans-nasally. The guidewire was initially placed either through the working channel of the bronchoscope or through a bronchography catheter. Fluoroscopy was performed to confirm the guidewire placement in the abscess cavity. The position of the pigtail catheter inside the abscess was determined by injecting contrast through the pigtail catheter. The catheter was then secured to the nose. Appropriate candidates were required to have airway communication with the cavity, and treatment decisions were made at multidisciplinary chest conferences. Drainage catheters were left in the abscess cavities until clinical or symptomatic improvement was observed. The cavities were flushed twice daily with

gentamicin or amphotericin B if fungal etiology was suspected. Thirty-eight (90%) patients, where the catheters were successfully placed, showed clinical improvement. Two patients (5%) required transient ventilation. No other complications were noted. This study demonstrated that bronchoscopic drainage was successfully performed for lung abscess when the clinical response to intravenous antibiotics was unsatisfactory. Moreover, this procedure did not result in significant complications. The patients in this study received antibiotics anywhere from 14 to 78 days before the placement of the pigtail catheters. The patients also received antibiotics 3–21 days after drainage catheter placement.

A similar lung abscess drainage approach was performed by Unterman *et al.* (7). Pigtail catheters were placed in lung abscesses of patients who did not respond adequately to antibiotics. This procedure was successful in 13 of

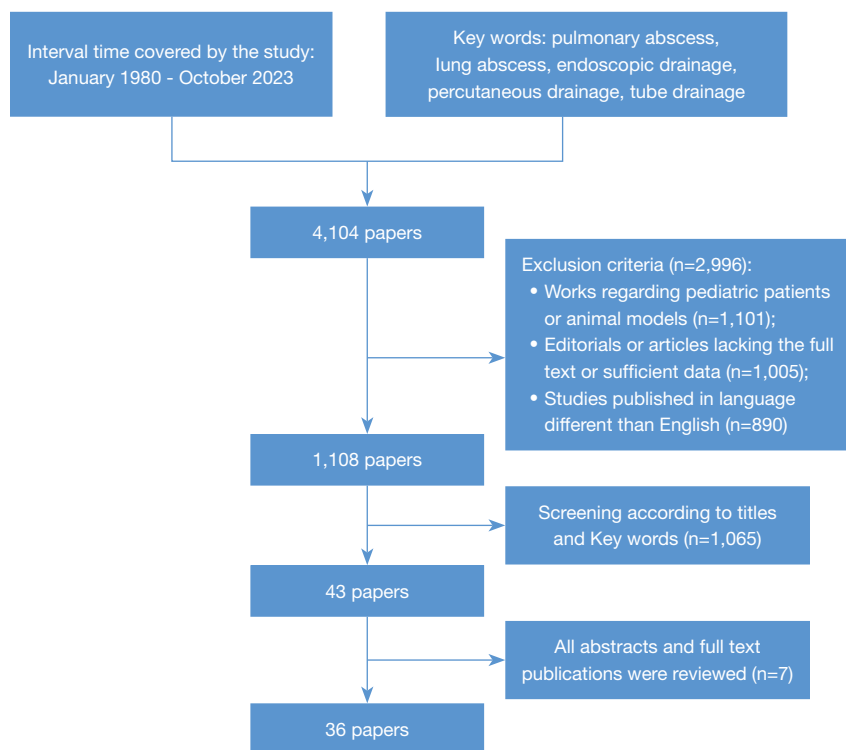


Figure 2 Flowchart for the narrative review.

Table 1 Search strategy summary

Items	Specifications
Date of search	October 30, 2023
Databases	Medline/PubMed
Search terms used	“endoscopic drainage AND percutaneous drainage AND tube drainage AND lung abscess OR pulmonary abscess”
Timeframe	January 1, 1980 to October 1, 2023
Inclusion and exclusion criteria	Inclusion: only study in English and adult patients were included Exclusion: study with pediatric patients or lacking enough data were excluded
Selection process	W.H. conducted the initial literature search. All authors conducted additional literature searches and involved in the final selection

15 patients. Twelve patients showed a significant response and clinical improvement.

Takaki *et al.* (8) described three cases where an endobronchial ultrasound guide sheath (EBUS-GS Kit, K-203; Olympus America) was used to access abscess cavities in the lungs. Two small holes were punched near the guide sheath (GS) tip. The GS was inserted into the abscess using a bronchoscope, and aspiration was performed in addition to lavage of the abscess cavity with normal saline. The antibiotic was changed in two cases based on the

culture results. All patients showed clinical improvement at the end of the antibiotic treatment. Two patients had persistent cavitation with no fluid collection in the cavities.

Yaguchi *et al.* (9) used GS to aspirate pus and obtain cultures from lung abscess. Abu-Awwad *et al.* used GS to instill DNase with normal saline into the abscess cavity (10). DNase facilitates drainage by lysing fibrin loculations. These bronchoscopic approaches have improved and helped accelerate the antibiotic response.

Cascone *et al.* (11) reported 12 elderly patients with lung

Table 2 Endoscopic lung abscess drainage, size of tube, improvement rate, complications and mortality rate

Study	No. of patients	Tube used	Improvement or recovery	Complications	Mortality rate
Herth <i>et al.</i> (6)	42	7 F or larger	38 (90%)	2 (5%)	0
Unterman <i>et al.</i> (7)	15	Pigtail	12 (80%)	0	0
Takaki <i>et al.</i> (8)	3	GS	3 (100%) clinically, 2 (66%) continue to have cavitation	0	0
Yaguchi <i>et al.</i> (9)	1	GS	1 (100%)	0	0
Cascone <i>et al.</i> (11)	12	UK*	12 (100%)	0	0
Izumi <i>et al.</i> (12)	1	GS	1 (100%)	0	0
	74	Different sizes	67 (90.5%)	2 (2.7%)	0

F, French; GS, guide sheath catheter; UK*, unknow size of the catheter, the authors mentioned as small size catheter.

abscesses and history of lymphoma. Ten patients showed no improvement with systemic antibiotic therapy, while two patients had worsening symptoms. Bronchoscopic drainage was performed by placing a catheter in the abscess cavity, and gentamicin was administered daily. This was performed while the patients were still on systemic antibiotics. Abscess cavities were frequently aspirated and cultured. The antibiotic choice was further tailored depending on the culture results from aspiration. Catheters were left in the abscesses for a period—3–5 days. All the patients showed clinical improvement with this approach.

These reports suggest that the ECD can be successfully placed in abscess cavities with clinical and radiological evidence of improvement in over 90% of cases. The complication rates were less than 3% (Table 2) (6-9,11,12). However, except for the cohort described by Herth *et al.* (6), the remaining reports include a smaller number of patients and the findings may not be generalizable.

PTTD

PTTD had been used as an alternative to surgery when conservative treatment with antibiotics failed (13–16). Monaldi *et al.* first described bacterial lung abscess aspiration in the 1950s (16). He had previously used the same aspiration technique for tuberculous abscesses.

There have been multiple case reports and case series of PTTD. Yellin *et al.* (13) described seven patients who did not respond to antibiotics and underwent surgery. All patients underwent PTTD. All the patients recovered fully without complications after the procedure. The patients were followed for a period of 2–5 years with no relapse. Three patients required surgery after PTTD due to the

malignant nature of the abscess. The authors concluded that PTTD was effective and safe alternative to surgical resection. Most early studies selected the sicker patients to undergo PTTD. Patients who were too sick to undergo lobe resection or surgical treatment. These patients had favorable outcome compared to patient less sick and underwent surgical resection (17,18). Mengoli *et al.* (18) suggested PTTD is effective and probably safer treatment than surgery for pulmonary abscesses the size 8 cm or larger and may need to be considered early during the hospitalization period.

vanSonnenberg *et al.* (19) performed computed tomography (CT) guided catheter drainage in 19 patients with lung abscesses and sepsis. The patients underwent conservative medical treatment. All patients received intravenous antibiotics for at least 5 days. All abscesses improved according to clinical and radiographic criteria. No surgery was required in 16 patients. Three patients required surgery for decortication or removal of organized tissues after abscess drainage. One patient had hemothorax and required chest tube placement, and two patients had clogged catheters.

PTTD can be performed at bedside under ultrasound guidance. Chest CT can be more accurate and provide accurate guidance, which may avoid or minimize the risk of puncture of the lung parenchyma (20). The drainage can be performed with a small-bore chest tube as small as 7 F. PTTD has been reported to be more helpful in identifying the microbiology of abscesses than conventional bronchoscopy or sputum culture (21). Intracavitary tissue plasminogen activator and deoxyribonuclease have been instilled along with PTTD to facilitate better evacuation of lung abscesses (22).

Early PTTD may shorten the length of hospital stay (LOS) (22). In a retrospective study, Chiang *et al.* (23) defined early PTTD as those performed within one week of the diagnosis of lung abscess and compared the outcomes between early and late PTTD. There were no significant differences in complications or 90-day mortality between the early and delayed PTTD groups.

Matarese *et al.* (4) used 14 G needle to aspirate lung abscesses under ultrasound guidance in a series of eight patients. They used a 14 G needle because no pigtail catheters were available at the hospital. The other six patients had 14 F pigtail catheters placed in the abscesses. Ultrasound was used in four of the six patients to help insert the guidewire into the abscess cavities. The other two patients had to have both ultrasound and fluoroscopy guidance to help place the catheter in the correct location. The Seldinger technique was used to insert pigtail catheters over the guidewire into the abscesses; 50% had complete resolution of the abscess cavities. One patient developed pneumothorax and no bronchopleural fistula (BPF) was reported (4).

Obtaining aspirations for culture and cytology of lung abscesses may change the management and diagnosis. Peña Griñan *et al.* (24) in 50 patients with lung abscess, used a 22 G spinal needle to aspirate and send the material for cultures. This procedure showed a high diagnostic yield and played a significant role in changing the initial empirical antibiotic treatment. Eight of nine patients were sent for cytology and showed malignant cells.

A recent systematic review and meta-analysis (25) reported 88.5% success rate of percutaneous catheter drainage of lung abscesses. Pooled major complication rate was 8.1%. The same review concluded that the sole risk factor for major complications is the catheter traversing the normal lung parenchyma. Seventeen patients experienced major complications. This included pneumothorax in 10 patients. Empyema occurred in six patients, BPF in five patients and hemothorax in one patient. Three patients developed pneumothorax and empyema, and two had complications of empyema and BPF simultaneously. Eight (61.5%) out of 13 patients who had the catheters traversing normal lung parenchyma ended up with major complications, and the most common was pneumothorax. In four of five patients with BPF, the catheter was not found traversing the normal lung parenchyma.

Another systematic review reported that PTTD is a safe and effective approach for the treatment of lung abscesses (26). The duration of fever and hospital stay

were shorter in patients with PTTD than in those treated conservatively.

In the systematic review and meta-analysis of 194 patients, 5 patients developed BPF (25). Rice *et al.* (27) in his series of 11 patients reported that it was not difficult to manage mechanical ventilation with BPF and only two patients required surgical management of BPF.

Currently, among the available options for various chest tube sizes, the smallest chest tube (such as 7–10 F) may be the best option, when the patient is not a surgical candidate. However, thick pus may sometimes occlude the small-bore chest tube and may require frequent flushing of the chest tube with saline solution. We prefer small chest tube as it has less risk of causing BPF compared to large bore chest tube. The GS catheter and 7–10 F tube has similar to higher success rate in treating lung abscess compared to large bore chest tubes (*Table 3*) (4,5,13,14,19,20,27–32). We reported the chest tube sizes if it was mentioned in the papers (*Table 3*).

Conservative management of BPF included endobronchial valve (EBV) placement to allow atelectasis of the involved bronchial segment or lobe and to allow a reasonable time for healing. Patients without emphysema and those who have complete lung fissures are more likely to benefit from EBVs. Patients with emphysema and incomplete fissures are less likely to benefit from EBV because of collateral ventilation between the lobes.

In our review, success rate of PTTD was 80% in achieving resolution of lung abscess. While complication rate was 20%, most complications did not require surgical intervention. In 15% of PTTD, further invasive procedures were needed such as surgery or chest tube for pneumothorax (*Table 3*).

Surgical management of lung abscess

Surgery is indicated in patients who fail to improve after receiving an adequate course of antibiotics either alone or in combination with percutaneous catheters or endoscopic drainage. The response may be monitored by observing improvement of symptoms and signs of infection, and improvement of radiographic findings. Patients who develop BPF, empyema or significant hemoptysis that is not controlled with either endobronchial intervention or bronchial artery embolization need to undergo surgical resection. Surgery is usually deferred as the last option because of high mortality, which can be as high as 11% (33). The mortality rate is related to patient morbidities, disease

Table 3 Percutaneous transthoracic tube drainage: tube size, images, successful and complications rate, mortality and additional procedures

Study	Images guidance	Catheter size	Patients' number	Clinical and radiographical improvement	Complications	Further procedure	Mortality
Matarese <i>et al.</i> (4)	Fluoroscopy and US	14 G (2 pts) needle, pigtail 14 F (6 pts)	8	4 (50%) C, 2 (25%) NC, 1 (13%) P	–	–	0
Parker <i>et al.</i> (5)	Fluoroscopy	7–10 F	6	6 (100%)	0	0	0
Yellin <i>et al.</i> (13)	PA/LA chest roentgenograms	Argyle trocar catheter, Foley catheter, 12 G IV PE catheter	10	7 (70%)	0	3 (30%) were malignant and required surgery	0
Shim <i>et al.</i> (14)	Roentgenograms [†]	Chest tube [‡]	5	5 (100%)	0	0	0
vanSonnenberg <i>et al.</i> (19)	CT chest	Catheter [‡]	19	19 (100%)	4 (21%)	3 (16%) surgery to remove organizing tissue or decortication	0
Rice <i>et al.</i> (27)	Fluoroscopy, chest roentgenograms	Chest tube [‡]	11	8 (73%)	11 (100%) BPF	2 (18%) surgical closer for BPF, 3 (27%) rib resection and operative tube insertion	1
Prasad <i>et al.</i> (28)	Chest roentgenograms, fluoroscopy, chest skiagram	8 F pigtail	12	12 (100%)	0	0	0
Cupido <i>et al.</i> (29)	US and chest CT	14 F pigtail	1	1 (100%)	0	0	0
Kelogrigoris <i>et al.</i> (30)	CT chest	8–10 F	40	33 (83%)	5 (13%) PTX	7 (17%) surgery, 3 (7%) chest tube for PTX	0
Yunus <i>et al.</i> (31)	CT chest	CT guided PD [‡]	19	8 (42%) complete	5 (26%) PTX, 2 (10.5%) BPF	Surgery in 2 (10.5%) for residual cavity and 2 (10.5%) for BPF	0
Ha <i>et al.</i> (20)	CT	PD [‡]	6	4 (66%) complete	0	0	0
Hirshberg <i>et al.</i> (32)	Unknown	Chest catheter [‡]	8	3 (37.5%)	–	–	5 (62.5%)
Total	–	–	145	113 (78%)	27 (19%)	25 (17%)	6 (4.1%)

[†], the author did not clarify the images used, possible he depends on CXR and physical examination; [‡], chest tube or catheter sizes was not clarified. US, ultrasound; G, gauge; pts, patients; F, French; C, complete; NC, near complete; P, partial; PA, posterior anterior; LA, lateral; IV, intravenous; PE, polyethylene; CT, computed tomography; BPF, bronchopleural fistula; PTX, pneumothorax; CXR, chest X-ray; PD, percutaneous drainage.

Table 4 ECD vs. PTTD: complications and mortalities

Complications	ECD	PTTD
Complication rate	2.6%	19%
Mortality rate	0	6%
BPF	0	3%
Pneumothorax	0%	5%
Hemothorax	0%	0.5%
Pulmonary artery injuries	0%	Reported

ECD, endoscopic catheter drainage; PTTD, percutaneous transthoracic tube drainage; BPF, bronchopleural fistula.

severity, and underlying clinical conditions. Surgical management ranges from wedge resection to lobectomy or even pneumonectomy (34-36).

Comparison of ECD to PTTD

Compared to PTTD (*Table 4*) there are fewer complications and higher success rate with ECD. No mortalities were reported in ECD. However, mortality is reported with PTTD in two studies (27,32) which limits its use. The presence of bronchial sign leading to the abscess make it easier to reach the abscess with ECD. Although robotic bronchoscopy and 3D fluoroscopy may be use in theory to access the abscess there is no such report yet.

Discussion

Even though most lung abscess improve with conservative medical management using systemic antibiotics, up to 37% of abscesses may still require invasive procedures or surgical management. Clinical symptoms usually begin to improve within the first 4 days. If patients do not show clinical or radiological improvement over the first 7–14 days of starting antibiotic therapy, an invasive procedure may need to be considered for drainage and lavage of the abscess and to obtain a better microbiological specimen for cultures (*Figure 1*). Abscesses 6 cm in diameter or larger are less likely to responds to antibiotics alone.

Even though PTTD has an acceptable safety profile, we need to be aware that BPF can be a devastating complication. In non-surgical patients, a small-bore chest tube may be considered to drain lung abscesses when conservative medical management fails. However, because of the risk of BPF, the decision for PTTD in lung abscess

should be carefully weighed by a multidisciplinary team of experts from infectious disease, pulmonary, interventional pulmonary, interventional radiology, and thoracic surgeons.

Like any other invasive procedure, relative contraindications for PTTD include coagulopathy, respiratory failure with severe hypoxia, and inability to access the abscess cavity. However, a clinician should weigh the benefit of PTTD depending on the clinical condition, severity, the need for drainage and the ability to tolerate surgical resection.

The location of the lung abscess is a major determinant of PTTD and ECD. CT images should be carefully reviewed, and 3D virtual imaging should be used in planning ECD. PTTD should be reserved for peripheral abscesses with none to very little existing normal lung parenchyma near the parietal pleura and the abscess. ECD can be done for central and proximally located abscesses (*Figure 1*). Local gentamicin or antifungal if fungal infection is suspected can be administered into the abscess cavity in addition to drainage, or to obtain specimen of cultures (6,11).

Without a head to head comparison of PTTD with ECD, the data from the available literature (*Tables 2,3*) suggest that both PTTD and ECD can be safe procedures with minimal complications. Several factors may affect the accuracy of this conclusion. In the largest study of ECD, Herth *et al.* (6) adopted a multidisciplinary approach with careful patient selection, which may have led to fewer complications. The remainder of the ECD data were reported from studies with smaller sample sizes. While small bore catheters, placed through the bronchus did not injure the lungs, the worst complication could be lack of drainage. Also, many PTTD procedures reported earlier, were performed with large bore chest tubes inserted through the visceral pleura and traversing the lung parenchyma, which by default, is expected to have a higher rate of complications including BPF (25). The mortality rate was 4.1% in PTTD compared to none with ECD. However, the mortality is reported from a retrospective study, where five out of eight patients died from lung abscesses after PTTD (32). In another report, one of 11 patients died from lung abscess complications after PTTD (27).

It is important to keep in mind that these procedures are guided by fluoroscopy and ultrasonography. Currently, we now have the options for 3D fluoroscopy, cone beam CT, and robot-assisted bronchoscopy. This may increase the success rate of accessing the abscess cavities to perform aspiration. Further research is needed to confirm this assumption.

The present review is limited to case series and

retrospective studies and lack data from robust randomized controlled trials to compare antibiotic alone *vs.* antibiotic and drainage procedures and also ECD *vs.* PTTD. Therefore, we recommend clinicians to use their judgment in combination of the information to make clinical decisions to manage patients with lung abscess.

Conclusions

In summary, PTTD and ECD should be considered for lung abscesses that do not respond to antibiotics. These procedures have a significant success rate in improving the resolution of abscesses, with low complication rates. Making the decision to drain the abscesses early, within 4–5 days of diagnosis, may reduce hospital stay and accelerate recovery. A multi-disciplinary team of pulmonologists, infectious disease specialists, radiologists and thoracic surgeons should be involved in decision making. Larger prospective studies are still needed, especially with current available technology to access lung abscesses and the availability of much smaller chest tube diameter than that used before.

Acknowledgments

The authors would like to thank Louisa Summers, PhD for her input on the accuracy of writing in English.

Funding: None.

Footnote

Reporting Checklist: The authors have completed the Narrative Review reporting checklist. Available at <https://jtd.amegroups.com/article/view/10.21037/jtd-23-1561/rc>

Peer Review File: Available at <https://jtd.amegroups.com/article/view/10.21037/jtd-23-1561/prf>

Conflicts of Interest: All authors have completed the ICMJE uniform disclosure form (available at <https://jtd.amegroups.com/article/view/10.21037/jtd-23-1561/coif>). The authors have no conflicts of interest to declare.

Ethical Statement: The authors are accountable for all aspects of the work in ensuring that questions related to the accuracy or integrity of any part of the work are appropriately investigated and resolved.

Open Access Statement: This is an Open Access article

distributed in accordance with the Creative Commons Attribution-NonCommercial-NoDerivs 4.0 International License (CC BY-NC-ND 4.0), which permits the non-commercial replication and distribution of the article with the strict proviso that no changes or edits are made and the original work is properly cited (including links to both the formal publication through the relevant DOI and the license). See: <https://creativecommons.org/licenses/by-nc-nd/4.0/>.

References

- Allewelt M, Schüler P, Bölskei PL, et al. Ampicillin + sulbactam vs clindamycin +/- cephalosporin for the treatment of aspiration pneumonia and primary lung abscess. *Clin Microbiol Infect* 2004;10:163-70.
- Ott SR, Allewelt M, Lorenz J, et al. Moxifloxacin vs ampicillin/sulbactam in aspiration pneumonia and primary lung abscess. *Infection* 2008;36:23-30.
- Uribe JP, Serna JCC, Mittal A, et al. Drainage Modalities in Patients with Lung Abscess: A Single Center Experience. *Chest* 2022;162:A400.
- Matarese A, Tamburrini M, Desai U, et al. Percutaneous lung abscess drainage: revisiting the old gold standard. *Monaldi Arch Chest Dis* 2020;90(1).
- Parker LA, Melton JW, Delany DJ, et al. Percutaneous small bore catheter drainage in the management of lung abscesses. *Chest* 1987;92:213-8.
- Herth F, Ernst A, Becker HD. Endoscopic drainage of lung abscesses: technique and outcome. *Chest* 2005;127:1378-81.
- Unterman A, Fruchter O, Rosengarten D, et al. Bronchoscopic Drainage of Lung Abscesses Using a Pigtail Catheter. *Respiration* 2017;93:99-105.
- Takaki M, Tsuyama N, Ikeda E, et al. The Transbronchial Drainage of a Lung Abscess Using Endobronchial Ultrasonography with a Modified Guide Sheath. *Intern Med* 2019;58:97-100.
- Yaguchi D, Ichikawa M, Inoue N, et al. Transbronchial drainage using endobronchial ultrasonography with guide sheath for lung abscess: A case report. *Medicine (Baltimore)* 2018;97:e10812.
- Abu-Awwad R, Medrek S, Lazarus DR, et al. Endobronchial Instillation of DNase to Facilitate Bronchoscopic Drainage of a Lung Abscess. *Ann Am Thorac Soc* 2015;12:1885-7.
- Cascone R, Sica A, Sagnelli C, et al. Endoscopic Treatment and Pulmonary Rehabilitation for Management of Lung Abscess in Elderly Lymphoma Patients. *Int J Environ Res*

- Public Health 2020;17:997.
12. Izumi H, Kodani M, Matsumoto S, et al. A case of lung abscess successfully treated by transbronchial drainage using a guide sheath. *Respirol Case Rep* 2017;5:e00228.
 13. Yellin A, Yellin EO, Lieberman Y. Percutaneous tube drainage: the treatment of choice for refractory lung abscess. *Ann Thorac Surg* 1985;39:266-70.
 14. Shim C, Santos GH, Zelefsky M. Percutaneous drainage of lung abscess. *Lung* 1990;168:201-7.
 15. Weissberg D. Percutaneous drainage of lung abscess. *J Thorac Cardiovasc Surg* 1984;87:308-12.
 16. Monaldi V. Endocavitary aspiration in the treatment of lung abscess. *Dis Chest* 1956;29:193-201.
 17. Estrera AS, Platt MR, Mills LJ, et al. Primary lung abscess. *J Thorac Cardiovasc Surg* 1980;79:275-82.
 18. Mengoli L. Giant lung abscess treated by tube thoracostomy. *J Thorac Cardiovasc Surg* 1985;90:186-94.
 19. vanSonnenberg E, D'Agostino HB, Casola G, et al. Lung abscess: CT-guided drainage. *Radiology* 1991;178:347-51.
 20. Ha HK, Kang MW, Park JM, et al. Lung Abscess: Percutaneous Catheter Therapy. *Acta Radiologica* 1993;34:362-5.
 21. Duncan C, Nadolski GJ, Gade T, et al. Understanding the Lung Abscess Microbiome: Outcomes of Percutaneous Lung Parenchymal Abscess Drainage with Microbiologic Correlation. *Cardiovasc Intervent Radiol* 2017;40:902-6.
 22. Chae J, Kern R, Nelson D, et al. Diffuse large B cell lymphoma with superimposed lung abscess: potential role for intracavitary fibrinolytic therapy through a percutaneous drain to facilitate lung abscess drainage. *BMJ Case Rep* 2018;11:e225670.
 23. Chiang PC, Lin CY, Hsu YC, et al. Early drainage reduces the length of hospital stay in patients with lung abscess. *Front Med (Lausanne)* 2023;10:1206419.
 24. Peña Griñan N, Muñoz Lucena F, Vargas Romero J, et al. Yield of percutaneous needle lung aspiration in lung abscess. *Chest* 1990;97:69-74.
 25. Lee JH, Hong H, Tamburrini M, et al. Percutaneous transthoracic catheter drainage for lung abscess: a systematic review and meta-analysis. *Eur Radiol* 2022;32:1184-94.
 26. Lin Q, Jin M, Luo Y, et al. Efficacy and safety of percutaneous tube drainage in lung abscess: a systematic review and meta-analysis. *Expert Rev Respir Med* 2020;14:949-56.
 27. Rice TW, Ginsberg RJ, Todd TR. Tube drainage of lung abscesses. *Ann Thorac Surg* 1987;44:356-9.
 28. Prasad B, Shashirekha, Tewari SC, et al. Management of Lung Abscess With Percutaneous Catheter Drainage. *Med J Armed Forces India* 1998;54:134-6.
 29. Cupido GC, Günther G, Ellitson L. Percutaneous catheter drainage of a pyogenic lung abscess: A case report. *Afr J Thorac Crit Care Med* 2022;28:10.7196/AJTCCM.2022.v28i1.145.
 30. Kelogrigoris M, Tsagouli P, Stathopoulos K, et al. CT-guided percutaneous drainage of lung abscesses: review of 40 cases. *JBR-BTR* 2011;94:191-5.
 31. Yunus M. CT guided transthoracic catheter drainage of intrapulmonary abscess. *J Pak Med Assoc* 2009;59:703-9.
 32. Hirshberg B, Sklair-Levi M, Nir-Paz R, et al. Factors predicting mortality of patients with lung abscess. *Chest* 1999;115:746-50.
 33. Delarue NC, Pearson FG, Nelems JM, et al. Lung abscess: surgical implications. *Can J Surg* 1980;23:297-302.
 34. Mitchell JD, Yu JA, Bishop A, et al. Thoracoscopic lobectomy and segmentectomy for infectious lung disease. *Ann Thorac Surg* 2012;93:1033-9; discussion 1039-40.
 35. Sun Y, Hou L, Xie H, et al. Wedge resection for localized infectious lesions: high margin/lesion ratio guaranteed operational safety. *J Thorac Dis* 2014;6:1173-9.
 36. Schweigert M, Solymosi N, Dubecz A, et al. Predictors of Outcome in Modern Surgery for Lung Abscess. *Thorac Cardiovasc Surg* 2017;65:535-41.

Cite this article as: Hadid W, Stella GM, Maskey AP, Bechara RI, Islam S. Lung abscess: the non-conservative management: a narrative review. *J Thorac Dis* 2024;16(5):3431-3440. doi: 10.21037/jtd-23-1561