

Giant bronchogenic cyst with pericardial defect: a case report & literature review in Japan

Toshiko Kamata¹, Shigetoshi Yoshida¹, Takekazu Iwata¹, Yukio Nakatani², Ichiro Yoshino¹

¹Department of General Thoracic Surgery, ²Department of Diagnostic Pathology, Chiba University Graduate School of Medicine, Chiba, Japan
Correspondence to: Shigetoshi Yoshida. Department of General Thoracic Surgery, Chiba University Graduate School of Medicine, Chiba, Japan.
Email: shigeyoshida@mac.com.

Abstract: Congenital pericardial defects are a rare anomaly, found during autopsy and cardiothoracic surgery. We describe a case of a 69-year-old female, with a right-sided congenital pericardial defect associated with a giant bronchogenic cyst (BC) found during surgery. The cyst was resected and the patient developed arrhythmia following surgery. A review of the literature in Japan was performed, focusing on congenital anomalies associated with pericardial defects and its pathogenesis. We paid particular attention to complications following thoracic surgery in patients with pericardial defects and indications of pericardial reconstruction in such patients.

Keywords: Bronchogenic cyst (BC); pericardial defect; thoracic surgery

Submitted Apr 15, 2016. Accepted for publication May 20, 2016.

doi: 10.21037/jtd.2016.06.65

View this article at: <http://dx.doi.org/10.21037/jtd.2016.06.65>

Introduction

Congenital diseases of the lung and mediastinum are increasingly being diagnosed in adults. Careful radiological evaluation of the lesions and knowledge of potential complications are important to provide adequate treatment (1). Anomalous arteries and veins, communications with surrounding mediastinal structures, coexisting congenital anomalies and infections may lead to unforeseen complications following surgery (2).

Here, we report a case of giant bronchogenic cyst (BC) associated with pericardial defect found during surgery. We discuss the cause of these congenital anomalies and review the literature, focusing on potential surgical complications.

Case presentation

A 69-year-old woman presented with dyspnea on excursion. Computed tomography (CT) revealed a mediastinal tumor and she was referred to the department of thoracic surgery.

She had a past history of hypertension and hyperlipidemia. She received operation for left breast cancer at the age of 60 and myoma of the uterus at 35.

Physical examination revealed no abnormalities,

blood pressure was 116/73 mmHg, and heart rate was 80 beats per minute, SpO₂ 99%. Her heart rate rose to 124 beats per minute on excursion. ECG was normal, but echocardiography revealed a mild left ventricular diastolic dysfunction and a mass adjacent to the left atrium. Chest radiography showed a mass overlapping the cardiac silhouette (*Figure 1A*). Chest multiple detector computed tomography (MDCT) demonstrated a large cystic mass 60 mm in diameter, which was located beneath the carina. It compressed the right superior pulmonary vein and left atrium. It also lay adjacent to the right pulmonary artery and the left superior pulmonary vein (*Figure 1B*).

The mass showed intermediate signal on sagittal-axis views of cine magnetic resonance imaging (MRI) (*Figure 1C*). And the mass showed high intensity in T1-weighted image, and mixed intensity in T2-weighted image on chest MRI (*Figure 1D*). Surgery was performed via a right posterolateral thoracotomy. The tumor lay between the superior and inferior pulmonary vein (*Figure 2A*). It was also loosely adhered to the pulmonary artery and right main bronchus. The tumor was dissected from its adjacent structures. Following resection, a partial defect in the pericardium was found and the left ventricle could

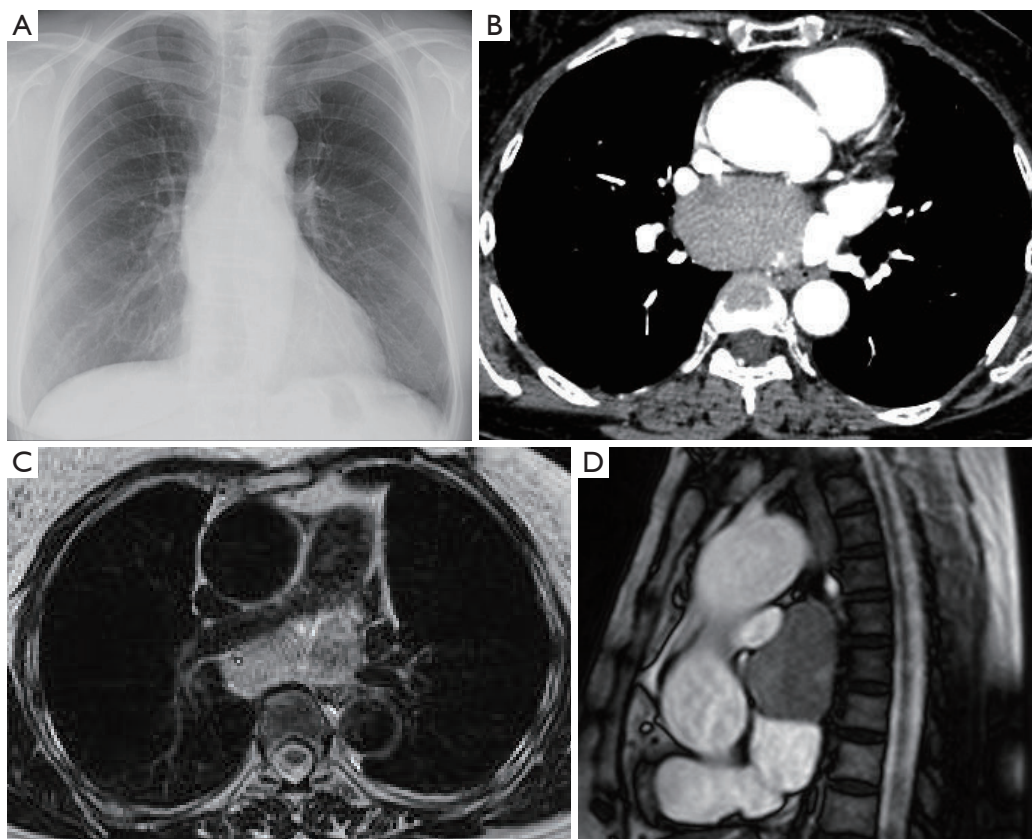


Figure 1 Findings on chest X-ray, computed tomography (CT) and MRI. (A) A mass overlapping the cardiac silhouette was detected on chest X-ray; (B) a large cystic mass measuring 60 mm was detected on MDCT, the mass compressed the left atrium and the right superior pulmonary vein, it also lay adjacent to the right pulmonary artery and the left superior pulmonary vein; (C) a high intensity in T2-weighted image; (D) the mass had an intermediate intensity on cine MRI. MDCT, multiple detector computed tomography; MRI, magnetic resonance imaging.

be observed (*Figure 2B,C*). The tumor was 72 mm in length and contained thick yellowish fluid (*Figure 2D*). Pathological diagnosis was BC.

The patient developed a paroxysmal atrial fibrillation on the third post-operative day and medication was started. She was discharged on the 13th post-operative day, but atrial fibrillation persisted three months after surgery.

Discussion

Congenital pericardial defect is a rare anomaly consisting of a partial or total defect in the pericardium. It was found in one case among 14,000 autopsies performed in a single institution (3). Most cases are found by chance at autopsies and thoracic surgeries. In a research by Ellis *et al.*, 73% were males, and were left sided in most cases. Only three among 99 cases had right sided defects (4).

During the 6th week of gestation, the pericardio-pleural canal fuses and the communication between the pleural cavity and the pericardium closes. The patency of the canal is said to be the cause of defects in the pericardium. According to a theory by Perna, premature atrophy of the duct of Cuvier results in deficient blood supply and incomplete development of the pleuro-pericardial membrane (5,6).

In 1945, Rusby *et al.* (5) reported a case of BC associated with left sided partial pericardial defect. The association between these two anomalies may also be due to the atrophy of the duct of Cuvier. The lung buds develop from the foregut in the 5th-week embryo. As the lung develops, structures such as the duct of Cuvier, prevents its expansion to the mesial side. Premature atrophy of the duct is theorized to enable the development of abnormal lung buds and additional lobes.

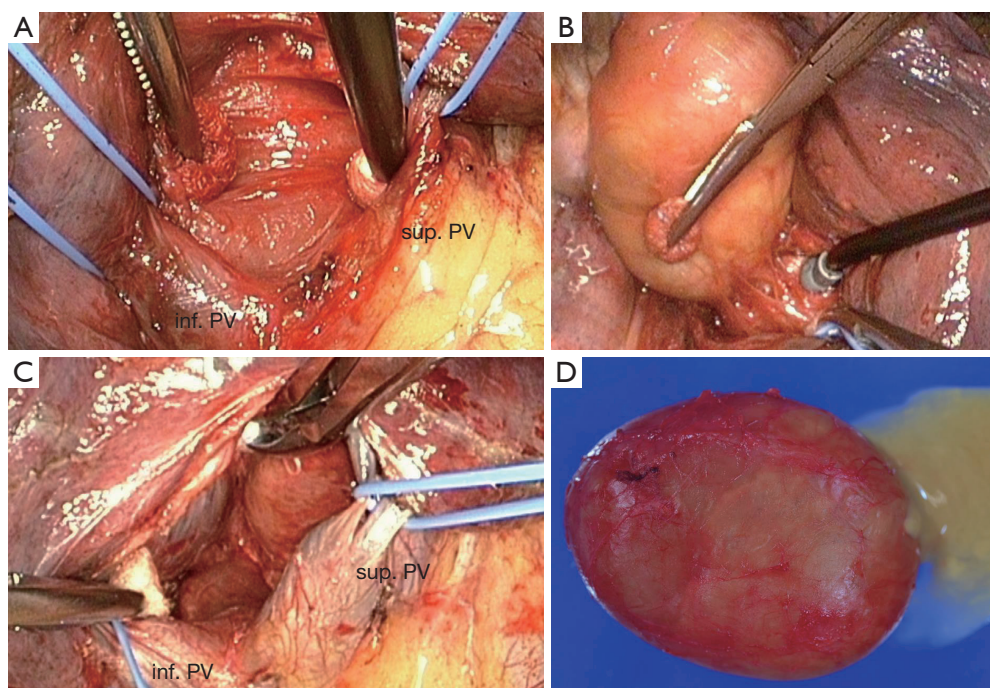


Figure 2 Surgical findings. (A) The tumor lay between the right superior and inferior pulmonary vein; (B) the tumor was loosely adhered to the adjacent structures; (C) following resection, the left ventricle could be observed through a partial defect in the pericardium (arrow); (D) the resected tumor containing thick yellowish fluid. sup. PV, superior pulmonary vein; inf. PV, inferior pulmonary vein.

In a search of the English literature, we found 25 cases of pericardial defects associated with developmental abnormalities arising from the foregut, such as BCs and pulmonary sequestrations (5,7-21). There were ten cases of mediastinal BCs among which one had a partial right-sided defect in the pericardium as seen in our case (9). Many of the cases had other malformations in the lung and vessels.

Though pericardial defects are usually asymptomatic, it is sometimes associated with increased mobility and stress on anchoring structures of the heart, resulting in local inflammation and chest pain. There are also occasional reports of sudden death due to herniation of the heart (4,22).

We performed a review of the Japanese literature between 1963 to April 2013. There were 28 reports on pericardial defects found during thoracic surgery. Mean age was 33.5 years and 24 were male. Nine had pneumothorax, four had cystic lung disease, three had lung cancer and three had BCs. Sixteen had complete left sided defects, 11 had partial defects on the left and 1 was right sided. Eight developed complications related to surgery, among which, two had cardiac arrest, two had arrhythmia, and two developed phrenic nerve palsy (Table 1) (23-30). Reconstruction of the pericardium was performed in six

patients. All had left sided deficiencies, among which two had a partial defect of around 5 cm in diameter. In most of the cases, reconstruction was performed to prevent strangulation from partial defects or because of a major decrease in lung volume, which threatened to lead to large displacement of the heart (Table 2) (25,26,31-34).

In conclusion, congenital pericardial defects are often found in association with other thoracic anomalies. Techniques to prevent arrhythmias and sudden death should be considered in some cases when large amounts of adjacent structures are removed during surgery.

Acknowledgements

None.

Footnote

Conflicts of Interest: The authors have no conflicts of interest to declare.

Informed Consent: Written informed consent was obtained from the patient for publication of this manuscript and any

Table 1 Reports on congenital pericardial defects found during thoracic surgery with surgical complications

Author	Age (year)	Sex	Disease	Operation	Pericardial defect	Complication
Yamamoto (23)	6	M	Bronchogenic cyst	Lung partial resection	Lt. comp	Cardiac arrest
Kakimoto (24)	11	M	Pectus excavatum	Sternal turnover	Lt. comp	Arrhythmia
Honda (25)	14	F	Bronchogenic cyst	Lt. upper lobectomy	Lt. comp	Cardiac arrest
Fuwa (26)	68	F	Diaphragmatic paralysis	Plication	Lt. comp	Arrhythmia phrenic N. palsy
Tsukada (27)	61	M	Lung cancer	Lt. upper lobectomy	Lt. comp	Atelectasis
Negoto (28)	17	M	Bronchial injury	Lt. lung resection	Lt. comp	Empyema
Takizawa (29)	22	F	Giant bulla	Bulla resection	Lt. comp	Angina
Ogawa (30)	52	M	Diaphragmatic paralysis	Plication	Lt. part	Phrenic N. palsy
Present case	69	F	Bronchogenic cyst	Cystectomy	Rt. part	Arrhythmia

Lt., left; Rt., right; comp, complete; part, partial; N., nerve.

Table 2 Reports on pericardial reconstructions performed in patients with pericardial defects associated with thoracic surgery

Author	Age (year)	Sex	Disease	Operation	Pericardial defect	Reason of reconstruction
Honda (25)	14	F	Bronchogenic cyst	Lt. upper lobectomy	Lt. comp	CPA on position change
Takanami (31)	17	M	Lt. pneumothorax	Lung partial resection	Lt. part	Herniation during surgery
Fuwa (26)	68	F	Diaphragmatic paralysis	Plication	Lt. comp	Prevention of friction and pericarditis
Ikeda (32)	53	M	Infected bulla	Bulla resection	Lt. comp	Low residual lung volume
Yamaguchi (33)	74	M	Inflammatory pseudo tumor	Lt. upper lobectomy + partial resection	Lt. comp	Low residual lung volume
Hamaguchi (34)	23	M	Lt. pneumothorax	Lung partial resection	Lt. part	Prevention of herniation

Lt., left; comp, complete; part, partial; CPA, cardiopulmonary arrest.

accompanying images.

References

- Shanmugam G. Adult congenital lung disease. *Eur J Cardiothorac Surg* 2005;28:483-9.
- Barua A, Rizig M, Davidson L, et al. Pulmonary infarction complicating thoroscopic removal of congenital foregut cyst. *Eur J Cardiothorac Surg* 2014;46:329-30.
- Southworth H, Stevenson CS. Congenital defects of the pericardium. *Arch Intern Med* 1938;61:223-40.
- Ellis K, Leeds NE, Himmelstein A. Congenital deficiencies in the parietal pericardium: a review with 2 new cases including successful diagnosis by plain roentgenography. *Am J Roentgenol Radium Ther Nucl Med* 1959;82:125-37.
- Rusby NL, Sellors TH. Congenital deficiency of the pericardium associated with a bronchogenic cyst. *Br J Surg* 1945;32:357-64.
- Somwaru LL, Midgley FM, Di Russo GB. Intrapericardial bronchogenic cyst overriding the pulmonary artery. *Pediatr Cardiol* 2005;26:713-4.
- Solomon V, Rajesh PB, Isaac DD, et al. Congenital pericardial defect with accessory lobules in the lung and patent ductus arteriosus: a case report. *Indian Heart J* 1979;31:61-3.
- Imperatori A, Rotolo N, Nardecchia E, et al. Bronchogenic cyst associated with pericardial defect: case report and review of the literature. *J Cardiothorac Surg* 2011;6:85.
- Victor S, D DI. Congenital partial pericardial defect on the right side associated with a bronchogenic cyst. A case report. *Indian Heart J* 1981;33:34-6.
- Mukerjee S. Congenital partial left pericardial defect with a bronchogenic cyst. *Thorax* 1964;19:176-9.
- Jones P. Developmental defects in the lungs. *Thorax* 1955;10:205-13.
- Kassner EG, Rosen Y, Klotz DH Jr. Mediastinal esophageal duplication cyst associated with a partial pericardial defect. *Pediatr Radiol* 1975;4:53-6.
- Fusonie D, Molnar W. Anomalous pulmonary venous

- return, pulmonary sequestration, bronchial atresia, aplastic right upper lobe, pericardial defect and intrathoracic kidney. An unusual complex of congenital anomalies in one patient. *Am J Roentgenol Radium Ther Nucl Med* 1966;97:350-4.
14. Ratib O, Perloff JK, Williams WG. Congenital complete absence of the pericardium. *Circulation* 2001;103:3154-5.
 15. Hamilton LC. Congenital deficiency of the pericardium. A case report of complete absence of the left pericardium. *Radiology* 1961;77:984-6.
 16. Warner CL, Britt RL, Riley HD Jr. Bronchopulmonary sequestration in infancy and childhood. *J Pediatr* 1958;53:521-8.
 17. Lonský V, Stětina M, Habal P, et al. Congenital absence of the left pericardium in combination with left pulmonary artery hypoplasia, right aortic arch, and secundum atrial septal defect. *Thorac Cardiovasc Surg* 1992;40:155-7.
 18. Ozpolat B, Doğan OV. Absence of pericardium in combination with bronchogenic cyst, atrial septal defect, mitral valve prolapsus and hypospadias. *Anadolu Kardiyol Derg* 2009;9:E16-7.
 19. Kwak DL, Stork WJ, Greenberg SD. Partial defect of the pericardium associated with a bronchogenic cyst. *Radiology* 1971;101:287-8.
 20. Eom DW, Kang GH, Kim JW, et al. Unusual bronchopulmonary foregut malformation associated with pericardial defect: bronchogenic cyst communicating with tubular esophageal duplication. *J Korean Med Sci* 2007;22:564-7.
 21. Leijala M, Louhimo I. Extralobar sequestration of the lung in children. *Prog Pediatr Surg* 1987;21:98-106.
 22. Van Son JA, Danielson GK, Schaff HV, et al. Congenital partial and complete absence of the pericardium. *Mayo Clin Proc* 1993;68:743-7.
 23. Yamamoto H, Hatanaka R, Chiu AF, et al. Congenital defect of the pericardium. *Nihon Kyobu Shikkan Gakkai Zasshi* 1973;11:16-21.
 24. Kakimoto S, Shiguma S, Sasaki M, et al. Three cases of congenital complete left pericardial defect. *Nihon Kyobu Geka Gakkai Zasshi* 1982;30:1637-41.
 25. Honda M, Endo Y, Inoue H. A case of congenital complete absence for left pericardium. *J Jpn Surg Assoc* 1985;46:1090-5.
 26. Fuwa S, Takiya H, Uji S, et al. A case of congenital absence of the left pericardium associated with relaxation of the diaphragm and supraventricular tachycardia. *Jpn J Chest Dis* 1990;49:792-7.
 27. Tsukada H, Ogawa I, Yamabe K, et al. A case of congenital complete left pericardial defect found at operation for left lung cancer. *Jpn J Chest Surg* 1989;3:379-83.
 28. Negoto Y, Migita H, Ito F, et al. A case of traumatic tracheal laceration associated with pericardial defect. *Kanto J Jpn Assoc Acute Med* 1989;10:758-9.
 29. Takizawa H, Ishikura H, Kimura S, et al. Giant pulmonary cyst associated with congenital pericardial defect. *Gen Thorac Cardiovasc Surg* 2007;55:65-8.
 30. Ogawa J, Nagashima H, Suhara M, et al. A case of left phrenic nerve paralysis caused by compression of the left auricle due to congenital partial left pericardial defect. *Nihon Kokyuki Gakkai Zasshi* 2009;47:200-4.
 31. Takanami I, Nakamura T, Ohnishi H, et al. A case of congenital partial defect of the left pericardium complicated with spontaneous pneumothorax and pneumocardium. *Jpn J Chest Dis* 1987;46:84-7.
 32. Ikeda N, Iwanami H, Narita K, et al. Congenital complete left pericardial defect and giant bulla of the lung repaired surgically; a case report. *Jpn J Chest Surg* 1991;5:782-7.
 33. Yamaguchi A, Yoshida S, Ito T. Cardiac displacement after lobectomy in a patient with a congenital complete left-sided pericardial defect. *Jpn J Thorac Cardiovasc Surg* 2001;49:317-9.
 34. Hamaguchi N, Fujishima N, Tanida N, et al. A case of congenital partial pericardial defect associated with spontaneous pneumothorax and pneumopericardium. *Jpn J Chest Surg* 2002;16:45-8.

Cite this article as: Kamata T, Yoshida S, Iwata T, Nakatani Y, Yoshino I. Giant bronchogenic cyst with pericardial defect: a case report & literature review in Japan. *J Thorac Dis* 2016;8(8):E684-E688. doi: 10.21037/jtd.2016.06.65