



The role of 3D printing in chest wall reconstruction

Marcelo Martinez-Ferro^{1,2^}, Gaston Bellia-Munzon^{1,2^}, Luzia Toselli^{1,2^}, Daniela Sanjurjo^{1,2^}

¹Fundacion Hospitalaria Mother and Child Medical Center, Buenos Aires, Argentina; ²Clinica Mi Pectus, Capital Federal, Buenos Aires, Argentina

Contributions: (I) Conception and design: M Martinez-Ferro, G Bellia-Munzon, L Toselli; (II) Administrative support: L Toselli, D Sanjurjo; (III) Provision of study materials or patients: All authors; (IV) Collection and assembly of data: M Martinez-Ferro, G Bellia-Munzon, L Toselli; (V) Data analysis and interpretation: M Martinez-Ferro, G Bellia-Munzon, L Toselli; (VI) Manuscript writing: All authors; (VII) Final approval of manuscript: All authors.

Correspondence to: Luzia Toselli, MD. Fundacion Hospitalaria Mother and Child Medical Center, Av. Crámer 4602, Buenos Aires, Argentina; Clinica Mi Pectus, Capital Federal, Buenos Aires, Argentina. Email: dra.luzia.toselli@gmail.com.

Abstract: Technology is advancing fast, and chest wall surgery finds particular benefit in the broader availability of three-dimensional (3D) reconstruction and printing. An increasing number of reports are being published on the use of these resources in virtual 3D reconstructions of chest walls in computed tomography (CT) scans, virtual surgeries, 3D printing of real-size models for surgical planning, practice, and education, and of note, the manufacture of customized 3D printed implants, changing the fundamental conception from a surgery that fits all, to a surgery for each patient. In this review, we explore the evidence published on simple chest wall reconstruction, including the use of 3D technology to assist in the improvement of the repair of the most frequent chest wall deformities: pectus excavatum and carinatum. Current studies are oriented to the automatization and customization of transthoracic implants, as well as education on real-size models. Next, we investigate the implementation of 3D printing in the repair of complex chest wall reconstruction, comprised of infrequent chest wall deformities such as pectus arcuatum and Poland syndrome. These malformations are very heterogeneous resulting in a high degree of improvisation during the surgical repair. In this setting, 3D technology plays a role in the standardization of a process that contemplates customization, concepts that may seem contradictory. Finally, 3D printing with biocompatible materials is rapidly becoming the first choice for the reconstruction of wide chest wall oncological resections. In this work, we review the first and most important current publications on the subject.

Keywords: Three-dimensional printing (3D printing); implant customization; pectus excavatum (PE); pectus carinatum (PC); pectus arcuatum

Submitted May 31, 2023. Accepted for publication May 08, 2024. Published online Jun 24, 2024.

doi: 10.21037/jtd-23-881

View this article at: <https://dx.doi.org/10.21037/jtd-23-881>

Introduction

The use of three-dimensional (3D) technology and preoperative simulation constitute modern technological and methodological resources that are being increasingly incorporated into the routine surgical practice of chest wall surgeons. Surgical specialties such as cardiac, vascular, orthopaedical, and craniomaxillofacial surgery have

already begun to implement these tools with vast clinical implications (1-7).

Standardization of surgical procedures might minimize or even eradicate intraoperative improvisation. However, planning and standardization of the repair of complex chest wall malformations is challenging given their inherent heterogeneity. 3D technology offers a unique alternative for

[^] ORCID: Marcelo Martinez-Ferro, 0000-0001-7704-0092; Gaston Bellia-Munzon, 0000-0002-8533-6384; Luzia Toselli, 0000-0002-6169-0303; Daniela Sanjurjo, 0000-0002-2801-8793.

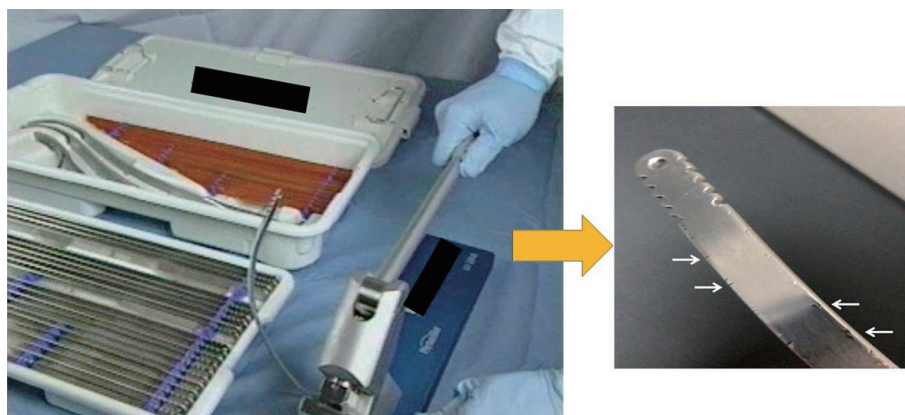


Figure 1 Implant bending during surgery. White arrows show scratches and notches of the implant after mechanical intraoperative bending.

simultaneous treatment standardization and customization.

In the last few years, there has been increasing interest on this subject, though with publications mostly involving case reports or small case series. In this review, we explore the current knowledge about the application of 3D technology for simple and complex chest wall reconstructions.

Simple chest wall reconstruction

Under this term, we refer to the use of 3D technology to aid in the resolution of simple chest wall deformities such as pectus excavatum (PE) and pectus carinatum (PC). Although these are far more prevalent than complex chest wall reconstructions, few studies have reported the implementation of 3D technology for the resolution of these malformations.

Regarding the minimally invasive repair of PE (MIRPE), although there have been many improvements to the original technique, decisions related to the number, location, and direction of implants are still made in the operating room with the patient under general anesthesia. This results in a time-consuming procedure that may lead, especially in the case of less experienced surgeons, to a wrong selection of the length and configuration of the implants, thus requiring extensive re-bending, removal, and repetitive flipping of the bars. Also, bending the implant during surgery prompts the creation of scratches and notches that have been related to bleeding complications during the procedure or at bar removal (*Figure 1*).

However, the aforementioned setbacks may be addressed using 3D technology. On one hand, the 3D virtual reconstruction from a computed tomography (CT) chest

scan enables the surgical team to elaborate a detailed preoperative plan, including the number of implants required, their direction, and their entry points to the thoracic cavity (*Figure 2*). Computer programs have been developed to determine the precise length and shape of the prescribed implants and Standard Triangle Language (STL) files can be created for 3D printing of templates in materials such as polylactic acid that can be used for implant customization (*Figure 3*). On the other hand, 3D printing of real-size models of the chest wall or even the complete thoracic cage is being used for simulation, education, or tailored implant template manufacture as well.

Using this approach, some authors have reported their initial experience in case reports or small case series. In 2018, Matsuo *et al.* published the 3D printing and reconstruction of the anterior chest wall of a PE patient, with preoperative simulation of the surgery, and further performing the procedure as planned (8). In 2022, Shan *et al.* described a larger cohort of 10 PE patients whose complete thoracic cages were 3D-printed for preoperative simulation and education of the patients and their families (9).

Other groups have extended the utility of this resource and used it not only for simulation but also for implant customization. Lai *et al.* reported in 2009 the use of CT versus the traditional method to determine implant length and the curvature of the malleable implant intraoperatively with increased accuracy and fewer errors than bending the bar intraoperatively (10). Lin *et al.* reported in 2018, 10 patients in whom they designed the implants virtually based on the CT 3D reconstruction, 3D printed the templates, and shaped the implants accordingly, through a process named 3DPMAN (11). In 2020 Wang *et al.* and Gaspar Perez *et al.*

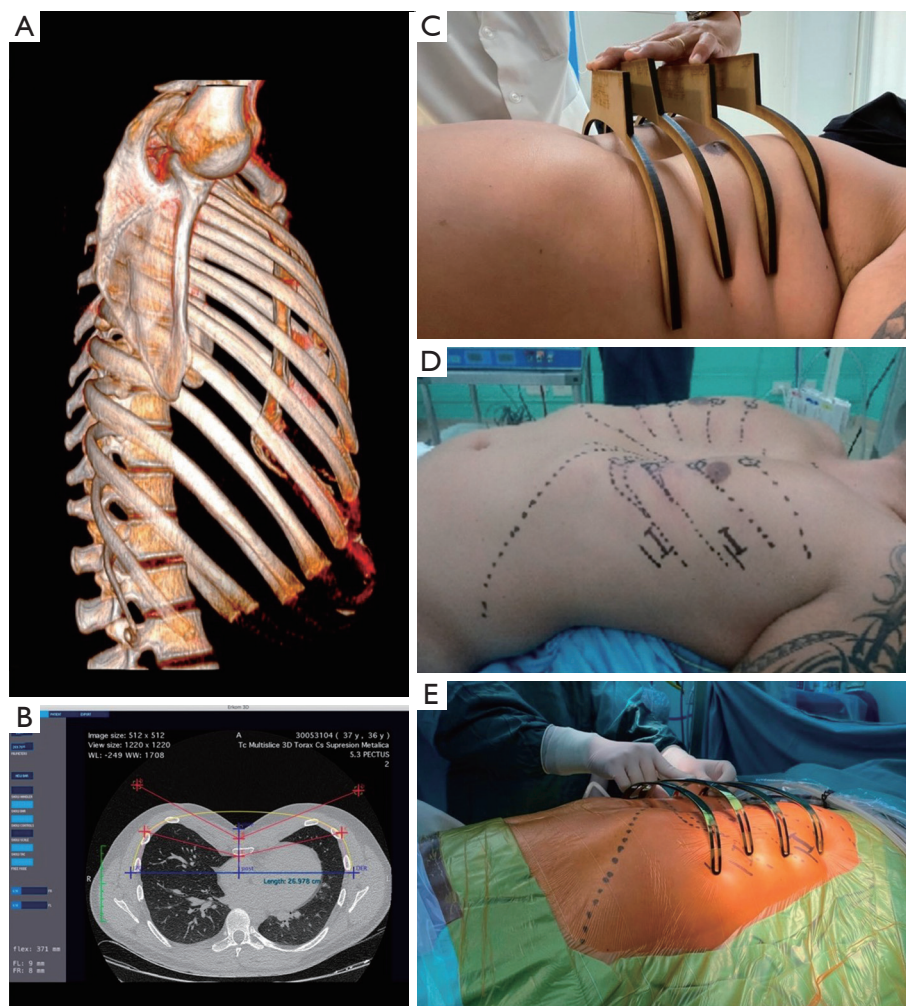


Figure 2 The preoperative planning of our patients undergoing minimally invasive repair of pectus excavatum is comprised of several steps. (A) Chest wall 3D virtual reconstruction from a CT; (B) virtual implant design using a semiautomatic software (Erkom 3D Chest Wall Pro 1.3, Pampamed, Buenos Aires, Argentina) that was specifically developed for this purpose; (C) during a dedicated fitting session at the outpatient clinic, 3D printed, customized, polylactic acid templates are checked on the patients' chest wall; (D) marking of the patient showing the intercostal spaces, as well as the implants' entry and exit points of the thoracic cavity; (E) final trial of the implants in the operation room. 3D, three-dimensional; CT, computed tomography.



Figure 3 Based on the virtual design of the customized implant using the chest CT of patient in end-expiration phase (A), a virtual template is designed (B), and 3D printed in polylactic acid (C). This template will be checked on the patient's chest wall preoperatively. CT, computed tomography; 3D, three-dimensional.

in 2021, they both reported 6 cases each performed with the same approach: 3D printing of the rib cage and the anterior aspect of the affected chest wall, respectively, and implant customization with optimal results (12,13).

However, the most extensive experiences were published by Vilaça *et al.* in 2014, Huang *et al.* in 2019, and Bellia-Munzon *et al.* in 2020 (14-16). Vilaça reported the creation of automatic pre-bent customized prostheses for patients undergoing MIRPE. They automatically manufactured and introduced 41 implants in 41 patients, and at the time of publication, 15 bars had been removed. In 2019, Huang performed 15 simulations of MIRPE in 3D printed real-size

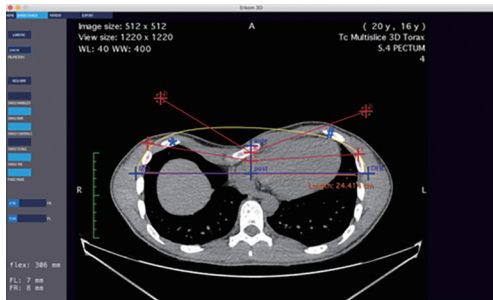


Figure 4 Implant design using the semiautomatic software mentioned in *Figure 2*. The yellow line represents the implant. Note that the line passes above on the right (*) and below on the left of the anterior costal line (#), so designed to compensate this particular patient's hemithoracic asymmetry.

models and implant customization and compared them with 342 other MIRPE cases. They found that the 3D printing group had a shorter operative time (60 versus 74 minutes, $P < 0.001$), fewer metallic bar placements (1.00 versus 1.36 bars, $P < 0.001$), and better improvement percentages in the Haller indices (20.3% versus 10.1%, $P < 0.001$) compared with the traditional Nuss procedure.

Finally, Bellia-Munzon *et al.* published the largest series including 130 patients systematically diagnosed and treated employing 3D technology in the process. This process consisted of the following:

- (I) Preoperative planning using 3D CT scan reconstruction and printing of an implant template based on the CT data (*Figure 4*),
- (II) An ambulatory fitting session with the custom 3D printed templates (*Figure 5*), and
- (III) Manufacture of a final, custom-made, pre-bent metallic implant based on the template configuration (*Figure 6*).

They found that 120 (92.3%) had an optimal “implant-deformity” anatomic match requiring no modification and minimal modifications in 10 cases, 7 minimal re-bending without bar flipping, 1 that required bar flipping and removal once, and 2 shorter than necessary. Also, they compared these cases with a historic cohort with the traditional approach and found a significant reduction in the operative time (87.6 ± 49.9 vs. 125.4 ± 30.7 minutes; $P < 0.0001$) with a further decrease when adjusted to the number of bars

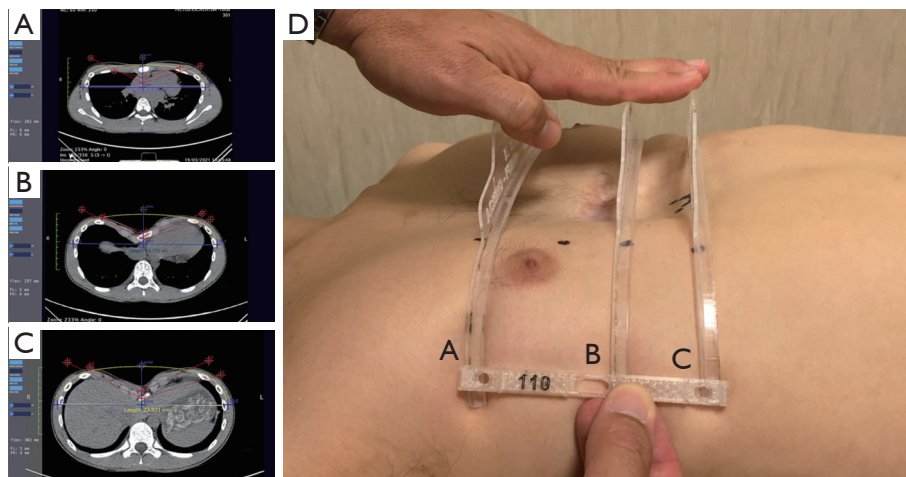


Figure 5 Customized implant template trial at the fitting session. (A-C) Virtual implants' design on a chest CT (A: superior, B: middle, C: inferior implant); (D) if the templates fit correctly, manufacturing is authorized and the customized, metallic implants are made and sterilized, ready for surgical use. If not, the necessary modifications are communicated, the templates are adjusted, and rechecked. CT, computed tomography.



Figure 6 Custom-made, pre-bent metallic implants personalized for the patient. Note the mirror-polished surface of the implants without scratches and notches.

per operation (41.8 ± 14.7 vs. 78.1 ± 31.7 minutes per implant; $P < 0.0001$).

Regarding PC, the extensive use of braces has reduced the number of surgical candidates. However, in 2022 Martinez-Ferro *et al.* published the implementation of 3D technology in the minimally invasive repair of PC (17). They reported its use in the diagnosis with a 3D reconstruction of the chest CT, virtual implant design, template 3D printing and checking, and customized implant manufacture. They applied this process in 9 cases with no intraoperative complications.

Complex chest wall reconstruction

Complex chest wall deformities include the excavatum/carinatum complex, pectus arcuatum, and the Poland Syndrome. Other complex reconstructions comprise those after extensive oncological resections that involve three or more adjacent ribs or the sternum.

Reconstruction for complex deformities

Despite the increasing implementation and usefulness of 3D technology in chest wall reconstructions, publications on the resolution of complex deformities are relatively rare.

In 2019, Leng *et al.* reported using computer-aided designed (CAD), 3D printed cutting templates in four patients with pectus arcuatum with optimal results (18). The wedge sternotomies and cutting templates were planned and designed virtually using 3D reconstructions of CT scans and then 3D printed.

In 2021, Martinez *et al.* published seven cases with complex chest wall deformities approached with a process

using 3D technology between 2015 and 2020 (19). Diagnosis included isolated Poland syndrome ($n=1$), pectus arcuatum ($n=2$), Poland syndrome associated with pectus arcuatum ($n=3$), and carinated deformity with complex sternal malformation ($n=1$).

The therapeutic process was comprised of the following steps:

- (I) Preoperative planning.
Using 6 medical photographs and the results of chest CT and 3D reconstruction as well as optical surface scan, patients were discussed in a multidisciplinary setting (Figure 7). The surgical plan was elaborated, including approach, need for sternal osteotomies and remodeling, sternal plates, chondral resection, prosthetic ribs, or retrosternal implants (Figure 8).
- (II) CT post-processing and 3D printing, simulation, and implant check.
CT post-processing and 3D printing of real-size models of the chest wall or areas of interest, such as the sternum and affected ribs in polylactic acid, were done. Simulation included wedge osteotomies using customized cutting guides, evaluation of thoracic stability, and concordance between plates and implants was checked (Figure 9). If intrathoracic implants were necessary, templates were 3d printed and checked on the patient during a fitting session.
- (III) Implant manufacturing and surgery.
Once the plates and templates were approved, titanium customized implants were manufactured (Figure 10). Later, the surgery was duly performed according to a detailed, stepwise plan (Figure 11).

The authors reported complete agreement and no need to re-bend or modify the implants during surgery.

Finally, Chavoin *et al.* also reported the usefulness of 3D printing in chest wall deformities in 2022, in a study comprising 638 with PE and 151 with Poland syndrome (20). Assisted by a computer-aided design and manufacturing, they used customized silicone elastomer implants to reshape their chest walls.

Reconstruction after oncological chest wall resections

Unlike complex chest wall deformities, the use of 3D technology for reconstruction after wide oncological thoracic resections has been extensively published in the

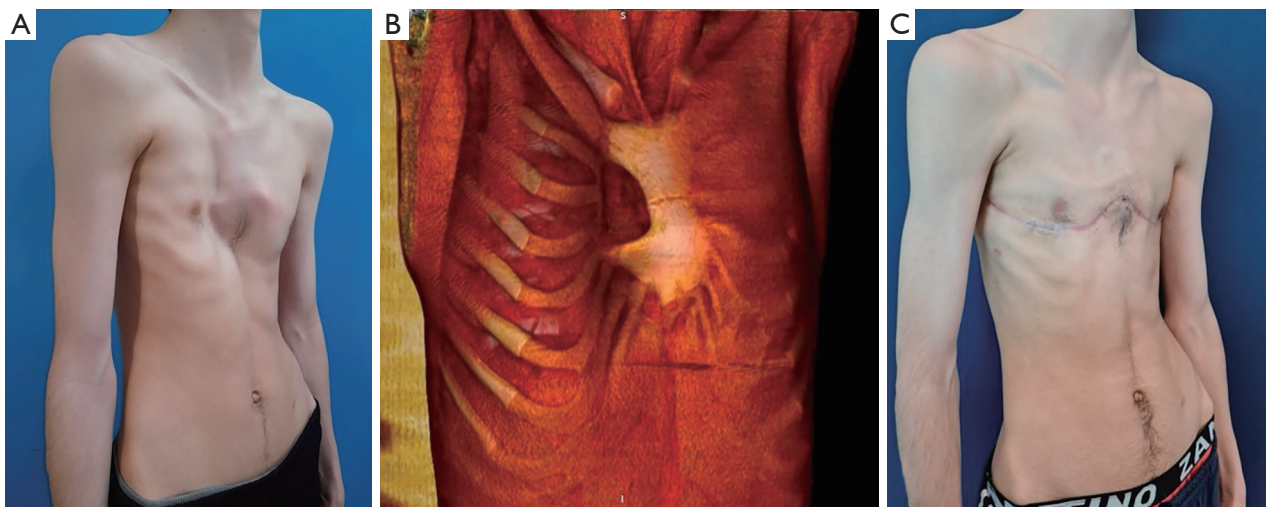


Figure 7 Complex patient with Poland Syndrome, pectus excavatum, sternal deformity, and chondral agenesis. (A) Preoperative, medical photograph showing extensive asymmetric deformity. (B) 3D-CT reconstruction showing the rotated sternum with a right defect and right chondral agenesis causing a lung herniation. (C) Postoperative photograph showing symmetric hemithoraxes and correction of prior pectus excavatum. 3D, three-dimensional; CT, computed tomography.

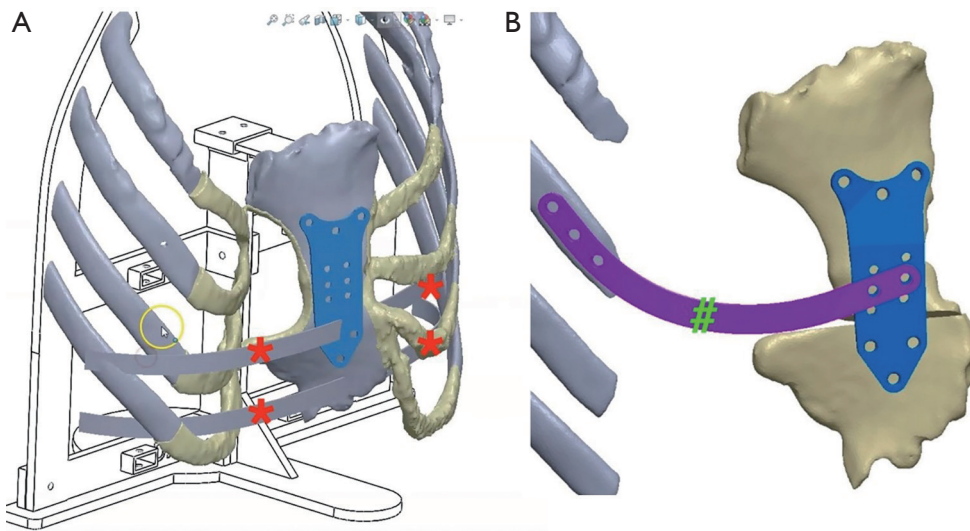


Figure 8 Virtual 3D reconstruction and implant design from patient with Poland syndrome, pectus excavatum, and chondral agenesis shown in *Figure 7*. (A) Retrosternal implants' design (asterisks). (B) Prosthetic rib (#) and sternal plate's design. 3D, three-dimensional.

last ten years for surgical planning, simulation, prostheses design, 3D printing of implants, and also education (21-35). In general, the aims of reconstruction include defect coverage, adequate implant anchoring, and preservation of functionality (*Figure 12*), especially when lower chest wall resections are made and normal excursion may be impaired by rigid prosthesis. In this sense, several authors explore increasing

implant flexibility by means of 3D printed prosthesis made of different materials.

Among the main case series employing 3D technology, Wu *et al.* published in 2018, six cases with large chest wall tumors with a mean age of 43.2 ± 23.8 years (28). They used CT scans to 3D print real-size models in which they simulated the resection and designed the prostheses.




Figure 9 Simulation of wedge sternotomies. This procedure enables the chest wall surgeon to determine the height, depth, and direction of the sternotomy needed to achieve the best sternal reconfiguration possible. Cutting guides are then designed and printed to facilitate the reproduction of the simulated sternotomy on the operative table. (A) First test simulating a wedge sternotomy, frontal view; (B) second test simulating a different wedge sternotomy on a duplicate model of the sternum in panel A, lateral view; (C) customized cutting guide on 3D printed sternum.

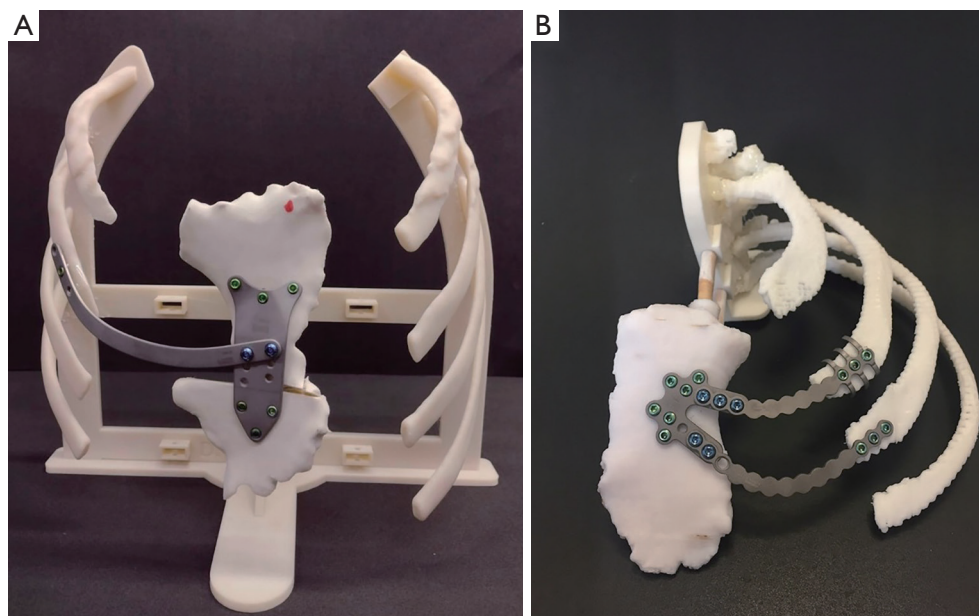


Figure 10 Examples of 3D real-sized, polylactic acid chest wall models of complex patients repaired with titanium, customized implants. (A) This patient required a sternal plate and a single titanium rib to bridge and cover the lung herniation; (B) this second patient had a wider chondral defect that was repaired using a customized sterno-bicostal prostheses. 3D, three-dimensional.

Subsequently, they manufactured conformal titanium plates, simulated the reconstruction, and posteriorly applied them in surgery. They reported good postoperative activity and respiratory movements. In 2019, Wang *et al.* reported for the first time sternal repair in 8 patients and rib

reconstruction in 10 patients with large tumors using 3D printed polyetheretherketone (PEEK) prostheses (33). They fixated the PEEK implants with wire or titanium screws, on the inner surface a pericardial patch was densely suspended and sutured to the adjacent pleura, and a myofascial flap

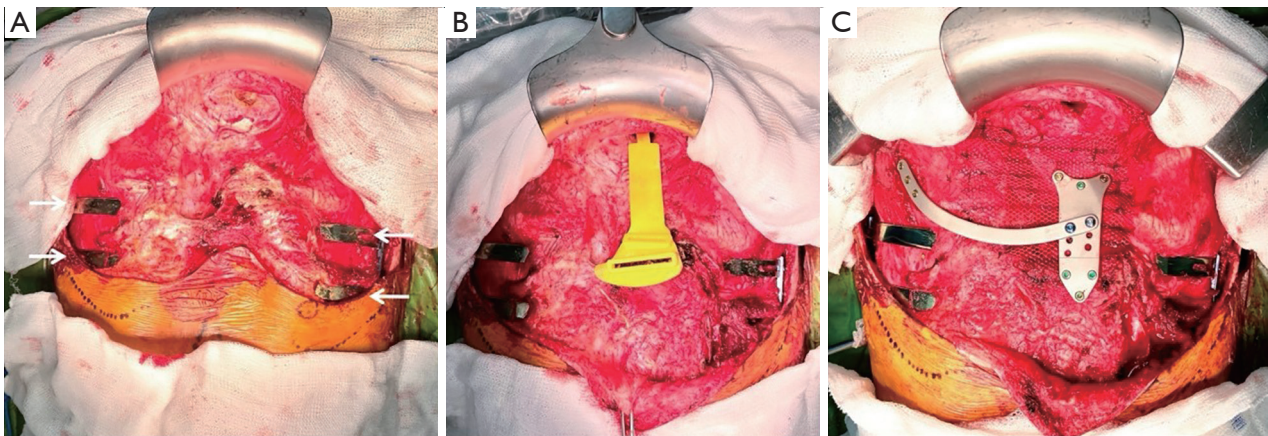


Figure 11 Stepwise surgical procedure according to preoperative plan of a patient with Poland syndrome and pectus excavatum. In this case, panel (A) shows the final location of retrosternal implants (white arrows) to correct the pectus excavatum; (B) the cutting guide is located on the sternum in order to perform a wedge osteotomy after the 2nd and 3rd parasternal cartilages are resected; (C) sternal and rib titanium implants after fixation, lying on top of a mesh.

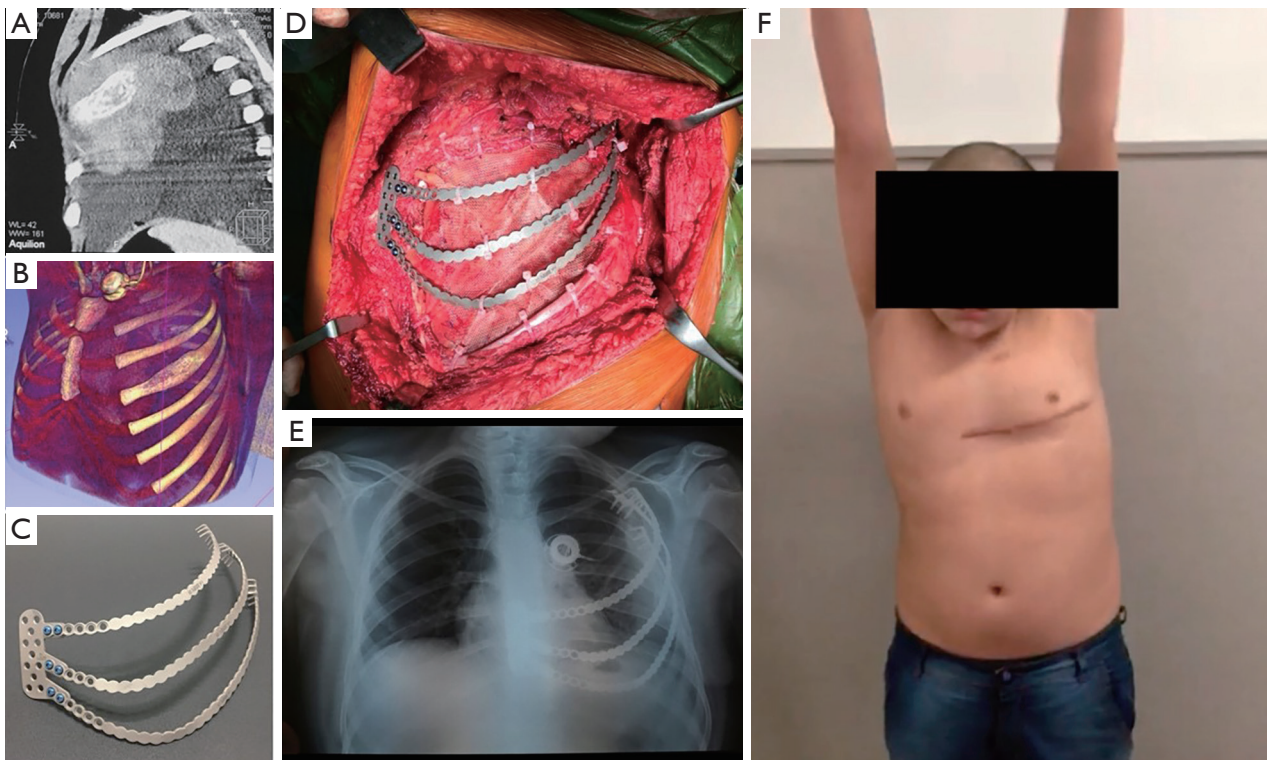


Figure 12 Preoperative planning, implant customization, surgery, and postoperative results of a pediatric patient with an Ewing sarcoma of his 4th left rib requiring a wide chest wall resection. (A) Chest CT scan showing rib involvement by the tumor. (B) 3D CT reconstruction where the extension of the tumor can be easily comprehended. (C) Customized, titanium sterno-costal prosthesis comprised of a sternal plate and three separate ribs. (D) Intraoperative view of the prosthesis already fixated after wide chest wall resection, covering a non-absorbable mesh. (E) Front chest X-ray, showing the metallic implants, good lung expansion, and a port-a-cath. (F) The patient at the 1-month postoperative visit to the outpatient clinic. He is moving his arms freely and his chest is symmetric. CT, computed tomography; 3D, three-dimensional.

covered the outer surface. In 2020, Tan *et al.* treated 34 patients with sizeable chest wall tumors and randomly divided them into two groups: one with the conventional approach and the research group, approached with the inclusion of 3D technology for simulation and printing (23). The duration of surgery, the accuracy of surgical route prediction, and bleeding volume in the research group were significantly lower, although there was no difference in the length of stay. Lastly, Pontiki *et al.* published in 2022 their experience in ten patients who underwent large chest wall tumor resection (27). They 3D printed silicone molds of the planned resection areas and manufactured customized methyl methacrylate implants. Compared with a simultaneous cohort of patients repaired with non-rigid meshes, patients showed a trend towards better cosmetics, improved breathing mechanics, and a higher quality of life.

Future directions include increasing accessibility of 3D technology, lower costs, and the development of processes that reduce the time required to manufacture 3D models and implants. Also, evidence-based data is necessary to provide firm support in investment in new technologies that enhance optimal medical results.

Creation of a 3D model based on preoperative CT images

As an example of the application of 3D technology and printing in the repair of the chest wall, the following steps illustrate the creative process of PE implants in our clinical experience within an institution dedicated to chest malformations.

- ❖ Step 1: image acquisition: based on non-contrast chest CT scans at end-expiration (80 kV, slice thickness 2.0 mm, increment 1.0 mm) (36).
- ❖ Step 2: determination of the number of implants required depending on the patient's age, presence of chondral calcifications, and Titanic Index (37). The direction and position of the implants are planned according to the definition of target areas necessary to treat in order to achieve total chest wall remodeling and whether the sternum is shaped as a banana or not (13).
- ❖ Step 3: prostheses design: using specially designed software (Erkom 3D Pro, Buenos Aires, Argentina), a semiautomatic process is performed to determine to precise length and shape of the implants. Next, STL files are created and the implants' templates are 3D printed.

- ❖ Step 4: an ambulatory fitting session is organized to test the templates on the patient's chest wall. If they fit correctly, metallic prebent implants are manufactured with steel or titanium depending on an allergy test.
- ❖ Step 5: the customized prebent mirror-polished sterile implants are delivered to the operation room for surgery.

Conclusions

3D technology has become increasingly available to the chest wall surgeon allowing for various practices that may enhance surgical planning through simulation in tailored, real-size phantoms, and the design and manufacture of customized implants. This approach might enable greater surgical precision and reduced improvisation, allowing for a better implant/deformity match, and potentially decreasing operative time. As this technology evolves and becomes available to a broader public, more chest wall teams should consider including them in their practices.

Acknowledgments

Funding: None.

Footnote

Provenance and Peer Review: This article was commissioned by the Guest Editors (Erik de Loos, José Ribas de Campos and Jean Daemen) for the series “Chest Wall Resections and Reconstructions” published in *Journal of Thoracic Disease*. The article has undergone external peer review.

Peer Review File: Available at <https://jtd.amegroups.com/article/view/10.21037/jtd-23-881/prf>

Conflicts of Interest: All authors have completed the ICMJE uniform disclosure form (available at <https://jtd.amegroups.com/article/view/10.21037/jtd-23-881/coif>). The special series “Chest Wall Resections and Reconstructions” was commissioned by the editorial office without any funding or sponsorship. M. M. F. reports ownership of Pampamed SRL. G. B. M. reports pending patents from Pampamed SRL. The authors have no other conflicts of interest to declare.

Ethical Statement: The authors are accountable for all aspects of the work in ensuring that questions related

to the accuracy or integrity of any part of the work are appropriately investigated and resolved. All clinical procedures described in this study were conducted in accordance with the Declaration of Helsinki (as revised in 2013). As a narrative review, this manuscript does not require ethics committee approval. Informed consent was obtained from all individual participants whose images were used in this manuscript.

Open Access Statement: This is an Open Access article distributed in accordance with the Creative Commons Attribution-NonCommercial-NoDerivs 4.0 International License (CC BY-NC-ND 4.0), which permits the non-commercial replication and distribution of the article with the strict proviso that no changes or edits are made and the original work is properly cited (including links to both the formal publication through the relevant DOI and the license). See: <https://creativecommons.org/licenses/by-nc-nd/4.0/>.

References

1. Khorsandi D, Fahimipour A, Abasian P, et al. 3D and 4D printing in dentistry and maxillofacial surgery: Printing techniques, materials, and applications. *Acta Biomater* 2021;122:26-49.
2. Zoabi A, Redenski I, Oren D, et al. 3D Printing and Virtual Surgical Planning in Oral and Maxillofacial Surgery. *J Clin Med* 2022;11:2385.
3. Rodriguez Colon R, Nayak VV, Parente PEL, et al. The presence of 3D printing in orthopedics: A clinical and material review. *J Orthop Res* 2023;41:601-13.
4. Feng Y, Zhu S, Mei D, et al. Application of 3D Printing Technology in Bone Tissue Engineering: A Review. *Curr Drug Deliv* 2021;18:847-61.
5. El Sabbagh A, Eleid MF, Al-Hijji M, et al. The Various Applications of 3D Printing in Cardiovascular Diseases. *Curr Cardiol Rep* 2018;20:47.
6. Verghe E, Catanese V, Nenna A, et al. 3D Printing in Cardiovascular Disease: Current Applications and Future Perspectives. *Surg Technol Int* 2021;38:314-24.
7. Ganguli A, Pagan-Diaz GJ, Grant L, et al. 3D printing for preoperative planning and surgical training: a review. *Biomed Microdevices* 2018;20:65.
8. Matsuo N, Matsumoto K, Taura Y, et al. Initial experience with a 3D printed model for preoperative simulation of the Nuss procedure for pectus excavatum. *J Thorac Dis* 2018;10:E120-4.
9. Shan Y, Yu G, Lu Y, et al. Application of three-dimensional reconstruction technology combined with three-dimensional printing in the treatment of pectus excavatum. *Ann Thorac Med* 2022;17:173-9.
10. Lai JY, Wang CJ, Chang PY. The measurement and designation of the pectus bar by computed tomography. *J Pediatr Surg* 2009;44:2287-90.
11. Lin KH, Huang YJ, Hsu HH, et al. The Role of Three-Dimensional Printing in the Nuss Procedure: Three-Dimensional Printed Model-Assisted Nuss Procedure. *Ann Thorac Surg* 2018;105:413-7.
12. Wang L, Guo T, Zhang H, et al. Three-dimensional printing flexible models: a novel technique for Nuss procedure planning of pectus excavatum repair. *Ann Transl Med* 2020;8:110.
13. Gaspar Pérez M, Núñez García B, Álvarez García N, et al. Initial experience with 3D printing in the use of customized Nuss bars in pectus excavatum surgery. *Cir Pediatr* 2021;34:186-90.
14. Bellia-Munzon G, Martinez J, Toselli L, et al. From bench to bedside: 3D reconstruction and printing as a valuable tool for the chest wall surgeon. *J Pediatr Surg* 2020;55:2703-9.
15. Vilaça JL, Rodrigues PL, Soares TR, et al. Automatic prebent customized prosthesis for pectus excavatum minimally invasive surgery correction. *Surg Innov* 2014;21:290-6.
16. Huang YJ, Lin KH, Chen YY, et al. Feasibility and Clinical Effectiveness of Three-Dimensional Printed Model-Assisted Nuss Procedure. *Ann Thorac Surg* 2019;107:1089-96.
17. Martinez-ferro M. Minimally Invasive Pectus Carinatum Repair. Second Ed. Holcomb III GW, Rothenberg SS, editors. *Atlas of Pediatric Laparoscopy and Thoracoscopy*. Elsevier Inc.; 2022. 1-6 p.
18. Leng S, Bici K, Facchini F, et al. Customized Cutting Template to Assist Sternotomy in Pectus Arcuatum. *Ann Thorac Surg* 2019;107:1253-8.
19. Martinez J, Toselli L, Aleixandre CG, et al. Surgical Planning, Simulation, and Prosthesis Customization for Complex Chest Wall Malformations. *Ann Thorac Surg* 2021;112:e295-8.
20. Chavoïn JP, Facchini F, Martinot-Duquennoy V, et al. Congenital thoracic deformities and 3D custom-made implants. New classification based on a series of 789 treated cases. *Ann Chir Plast Esthet* 2022;67:393-403.
21. Aranda JL, Jiménez MF, Rodríguez M, et al. Tridimensional titanium-printed custom-made prosthesis for sternocostal reconstruction. *Eur J Cardiothorac Surg*

- 2015;48:e92-4.
22. Moradiellos J, Amor S, Córdoba M, et al. Functional Chest Wall Reconstruction With a Biomechanical Three-Dimensionally Printed Implant. *Ann Thorac Surg* 2017;103:e389-91.
 23. Tân D, Yao J, Hua X, et al. Application of 3D modeling and printing technology in accurate resection of complicated thoracic tumors. *Ann Transl Med* 2020;8:1342.
 24. Smelt J, Pontiki A, Jahangiri M, et al. Three-Dimensional Printing for Chest Wall Reconstruction in Thoracic Surgery: Building on Experience. *Thorac Cardiovasc Surg* 2020;68:352-6.
 25. Liu D, Wang Z, Qiu T, et al. Resection of a giant sternal chondrosarcoma and chest wall reconstruction: a case report. *Ann Transl Med* 2021;9:1706.
 26. Goldsmith I, Dovgalski L, Evans PL. 3D Printing Technology for Chest Wall Reconstruction With a Sternum-Ribs-Cartilage Titanium Implant: From Ideation to Creation. *Innovations (Phila)* 2023;18:67-72.
 27. Pontiki AA, Natarajan S, Parker FNH, et al. Chest Wall Reconstruction Using 3-Dimensional Printing: Functional and Mechanical Results. *Ann Thorac Surg* 2022;114:979-88.
 28. Wu Y, Chen N, Xu Z, et al. Application of 3D printing technology to thoracic wall tumor resection and thoracic wall reconstruction. *J Thorac Dis* 2018;10:6880-90.
 29. Sharaf B, Sabbagh MD, Vijayasekaran A, et al. Virtual surgical planning and three-dimensional printing in multidisciplinary oncologic chest wall resection and reconstruction: A case report. *Int J Surg Case Rep* 2018;47:52-6.
 30. Wen X, Gao S, Feng J, et al. Chest-wall reconstruction with a customized titanium-alloy prosthesis fabricated by 3D printing and rapid prototyping. *J Cardiothorac Surg* 2018;13:4.
 31. Cano JR, Escobar FH, Alonso DP, et al. Reconstruction of the anterior chest wall with a 3-dimensionally printed biodynamic prosthesis. *J Thorac Cardiovasc Surg* 2018;155:e59-60.
 32. Oswald N, Senanayake E, Naidu B, et al. Chest Wall Mechanics In Vivo With a New Custom-Made Three-Dimensional-Printed Sternal Prosthesis. *Ann Thorac Surg* 2018;105:1272-6.
 33. Wang L, Huang L, Li X, et al. Three-Dimensional Printing PEEK Implant: A Novel Choice for the Reconstruction of Chest Wall Defect. *Ann Thorac Surg* 2019;107:921-8.
 34. Wang B, Guo Y, Tang J, et al. Three-dimensional custom-made carbon-fiber prosthesis for sternal reconstruction after sarcoma resection. *Thorac Cancer* 2019;10:1500-2.
 35. Vannucci J, Scarnecchia E, Potenza R, et al. Dynamic titanium prosthesis based on 3D-printed replica for chest wall resection and reconstruction. *Transl Lung Cancer Res* 2020;9:2027-32.
 36. Albertal M, Vallejos J, Bellia G, et al. Changes in chest compression indexes with breathing underestimate surgical candidacy in patients with pectus excavatum: a computed tomography pilot study. *J Pediatr Surg* 2013;48:2011-6.
 37. Bellía-Munzón G, Sanjurjo D, Toselli L, et al. Novel index to estimate the cephalocaudal extent of the excavation in pectus excavatum: The Titanic index. *J Pediatr Surg* 2023;58:605-7.

Cite this article as: Martinez-Ferro M, Bellia-Munzon G, Toselli L, Sanjurjo D. The role of 3D printing in chest wall reconstruction. *J Thorac Dis* 2024;16(6):4053-4063. doi: 10.21037/jtd-23-881