



# Management for recurrent laryngeal nerve paralysis following oesophagectomy for oesophageal cancer: thoracic surgeon perspective

Jun Oh Lee<sup>1#^</sup>, Jae Kwang Yun<sup>1#^</sup>, Yong Ho Jeong<sup>2^</sup>, Yoon Se Lee<sup>3^</sup>, Yong-Hee Kim<sup>1^</sup>

<sup>1</sup>Department of Thoracic and Cardiovascular Surgery, Asan Medical Center, University of Ulsan College of Medicine, Seoul, Korea; <sup>2</sup>Department of Thoracic and Cardiovascular Surgery, Gangnam Severance Hospital, Yonsei University, College of Medicine, Seoul, Korea; <sup>3</sup>Department of Otorhinolaryngology - Head and Neck Surgery, Asan Medical Center, University of Ulsan, College of Medicine, Seoul, Korea

**Contributions:** (I) Conception and design: JO Lee, JK Yun, YH Kim; (II) Administrative support: JO Lee, JK Yun, YH Kim; (III) Provision of study materials or patients: JO Lee, JK Yun; (IV) Collection and assembly of data: JO Lee, JK Yun; (V) Data analysis and interpretation: JO Lee, JK Yun; (VI) Manuscript writing: All authors; (VII) Final approval of manuscript: All authors.

<sup>#</sup>These authors contributed equally to this work as co-first authors.

**Correspondence to:** Yong-Hee Kim, MD, PhD. Department of Thoracic and Cardiovascular Surgery, Asan Medical Center, University of Ulsan College of Medicine, 88 Olympic-ro-43-gil, Songpa-gu, Seoul 05505, Korea. Email: kimyh67md@hotmail.com.

**Background:** Recurrent laryngeal nerve (RLN) paralysis following oesophagectomy may increase postoperative morbidity and mortality. However, clinical studies on this complication are uncommon. The aim of this study was to report the clinical course of patients with RLN paralysis following oesophageal cancer surgery.

**Methods:** We retrospectively examined patients who underwent oesophagectomy for oesophageal carcinoma at Asan Medical Center between January 2013 and November 2018. We enrolled 189 patients with RLN paralysis confirmed using laryngoscopy in this study.

**Results:** Of the 189 patients, 22 patients had bilateral RLN paralysis, and 167 patients had unilateral RLN paralysis. Every patient received oral feeding rehabilitation, and 145 (76.7%) patients received hyaluronic acid injection laryngoplasty. During the postoperative period, 21 (11.1%) patients experienced aspiration pneumonia and recovered. One patient died of severe pulmonary complication. Twenty-four (12.7%) patients underwent feeding jejunotomy, while 11 (5.9%) patients underwent tracheostomy. In total, 173 (91.5%) patients were discharged with oral nutrition, and the median time to begin oral diet was 9 days. Statistical analysis using logistic regression revealed that only the advanced T stage affected nerve recovery. More than 50% of the patients showed nerve recovery within 6 months, and 165 (87.9%) patients fully or partially recovered during the observation period.

**Conclusions:** RLN paralysis following oesophagectomy in oesophageal carcinoma is a predictable complication. In patients with RLN paralysis, early detection and intervention through multidisciplinary cooperation are required, and the incidence of postoperative complications can be reduced by implementing the appropriate management.

**Keywords:** Oesophagectomy; oesophageal cancer; vocal cord palsy (VCP); recurrent laryngeal nerve paralysis

Submitted Feb 01, 2024. Accepted for publication Mar 22, 2024. Published online Jun 26, 2024.

doi: 10.21037/jtd-24-9

**View this article at:** <https://dx.doi.org/10.21037/jtd-24-9>

<sup>^</sup> ORCID: Jun Oh Lee, 0000-0003-3373-1144; Jae Kwang Yun, 0000-0001-5364-5548; Yong Ho Jeong, 0000-0001-7696-1236; Yoon Se Lee, 0000-0001-6534-5753; Yong-Hee Kim, 0000-0003-2177-4876.

## Introduction

Oesophagectomy with radical lymph node (LN) dissection is the mainstay of treatment for the management of oesophageal cancer (1-3). However, oesophagectomy carries a high risk of morbidity and mortality because it is performed over a large area from the neck to the stomach while preserving the major blood vessels and nerves (4).

Recurrent laryngeal nerve paralysis (RLNP) is one of the most common complications after oesophagectomy, with the incidence ranging between 1% and 80% (5-8). This wide range is attributed to several factors, including the anastomosis site, the degree and extent of LN dissection, and the method of postoperative laryngeal examination (9). Recurrent laryngeal nerve (RLN) injury is closely related to thermal injury from energy devices, mechanical touch, or impaired blood supply during the dissection of cervical paraoesophageal and thoracic paratracheal LNs (10,11). Unilateral or bilateral RLNP causes hoarseness and dysphonia. The prognosis and recovery outcomes for patients with RLNP remain uncertain, although risk factors and protective strategies have been explored. RLNP can lead to serious respiratory complications, including aspiration, pneumonia, and breathing difficulties (4,8,12). This risk may increase for patients prone to aspiration due to reflux, exacerbated by delayed gastric emptying following oesophagectomy (13). Mitigating the risk of RLNP is crucial, yet equally important is the thoracic surgeon's role

in managing patients who develop complications during the postoperative period. In this regard, we aim to elucidate the recovery process of vocal cord palsy (VCP) in patients after oesophagectomy for oesophageal cancer. We examined clinical factors and the effectiveness of our institution's strategies in managing RLNP recovery. We present this article in accordance with the STROBE reporting checklist (available at <https://jtd.amegroups.com/article/view/10.21037/jtd-24-9/rc>).

## Methods

We conducted a retrospective study of patients presenting with new-onset symptoms suggestive of VCP following oesophagectomy for oesophageal cancer. We reviewed patients who underwent oesophagectomy for oesophageal carcinoma at Asan Medical Center between January 2013 and November 2018. Oesophagectomy was performed via open thoracostomy, video-assisted thoracoscopic oesophagectomy (VE), or robot-assisted oesophagectomy (RAE). Due to missing clinical information, patients with secondary reconstruction were excluded from this study. In study periods, a total of 987 patients who underwent oesophagectomy performed by two attending surgeons with at least 5 years of experience were identified. Among these, 189 patients (20.1%) with unilateral or bilateral RLNP after oesophagectomy confirmed using laryngoscopy were enrolled in this study. The patients' follow up information was obtained from outpatient follow-up note of both thoracic surgeon and otolaryngologist, and the median follow-up time was 4.43 [interquartile range (IQR): 2.20–8.27] months. The study was conducted in accordance with the Declaration of Helsinki (as revised in 2013). The study was approved by the Institutional Review Board of the Ethics Committee of Asan Medical Center (No. 2022-3027) and individual consent for this retrospective analysis and the publication was waived.

After initial clinical staging, patients with locally advanced disease (stage T2 or higher, or N1 or higher) were administered neoadjuvant chemoradiotherapy, unless the patient was over 75 years of age or deemed in poor physical condition, based on the oncologist's assessment at a multidisciplinary clinic. This study used clinical and pathological tumour staging for primary tumour (T) and LN metastasis (N) scales. All specimens were pathologically examined at the Asan Medical Center Department of Pathology and Union for International Cancer Control

### Highlight box

#### Key findings

- Under appropriate management strategy, a good prognosis can be expected even if vocal cord palsy occurs after oesophagectomy.

#### What is known and what is new?

- Recurrent laryngeal nerve paralysis, a result of oesophageal cancer surgery, typically resolves within 6 months, allowing most patients to resume oral feeding.
- Whether recurrent laryngeal nerve palsy is temporary or permanent, prompt intervention, including hyaluronic acid injection laryngoplasty and active rehabilitation, enhances prognosis.

#### What is the implication, and what should change now?

- In patients with recurrent laryngeal nerve paralysis following oesophagectomy, early detection and intervention through multidisciplinary cooperation are required, and the incidence of postoperative complications can be reduced by implementing the appropriate management.

(UICC) 8th edition was used for TNM classification.

### ***Surgical procedure***

Most oesophagectomy procedures begin with abdominal phase. Stomach was used as conduit for oesophageal reconstruction through midline laparotomy. Patients whose stomachs were unsuitable received colon mobilization. Oesophagectomies, whether through open thoracotomy or minimally invasive surgery, are usually performed through the right thoracic approach. The mobilized conduit is pulled up to either the chest or neck via the posterior mediastinal route. After that, the oesophagus was anastomosed to the conduit below the thoracic inlet, or in cervical anastomosis, on the left side of the neck. An anastomosis was created using a circular surgical stapler and hand-sewing reinforcement. No thoracotomy approaches are used in the transhiatal oesophagectomy. Working upward from the diaphragmatic hiatus and downward through the cervical incision, the mobilization of the oesophagus is completed using blunt dissection. Subsequently, an anastomosis is created through the cervical incision.

Lymphadenectomy was performed in all oesophagectomy patients. Two-field lymphadenectomy (2FL) was performed at abdominal and mediastinal LN that includes LN along bilateral RLN and three-field lymphadenectomy was performed at 2FL stations and cervical LN. Cervical node dissection was performed by a head and neck surgeon if the patient had cervical oesophageal cancer, advanced T stage upper thoracic oesophageal cancer, or a suspected cervical/highest-mediastinal LN metastasis before neoadjuvant chemoradiation therapy.

### ***Assessment of VCP***

The otolaryngologist referred all patients with suspicious clinical symptoms of VCP for laryngoscopy. The suspicious clinical symptoms observed included breathing difficulty, ineffective coughing, dysphonia, and signs of aspiration, as well as patients with silent RLNP that exhibited signs of pneumonia on daily chest X-rays. Therefore, they are routinely followed up in outpatient clinic by a thoracic surgeon as well as otolaryngologist. Patients with impaired unilateral or bilateral vocal cord movement were diagnosed as unilateral or bilateral RLNP.

We classified vocal cord recovery in RLNP patients into

three groups with reference to otolaryngologist's follow-up medical note. The improvement of swallowing function and voice disturbance was used to assess the state of RLNP recovery. In this study, 'fully recovered' was defined as normal swallowing function without any dysphonia, whereas 'partially recovered' was defined as the improvement of swallowing function and voice but still with dysphonia. Furthermore, 'permanent palsy' was defined as no changes of dysphonia during the study period.

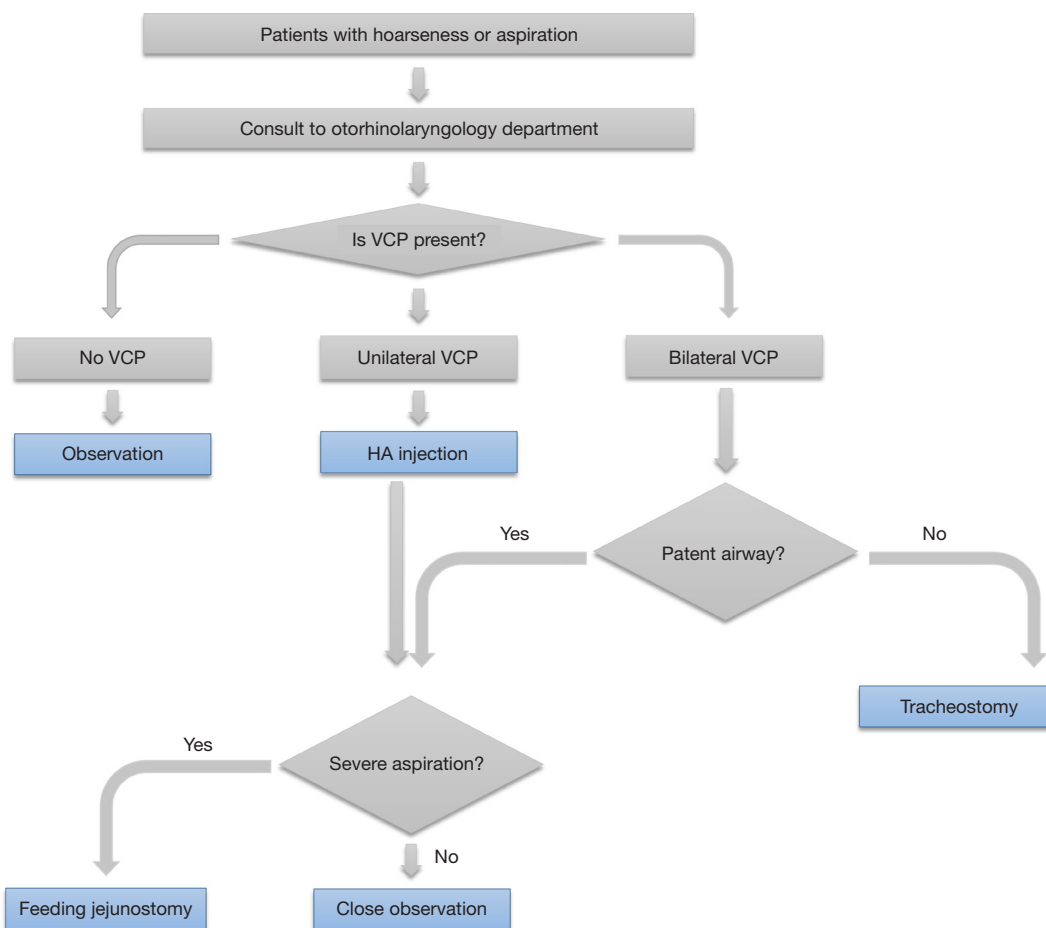
### ***Management of VCP following oesophagectomy***

Figure 1 shows general protocol of Asan Medical Center for patients with suspected VCP following oesophagectomy. Patients with uncontrolled airway or swallowing problems were kept *nil per os*. Hyaluronic acid (HA) injection laryngoplasty was performed on patients with unilateral RLNP. The HA injection is administered using a trans-cervical approach via a cricothyroid membrane puncture, under local anesthesia. This procedure is performed with the aid of flexible laryngoscopy, on patients in a sitting position (14). If an otolaryngologist determines that additional intervention is necessary for the patients, intracordal HA injection may be performed repeatedly in an outpatient setting.

In case of bilateral RLNP, the management strategies depended on each patient's airway patency. Patients with severe airway obstruction required immediate intubation and tracheostomy. Feeding jejunostomy was performed on patients with patent airway and severe aspiration. Patients with patent airway and no sign of aspiration began swallowing training. Oral feeding was scheduled after the swallowing rehabilitation. Before commencing oral feeding, all patients with oesophagectomy underwent barium swallowing oesophagography at our institution.

### ***Statistical analysis***

Student's *t*-test and one-way analysis of variance were used to compare continuous variables. All results were expressed as the mean  $\pm$  standard deviation, median with IQR, or proportion. Univariate and multivariate analysis of risk factors for recovery of RLN was performed with logistic regression. The R software package, version 4.1.0 (<http://www.R-project.org>), was used to perform all statistical analysis.  $P < 0.05$  was considered statistically significant.



**Figure 1** The management flowchart of our institution for patients with recurrent laryngeal nerve paralysis. The flowchart shows management of patients with recurrent laryngeal nerve paralysis in our institution. The main theme of our strategy is reducing pulmonary complication and proceeding oral feeding with early intervention. VCP, vocal cord palsy; HA, hydraulic acid.

## Results

### Baseline characteristics of patients

Table 1 shows the baseline characteristics of the enrolled 189 patients in this study. The median age of the entire group was 63.0 years (IQR: 38–84 years), and 175 patients (92.6%) were men. The diagnosis of squamous cell carcinoma was confirmed histopathologically in nearly all patients (n=188, 99.5%). Most of the tumours were found in the thoracic oesophagus (n=181, 95.7%) and only a few in the cervical oesophagus (n=8, 4.2%). The middle thoracic oesophagus was the most common site for thoracic oesophagus tumours (n=87, 46.0%), followed by the lower thoracic oesophagus (n=49, 25.9%) and upper thoracic oesophagus (n=45, 23.8%).

There were 89 (47.1%) cases of cT1 stage cancer, 37 (19.6%) cases of cT2 stage cancer, and 52 (27.5%) cases of cT3 stage cancer. We administered neoadjuvant chemotherapy to 73 (38.6%) patients. After surgery, 8 (4.2%), 21 (11.1%), and 8 (4.2%) patients were diagnosed with pathologically stage IIIA, IIIB, and stage IV, respectively.

There were no statistically significant differences between the unilateral VCP group and the bilateral VCP group regarding baseline characteristics.

### Operative details

In this study group, we performed oesophagectomy via right thoracotomy, transhiatal, and RAE. We performed

**Table 1** Baseline characteristics

Characteristics	Total (N=189)	Unilateral RLNP (N=167)	Bilateral RLNP (N=22)	P value
Age, years	63.0 [38–84]	63.0 [38–84]	63.5 [53–72]	0.99
Sex (male)	175 (92.6)	154 (92.2)	21 (95.5)	0.91
BMI, kg/m <sup>2</sup>	23.4 [20.5–25.5]	23.4 [20.5–25.4]	23.1 [21.0–26.5]	0.83
Histology (SqCC)	188 (99.5)	167 (100.0)	21 (95.5)	0.23
Conduit				>0.99
Colon	9 (4.8)	8 (4.8)	1 (4.5)	
Stomach	180 (95.2)	159 (95.2)	21 (95.5)	
Anastomosis				0.24
Cervical	111 (58.7)	95 (56.9)	16 (72.7)	
Intrathoracic	78 (41.3)	72 (43.1)	6 (27.3)	
Approach				0.70
Transhiatal	5 (2.6)	5 (3.0)	0 (0.0)	
Transthoracic	114 (60.3)	100 (59.9)	14 (63.6)	
Robot	70 (37.0)	62 (37.1)	8 (36.4)	
Primary tumour location				0.52
Cervical	8 (4.2)	8 (4.8)	0 (0.0)	
Lower	49 (25.9)	41 (24.6)	8 (36.4)	
Middle	87 (46.0)	78 (46.7)	9 (40.9)	
Upper	45 (23.8)	40 (24.0)	5 (22.7)	
Neoadjuvant treatment	73 (38.6)	61 (36.5)	12 (54.5)	0.16
CND	68 (36.0)	57 (34.1)	11 (50.0)	0.22
Clinical T				0.23
T1a	15 (7.9)	13 (7.8)	2 (9.1)	
T1b	74 (39.2)	63 (37.7)	11 (50.0)	
T2a	37 (19.6)	35 (21.0)	2 (9.1)	
T3	52 (27.5)	48 (28.7)	4 (18.2)	
Clinical N				0.17
N1	99 (52.4)	91 (54.5)	8 (36.4)	
N2	51 (27.0)	43 (25.7)	8 (36.4)	
N3	10 (5.3)	10 (6.0)	0 (0.0)	
Nx	18 (9.5)	15 (9.0)	3 (13.6)	
Pathologic stage				0.99
0	32 (16.9)	29 (17.4)	3 (13.6)	
IA	16 (8.5)	15 (9.0)	1 (4.5)	
IB	56 (29.6)	49 (29.3)	7 (31.8)	

Table 1 (continued)

Table 1 (continued)

Characteristics	Total (N=189)	Unilateral RLNP (N=167)	Bilateral RLNP (N=22)	P value
IIA	10 (5.3)	9 (5.4)	1 (4.5)	
IIB	38 (20.1)	34 (20.4)	4 (18.2)	
IIIA	8 (4.2)	7 (4.2)	1 (4.5)	
IIIB	21 (11.1)	17 (10.2)	4 (18.2)	
IV	8 (4.2)	7 (4.2)	1 (4.5)	
Total_LN*	36.6±14.3	35.7±13.7	43.3±16.9	0.02
Metastatic_LN**	0.9±2.3	0.9±2.4	1.1±1.5	0.61
RLN LN metastasis	23 (12.2)	19 (11.4)	4 (18.2)	0.57
Resection status				0.22
R0	165 (87.3)	146 (87.4)	19 (86.4)	
R1	22 (11.6)	20 (12.0)	2 (9.1)	
R2	2 (1.1)	1 (0.6)	1 (4.5)	

Data are expressed as n (%), median [IQR] or mean ± SD. \*, Total\_LN: total number of lymph nodes obtained during intraoperative lymphadenectomy. \*\*, Metastatic\_LN: total number of pathologically confirmed metastatic lymph nodes after surgery. RLNP, recurrent laryngeal nerve paralysis; BMI, body mass index; SqCC, squamous cell carcinoma; CND, central neck node dissection; RLN, recurrent laryngeal nerve; LN, lymph node; IQR, interquartile range; SD, standard deviation.

transthoracic oesophagectomy via right thoracotomy in 114 (60.3%) patients, 5 (2.6%) patients underwent transhiatal oesophagectomy, and 70 (37.0%) patients underwent RAE. The stomach was most commonly used as a conduit (95.2%) during oesophagectomy, while the colon was used for conduit in nine cases (4.8%). More than half of the study group (58.7%) underwent cervical anastomosis, while 41.3% of the patients underwent intrathoracic anastomosis.

We performed R0 resection on 165 (87.3%) patients, 22 (11.6%) patients underwent R1 resection, and 2 (1.1%) patients underwent R2 resection.

All patients in this study underwent two-field (n=121, 64.0%) or three-field (n=68, 36.0%) LN dissection with abdominal LN dissection. The mean number of LN dissected was 37 (36.6±14.3), and statistically, more LN dissections were performed in the bilateral RLNP group than in the unilateral RLNP group (P=0.02). Oesophagectomy was performed with a central neck dissection by an otolaryngologist.

### Clinical course of patients with VCP

Table 2 shows the postoperative course of RLNP patients who underwent oesophagectomy. There were 22 (11.6%)

and 167 (88.4%) patients with bilateral and unilateral RLNP, respectively. In patients with unilateral RLNP, left-sided RLNP was more common than right-sided RLNP (73.7% vs. 26.3%).

The most common RLNP-related complication was dysphonia (n=184, 97.4%), followed by aspiration (n=38, 20.1%). During the postoperative course, aspiration pneumonia occurred in 21 (11.1%) patients. Tracheostomy was performed in 11 patient (5.9% of the entire group). Dyspnoea and tracheostomy were more common in the bilateral RLNP group than in the unilateral RLNP group.

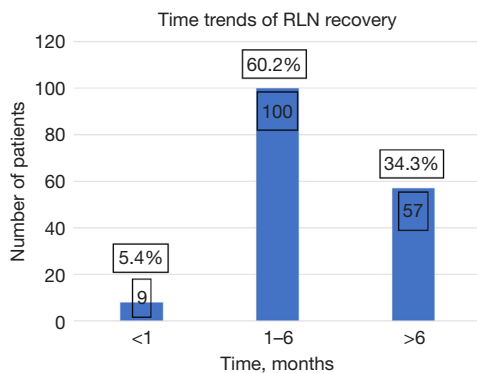
Every patient with RLNP received oral feeding rehabilitation, and 145 (76.7%) patients underwent injection laryngoplasty with HA by an otolaryngologist. The patients with unilateral RLNP (83.2%) were mainly targeted; however, 27.3% of the patients in the bilateral group received HA injections. The median injection time for HA was 10 days (IQR: 7–27 days). Feeding jejunostomy was performed on 24 (12.7%) patients.

We discharged 173 (91.5%) patients with oral feeding. The swallowing function recovery rate tended to be higher in patients in the unilateral group (95.2%) than in the bilateral group, while 14 (63.6%) patients in the bilateral group recovered. The median time to initiate an effective

**Table 2** Postoperative outcomes

Characteristics	Total (N=189)	Unilateral (N=167)	Bilateral (N=22)	P value
<b>Lateralization</b>				
Right	44 (23.3)	44 (26.3)	0 (0.0)	
Left	123 (65.1)	123 (73.7)	0 (0.0)	
Both	22 (11.6)	0 (0.0)	22 (100.0)	
<b>Clinical symptoms</b>				
Dysphonia	184 (97.4)	163 (97.6)	21 (95.5)	>0.99
Aspiration	38 (20.1)	35 (21.0)	3 (13.6)	0.60
Dyspnoea	11 (5.8)	7 (4.2)	4 (18.2)	0.03
HA injection	145 (76.7)	139 (83.2)	6 (27.3)	<0.001
Time to HA injection, days, median [IQR]	10 [7–27]	10 [7–22]	112.5 [69.5–212.2]	0.07
Tracheostomy	11 (5.9)	4 (2.4)	7 (31.8)	<0.001
Feeding jejunostomy	24 (12.7)	17 (10.2)	7 (31.8)	0.01
Discharge with Oral diet	173 (91.5)	159 (95.2)	14 (63.6)	<0.001
Time to oral diet, days	9 [7–15]	9 [7–13]	16.5 [10.8–73.5]	0.04
<b>Recovery</b>				
No	23 (12.2)	18 (10.8)	5 (22.7)	0.06
Partially	102 (54.0)	95 (56.9)	7 (31.8)	
Fully	64 (33.9)	54 (32.3)	10 (45.5)	
Recover period, months	4.4 [2.2–8.3]	4.1 [2.1–8.2]	6.55 [4.1–14.2]	0.31

Data are expressed as n (%) or median [IQR]. HA, hyaluronic acid; IQR, interquartile range.



**Figure 2** Time trends of recurrent laryngeal nerve recovery. The time trend graph shows most patient with recurrent laryngeal nerve palsy recovered within 6 months. RLN, recurrent laryngeal nerve.

oral diet was 9 days (IQR: 7–15 days)]. Patients in the bilateral RLNP group took a significantly longer time to commence oral diet [median 16.5 days (IQR: 10.8–73.5 days) in the bilateral group *vs.* median 9 days (IQR: 7–13 days) in the unilateral group]. During the study period, 64 patients were fully recovered, 102 patients were partially recovered, and 23 patients were observed in a permanent palsy. Of the permanent palsy patients, 18 patients could achieve oral diet with suitable rehabilitation and interventions.

*Figure 2* shows the recovery passage over time. During the observed periods, 166 patients were able to regain oral feeding. Approximately two-thirds of the patients (65.6%) with RLNP recovered their swallowing function within 6 months. In detail, 9 (5.4%) patients recovered within

**Table 3** Factors analysis of nerve recovery with univariable and multivariable logistic regression

Factor	Univariable		Multivariable	
	OR (95% CI)	P value	OR (95% CI)	P value
Age	0.97 (0.92–1.03)	0.37		
Sex (male)	2.11 (0.45–7.48)	0.28		
Smoking (yes)	0.71 (0.20–2.04)	0.56		
BMI	1.07 (0.94–1.24)	0.30		
Neoadjuvant treatment	0.8 (0.33–1.96)	0.61		
Conduit (stomach)	0.9 (0.05–5.24)	0.92		
Anastomosis (cervical)	0.59 (0.22–1.45)	0.26		
RAE	1 (0.41–2.53)	>0.99		
CND	1.06 (0.43–2.77)	0.90		
pNodal stage ( $\geq$ N1)	0.88 (0.36–2.3)	0.78		
RLN LN positive	1.52 (0.40–9.93)	0.59		
pT1	0.23 (0.01–1.26)	0.17	0.22 (0.01–1.24)	0.16
pT2	0.34 (0.01–9.12)	0.46	0.22 (0.01–6.13)	0.31
pT3	0.1 (0.01–0.61)	0.04	0.11 (0.01–0.65)	0.04
pT4	0.01 (0–0.25)	0.008	0.02 (0–0.35)	0.01
Total number of dissected LN	1.02 (0.99–1.06)	0.25		
RLNP side (right)	6.9 (1.35–126.18)	0.07	5.8 (1.08–107.85)	0.10
RLNP side (bilateral)	0.55 (0.19–1.83)	0.29	0.53 (0.17–1.9)	0.29
HA laryngoplasty ( $\geq$ 1 month)	1.19 (0.41–3.09)	0.73		
Postoperative complication (yes)	1.42 (0.53–4.5)	0.51		

OR, odds ratio; CI, confidence interval; BMI, body mass index; RAE, robot-assisted oesophagectomy; CND, central neck dissection; RLN, recurrent laryngeal nerve; LN, lymph node; RLNP, recurrent laryngeal nerve paralysis; HA, hyaluronic acid.

1 month, and 100 (60.2%) patients recovered within 1 to 6 months. Fifty-seven (34.3%) patients recovered after 6 months. Using several clinical and pathological factors, *Table 3* shows the logistic regression analysis for RLNP recovery with successful oral feeding. As a result, pathologic T3 [odds ratio (OR) 0.11; 95% CI: 0.01–0.65,  $P=0.04$ ] and T4 (OR 0.02; 95% CI: 0–0.35,  $P=0.01$ ) stages were the only significant poor prognostic factor in univariable and multivariate analysis (*Table 3*).

#### Postoperative morbidity after oesophagectomy

*Table 4* shows the postoperative complications. The median length of hospital stay after oesophagectomy was 16 days (IQR: 12–21 days). The unilateral group had a longer

hospitalization period than the bilateral group ( $P=0.11$ ), however, it was not statistically significant. The median intensive care unit (ICU) stay was 8 days (IQR: 2.5–14.5 days), and 17 (9.0%) patients were readmitted to the ICU because of pulmonary complications after transfer to the general ward. The bilateral group had a significantly higher ICU readmission rate than the unilateral group ( $P=0.046$ ). The major complications of patients with RLNP in this study were as follows: 8 (4.2%) patients with pneumonia, 2 (1.1%) patients with acute respiratory distress syndrome, and 11 (5.8%) patients with anastomosis-site leakage. There was no statistically difference in complication rate between the unilateral and bilateral groups. There was no early mortality within a month, but one in-hospital mortality was observed 40 days after the operation due to severe pneumonia.



**Table 4** Postoperative complication

Outcomes	Total (N=189)	Unilateral (N=167)	Bilateral (N=22)	P value
Hospital stay, days	16 [12–21]	15 [12–20]	22.5 [16.5–32.75]	0.11
ICU readmission	17 (9.0)	12 (7.2)	5 (22.7)	0.046
ICU stay*, days	8 [2.5–14.5]	9 [2–16.5]	7 [4.5–10.5]	0.27
In-hospital mortality	1 (0.6)	1 (0.5)		
Postoperative complication	52 (27.5)	43 (25.7)	9 (40.9)	0.21
Detailed data				
Pneumonia	8 (4.2)	6 (3.6)	2 (9.1)	0.52
ARDS	2 (1.1)	1 (0.6)	1 (4.5)	0.55
Wound infection	3 (1.6)	3 (1.8)	0 (0.0)	>0.99
Anastomosis leakage	11 (5.8)	11 (6.6)	0 (0.0)	0.45
Conduit necrosis	1 (0.5)	1 (0.6)	0 (0.0)	>0.99
Chylothorax	5 (2.6)	4 (2.4)	1 (4.5)	>0.99

Data are expressed as n (%) or median [IQR]. \*, ICU stay, median ICU days among the readmitted patients. ICU, intensive care unit; ARDS, acute respiratory distress syndrome; IQR, interquartile range.

## Discussion

This study evaluated 189 patients with RLNP after oesophagectomy for clinical course and prognostic factors of nerve recovery. Initially 198 patients (20.1%) were diagnosed as RLNP during the post-operative hospital course and 23 patients (2.3%) were permanent RLNP in this observed period. In our institution's strategy for management of RLNP, any patients who suspicious symptoms with VCP undergo vocal cord examination with laryngoscopy by otolaryngologist. This early screening strategy may relatively maximize the number of patients diagnosed with RLNP at early period, however, compared to the prevalence rate reported in previous papers, we think it falls within the expected range (5–8).

RLNP-induced VCP after oesophagectomy is clinically significant because it can delay oral nutrient supply and cause morbidity and mortality. In total, 87.9% of the patients with RLNP recovered in this study. Through active interventions and rehabilitation training, 92% of the patients with RLNP could begin oral feeding before discharge, and all patients, except one deceased patient, could achieve oral feeding during follow-up. In total, 5.3% of the patients had pulmonary complications. RLNP is caused by tumor progression, surgical technique, LN metastasis, and number of dissected LN. Only tumor T stage was statistically independent of VCP recovery.

Lymphadenectomy during oesophageal cancer surgery has complex procedures, longer surgery, and complications, especially RLNP. Previous studies reported that LN dissection might increase the incidence of RLNP (6,8,15). However, numerous recent studies clarify the survival benefit of oesophagectomy with LN dissection after neoadjuvant treatment (16–18). Additional cervical LN dissection, LN metastasis, and neoadjuvant treatment may be the cause of RLNP but were not related to nerve recovery in this study (17). Our findings could support the radical treatment for oesophageal cancer. Thoracoscopic oesophagectomy was developed as surgical techniques and instruments advanced and robot-assisted surgery magnifies intrathoracic surgical fields, allowing precise LN dissection (19,20). However, in our study, the robot-assisted technique was not a positive prognostic factor for RLNP recovery. The advantages of minimally invasive oesophagectomy for reducing RLNP continue to be debated, and further studies are needed (21).

Understanding normal anatomy and anatomic variants of the RLN is essential for thoracic surgeons to prevent RLN injury during oesophagectomy. The RLN originates from the vagus nerve and innervates the larynx. The left RLN loops under the aortic arch and ascends through the thoracic cavity, whereas the right RLN loops under the right subclavian artery. Because the left RLN has a longer anatomic course and is closer to the oesophagus or trachea

than the right RLN, the risk of left RLN injury during the surgery is higher, as observed in our study (65.1% *vs.* 23.3%) (15). Due to the close anatomical proximity of RLN to the oesophagus at the cervical level, the incidence of RLNP is notably high in cases of cervical anastomosis (5,11,22). Meticulous dissection and proactive identification of the recurrent nerve can minimize nerve damage. However, this study found that cervical anastomosis, as a factor, did not have a statistically significant impact on RLNP recovery. Recently, continuous intraoperative RLN monitoring has been implemented in oesophageal surgery. Recent thoracic surgeons have used RLN monitoring based on an electrically stimulated nerve response. Ongoing studies examine the technical viability and clinical benefits of new RLN monitoring (23,24).

Recovery from RLNP occurred 2 weeks after oesophagectomy, and most patients with RLNP recovered spontaneously within 1 year after oesophagectomy for oesophageal cancer; recovery of RLNP after 1 year is uncommon (11,25,26). In this study, the median RLN recovery time was 4.4 months (IQR: 2.2–8.3 months), and there was no significant difference between the unilateral and bilateral groups. More than half of the 166 recovered patients with RLNP achieved nerve recovery within 6 months ( $n=108$ , 65.3%), and only 22 patients recovered after 12 months (13.3%). During the entire study period, the partial or full recovery of RLN rate was 87%, and 12.2% of the patients were diagnosed with permanent RLNP.

The T stage of the primary tumour can be used to predict the development of RLNP during surgery (4). Since our study subject was about the patient with RLNP, more advanced stage patients were included, and the rate of incomplete surgical resection seems to be rather high. In this study, pathologic T3 and T4 were poor prognostic factors for RLNP recovery. Advanced T stage is linked to LN metastasis and a neoadjuvant treatment target. But neither LN metastasis nor neoadjuvant treatment affected prognosis of nerve recovery in this study. Primary T stage is an RLNP risk factor and a recovery factor. In the advanced T stage, the thoracic phase takes longer due to adhesion with surrounding structures and difficulty in surgery. Our statistical analysis did not include operation time, but a longer thoracic phase is associated with RLNP (27,28).

Pulmonary complications associated with RLNP after oesophagectomy significantly increase the ICU readmission rate, hospital stay, and mortality rate (4,8,12). Pulmonary complications after oesophagectomy have been reported to

be 20–50%, and mortality rate is 10–40% (26,29,30). After oesophagectomy, proper management of RLNP improves the patient's prognosis. Laryngoscopy performed at the appropriate time for a patient with suspicious symptoms allows for early detection of RLNP after oesophagectomy. In our institution, patients with suspicious RLNP symptoms at least 3 to 4 days after oesophagectomy were selected for vocal cord exam using laryngoscopy performed by an otorhinolaryngologist. All patients with RLNP were referred to swallowing rehabilitation by a rehabilitation specialist. Swallowing rehabilitation is conducted by the department of Rehabilitation Medicine. It is designed to promote movement of the oesophagus and protecting the airway by strengthening the oropharyngeal muscles from two perspectives: remedial approach and compensation. In our study, pulmonary complications in patients with RLNP were <1%. Although the RLNP state increases pulmonary complication, early active intervention could prevent mortality.

The intervention and surgical treatments for RLNP include thyroplasty, intracordal injection, arytenoid adduction, and laryngeal reinnervation to inwardly move the vocal cord or expand the glottis (31). There are many ways to improve symptoms caused by RLNP, but our institution primarily performs intracordal HA injection for patients with unilateral RLNP. Six patients with bilateral RLNP received HA injections after nerve recovery on one side. We tried to administer HA injections earlier than other institutions according to our VCP management strategy. We thought determining if the VCP is temporary or permanent was less important than patient recovery. The most important advantage of intracordal HA injection for patients is that it eliminates the risk of aspiration almost immediately after the procedure (32), thereby reducing the occurrence of pulmonary complication and speed oral diet implementation, which are the most important factors affecting the prognosis after oesophagectomy. In addition, improving voice quality increase satisfaction of patients (14,33). Another advantage is that reabsorption of the injection material is possible (14,33), so it can serve as a bridge before being diagnosed with permanent RLNP and performing other permanent techniques for treatment of RLNP.

Direct nerve anastomosis can repair the vocal cord and restore laryngeal muscle tone (28). In our institution, there was a small number of cases of RLN reconstruction for patients with bilateral RLNP, and the result was effective.

There were limitations to this study. First, the

retrospective nature of our database was not randomized control trial, and it was a single-centre study. Second, in our database, the laryngoscopic examination was performed only for diagnosis of RLNP and was not used to confirm the recovery state routinely. Third, we could not perform a statistical analysis to compare the effectiveness of the early application of HA injection, which we emphasize, against a group that did not receive it. Finally, we aim to evaluate clinical factors and strategy of our institution focused on RLNP recovery, and unfortunately, studies for the risk factors about occurrence of RLNP was not included in this study. In a future follow-up study, there should be a comprehensive studies or meta-analyses involving larger patient cohorts to robustly assess the effects on RLNP recovery.

## Conclusions

RLNP is a predictably serious complication of oesophagectomy. Advanced T stage was the only poor prognostic factor for RLNP recovery. Although many VCP patients recover spontaneously, early detection and multidisciplinary intervention are needed. Appropriate management of RLNP reduces postoperative complications.

## Acknowledgments

*Funding:* None.

## Footnote

*Reporting Checklist:* The authors have completed the STROBE reporting checklist. Available at <https://jtd.amegroups.com/article/view/10.21037/jtd-24-9/rc>

*Data Sharing Statement:* Available at <https://jtd.amegroups.com/article/view/10.21037/jtd-24-9/dss>

*Peer Review File:* Available at <https://jtd.amegroups.com/article/view/10.21037/jtd-24-9/prf>

*Conflicts of Interest:* All authors have completed the ICMJE uniform disclosure form (available at <https://jtd.amegroups.com/article/view/10.21037/jtd-24-9/coif>). The authors have no conflicts of interest to declare.

*Ethical Statement:* The authors are accountable for all aspects of the work in ensuring that questions related

to the accuracy or integrity of any part of the work are appropriately investigated and resolved. The study was conducted in accordance with the Declaration of Helsinki (as revised in 2013). The study was approved by the Institutional Review Board of the Ethics Committee of Asan Medical Center (No. 2022-3027) and individual consent for this retrospective analysis and the publication was waived.

*Open Access Statement:* This is an Open Access article distributed in accordance with the Creative Commons Attribution-NonCommercial-NoDerivs 4.0 International License (CC BY-NC-ND 4.0), which permits the non-commercial replication and distribution of the article with the strict proviso that no changes or edits are made and the original work is properly cited (including links to both the formal publication through the relevant DOI and the license). See: <https://creativecommons.org/licenses/by-nc-nd/4.0/>.

## References

1. Kang CH, Kim YT, Jeon SH, et al. Lymphadenectomy extent is closely related to long-term survival in esophageal cancer. *Eur J Cardiothorac Surg* 2007;31:154-60.
2. Fujita H, Sueyoshi S, Tanaka T, et al. Optimal lymphadenectomy for squamous cell carcinoma in the thoracic esophagus: comparing the short- and long-term outcome among the four types of lymphadenectomy. *World J Surg* 2003;27:571-9.
3. Tong D, Law S. Extended lymphadenectomy in esophageal cancer is crucial. *World J Surg* 2013;37:1751-6.
4. Scholtmeijer MG, Seesing MFJ, Brenkman HJF, et al. Recurrent laryngeal nerve injury after esophagectomy for esophageal cancer: incidence, management, and impact on short- and long-term outcomes. *J Thorac Dis* 2017;9:S868-78.
5. Pertl L, Zacherl J, Mancusi G, et al. High risk of unilateral recurrent laryngeal nerve paralysis after esophagectomy using cervical anastomosis. *Eur Arch Otorhinolaryngol* 2011;268:1605-10.
6. Taniyama Y, Miyata G, Kamei T, et al. Complications following recurrent laryngeal nerve lymph node dissection in oesophageal cancer surgery. *Interact Cardiovasc Thorac Surg* 2015;20:41-6.
7. Johnson PR, Kanegoanker GS, Bates T. Indirect laryngoscopic evaluation of vocal cord function in patients undergoing transhiatal esophagectomy. *J Am Coll Surg* 1994;178:605-8.

8. Gockel I, Kneist W, Keilmann A, et al. Recurrent laryngeal nerve paralysis (RLNP) following esophagectomy for carcinoma. *Eur J Surg Oncol* 2005;31:277-81.
9. Walther B, Johansson J, Johnsson F, et al. Cervical or thoracic anastomosis after esophageal resection and gastric tube reconstruction: a prospective randomized trial comparing sutured neck anastomosis with stapled intrathoracic anastomosis. *Ann Surg* 2003;238:803-12; discussion 812-4.
10. Myssiorek D. Recurrent laryngeal nerve paralysis: anatomy and etiology. *Otolaryngol Clin North Am* 2004;37:25-44, v.
11. Sato Y, Kosugi S, Aizawa N, et al. Risk Factors and Clinical Outcomes of Recurrent Laryngeal Nerve Paralysis After Esophagectomy for Thoracic Esophageal Carcinoma. *World J Surg* 2016;40:129-36.
12. Hulscher JB, van Sandick JW, Devriese PP, et al. Vocal cord paralysis after subtotal oesophagectomy. *Br J Surg* 1999;86:1583-7.
13. Périé S, Laccourreye O, Bou-Malhab F, et al. Aspiration in unilateral recurrent laryngeal nerve paralysis after surgery. *Am J Otolaryngol* 1998;19:18-23.
14. Wang CC, Wu SH, Tu YK, et al. Hyaluronic Acid Injection Laryngoplasty for Unilateral Vocal Fold Paralysis-A Systematic Review and Meta-Analysis. *Cells* 2020;9:2417.
15. Wright CD, Zeitels SM. Recurrent laryngeal nerve injuries after esophagectomy. *Thorac Surg Clin* 2006;16:23-33, v.
16. Watanabe M, Otake R, Kozuki R, et al. Recent progress in multidisciplinary treatment for patients with esophageal cancer. *Surg Today* 2020;50:12-20.
17. Matsuda S, Takeuchi H, Kawakubo H, et al. Three-field lymph node dissection in esophageal cancer surgery. *J Thorac Dis* 2017;9:S731-40.
18. Napier KJ, Scheerer M, Misra S. Esophageal cancer: A Review of epidemiology, pathogenesis, staging workup and treatment modalities. *World J Gastrointest Oncol* 2014;6:112-20.
19. Hosoda K, Niihara M, Ushiku H, et al. Prevention of intra-thoracic recurrent laryngeal nerve injury with robot-assisted esophagectomy. *Langenbecks Arch Surg* 2020;405:533-40.
20. Duan X, Yue J, Chen C, et al. Lymph node dissection around left recurrent laryngeal nerve: robot-assisted vs. video-assisted McKeown esophagectomy for esophageal squamous cell carcinoma. *Surg Endosc* 2021;35:6108-16.
21. Mederos MA, de Virgilio MJ, Shenoy R, et al. Comparison of Clinical Outcomes of Robot-Assisted, Video-Assisted, and Open Esophagectomy for Esophageal Cancer: A Systematic Review and Meta-analysis. *JAMA Netw Open* 2021;4:e2129228.
22. Biere SS, Maas KW, Cuesta MA, et al. Cervical or thoracic anastomosis after esophagectomy for cancer: a systematic review and meta-analysis. *Dig Surg* 2011;28:29-35.
23. Wong I, Tong DKH, Tsang RKY, et al. Continuous intraoperative vagus nerve stimulation for monitoring of recurrent laryngeal nerve during minimally invasive esophagectomy. *J Vis Surg* 2017;3:9.
24. Yuda M, Nishikawa K, Takahashi K, et al. A Strategy for Using Intraoperative Nerve Monitoring During Esophagectomy to Prevent Recurrent Laryngeal Nerve Palsy. *Anticancer Res* 2018;38:1563-7.
25. Orringer MB, Marshall B, Chang AC, et al. Two thousand transhiatal esophagectomies: changing trends, lessons learned. *Ann Surg* 2007;246:363-72; discussion 372-4.
26. Jeon YJ, Cho JH, Lee HK, et al. Management of patients with bilateral recurrent laryngeal nerve paralysis following esophagectomy. *Thorac Cancer* 2021;12:1851-6.
27. Ohi M, Toiyama Y, Yasuda H, et al. Preoperative computed tomography predicts the risk of recurrent laryngeal nerve paralysis in patients with esophageal cancer undergoing thoracoscopic esophagectomy in the prone position. *Esophagus* 2021;18:228-38.
28. Koyanagi K, Igaki H, Iwabu J, et al. Recurrent Laryngeal Nerve Paralysis after Esophagectomy: Respiratory Complications and Role of Nerve Reconstruction. *Tohoku J Exp Med* 2015;237:1-8.
29. Dumont P, Wihlm JM, Hentz JG, et al. Respiratory complications after surgical treatment of esophageal cancer. A study of 309 patients according to the type of resection. *Eur J Cardiothorac Surg* 1995;9:539-43.
30. Fang W, Kato H, Tachimori Y, et al. Analysis of pulmonary complications after three-field lymph node dissection for esophageal cancer. *Ann Thorac Surg* 2003;76:903-8.
31. Dispenza F, Dispenza C, Marchese D, et al. Treatment of bilateral vocal cord paralysis following permanent recurrent laryngeal nerve injury. *Am J Otolaryngol* 2012;33:285-8.
32. Laccourreye O, Paczona R, Ageel M, et al. Intracordal autologous fat injection for aspiration after recurrent laryngeal nerve paralysis. *Eur Arch Otorhinolaryngol* 1999;256:458-61.

33. Švejdová A, Dršata J, Mejzlík J, et al. Injection laryngoplasty with hyaluronic acid for glottal insufficiency in unilateral vocal fold paralysis:

a systematic review of the literature. *Eur Arch Otorhinolaryngol* 2022;279:5071-9.

**Cite this article as:** Lee JO, Yun JK, Jeong YH, Lee YS, Kim YH. Management for recurrent laryngeal nerve paralysis following oesophagectomy for oesophageal cancer: thoracic surgeon perspective. *J Thorac Dis* 2024;16(6):3805-3817. doi: 10.21037/jtd-24-9