



# Reoperative aortic root surgery: single-center long-term outcomes and literature review

Giacomo Murana<sup>1</sup>^, Valeria Santamaria<sup>1</sup>, Chiara Nocera<sup>1</sup>, Francesco Campanini<sup>1</sup>, Silvia Snaidero<sup>1</sup>, Carlo Mariani<sup>1,2</sup>, Luca Di Marco<sup>1,2</sup>, Davide Pacini<sup>1,2</sup>

<sup>1</sup>Division of Cardiac Surgery, Cardiac Surgery Department, IRCCS, Azienda Ospedaliero-Universitaria di Bologna, Bologna, Italy; <sup>2</sup>Department of Experimental, Diagnostic and Specialty Medicine, DIMES, University of Bologna, Bologna, Italy

*Contributions:* (I) Conception and design: All authors; (II) Administrative support: All authors; (III) Provision of study materials or patients: All authors; (IV) Collection and assembly of data: All authors; (V) Data analysis and interpretation: All authors; (VI) Manuscript writing: All authors; (VII) Final approval of manuscript: All authors.

*Correspondence to:* Giacomo Murana, MD, PhD. Cardiac Surgery Department, S. Orsola Hospital, University of Bologna, Via Massarenti 9, 40138, Bologna, Italy. Email: g.murana@hotmail.com; giacomo.murana@aosp.bo.it.

**Background and Objective:** Reoperative aortic root surgery has become more and more common over the years and is considered high-risk, with significantly worse outcomes compared to first-procedure root surgery. At our institution, this kind of surgery is frequently performed. The aim of the present review is to describe currently available literature on reoperative surgery on the aortic root in terms of patients' population, indications for surgery and outcomes and to present our center's experience on the matter.

**Methods:** A literature review was performed in order to identify pertinent studies. They were then compared and described. We also described preoperative characteristics, operative strategies and outcomes of all the patients who underwent redo aortic root surgery from January 1986 to December 2022 at our center.

**Key Content and Findings:** Our literature review identified 12 pertinent studies, with a total of 16,627 considered patients. The most frequent indications for redo surgery were endocarditis (35.5%), aneurysm, dissection and pseudoaneurysm. Mean cardiopulmonary bypass (CPB) and cross-clamp times were 218 and 152 minutes, respectively. In-hospital mortality was 12%. When analyzing our center's data, 344 procedures were identified. Aortic root dilation was the most frequent indication (36.9%). Mean CPB and cross-clamp times were 218.0±78.8 and 158.2±49.7 minutes, respectively. In-hospital mortality was 9.6%. Survival at 5 and 15 years was 76.1% and 51.4% respectively. Freedom from further aortic reintervention was 88.1% after 5 years and 64.9% after 15 years.

**Conclusions:** Reoperative aortic root surgery is a difficult cardiac procedure which is linked to significantly higher mortality than first-time root replacement. If it is performed by experienced surgeons with a careful preoperative planning its result can still be satisfactory. Our results showed acceptable rates of mortality and reinterventions at follow-up. Endocarditis, however, was linked to worse outcomes.

**Keywords:** Aortic root; redo surgery; Bentall operation; reoperations; outcomes

Submitted Oct 25, 2023. Accepted for publication May 10, 2024. Published online Jun 28, 2024.

doi: 10.21037/jtd-23-1629

View this article at: <https://dx.doi.org/10.21037/jtd-23-1629>

^ ORCID: 0000-0002-2244-2024.

## Introduction

Surgical treatment of aortic root pathologies improved significantly over the last 20 years. Better perioperative management and surgical technique led to reduced mortality, and better long-term outcomes (1,2). The latest report based on the Society of Thoracic Surgeons (STS) database showed a 2.2% operative mortality for elective aortic root replacement (3). However, redo aortic surgery in general is still a high-risk cardiac procedure, with a reported surgical mortality of 6–16% (4-6). The main indications are illustrated in *Table 1*. Reoperations on the aortic root have increased due to the aging of the population, the growing use of biological conduits and the increase of reparative aortic root operations. Furthermore, prosthetic valve endocarditis and pseudoaneurysms are indications

for aortic root reoperations. Although aortic root surgery yields excellent results as a primary procedure, reoperations, especially if root surgery was performed during the first procedure, are still challenging and result in a higher mortality rate.

The purpose of this article was to collect and critically review the literature on aortic root redo to evaluate the main challenges of this type of surgery. We also aim to describe our center's experience in aortic root redo surgery. We present this article in accordance with the Narrative Review reporting checklist (available at <https://jtd.amegroups.com/article/view/10.21037/jtd-23-1629/rc>).

## Methods

### *Literature search criteria*

The initial search was performed using PubMed databases selecting publications in English, with no time restrictions. A further selection was achieved by filtering literature using 'aortic root redo' OR 'redo operation on aortic root' OR 'aortic root replacement after previous surgical intervention' as either keywords or MeSH terms. Studies with a population of less than 20 patients were not considered. When more than one article describing the experience of a single center was found, only the most recent one was considered. The search strategy for the review is summarized in *Table 2* and in the flowchart provided in

**Table 1** Main indications for aortic root redo surgery

No.	Indications
I	Aneurysmal dilation
II	Acute or residual dissection
III	Pseudoaneurysm, proximal suture, coronary buttons
IV	Prosthesis dysfunction, valve, aortic conduit
V	Failure of aortic valve repair
VI	Endocarditis

**Table 2** Search strategy summary

Items	Specification
Date of search	14/09/2023
Databases and other sources searched	PubMed
Search terms used	<ul style="list-style-type: none"> <li>• Aortic root redo</li> <li>• Redo operation on aortic root</li> <li>• Aortic root replacement after previous surgical intervention</li> </ul>
Timeframe	No time restrictions
Inclusion and exclusion criteria	Inclusion criteria: <ul style="list-style-type: none"> <li>• English language</li> <li>• Population of at least 20 patients</li> </ul> Exclusion criteria: <ul style="list-style-type: none"> <li>• Other recent studies from the same center</li> </ul>
Selection process	Two investigators independently reviewed each retrieved article (V.S., C.N.). The results were reviewed by two senior investigators (G.M., L.D.M.)

Figure S1. No protocol is available for this scoping review.

### **Data extraction and appraisal**

All data was extracted from article text and tables. All values are represented as numbers (percentages), mean  $\pm$  standard deviation or median. Freedom from further aortic reintervention has been analyzed by using Kaplan-Meier method. This retrospective study was approved by local institutional review board (G.D.G., D.P-10/2023), and did not require patients' informed consent.

### **Surgical technique**

The surgical strategy must be carefully planned: the main concern is to assess a safe re-entry, a proper cannulation and, if needed, cerebral protection strategy. Chest re-sternotomy is a critical moment of the procedure, and a preoperative computed tomography (CT) scan is recommended to measure the distance between the sternum and ascending aorta (or right ventricle) and to plan a safe re-entry (7).

In re-entries, our standard approach includes complete removal of the steel wires and the use of the oscillating saw. Before re-sternotomy, patient should be in anti-trendelenburg position in order to reduce the heart's filling and systolic blood pressure should be lowered under 100 mmHg. Moreover, we always prepare arterial and venous lines on the surgical field, ready for emergency cannulation: in selected high-risk patients, surgical isolation of peripheral cannulation sites could be performed before re-sternotomy.

Selection of cannulation sites has changed over the years: the employment of the femoral artery has been reduced in favor of central cannulation sites, such as the ascending aorta, aortic arch, and right axillary or innominate artery. In recent years this trend has been validated by literature, as central cannulation in redo surgery has been associated with better postoperative outcomes (8). In accordance with this, when possible, we prefer to cannulate the right axillary and the innominate artery when an arch reconstruction is also required and the ascending aorta or the aortic arch when only root procedures are planned. However, in patients with difficult re-opening at preoperative imaging, we choose to cannulate right axillary or the femoral artery. In extremely complicated re-entries or in an emergent setting cardiopulmonary bypass (CPB) may be started before or during sternotomy. This should only be considered in selected cases and it has become rarer over the years.

If coronary artery bypass grafting was performed during

the first surgery, mobilization of the coronary arteries and of patent graft should be performed carefully and can be made difficult by the presence of scarring (9).

Surgical technique depends on location of the aortic disease: in case of aortic root involvement, we can choose among different options.

The first choice is the Modified Bentall procedure with the coronary ostia reimplantation. Dissecting out the coronary buttons is the critical part of the operation, and difficulty is frequently due to the presence of felt and biologic glue. In case of reintervention on previous Bentall or in case of a massive pathology involving the coronary ostia, the Cabrol technique could be a valid alternative (10).

## **Results**

### **Literature review**

We analyzed experiences from multiple centers with aortic root redo operations. *Tables 3-5* summarize the most relevant studies on the matter of redo aortic surgery. We chose to analyze 12 studies (11-22). Most were single center, retrospective. One was a multicentric retrospective study based on inquiry of the STS database on the population of the USA. A total population of 16,627 patients across 12 studies was depicted in our analysis. The mean age was 57 years.

Indications for aortic root redo surgery are usually represented by progression of aortic disease (aneurysm or dissection), prosthesis valve or aortic conduit dysfunction or infective complications after previous surgery. Endocarditis was the indication for surgery in a total of 5,901 (35.5%) of patients (*Table 3*).

At the time of redo surgery, a Bentall procedure was performed in most cases (90%), while valve-sparing or prosthesis sparing techniques were much less common (4%). Though very variable across the studies, mean cardiopulmonary bypass and cross-clamp times were 218 and 152 minutes, respectively (*Table 4*).

Postoperative results are represented in *Table 5*. The reported in-hospital or 30-day mortality was 12%. Long-term follow-up was not available in all studies as some of them focused on short-term results.

### **Results in Bologna**

Since the early 2000s, we acquired a wide experience in redo surgery both for proximal and distal aortic disease (16,20,21). We observed a progressive increase in the frequency of

Table 3 Patients' characteristics in literature

Author	Journal, year	Type of study	Patients (n)	Mean age (years)	Marfan patients, n (%)	Bicuspid aortic valve, n (%)	Indication, n (%)			Urgent/emergent, n (%)	Time from previous surgery (months)	First operation on root, n (%)
							Endocarditis	Aneurysm	Dissection			
Malvindi et al. (11)	ATS, 2010	SC, R	46	57	5 (11)	N/A	16 (35)	30 (65)	N/A	7 (15.2)	94	46 (100)
Luciani et al. (12)	ATS, 2011	SC, R	41	63	N/A	N/A	3 (7)	29 (71)	N/A	0	N/A	6 (15)
Jassar et al. (13)	ATS, 2015	SC, R	120	50	N/A	71 (59)	60 (50)	N/A	N/A	49 (40.8)	N/A	120 (100)
Chong et al. (14)	KJTCVS, 2016	SC, R	66	45	8 (12.1)	N/A	30 (45.5)	15 (22.8)	6 (9.1)	1 (1.5)	65	17 (25.7)
Esaki et al. (15)	JTCVS, 2017	SC, R	280	52	14 (5)	72 (25.7)	50 (17.9)	N/A	6 (2.1)	N/A	112	63 (22.5)
Heubner et al. (16)	EJCTS, 2019	SC, R	130	N/A	N/A	N/A	65 (50)	37 (30.8)	1 (0.7)	N/A	N/A	50 (38.5)
Brown et al. (17)	JTCVS, 2023	SC, R	220 (redo group)	63	N/A	N/A	55 (25)	N/A	3 (4.6)	N/A	N/A	N/A
Deng et al. (18)	JCTS, 2021	SC, R	41	49	2 (4.9)	N/A	5 (12.2)	20 (48.8)	7 (17.1)	4 (9.8)	84	31 (75.6)
Mazine et al. (19)	JTCVS, 2021	SC, R	473	57	N/A	N/A	73 (15.4)	47 (10)	14 (2.9)	178 (38)	156	96 (20)
Di Marco et al. (20)	JTCVS, 2024	SC, R	218 (proximal group)	61	13 (6)	39 (17.9)	42 (19.3)	104 (47.7)	7 (3.2)	31 (14.2)	N/A	N/A
Pedroza et al. (21)	STCVS, 2023	SC, R	57	53	9 (16)	7 (13)	5 (8.8)	41 (72)	N/A	13 (22.8)	57	N/A
Ogami et al. (22)	JTCVS, 2024	MC, R	14,935	57	N/A	N/A	5,497 (36.9)	6,392 (43.9)	1,535 (10.3)	6,976 (48.5)	N/A	2,474 (16.6)
Summary	-	-	16,627	57	-	-	5,901 (35.5)	-	-	-	-	-

ATS, Annals of Thoracic Surgery; SC, single center; R, retrospective; N/A, not available; KJTCVS, Korean Journal of Thoracic and Cardiovascular Surgery; JTCVS, Journal of Thoracic and Cardiovascular Surgery; EJCTS, European Journal of Cardiothoracic Surgery; JCTS, Journal of Cardiothoracic Surgery; STCVS, Seminars in Thoracic and Cardiovascular Surgery; MC, multicentric.

**Table 4** Intraoperative variables in literature

Author	Journal, year	Type of study	Patients (n)	Type of surgery, n (%)			Cannulation site, n (%)					CPB time (min)	Cross-clamp time (min)
				Bentall	Valve/prosthesis-sparing	Pseudoaneurysm closure	Ascending aorta/arch	Axillary artery	Femoral artery	Innominate artery			
Malvindi <i>et al.</i> (11)	ATS, 2010	SC, R	46	39 (85)	0	7 (15)	21 (46)	N/A	19 (41)	N/A	193	130	
Luciani <i>et al.</i> (12)	ATS, 2011	SC, R	41	25 (61)	7 (17.1)	0	N/A	N/A	N/A	N/A	213	125	
Jassar <i>et al.</i> (13)	ATS, 2015	SC, R	120	120 (100)	0	0	N/A	N/A	N/A	N/A	290	220	
Chong <i>et al.</i> (14)	KJTCVS, 2016	SC, R	66	66 (100)	0	0	N/A	N/A	N/A	N/A	274	164	
Esaki <i>et al.</i> (15)	JTCVS, 2017	SC, R	280	233 (83.2)	47 (16.8)	0	106 (37.9)	158 (56.4)	16 (5.7)	0	240	198	
Heubner <i>et al.</i> (16)	EJCTS, 2019	SC, R	130	122 (93.8)	8 (6.1)	0	N/A	N/A	N/A	N/A	146	87	
Brown <i>et al.</i> (17)	JTCVS, 2023	SC, R	220 (redo group)	220 (100)	0	0	216 (98.2)	N/A	N/A	N/A	208	165	
Deng <i>et al.</i> (18)	JCTS, 2021	SC, R	41	41 (100)	0	0	2 (4.9)	0	39 (95.1)	0	168	84	
Mazine <i>et al.</i> (19)	JTCVS, 2021	SC, R	473	473 (100)	0	0	N/A	N/A	N/A	N/A	156	123	
Di Marco <i>et al.</i> (20)	JTCVS, 2024	SC, R	218 (proximal group)	130 (59.6)	39 (17.9)	5 (1.1)	109 (50)	18 (8.3)	73 (33.5)	16 (7.3)	167	127	
Pedroza <i>et al.</i> (21)	STCVS, 2023	SC, R	57	53 (93)	4 (7)	0	10 (18)	37 (65)	2 (3.5)	6 (11)	334	239	
Ogami <i>et al.</i> (22)	JTCVS, 2024	MC, R	14,935	13,406 (89.8)	622 (4.2)	N/A	9,976 (68)	2,348 (16)	2,365 (16.1)	319 (2.2)	224	166	
Summary	-	-	16,627	90	4	-	-	-	-	-	218	152	

CPB, cardiopulmonary bypass; ATS, *Annals of Thoracic Surgery*; SC, single center; R, retrospective; N/A, not available; KJTCVS, Korean *Journal of Thoracic and Cardiovascular Surgery*; JTCVS, *Journal of Thoracic and Cardiovascular Surgery*; EJCTS, *European Journal of Cardiothoracic Surgery*; JCTS, *Journal of Cardiothoracic Surgery*; STCVS, *Seminars in Thoracic and Cardiovascular Surgery*; MC, multicentric.

**Table 5** Postoperative results in literature

Author	Journal, year	Type of study	Patients (n)	In-hospital mortality	In-hospital mortality (cardiovascular)	5-year survival	5-year freedom from further redo	Follow-up time (months)
Malvindi <i>et al.</i> (11)	ATS, 2010	SC, R	46	3 (6.5%)	2 (66.7%)	74%	90%	18
Luciani <i>et al.</i> (12)	ATS, 2011	SC, R	41	5 (12%)	4 (80%)	80%	97%	26
Jassar <i>et al.</i> (13)	ATS, 2015	SC, R	120	6 (5%)	N/A	86.3%	89.8%	34
Chong <i>et al.</i> (14)	KJTCVS, 2016	SC, R	66	3 (4.5%)	1 (33.3%)	81.5%	N/A	55
Esaki <i>et al.</i> (15)	JTCVS, 2017	SC, R	280	40 (14.3%)	13 (32.5%)	74%	96.4%	21
Heubner <i>et al.</i> (16)	EJCTS, 2019	SC, R	130	13 (10%)	4 (30.8%)	85%	98%	60
Brown <i>et al.</i> (17)	JTCVS, 2023	SC, R	220 (redo group)	8 (12.1%)	N/A	72.9%	N/A	49
Deng <i>et al.</i> (18)	JCTS, 2021	SC, R	41	6 (14.6%)	3 (50%)	91.4%	N/A	30
Mazine <i>et al.</i> (19)	JTCVS, 2021	SC, R	473	37 (7.8%)	N/A	N/A	N/A	1
Di Marco <i>et al.</i> (20)	JTCVS, 2024	SC, R	218 (proximal group)	14 (6.4%)	10 (71.4%)	66.3%	99.5%	163
Pedroza <i>et al.</i> (21)	STCVS, 2023	SC, R	57	4 (7%)	1 (25%)	80.6%	87.7%	66
Ogami <i>et al.</i> (22)	JTCVS, 2024	MC, R	14,935	1,867 (12.5%)	N/A	N/A	N/A	1
Summary	-	-	16,627	2,006 (12%)	-	-	-	-

ATS, *Annals of Thoracic Surgery*; SC, single center; R, retrospective; KJTCVS, *Korean Journal of Thoracic and Cardiovascular Surgery*; N/A, not available; JTCVS, *Journal of Thoracic and Cardiovascular Surgery*; EJCTS, *European Journal of Cardiothoracic Surgery*; JCTS, *Journal of Cardiothoracic Surgery*; STCVS, *Seminars in Thoracic and Cardiovascular Surgery*; MC, multicentric.

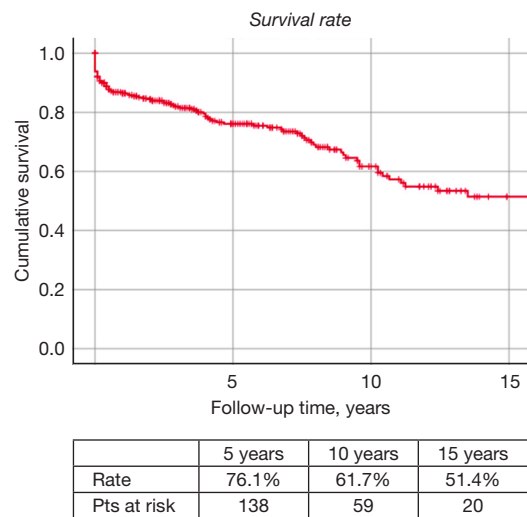
thoracic aorta reoperations through the decades (20). A total of 344 aortic root redo operations were performed at our center from January 1986 to December 2022. Indications for redo surgery were mostly related to the progression of aortic root dilatation (n=127, 36.9%), chronic or residual dissections after a previous type A dissection repair (n=89, 25.9%), endocarditis (n=65, 18.9%), pseudoaneurysm (n=40, 11.6%), acute aortic syndrome (n=11, 3.2%) and prosthesis dysfunction (n=12, 3.5%). First interventions were mostly aortic valve replacement, either isolated (n=137, 39.8%) or paired with ascending aorta replacement (n=26, 7.6%). Others were Bentall operation (n=59, 17.2%), aortic valve repair associated with procedures on the root and ascending aorta (n=21, 6.1%), ascending aorta and arch replacement (n=84, 24.4%) and other cardiac procedures (n=17, 4.9%). The mean age of our population was 58.9±13.2 years, the majority of patients were male (78.8%). Among the considered surgeries, 16% were performed as urgent. At reoperation, 162 patients (47.1%) underwent a Bentall procedure, 104 (30.2%) also received arch replacement, valve-sparing root replacement was done in 7 patients (2%)

and prosthesis sparing root replacement was performed in 59 cases (17.2%). Mean CPB and cross-clamp times were 218.0±78.8 and 158.2±49.7 minutes, respectively. Pre- and intraoperative characteristics of our population are depicted in *Table 6*. Overall, in-hospital mortality was 9.6% (including patients who underwent arch replacement). When considering only patients in which arch surgery was not performed, in-hospital mortality declined to 6.7%. Mortality was significantly higher when endocarditis was the indication (16.9%). Intensive care unit (ICU) stay was 5.1±8.2 days. Mean follow-up time was 52.3±41 months. Survival was 76.1% after 5 years and 51.4% after 15 years (*Figure 1*). Further aortic reinterventions were performed in 41 patients. The most frequent procedure at follow-up was TEVAR (n=20, 48.8%), followed by Bentall (n=8, 19.5%), arch replacement (n=5, 12.2%), pseudoaneurysm repair (n=5, 12.2%) and hemiarch replacement (n=3, 0.7%). Freedom from aortic redo of was 88.1% after 5 and 64.9% after 15 years (*Figure 2*). Causes of death at follow-up were cardiac/aortic death (15, 19.7%), neurological (12, 15.8%), septic shock (6, 7.9%),

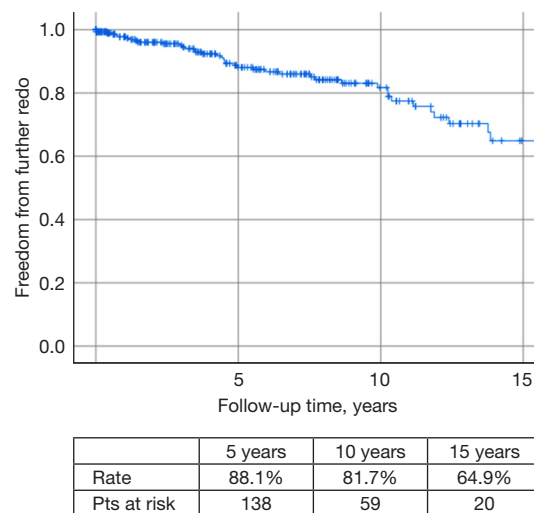
**Table 6** Preoperative and intraoperative characteristics of our population (N=344)

Variables	Values
Age (years)	58.9±13.2
Female	73 (21.2)
COPD	25 (7.3)
CKD	23 (6.7)
Hypertension	216 (62.8)
Diabetes	24 (7.0)
CAD	52 (16.6)
Smoking	105 (30.5)
CPB time	218.0±78.8
Cross-clamp time	158.2±49.7
<b>Indications</b>	
Root dilatation progression	127 (36.9)
Chronic/residual dissection	89 (25.9)
Endocarditis	65 (18.9)
Pseudoaneurysm	40 (11.6)
Acute aortic syndrome	11 (3.2)
Prosthesis dysfunction	12 (3.5)
<b>First operation</b>	
Aortic valve replacement	137 (39.8)
Aortic valve and ascending aorta replacement	26 (7.6)
Bentall	59 (17.2)
Aortic valve repair + root/ascending aorta	21 (6.1)
Ascending aorta and arch replacement	84 (24.4)
Others	17 (4.9)
<b>Surgical procedure</b>	
Bentall	162 (47.1)
Bentall + arch replacement	104 (30.2)
Cabrol	4 (1.2)
David	7 (2.0)
Prosthesis-sparing root replacement	59 (17.2)
Pseudoaneurysm repair	4 (1.2)
Others/combined	4 (1.2)

Data are presented as mean ± standard deviation or n (%). COPD, chronic obstructive pulmonary disease; CKD, chronic kidney disease; CAD, coronary artery disease; CPB, cardio-pulmonary bypass.



**Figure 1** Survival at follow-up after redo aortic root surgery at our center.

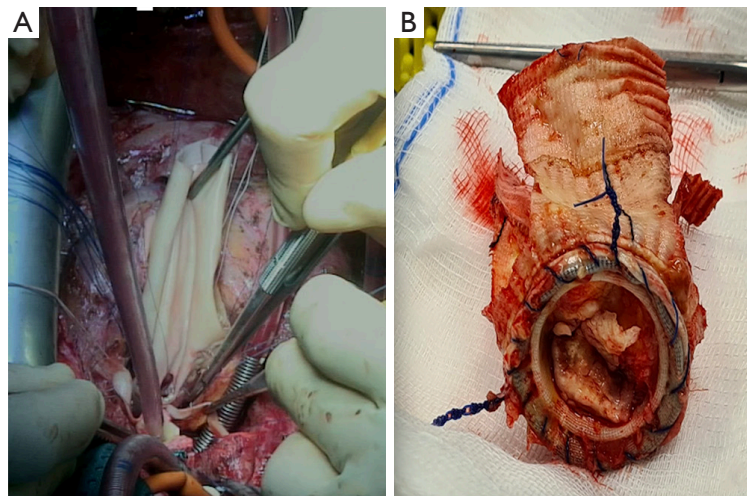


**Figure 2** Freedom from further reoperation at follow-up after redo aortic root surgery at our center.

cancer (8, 10.5%), endocarditis (2, 2.6%), multi-organ failure (1, 1.3%) and unknown (32, 42.1%).

### Discussion

Even though aortic root surgery has shown excellent results as a primary procedure, reoperations, especially in patients with previous aortic root surgery, are still challenging (23,24). Since redo aortic root surgery is very complex



**Figure 3** Intraoperative images during a case of redo root surgery for endocarditis. When endocarditis is the cause, redo surgery may require reconstruction of the aortic “annulus”, often performed with pericardial patch (A). (B) An explanted prosthesis in a patient reoperated for endocarditis.

and needs to be performed in centers with great expertise, only a limited number of studies are available in literature and not all provide long-term results and information on freedom from further reoperation. Regarding indications, endocarditis, degenerative aneurysm progression and residual dissections after replacement of the ascending aorta in acute type A aortic dissection have been reported as the most frequent (25). This is in accordance with both what we found in literature and our own experience. Also, pseudoaneurysms are observed very often: they may involve the aortic annulus, the coronary buttons reattachments, or both. They are more frequently observed in patients with connective tissue disorders or after root replacement in acute aortic dissections (26). Pseudoaneurysms often represent a technical challenge as they can be very large and reach a retrosternal position, rendering reopening particularly tricky. Therefore, they often require a careful and personalized planning for re-entry as some examples in literature show (27,28).

Another frequent etiology is infective endocarditis, which is linked to high postoperative mortality (16) and worse postoperative outcomes (13). Endocarditis might lead to the involvement of the mitro-aortic curtain, presence of abscess or fistula and, in the worst scenario, a complete detachment of a previous aortic prosthesis or conduit. In some of these cases, a reconstruction of the aortic valve annulus might be needed and is often performed at our center using pericardium patches (*Figure 3*). When the

mitro-aortic curtain is involved, with or without mitral valve endocarditis, its reconstruction might be needed requiring a “Commando” operation (29,30).

Failure in coronary reimplantation and unplanned coronary artery bypass graft (CABG) surgery represents a possible complication of this type of reintervention and a significant risk factor for patient mortality (21). In case of well-functioning prosthesis, a valid surgical option is the prosthesis-sparing reoperation first described in 2005, which consist in the replacement of the aortic root leaving aortic prosthesis in place (23,31). In some patients aortic hemiarch or arch replacement is also required, associated with increased risk of mortality and major morbidity.

The data we are here reporting from our experience seems consistent with what emerged from our literature review when considering indications for surgery, CPB and cross-clamp times, population characteristics and postoperative outcomes. Further data on the matter will, however, be necessary in order to clearly identify risk profiles for patients who might have worse outcomes after such complex procedures.

### Study limitations

The studies the present literature review is based on are all retrospective. All but one are single-center studies and the only multicentric one, based on the whole available data from the USA STS Database, comprises the vast majority



of the patients considered. This means that the sources are very hard to compare both for the highly variable number of patients and for the variables considered and the outcomes that were investigated.

## Conclusions

Reoperative aortic root surgery is being performed more and more frequently. Despite its complexity, good outcomes can be achieved with an appropriate surgical approach in high-volume aortic centers. According to our experience, outcomes are significantly worse in infective endocarditis and further redo was not frequently observed at follow-up.

## Acknowledgments

*Funding:* None.

## Footnote

*Reporting Checklist:* The authors have completed the Narrative Review reporting checklist. Available at <https://jtd.amegroups.com/article/view/10.21037/jtd-23-1629/rc>

*Peer Review File:* Available at <https://jtd.amegroups.com/article/view/10.21037/jtd-23-1629/prf>

*Conflicts of Interest:* All authors have completed the ICMJE uniform disclosure form (available at <https://jtd.amegroups.com/article/view/10.21037/jtd-23-1629/coif>). The authors have no conflicts of interest to declare.

*Ethical Statement:* The authors are accountable for all aspects of the work in ensuring that questions related to the accuracy or integrity of any part of the work are appropriately investigated and resolved.

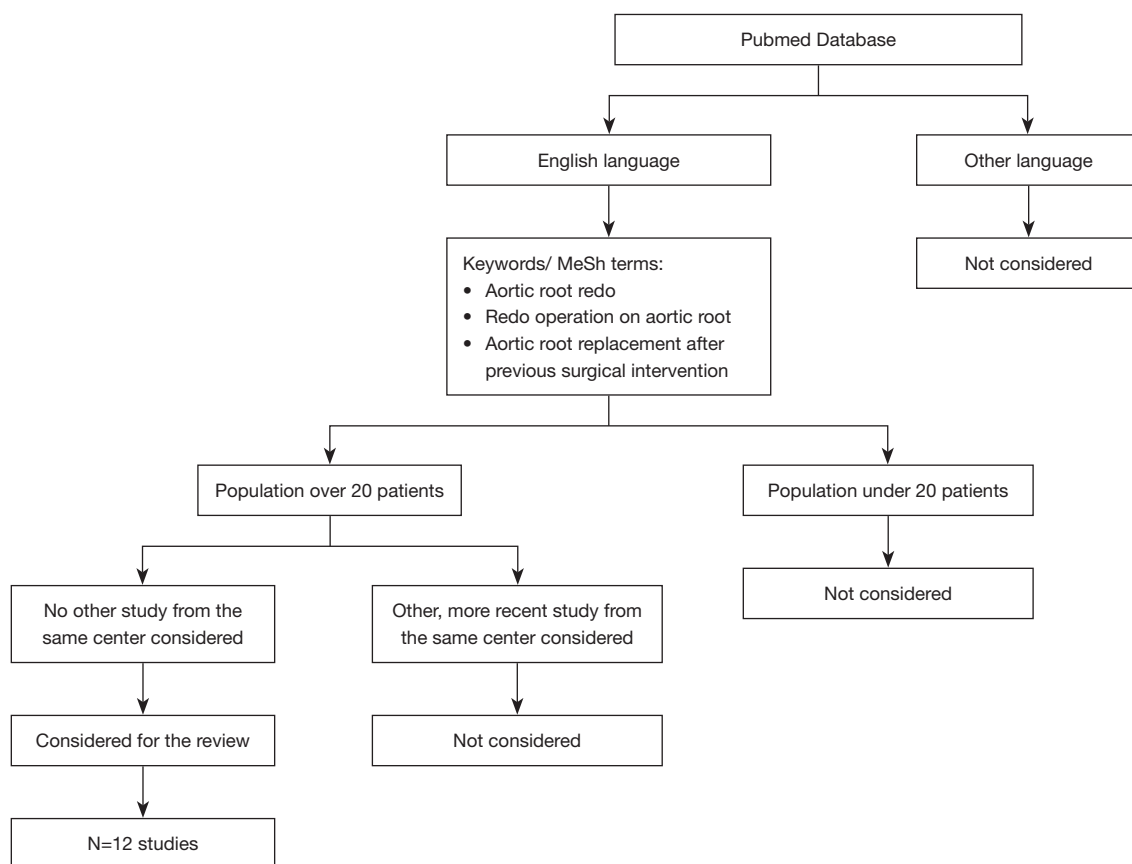
*Open Access Statement:* This is an Open Access article distributed in accordance with the Creative Commons Attribution-NonCommercial-NoDerivs 4.0 International License (CC BY-NC-ND 4.0), which permits the non-commercial replication and distribution of the article with the strict proviso that no changes or edits are made and the original work is properly cited (including links to both the formal publication through the relevant DOI and the license). See: <https://creativecommons.org/licenses/by-nc-nd/4.0/>.

## References

1. Sioris T, David TE, Ivanov J, et al. Clinical outcomes after separate and composite replacement of the aortic valve and ascending aorta. *J Thorac Cardiovasc Surg* 2004;128:260-5.
2. Zehr KJ, Orszulak TA, Mullany CJ, et al. Surgery for aneurysms of the aortic root: a 30-year experience. *Circulation* 2004;110:1364-71.
3. Wallen T, Habberthuer A, Bavaria JE, et al. Elective Aortic Root Replacement in North America: Analysis of STS Adult Cardiac Surgery Database. *Ann Thorac Surg* 2019;107:1307-12.
4. Szeto WY, Bavaria JE, Bowen FW, et al. Reoperative aortic root replacement in patients with previous aortic surgery. *Ann Thorac Surg* 2007;84:1592-8; discussion 1598-9.
5. Wang Z, Greason KL, Pochettino A, et al. Long-term outcomes of survival and freedom from reoperation on the aortic root or valve after surgery for acute ascending aorta dissection. *J Thorac Cardiovasc Surg* 2014;148:2117-22.
6. Pacini D, Di Marco L, Loforte A, et al. Reoperations on the ascending aorta and aortic root. Early and late results? *J Cardiovasc Surg (Torino)* 2005;46:491-8.
7. Di Eusanio M, Berretta P, Bissoni L, et al. Re-operations on the proximal thoracic aorta: results and predictors of short- and long-term mortality in a series of 174 patients. *Eur J Cardiothorac Surg* 2011;40:1072-6.
8. Brown JA, Kilic A, Aranda-Michel E, et al. The long-term impact of peripheral cannulation for redo cardiac surgery. *J Card Surg* 2020;35:1920-6.
9. Fukada Y, Endo Y, Kitagawa A, et al. Re-operative Cardiac Surgery in Patients with Patent In Situ Coronary Artery Bypass Grafts. *Kyobu Geka* 2022;75:911-6.
10. Ohira S, Malekan R, Kai M, et al. Safe Technique of Coronary Button Preparation in Redo Bentall Operation. *Thorac Cardiovasc Surg* 2022;70:684-6.
11. Malvindi PG, van Putte BP, Heijmen RH, et al. Reoperations on the aortic root: experience in 46 patients. *Ann Thorac Surg* 2010;89:81-6.
12. Luciani N, De Geest R, Anselmi A, et al. Results of reoperation on the aortic root and the ascending aorta. *Ann Thorac Surg* 2011;92:898-903.
13. Jassar AS, Desai ND, Kobrin D, et al. Outcomes of aortic root replacement after previous aortic root replacement: the "true" redo root. *Ann Thorac Surg* 2015;99:1601-8; discussion 1608-9.

14. Chong BK, Jung SH, Choo SJ, et al. Reoperative Aortic Root Replacement in Patients with Previous Aortic Root or Aortic Valve Procedures. *Korean J Thorac Cardiovasc Surg* 2016;49:250-7.
15. Esaki J, Leshnower BG, Binongo JN, et al. Reoperative aortic root replacement: Outcome in a contemporary series. *J Thorac Cardiovasc Surg* 2017;154:800-808.e3.
16. Heubner L, Schneider U, Giebels C, et al. Early and long-term outcomes for patients undergoing reoperative aortic root replacement. *Eur J Cardiothorac Surg* 2019;55:232-7.
17. Brown JA, Serna-Gallegos D, Kilic A, et al. Outcomes of reoperative aortic root surgery. *J Thorac Cardiovasc Surg* 2023;166:716-724.e3.
18. Deng J, Zhong Q. Clinical analysis of redo aortic root replacement after cardiac surgery: a retrospective study. *J Cardiothorac Surg* 2021;16:202.
19. Mazine A, David TE, Lafreniere-Roula M, et al. Early outcomes of the Bentall procedure after previous cardiac surgery. *J Thorac Cardiovasc Surg* 2021;162:1063-71.
20. Di Marco L, Gliozzi G, Votano D, et al. Reoperations on the ascending aorta and aortic arch: A retrospective series of 453 patients. *J Thorac Cardiovasc Surg* 2024;167:897-907.e3.
21. Pedroza AJ, Dalal AR, Krishnan A, et al. Outcomes of Reoperative Aortic Root Replacement After Previous Acute Type A Dissection Repair. *Semin Thorac Cardiovasc Surg* 2023;S1043-0679(23)00016-3.
22. Ogami T, Serna-Gallegos D, Arnaoutakis GJ, et al. The impact of reoperative surgery on aortic root replacement in the United States. *J Thorac Cardiovasc Surg* 2024;167:1185-1193.e1.
23. Di Eusanio M, Berretta P, Cefarelli M, et al. Root graft substitution after aortic valve replacement: sparing the valve prosthesis is a valid option. *Eur J Cardiothorac Surg* 2013;44:427-30.
24. Kirsch EW, Radu NC, Mekontso-Dessap A, et al. Aortic root replacement after previous surgical intervention on the aortic valve, aortic root, or ascending aorta. *J Thorac Cardiovasc Surg* 2006;131:601-8.
25. Antoniou A, Bashir M, Harky A, et al. Redo proximal thoracic aortic surgery: challenges and controversies. *Gen Thorac Cardiovasc Surg* 2019;67:118-26.
26. Orozco-Sevilla V, Whitlock R, Preventza O, et al. Redo Aortic Root Operations in Patients with Marfan Syndrome. *Int J Angiol* 2018;27:92-7.
27. Fujiwara H, Saiki Y, Nitta Y, et al. Surgical treatment of a retrosternal pseudoaneurysm arising from the posterior aortic root. *Jpn J Thorac Cardiovasc Surg* 2005;53:615-8.
28. Hussain ST, Blackstone EH, Pettersson GB. An extreme case of aortic root pseudoaneurysm after allograft root replacement: a technical challenge. *J Thorac Cardiovasc Surg* 2014;148:3232-3.
29. Chen P, Chang C, Chuang Y, et al. Modified commando procedure in complicated infective endocarditis — a case series. *J Cardiothorac Surg* 2021;16:79.
30. Quintana E, Mestres CA, Sandoval E, et al. Infective aortic valve endocarditis with root abscess formation: a mitral sparing root-Commando operation. *Ann Cardiothorac Surg* 2019;8:711-2.
31. Pacini D, Villa E, Martin-Suarez S, et al. Aortic root substitution after aortic valve replacement: a prosthesis-sparing operation. *Eur J Cardiothorac Surg* 2005;27:717-9.

**Cite this article as:** Murana G, Santamaria V, Nocera C, Campanini F, Snaidero S, Mariani C, Di Marco L, Pacini D. Reoperative aortic root surgery: single-center long-term outcomes and literature review. *J Thorac Dis* 2024;16(6):4043-4052. doi: 10.21037/jtd-23-1629



**Figure S1** Flowchart describing the search strategy.