



Bronchoscopic holmium laser ablation continuous cryoablation for the treatment of airway stenosis caused by tissue hyperplasia after tracheal intubation: clinical case observation

Qingjie Yang[^], Shenghua Lv, Qingtian Li, Linhui Lan, Xiaoyan Sun, Xinhai Feng, Kaibao Han[^]

Department of Thoracic Surgery, Xiamen Humanity Hospital, Fujian Medical University, Xiamen, China

Contributions: (I) Conception and design: Q Yang, K Han; (II) Administrative support: K Han; (III) Provision of study materials or patients: X Sun, X Feng; (IV) Collection and assembly of data: S Lv, Q Li, L Lan; (V) Data analysis and interpretation: Q Yang; (VI) Manuscript writing: All authors; (VII) Final approval of manuscript: All authors.

Correspondence to: Kaibao Han, MM. Department of Thoracic Surgery, Xiamen Humanity Hospital, Fujian Medical University, No. 3777, Xianyue Road, Huli District, Xiamen 361000, China. Email: hankaibao@163.com.

Abstract: This study aimed to design a standardised bronchoscopic holmium laser ablation continuous cryoablation for the treatment of airway stenosis caused by tissue hyperplasia after tracheal intubation and to retrospectively analyse its safety and feasibility. We collected the data of patients who had undergone bronchoscopic holmium laser ablation continuous cryoablation due to airway stenosis caused by tracheal mucosal tissue hyperplasia after tracheal intubation. The patients' baseline characteristics, ablation effects, surgical complications and other data were analysed. In total, 16 patients were enrolled in this study. On average, airway stenosis occurred 96.00 (interquartile range, 69.75–152.50) days after tracheal intubation and bronchoscopic holmium laser ablation continuous cryoablation took an average of 90.38 minutes (standard deviation: 16.78). After the first continuous cryoablation, 75.0% (12/16) of the patients had complete ablation of hyperplastic tissue, and 25.0% (4/16) had most of the hyperplastic tissue (>50%) removed. Altogether, 18.75% (3/16) and 6.25% (1/16) of the patients had complete ablation of hyperplastic tissue after the second and third cryoablation, respectively. Moreover, one patient (6.25%) had minimal wound bleeding postoperatively, and no other surgical complications occurred. No airway stenosis was found in all enrolled patients during follow-up 1 and 6 months after the last cryoablation. According to the above results of our small sample study indicated that bronchoscopic holmium laser ablation continuous cryoablation seems safe and effective for treating airway stenosis caused by tissue hyperplasia after tracheal intubation.

Keywords: Airway stenosis; tracheal intubation; bronchoscope; laser ablation; cryoablation

Submitted Jan 11, 2024. Accepted for publication May 31, 2024. Published online Jul 23, 2024.

doi: 10.21037/jtd-24-67

View this article at: <https://dx.doi.org/10.21037/jtd-24-67>

Introduction

Airway stenosis is among the complications of tracheal intubation. Among all patients requiring intubation, approximately 63% may present with various airway injuries, approximately 10–11% with airway stenosis and approximately 1–2% with clinical symptoms (1-5). Regarding

the primary cause of stenosis, the balloon used in tracheal intubation compresses the bronchial mucosa, leading to ischaemia of the bronchial mucosa and hyperplasia of granulation tissues, which blocks the airway (6,7). Another case of airway stenosis caused by tracheal intubation has also been reported. It is considered that the tracheal intubation balloon repeatedly slides up and down, stimulating the

[^] ORCID: Qingjie Yang, 0000-0002-1178-343X; Kaibao Han, 0009-0002-9541-5980.

tracheal mucosa and causing fibrous hyperplasia and eventually forms a doughnut-like annular fibrous membrane at the proximal and distal ends of the tracheal intubation balloon, respectively, thereby leading to airway stenosis. Similar multi-segmental stenosis has also been reported in previous literature (8).

Conventionally, surgical resection of the trachea's stenotic segment is used in the treatment of airway stenosis. Despite its high success rate and few complications reported in the literature, the procedure is still relatively traumatic (9,10). Alternatively, bronchoscopic interventional therapy, including cryotherapy, laser cryoablation, electrosurgery, stent implantation and so on, can be used as a key method for treating airway stenosis caused by tracheal intubation. This technique is not only minimally invasive but also effective. Based on the summary and analysis of the experience of conventional bronchoscopic interventional therapy, we began to use bronchoscopic holmium laser ablation continuous cryoablation in 2019 for the treatment of airway stenosis caused by tissue hyperplasia after tracheal intubation. This surgical plan has initially achieved satisfactory results. The present study aimed to design a standardised bronchoscopic holmium laser ablation continuous cryoablation for the treatment of airway stenosis caused by tissue hyperplasia after tracheal intubation and to retrospectively analyse its safety and feasibility. We present this article in accordance with the SUPER reporting

checklist (available at <https://jtd.amegroups.com/article/view/10.21037/jtd-24-67/rc>).

Preoperative preparations and requirements

This study was approved by the Medical Ethics Committee of Xiamen Humanity Hospital of Fujian Medical University (No. HAXM-MEC-20230913-034-01). All procedures performed in this study were in accordance with the ethical standards of the institutional and/or national research committee and with the Helsinki Declaration (as revised in 2013). Written informed consent was obtained from each patient or their legal guardians for publication of this article and accompanying images. A copy of the written consent is available for review by the editorial office of this journal. Patients who underwent bronchoscopic holmium laser ablation continuous cryoablation in our hospital due to airway stenosis after oral/nasal tracheal intubation or tracheostomy intubation from 1 October 2019 to 30 June 2023 were enrolled. The patient inclusion criteria were as follows: airway stenosis occurring after oral/nasal tracheal intubation or tracheostomy intubation; hyperplastic tissues, such as granulation tissue hyperplasia and fibroplasia, had grown into the trachea lumen, resulting in airway stenosis; and bronchoscopic holmium laser ablation continuous cryoablation was performed. The exclusion criteria were as follows: airway stenosis mainly caused by tracheal softening, collapse, scar contraction and so on, with no hyperplasia in the tracheal lumen; tracheal intubation cannot be removed after ablation, but it still needed to be retained for a long time, which affected the observation of ablation efficacy; and after ablation, the patient refused to undergo bronchoscopy or computed tomography (CT) for various reasons, or was lost to follow-up.

A total of 16 cases were enrolled, including 11 males and five females, ranging in age from 17 to 69 years old. Among the enrolled cases, seven cases had endotracheal intubation because the patients with respiratory infection could not effectively expel sputum and the infection could not be controlled. The main purpose was to aspirate sputum through endotracheal intubation. There were seven cases of type 2 respiratory failure due to chronic obstructive pulmonary disease (three cases), pulmonary contusion (two cases), immune-related interstitial pneumonia (one case), and pulmonary embolism (one case), which required ventilator assisted breathing and endotracheal intubation. One case was intubated due to airway obstruction caused by a throat tumour. One case was intubated due to high

Highlight box

Key findings

- Bronchoscopic holmium laser ablation continuous cryoablation for the treatment of airway stenosis caused by tissue hyperplasia after tracheal intubation can completely ablate the proliferative tissue in the airway, without causing proliferative re-stenosis of the airway mucosa.

What is conventional and what is novel/modified?

- The conventional treatment is either bronchoscopic laser ablation alone or cryoablation, or both at the same time without proper procedures for use.
- The modified treatment is bronchoscopic holmium laser ablation continuous cryoablation with reasonable ablation range and procedure.

What is the implication, and what should change now?

- Bronchoscopic holmium laser ablation continuous cryoablation with reasonable ablation range and procedure can overcome the shortcomings of the two ablation methods and achieve better treatment results for the treatment of airway stenosis caused by tissue hyperplasia after tracheal intubation.

paraplegia and respiratory muscle weakness. All the patients did not use drugs that could clearly cause or aggravate tracheal granulomas, had no history of intratracheal granulomas, and had no history of bronchial disease before.

Step-by-step description

Bronchoscopic holmium laser ablation continuous cryoablation

A 7.5# laryngeal mask airway (LMA) was inserted under general anaesthesia (for those who had not yet had their tracheal intubation removed, the LMA must be inserted after removal). First, a bronchoscope (Olympus Corporation, Tokyo, Japan, BF-Q290) was inserted into the trachea through the LMA to explore the internal situation. It was clear that the airway stenosis was caused by the growth of hyperplastic tissues, such as granulation tissue hyperplasia and fibroplasia, into the tracheal lumen. Subsequently, a holmium laser probe (Lumenis laser Technology Co., LTD, Beijing, China, Moses Pluse 120H) was introduced through the bronchoscope's working channel with a power of 1.0 J and a frequency of 10 Hz. The probe was attached to the free edge of the hyperplastic tissue, and the laser was emitted by clicking the switch to ablate the hyperplastic tissue. Eschar or hyperplastic tissue with shedding was removed later with biopsy forceps. When holmium laser ablation reached the root of the hyperplastic tissue, that is, when the hyperplastic tissue protruded from the tracheal surface by ≤ 2 mm, cryoablation was performed instead. Finally, the laser probe was removed, and the probe of the carbon dioxide cryosurgery machine (Beijing Kooland Medical Equipment Co., LTD, Beijing, China, K320) was introduced. The new probe was attached to the free edge of the hyperplastic tissue, and the cryostat started to freeze for 60 seconds and stopped for 30 seconds for a cycle. At each cryoablation site, three cycles were performed. Depending on the size of the hyperplastic tissue, cryoablation was performed several times to ensure that all the roots of the hyperplastic tissue were frozen. After cryoablation, the frozen tissue was not clamped or torn to avoid local bleeding. If the wound obviously oozed blood, 0.01% ice adrenaline water was sprayed to stop the bleeding. The bronchoscope was withdrawn when no active bleeding was seen in the operative area (shown in *Figure 1*).

Postoperative considerations and tasks

After ablation, the LMA was removed immediately after

the patient recovered from anaesthesia (as soon as the patient's respiratory function permitted). In the case of post-operative ventilator-assisted breathing, the LMA was removed, and the indwelling tracheal intubation was replaced. The depth of the tracheal intubation was adjusted to avoid contact between the tracheal intubation and ablation area, especially so that the balloon of the tracheal intubation was not pressed against the ablation area. In post-operative dyspnoea and other airway stenosis-related symptoms, chest CT and bronchoscopy were performed to evaluate the condition in the trachea. If the patient's post-operative condition was stable and no symptoms related to airway stenosis recurred, chest CT and bronchoscopy were performed 1 week after ablation to assess the ablation area. Additional cryoablation was carried out if hyperplastic tissues were still present in the trachea as seen by CT or bronchoscopy, regardless of dyspnoea. One month after the operation, CT or bronchoscopy was performed to determine any presence of recurrent airway stenosis. If there was no recurrent airway stenosis, no regular follow-up examination was performed unless the patient had recurrent symptoms of airway stenosis.

Tips and pearls

In the treatment of airway stenosis caused by tissue hyperplasia after tracheal intubation, for most of the hyperplasia tissue on the free side, holmium laser ablation can quickly remove the obstruction existing in the bronchial cavity. However, the ablation range should be controlled at a distance of 2 mm from the tracheal mucosa to avoid scar hyperplasia and stenosis caused by airway perforation or tracheal mucosa injury in the future. For cryoablation of the remaining hyperplastic tissue within 2 mm from the tracheal mucosa, multi-point freezing can be used to completely freeze the hyperplastic tissue as much as possible.

Discussion

Airway stenosis after tracheal intubation can result from various diseases, such as granulation tissue hyperplasia, fibre hyperplasia, scar contraction and tracheal softening (11-14). Conventionally, surgical resection of the stenotic segment of the trachea is used in airway stenosis treatment (15-17). With the development of bronchoscopic treatment technology, some relatively uncomplicated lesions, including granulation tissue hyperplasia and fibrous hyperplasia, are treated by bronchoscopic treatment first, and then surgery

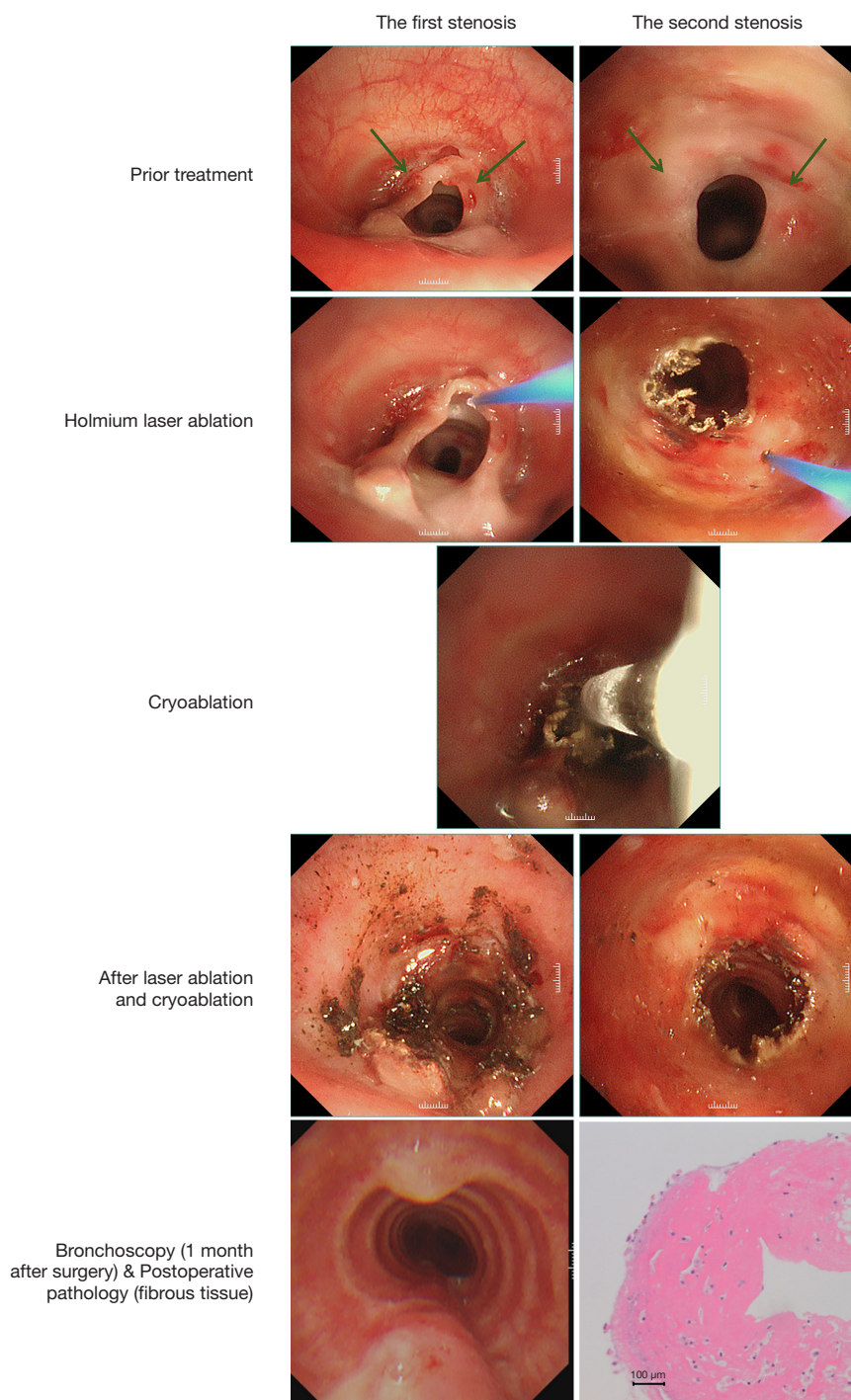


Figure 1 A case of bronchoscopic holmium laser ablation continuous cryoablation showing the process of ablation and post-operative findings. The green arrows indicate the hyperplastic tissue in the trachea. Pathological staining method: hematoxylin-eosin staining. A 17-year-old woman had coma, liver and kidney dysfunctions and cardiopulmonary insufficiency due to drug overdose. She had respiratory failure and was intubated by using an oral tube. After 21 days, tracheal intubation was removed, and she developed dyspnoea. Bronchoscopic examination showed that the trachea was located at the upper and lower edges of the original tracheal intubation balloon, and fibrous tissue was present, which led to tracheal stenosis. Bronchoscopic holmium laser ablation continuous cryoablation under general anaesthesia was performed. The post-operative pathology of the excised tissue suggested the presence of fibrous tissues. One month after the operation, the hyperplastic tissue in the trachea was completely eliminated.

is considered if the outcome is not good (18,19).

Different treatment methods under bronchoscopy have their own advantages and disadvantages (19-25). Among them, laser ablation is among the commonly used means, including carbon dioxide laser (26-28), Nd:YAG laser (29-31), holmium laser (32-34) and so on. In our hospital, the holmium laser is equipped with a thin optical fibre probe. Basically, all types of bronchoscopes can be introduced through the working channel, and the lens is not blocked; thus, the field of vision under the microscope is good. Holmium laser cryoablation can quickly eliminate hyperplastic tissues, with a tissue penetration depth of <0.4 mm and a thermal damage depth of 0.5–1.0 mm, which can reduce the damage to the surrounding tissues, especially to the bronchial membrane. However, if the power and excitation time are not well controlled during ablation, it may likely burn through the hyperplastic tissue and damage the normal tissue underneath, resulting in tracheal perforation. There is a certain risk when ablating the hyperplastic tissue close to the tracheal membrane. Even if only burning the tracheal mucosa does not lead to tracheal perforation, the later burned tracheal mucosa is easy to form scars, which may lead to restenosis. Cryoablation can ablate hyperplastic tissues close to the tracheal membrane with little damage to the normal tissue. Even if the normal tissue is frostbitten, scar formation does not easily occur in the later stage (35). However, it takes some time for the frozen tissue to fall off or be absorbed after cryoablation. Thus, pulling the hyperplastic tissue directly through the cryoprobe can easily cause bleeding, and the effect of cryohemostasis becomes unsatisfactory (8).

For the management of airway stenosis caused by tissue hyperplasia under bronchoscopic guidance, clinicians usually choose laser, cryotherapy, electrotome, stent implantation, drug injection and other means according to their own experience. Hence, there are no standardised processing steps. The therapeutic effects of different reports are also very different. Certainly, if a patient's airway stenosis has already caused respiratory difficulties, the initial step would be tracheal intubation or tracheostomy to ensure an unobstructed airway. Following this, based on our experience, most of the hyperplastic tissues on the free side can be ablated with a holmium laser first, which quickly removes the obstruction present in the bronchial cavity, but it cannot be ablated too deeply. Given that the thermal damage depth of the holmium laser is 0.5–1.0 mm, the ablation range of the holmium laser should be controlled at a distance of 2 mm from the tracheal mucosa, so as to

avoid the development of scar hyperplasia and stricture later, which are caused by perforation of the airway or injury to the tracheal mucosa. The remaining hyperplastic tissues within 2 mm that are close to the tracheal mucosa will undergo cryoablation, and the cryoablation tissue will eventually and gradually fall off. Given that cryoablation causes less damage to the bronchial mucosa, scar hyperplasia can occur; hence, it can be frozen at multiple points, and the hyperplastic tissue can be completely frozen as far as possible. Holmium laser ablation continuous cryoablation can remove hyperplastic tissues more thoroughly while reducing trauma and risk for complications. In this study, altogether, 16 patients, including 11 men and five women with a median age of 35.0 [interquartile ranges (IQRs), 27.5–62.8] years, who met the inclusion and exclusion criteria were included. Patients endotracheal intubated due to pulmonary infection and respiratory failure accounted for the highest percentage, each making up 43.75% (7/16). Furthermore, 6.25% (1/16) were intubated due to high paraplegia and respiratory muscle weakness, and 6.25% (1/16) of the patients were intubated due to airway obstruction caused by the presence of a throat tumour. This case of throat cancer was supraglottic laryngeal squamous cell carcinoma. Due to airway obstruction, the patient was treated with tracheotomy and intubation to keep the airway open, and then underwent carbon dioxide laser surgery, and remove the intubation after the postoperative recovery was good. The patient did not receive radiotherapy or chemotherapy during intubation. Altogether, 12.5% (2/16) of the patients were intubated only by an oral tube, 12.5% (2/16) only by a nasotracheal tube, and 50.0% (8/16) were intubated by oral tube before tracheotomy; moreover, 25.0% (4/16) were directly intubated by tracheotomy. Tracheotomy refers to the incision of the trachea at the neck level and the insertion of a metal or silicone tracheal tube. During bronchoscopic continuous cryoablation, the tracheal intubation was still not removed in 10 patients, whereas, in the remaining 6 patients, the tracheal tube was removed. The intermediate time from tracheal intubation to airway stenosis was 96.00 (IQRs, 69.75–152.50) days. Trachea cross-sectional area at the stenosis was 246.55 (IQRs, 190.41–281.04) mm². Altogether, 12.5% (2/16), 62.5% (10/16) and 25.0% (4/16) of the patients had airway stenosis of $\leq 25\%$, 26–50% and 51–75%, respectively. The degree of airway stenosis was referred to as the cross section of the trachea at airway stenosis and the percentage of the blocked airway area to the total airway area.

Bronchoscopic holmium laser ablation continuous

Table 1 The statistical results of the observation indicators

Variables	Statistical results
Sex, n (%)	
Male	11 (68.75)
Female	5 (31.25)
Age (years), median (IQRs)	35.0 (27.5–62.8)
Reasons for indwelling tracheal intubation, n (%)	
Pulmonary infection	7 (43.75)
Respiratory failure	7 (43.75)
Throat tumor	1 (6.25)
High paraplegia	1 (6.25)
Intubation method, n (%)	
Nasal tracheal intubation	2 (12.50)
Oral tube intubation	2 (6.25)
Tracheotomy cannula	12 (75.00)
Indwelling tracheal intubation time (days), median (IQRs)	96.00 (69.75–152.50)
Distance between the airway stenosis and the glottis (cm), mean (SD)	3.03 (0.62)
Causes of airway stenosis, n (%)	
Granulation tissue hyperplasia	10 (62.50)
Fibrohyperplasia	6 (37.50)
Trachea cross-sectional area at the stenosis (mm ²), median (IQRs)	246.55 (190.41–281.04)
Degree of airway stenosis, n (%)	
≤25%	2 (12.50)
26–50%	10 (62.50)
51–75%	4 (25.00)
>75%	0
Operative time (min), mean (SD)	90.38 (16.78)
Ablation frequency, n (%)	
1 time	12 (75.00)
2 times	3 (18.75)
3 times	1 (6.25)
Ablation effect, n (%)	
Completely cleared hyperplastic tissue	12 (75.00)
Mostly cleared hyperplastic tissue (>50%)	4 (25.00)

Table 1 (continued)**Table 1** (continued)

Variables	Statistical results
Partially cleared hyperplastic tissue (<50%)	0
Ineffective	0
Operative complications, n (%)	
Wound oozed blood	1 (6.25)
Other complications	0
Recurrent airway stenosis, n (%)	
1 month after surgery	0
6 months after surgery	0

IQRs, interquartile ranges; SD, standard deviation.

cryoablation took an average of 90.38 [standard deviation (SD): 16.78] minutes. After the first continuous cryoablation, 75.0% (12/16) of the patients had complete ablation of hyperplastic tissue, and 25.0% (4/16) had most of the hyperplastic tissue (>50%) removed. Moreover, 18.75% (3/16) and 6.25% (1/16) of patients had complete ablation of hyperplastic tissue after the second and third cryoablation, respectively. Only one patient (6.25%) had minimal wound bleeding postoperatively, and the bleeding was stopped after spraying 0.01% ice adrenaline water under bronchoscopy again. The remaining patients had a smooth operative course without other complications. No airway stenosis was found in all patients during the follow-up visit 1 and 6 months after the operation (shown in *Table 1*).

Given that the range of holmium laser cryoablation is controlled at a distance of 2 mm away from the bronchial mucosa, it does not cause damage to the bronchial mucosa, whereas cryoablation may slightly damage the bronchial mucosa, but it generally does not cause scar hyperplasia and can also promote the regeneration of bronchial mucosa epithelium (36,37). This may be the main reason why no recurrent tracheal stenosis was found in all studied cases after the hyperplastic tissue was completely eliminated.

To sum it up, bronchoscopic holmium laser ablation continuous cryoablation is a reasonable and optimal ablation technique designed according to the characteristics of holmium laser ablation and cryoablation. With a distance of 2 mm from bronchial mucosa as the boundary, laser ablation at the edge and freezing ablation at the root can completely eliminate tracheal hyperplasia and reduce tracheal damage and incidence of complications and airway restenosis.

The present study has several limitations. It must be pointed out that our study is only a small retrospective investigation, and the conclusions may be one-sided. As most patients refused to undergo CT or bronchoscopy due to fear of discomfort, we only followed up with the patients at 1 and 6 months after the operation. Although no patient reported any symptoms of recurrent airway stenosis in the long term, we still cannot conclude that all patients did not have recurrent airway stenosis postoperatively. Additionally, it is unknown whether other combinations of holmium laser ablation power and freezing time can achieve better results because the number of cases analysed was small, and we do not have the conditions to do relevant research to investigate this. Similarly, because of the small number of patients analysed, we are unable to do a comparative study of holmium laser ablation continuous cryoablation under bronchoscopy with laser ablation alone, cryoablation alone or surgery. In other words, it remains unclear whether holmium laser ablation continuous cryoablation under bronchoscopy can be recommended for the treatment of airway stenosis caused by tissue hyperplasia; hence, a more large-scale prospective comparative study is required in the future to investigate this.

Conclusions

In the present study, with a small sample size, bronchoscopic holmium laser ablation continuous cryoablation seems to be safe and effective in the treatment of airway stenosis caused by tissue hyperplasia after tracheal intubation. However, a large sample prospective comparative study is still needed to demonstrate its application prospect.

Acknowledgments

The authors would like to express gratitude to Dr. Zhinuan Hong (Department of Thoracic Surgery, Fujian Medical University Union Hospital) for his valuable insights and contributions to the writing of this article.

Funding: None.

Footnote

Reporting Checklist: The authors have completed the SUPER reporting checklist. Available at <https://jtd.amegroups.com/article/view/10.21037/jtd-24-67/rc>

Peer Review File: Available at <https://jtd.amegroups.com/>

[article/view/10.21037/jtd-24-67/prf](https://jtd.amegroups.com/article/view/10.21037/jtd-24-67/prf)

Conflicts of Interest: All authors have completed the ICMJE uniform disclosure form (available at <https://jtd.amegroups.com/article/view/10.21037/jtd-24-67/coif>). The authors have no conflicts of interest to declare.

Ethical Statement: The authors are accountable for all aspects of the work in ensuring that questions related to the accuracy or integrity of any part of the work are appropriately investigated and resolved. This study was approved by the Medical Ethics Committee of Xiamen Humanity Hospital of Fujian Medical University (No. HAXM-MEC-20230913-034-01). All procedures performed in this study were in accordance with the ethical standards of the institutional and/or national research committee and with the Helsinki Declaration (as revised in 2013). Written informed consent was obtained from each patient or their legal guardians for publication of this article and accompanying images. A copy of the written consent is available for review by the editorial office of this journal.

Open Access Statement: This is an Open Access article distributed in accordance with the Creative Commons Attribution-NonCommercial-NoDerivs 4.0 International License (CC BY-NC-ND 4.0), which permits the non-commercial replication and distribution of the article with the strict proviso that no changes or edits are made and the original work is properly cited (including links to both the formal publication through the relevant DOI and the license). See: <https://creativecommons.org/licenses/by-nc-nd/4.0/>.

References

1. Esteller-Moré E, Ibañez J, Matión E, et al. Prognostic factors in laryngotracheal injury following intubation and/or tracheotomy in ICU patients. *Eur Arch Otorhinolaryngol* 2005;262:880-3.
2. Geffin B, Grillo HC, Cooper JD, et al. Stenosis following tracheostomy for respiratory care. *JAMA* 1971;216:1984-8.
3. Herrak L, Ahid S, Abouqal R, et al. Tracheal stenosis after intubation and/or tracheostomy. *Egyptian Journal of Chest Diseases and Tuberculosis* 2014;63:233-7.
4. Stauffer JL, Olson DE, Petty TL. Complications and consequences of endotracheal intubation and tracheotomy. A prospective study of 150 critically ill adult patients. *Am J Med* 1981;70:65-76.

5. Uğur Chousein EG, Özgül MA. Postintubation tracheal stenosis. *Tuberk Toraks* 2018;66:239-48.
6. Wain JC Jr. Postintubation tracheal stenosis. *Semin Thorac Cardiovasc Surg* 2009;21:284-9.
7. Wright CD, Li S, Geller AD, et al. Postintubation Tracheal Stenosis: Management and Results 1993 to 2017. *Ann Thorac Surg* 2019;108:1471-7.
8. Hosna A, Haseeb Ul Rasool M, Noff NC, et al. Cryotherapy for the Treatment of Tracheal Stenosis: A Systematic Review. *Cureus* 2023;15:e41012.
9. Kanlikama M, Celenk F, Gonuldas B, et al. Cervical Tracheal Resection and Anastomosis for Postintubation Tracheal Stenosis. *J Craniofac Surg* 2018;29:e578-82.
10. Ezemba N, Echieh CP, Chime EN, et al. Postintubation tracheal stenosis: Surgical management. *Niger J Clin Pract* 2019;22:134-7.
11. Zias N, Chroneou A, Tabbu MK, et al. Post tracheostomy and post intubation tracheal stenosis: report of 31 cases and review of the literature. *BMC Pulm Med* 2008;8:18.
12. Sarper A, Ayten A, Eser I, et al. Tracheal stenosis after tracheostomy or intubation: review with special regard to cause and management. *Tex Heart Inst J* 2005;32:154-8.
13. Murgu SD, Egressy K, Laxmanan B, et al. Central Airway Obstruction: Benign Strictures, Tracheobronchomalacia, and Malignancy-related Obstruction. *Chest* 2016;150:426-41.
14. Gelbard A, Francis DO, Sandulache VC, et al. Causes and consequences of adult laryngotracheal stenosis. *Laryngoscope* 2015;125:1137-43.
15. Elsayed H, Mostafa AM, Soliman S, et al. First-line tracheal resection and primary anastomosis for postintubation tracheal stenosis. *Ann R Coll Surg Engl* 2016;98:425-30.
16. Majeed FA, Khan YS, Sheikh NA, et al. Outcome of Post-intubation Tracheal Stenosis (PITS) with Primary Resection and Anastomosis. *J Coll Physicians Surg Pak* 2022;32:373-6.
17. Ulasan A, Sanli M, Isik AF, et al. Surgical treatment of postintubation tracheal stenosis: A retrospective 22-patient series from a single center. *Asian J Surg* 2018;41:356-62.
18. Galluccio G, Lucantoni G, Battistoni P, et al. Interventional endoscopy in the management of benign tracheal stenoses: definitive treatment at long-term follow-up. *Eur J Cardiothorac Surg* 2009;35:429-33; discussion 933-4.
19. Ravikumar N, Ho E, Wagh A, et al. The role of bronchoscopy in the multidisciplinary approach to benign tracheal stenosis. *J Thorac Dis* 2023;15:3998-4015.
20. Wierzbicka M, Tokarski M, Puszczewicz M, et al. The efficacy of submucosal corticosteroid injection and dilatation in subglottic stenosis of different aetiology. *J Laryngol Otol* 2016;130:674-9.
21. Jeong BH, Um SW, Suh GY, et al. Results of interventional bronchoscopy in the management of postoperative tracheobronchial stenosis. *J Thorac Cardiovasc Surg* 2012;144:217-22.
22. Bi Y, Yu Z, Ren J, et al. Metallic stent insertion and removal for post-tracheotomy and post-intubation tracheal stenosis. *Radiol Med* 2019;124:191-8.
23. Wu CY, Liu YH, Hsieh MJ, et al. Airway stents in management of tracheal stenosis: have we improved? *ANZ J Surg* 2007;77:27-32.
24. Yu Z, Wang J, Liang XH, et al. Placing covered self-expanding metal stents by suspension laryngoscope in benign tracheal stenosis. *Am J Otolaryngol* 2021;42:103040.
25. Smith ME, Elstad M. Mitomycin C and the endoscopic treatment of laryngotracheal stenosis: are two applications better than one? *Laryngoscope* 2009;119:272-83.
26. Ozkul Y, Songu M, Imre A, et al. CO₂ laser treatment of tracheal stenosis. *Acta Otolaryngol* 2015;135:1160-2.
27. Whitehead E, Salam MA. Use of the carbon dioxide laser with the Montgomery T-tube in the management of extensive subglottic stenosis. *J Laryngol Otol* 1992;106:829-31.
28. Ossoff RH, Tucker GF Jr, Duncavage JA, et al. Efficacy of bronchoscopic carbon dioxide laser surgery for benign strictures of the trachea. *Laryngoscope* 1985;95:1220-3.
29. Gelb AF, Epstein JD. Nd-YAG laser treatment of tracheal stenosis. *West J Med* 1984;141:472-5.
30. Mehta AC, Lee FY, Cordasco EM, et al. Concentric tracheal and subglottic stenosis. Management using the Nd-YAG laser for mucosal sparing followed by gentle dilatation. *Chest* 1993;104:673-7.
31. Rau BK, Harikrishnan KM, Krishna S. Neodymium: YAG laser in the management of tracheal stenosis. *Ann Acad Med Singap* 1994;23:333-4.
32. Verret DJ, Jategaonkar A, Helman S, et al. Holmium Laser for Endoscopic Treatment of Benign Tracheal Stenosis. *Int Arch Otorhinolaryngol* 2018;22:203-7.
33. Deshmukh A, Jadhav S, Wadgaonkar V, et al. Airway Management and Bronchoscopic Treatment of Subglottic and Tracheal Stenosis Using Holmium Laser with Balloon Dilatation. *Indian J Otolaryngol Head Neck Surg* 2019;71:453-8.
34. Castellanos P, Mk M, Atallah I. Laser

- tracheobronchoplasty: a novel technique for the treatment of symptomatic tracheobronchomalacia. *Eur Arch Otorhinolaryngol* 2017;274:1601-7.
35. Xie BS, Ye L, Li GP, et al. Effects of different time of cryoablation on the proliferation of airway traumatic granuloma and its mechanism in rabbits. *Zhonghua Yi Xue Za Zhi* 2018;98:3587-91.
36. Krinsky WS, Broussard JN, Sarkar SA, et al. Bronchoscopic spray cryotherapy: assessment of safety and depth of airway injury. *J Thorac Cardiovasc Surg* 2010;139:781-2.
37. Janke KJ, Abbas AE, Ambur V, et al. The Application of Liquid Nitrogen Spray Cryotherapy in Treatment of Bronchial Stenosis. *Innovations (Phila)* 2016;11:349-54.

Cite this article as: Yang Q, Lv S, Li Q, Lan L, Sun X, Feng X, Han K. Bronchoscopic holmium laser ablation continuous cryoablation for the treatment of airway stenosis caused by tissue hyperplasia after tracheal intubation: clinical case observation. *J Thorac Dis* 2024;16(7):4693-4701. doi: 10.21037/jtd-24-67