



Systematic review and meta-analysis of the efficacy and safety of high-intensity focused ultrasound combined with transarterial chemoembolization and transarterial chemoembolization alone in the treatment of liver cancer

Jie Hu¹, Huiping Mao², Yaxi He³

¹Department of Radiology Oncology, Taizhou Central Hospital (Taizhou University Hospital), Taizhou, China; ²Department of Nursing, Taizhou First People's Hospital (Huangyan Hospital affiliated to Wenzhou Medical University), Taizhou, China; ³Department of General Surgery, Taizhou First People's Hospital (Huangyan Hospital affiliated to Wenzhou Medical University), Taizhou, China

Contributions: (I) Conception and design: J Hu, Y He; (II) Administrative support: H Mao; (III) Provision of study materials or patients: All authors; (IV) Collection and assembly of data: J Hu, Y He; (V) Data analysis and interpretation: Y He, H Mao; (VI) Manuscript writing: All authors; (VII) Final approval of manuscript: All authors.

Correspondence to: Yaxi He. Taizhou First People's Hospital, No. 218, Hengjie Road, Huangyan District, Taizhou, China. Email: heyx986824@163.com.

Background: High-intensity focused ultrasound (HIFU) and transarterial chemoembolization (TACE) have been shown to be effective in the treatment of malignant tumors such as hepatocellular carcinoma. In recent years, HIFU combined with TACE has been frequently reported, but researchers have not yet reached a uniform conclusion on the efficacy and safety of this treatment modality.

Methods: The Chinese National Knowledge Infrastructure (CNKI), China Biomedical Literature Database, Cochrane Library, MEDLINE, and Embase databases were searched using the terms “randomized controlled trial (RCT)”, “liver cancer”, “transarterial chemoembolization”, “TACE”, “high intensity focused ultrasound”, “HIFU”, “HIFU combined with TACE”, and “efficacy analysis”. Studies were included in accordance with the PICOS principle, and risk of bias was assessed in randomized controlled trials in accordance with the Cochrane Manual for Systematic Evaluation of Interventions. Rev Man 5.3 and Stata 13 were employed for meta-analysis.

Results: Six randomized controlled trials with a total sample size of 488 were included in this study. Of these studies, 5 described a random allocation (RA) method, 4 described allocation sequence concealment, and 4 used a blind method for the allocation of study subjects. The results of the meta-analysis showed that the 1-year [odds ratio (OR) =3.13, 95% CI: 1.92, 5.11, P<0.00001], 2-year (OR =3.38, 95% CI: 1.71, 6.66, P=0.0004), and 5-year (OR =2.15, 95% CI: 1.02, 4.55, P=0.04) survival rates (SRs) of patients treated with HIFU + TACE were significantly better than those of patients treated with TACE alone. The total effective rate (TER) of patients treated with HIFU + TACE (OR =3.61, 95% CI: 2.14, 6.08, P<0.00001) was significantly better than that of patients treated with TACE alone. Compared with TACE alone, HIFU combined with TACE significantly reduced the incidence of postoperative adverse reactions (OR= 0.57, 95% CI: 0.34, 9.96, P=0.03).

Discussion: Meta-analysis was adopted in this study, and it was found that compared with TACE alone, HIFU combined with TACE in the treatment of LC had better efficacy, higher prognosis and survival rate, and lower incidence of adverse reactions. However, due to the limited sample size of the study, there was some risk of bias in the findings.

Keywords: High-intensity focused ultrasound (HIFU); transarterial chemoembolization (TACE); liver cancer (LC); meta-analysis

Submitted Apr 02, 2022. Accepted for publication Jun 01, 2022.

doi: 10.21037/tcr-22-1094

View this article at: <https://dx.doi.org/10.21037/tcr-22-1094>

Introduction

Liver cancer (LC) is a common tumor in China, with 466,100 new cases reported by The National Cancer Center in 2018. The rate of death after onset of LC is very high (1,2). LC occurs more commonly in rural areas and in males, and the incidence increases with age. At present, LC can be classified into primary and secondary LC according to the origin of the cancer cells (3). Primary LC originates in liver cells, while secondary LC is formed by metastasis in other organs of the body. Hepatocellular carcinoma (HCC), cholangiocarcinoma or intrahepatic cholangiocarcinoma (ICC), hemangiosarcoma and hemangioendothelioma, and hepatoblastoma (4,5) are all considered types of LC. Early-stage LC is usually asymptomatic. Patients may suffer from appetite loss, abdominal pain and bloating, unexplained weight loss, and yellowing of the skin and sclera (6). Dynamic contrast-enhanced magnetic resonance imaging (MRI), computed tomography (CT), ultrasonography, and selective hepatic arteriography are common imaging methods for LC. Depending on the type and stage of LC, different treatment methods can be selected. These include local treatment methods such as surgery, ablation, and embolization, or systemic treatment methods such as targeted therapy, immunotherapy, and chemotherapy (7).

Ablation is commonly used for patients with small tumor lesions that can be cured by surgery. Ablation is most effective for LCs no larger than 3 cm. For slightly larger LCs (3–5 cm), ablation can be used together with chemoembolization (an interventional approach). In recent years, high-intensity focused ultrasound (HIFU) has been used as a tumor treatment method. Ultrasound can be used to achieve precise localization of the tumor lesions and deliver subsequent thermal tumor ablation therapy (8,9).

Interventional embolization is a treatment method in which drugs are injected directly into tumor blood vessels to reduce or block the blood supply to LC lesions (10). Common HCC embolization methods include hepatic transarterial embolization (TAE), transarterial chemoembolization (TACE), drug-eluting bead TACE (DEB-TACE), and radioembolization (RE) (11). The treatment process of TACE is similar to TAE. The drugs introduced are chemotherapeutic drugs, which not only block the arteries that supply oxygen and nutrition to the tumor, but also direct the chemotherapeutic drugs into the tumor to kill cancer cells. The most commonly used chemotherapy drugs are mitomycin C, daunorubicin, and cisplatin (12).

However, TACE is recognized as the preferred treatment

for intermediate and advanced primary LC. Currently, TACE is faced with problems such as low complete necrosis rate and limited long-term efficacy, and repeated use of TACE can affect patients' liver function. Comprehensive treatment based on TACE and HIFU has gradually become one of the research hotspots in the clinical treatment of LC patients in recent years due to its non-invasive and ability to enhance patients' immunity and further kill the remaining tumor cells. Multiple reports indicated that TACE combined with HIFU has obvious complementary synergistic effect in the treatment of primary LC, which can effectively prolong the long-term survival of patients. Both theory and clinical practice showed that TACE plus HIFU has a good application prospect (13,14), but there is still no unified conclusion on the therapeutic effect, prognosis, and survival and the occurrence of adverse reactions of TACE combined with HIFU and TACE alone in LC patients, and there is still a lack of due research efforts on this treatment mode. There is also a lack of comprehensive analysis articles on such studies. In this study, the intervention effects of TACE combined with HIFU and TACE alone on LC patients were quantitatively analyzed and summarized by systematic evaluation and meta-analysis methods, hoping to provide scientific evidence-based basis for the selection and optimization of treatment plans for LC patients. We present the following article in accordance with the PRISMA reporting checklist (available at <https://tcr.amegroups.com/article/view/10.21037/tcr-22-1094/rc>).

Methods

Article screening

To study the difference between HIFU combined with TACE and TACE alone in the therapeutic effect and safety of LC patients, the China National Knowledge Internet (CNKI), Chinese Biomedical Literature Database, Cochrane Library, Medline, Embase, and other databases were searched. The Boolean logic retrieval method was used, and the databases were searched using the following search items: “randomized controlled trial”, “liver cancer”, “transarterial chemoembolization”, “TACE”, “high intensity focused ultrasound”, “HIFU”, “HIFU combined with TACE”, “HIFU + TACE”, and “efficacy analysis”. These search terms were freely combined to retrieve the required literature. randomised controlled trials (RCTs) of patients with LC receiving TACE alone or HIFU + TACE published before November 2021 were retrieved, and the relevant articles were manually searched. After the titles and abstracts

were read, any articles that did not meet the selection criteria given in the next section were excluded. The literature was screened again according to the criteria and then traced using a search engine. Finally, the full texts of the obtained articles were read to evaluate the quality. Meta-analyses were performed using RevMan 5.3 (Cochrane, London, UK) and Stata 13 (StataCorp LLC, College Station, TX, USA) software as directed by the *Cochrane Handbook for Systematic Reviews of Interventions*.

Inclusion and exclusion criteria

The inclusion criteria were as follows: (I) the research design was a RCT; (II) the article was published in a journal; (III) the article mentioned the clinical application of HIFU or TACE to treat LC; (IV) the grouping method used in the article was HIFU + TACE as 1 group and TACE alone as 1 group; and (V) the articles contained complete data, including patient observation indicators.

The exclusion criteria were as follows: (I) articles without clear clinical diagnostic results; (II) articles that consisted of case reports, reviews, or expert experience; and (III) articles without randomization.

Observation indicators

The main observation indicators included postoperative survival rate (SR; 6 months, 1 year, 2 years, 3 years, and 5 years), total effective rate (TER), aspartate aminotransferase (AST) level, alanine aminotransferase (ALT) level, mature T lymphocyte (CD3+) level, induced T cell/helper T cell (CD4+) level, suppressor T cell/cytotoxic T cell (CD8+), natural killer (NK) cell level, and the incidence of adverse reactions.

Data extraction

The data extraction and literature quality evaluation were conducted as follows. All data were extracted independently by 2 reviewers using Microsoft Excel. When the reviewers disagreed, a consensus was obtained through mutual discussion or consultation with relevant experts. The data to be extracted included first author, topic, study time, sample size, and grouping.

Quality assessment

The articles were screened independently according to the

above criteria by 2 experts. The risk of bias of the RCTs was comprehensively assessed according to the *Risk-of-Bias Assessment Tool for Randomized Controlled Trials* in the *Cochrane RoB 2.0*. The specific evaluation contents included RA method, concealed allocation method, blinding, completeness of outcome data, selective reporting of research results, and other sources of bias. The articles were divided into 3 grades based on the above criteria: grade A (low), grade B (moderate), and grade C (high).

Statistical methods

Statistical analysis was performed using Stata SE 12.0 (College Station, USA). The risk bias of the included references was assessed using the bias risk assessment map of Rev Man 5.3. Mean difference (MD) was used for continuous variables, standardized mean difference (SMD) was used for discrete variables, and odds ratio (OR) was used for discontinuous variables. The effect size was hazard ratio (HR) or odds ratio (OR) and 95% confidence interval (CI). χ^2 test was used for heterogeneity among included studies. When there was statistical homogeneity between studies ($P > 0.1$, $F < 50\%$), the fixed effect model was adopted. If there was statistical heterogeneity among studies ($P < 0.1$, $F > 50\%$), the source of heterogeneity was analyzed, and subgroup analysis was performed according to the factors that may lead to heterogeneity. When there was sufficient similarity between studies within and between subgroups (subgroup $P > 0.1$, $F < 50\%$), the meta-analyzed was conducted using fixed effect model. If there was statistical heterogeneity among the subgroups but no clinical heterogeneity or the clinical differences were not statistically significant, the random-effect model was used for analysis. If there was too much heterogeneity between the two groups, descriptive analysis was used. The stability of the results was tested by sensitivity analysis when necessary. If there was only one study in the subgroup, the efficacy and safety analysis of the study still used the same statistics as the meta-analysis.

Results

Search results

A total of 735 articles were obtained, and 590 remained after the removal of duplicate articles ($n=56$), unqualified articles automatically screened by the system ($n=42$), and articles deleted for other reasons ($n=47$). After the abstracts and titles of the articles were read, 458 articles were removed.

Table 1 Basic information of the included articles

The first author	Year of publication	Number of cases	Experimental group (HIFU + TACE)	Control group (TACE alone)	Follow-up time (years)	Quality score
Gu L. (15)	2022	37	25	12	2	4
Li C. (16)	2010	89	44	45	5	3
Luo Y. (17)	2019	90	45	45	1	2
Sun M. (18)	2021	122	68	54	3	3
Wu F. (19)	2005	50	24	26	1	1
Zhang Q. (20)	2019	100	50	50	3	4

HIFU, high-intensity focused ultrasound; TACE, transarterial chemoembolization.

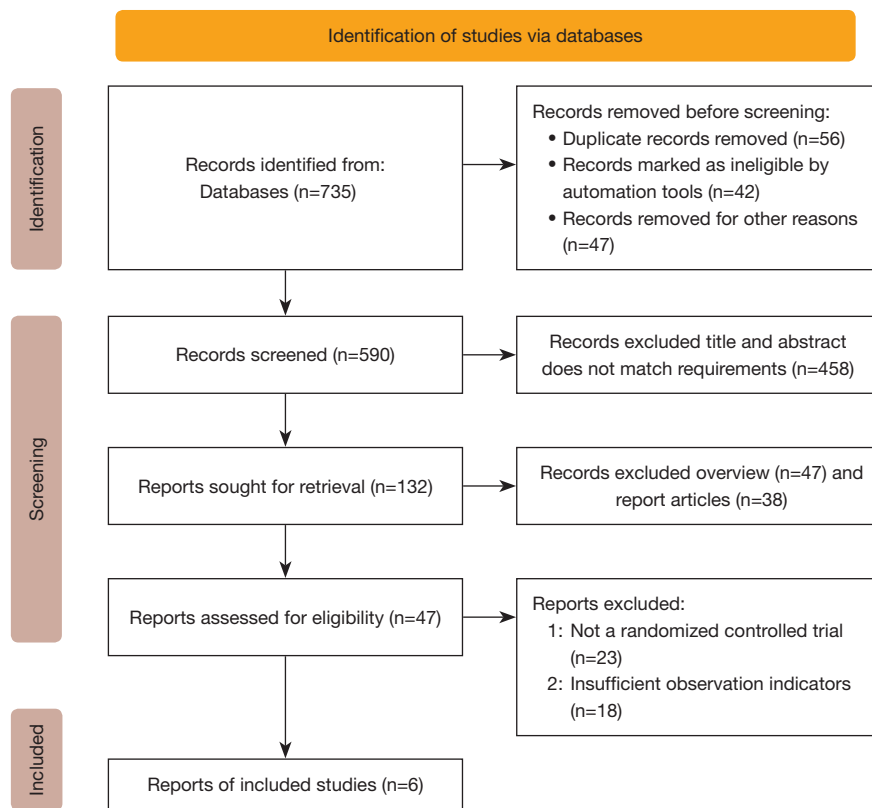


Figure 1 Process of article retrieval. RCT, randomized controlled trial.

A further 47 review articles and 38 research reports were removed, with 47 articles remaining. After reading the full text, we excluded 23 articles that were not RCTs and 18 articles with insufficient indicators. A total of 6 articles were finally included in the study.

The 6 articles (15-20) selected for meta-analysis included a total of 488 patients. The sample sizes were small, ranging from 12 to 68 cases. The authors, publication year, sample

size, treatment method, grouping, and follow-up time were described in detail in the articles. *Table 1* presents the included articles and their basic information, while *Figure 1* details the process of article retrieval.

Risk-of-bias assessment results

Figures 2,3 present the results of the risk-of-bias assessment.

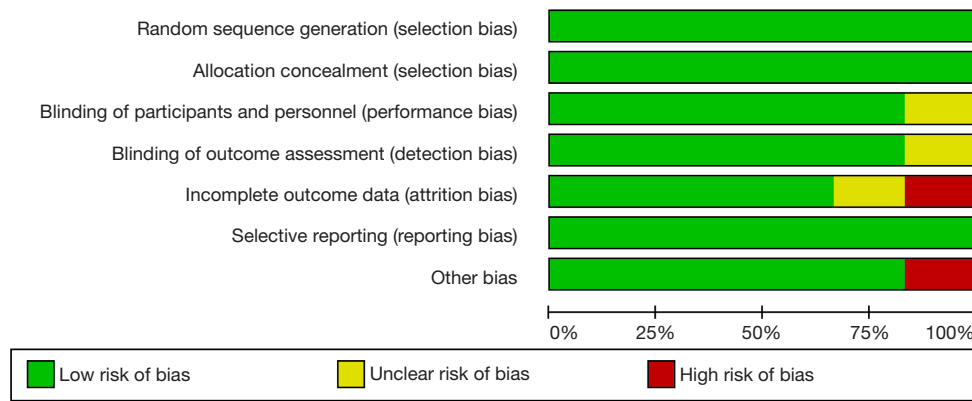


Figure 2 The risk of bias.

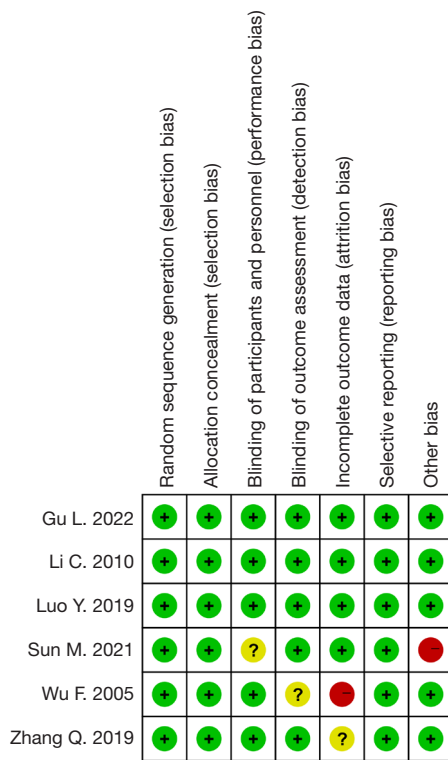


Figure 3 Multiple risk-of-bias assessments of the articles. + signifies low risk of bias, - signifies high risk of bias, and ? signifies unclear risk.

Five articles (83.33%) described a random allocation (RA) method, and 4 articles (66.67%) described a concealed allocation scheme. Four articles (66.67%) used a blind allocation method, and the remainder did not use a blind method.

Effect of HIFU + TACE on postoperative SR of patients with LC

Forest plots were drawn to illustrate the effect of HIFU + TACE versus TACE alone on patient SRs 6 months, 1 year, 2 years, 3 years, and 5 years after surgery (Figures 4-8). The SRs of patients in both the control and the experimental groups showed poor homogeneity at 6 months and 3 years after surgery ($I^2 > 50%$; Figures 4,7), so a random-effect model (REM) was adopted. There was no obvious difference in the 6-month (OR =9.03, 95% CI: 0.87, 94.13, P=0.07) or 3-year (OR =2.26, 95% CI: 0.46, 11.21, P=0.32) SRs of patients between the 2 groups (P>0.05). The included articles showed homogeneity in the SRs of patients at 1 year, 2 years, and 5 years after surgery ($I^2 < 50%$; Figures 5,6,8), so a fixed-effect model (FEM) was adopted. The SRs of patients in the experimental group at 1 year (OR =3.13, 95% CI: 1.92, 5.11, P<0.00001), 2 years (OR =3.38, 95% CI: 1.71, 6.66, P=0.0004), and 5 years (OR =2.15, 95% CI: 1.02, 4.55, P=0.04) after surgery were observably better than those of patients in the control group, and the differences were statistically significant (P<0.05).

TER of HIFU + TACE in patients with LC

A forest plot was drawn to illustrate the TER of HIFU + TACE versus TACE alone in the treatment of LC (Figure 9). The TER of all patients showed good homogeneity among the articles ($I^2 = 0%$), so a FEM was used. The TER of patients in the experimental group was much higher than that of patients in the control group (OR =3.61, 95% CI: 2.14, 6.08, P<0.00001), with a statistically significant

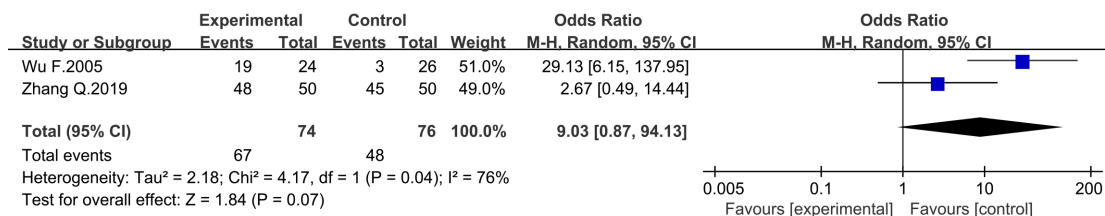


Figure 4 Forest plot of postoperative 6-month SR of patients. SR, survival rate; CI, confidence interval.

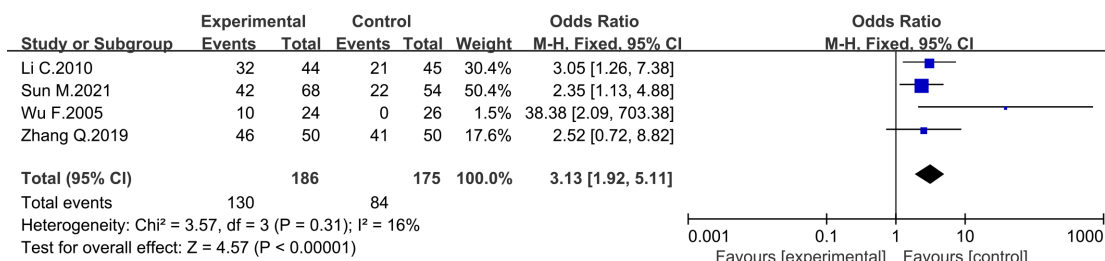


Figure 5 Forest plot of postoperative 1-year SR of patients. SR, survival rate; CI, confidence interval.

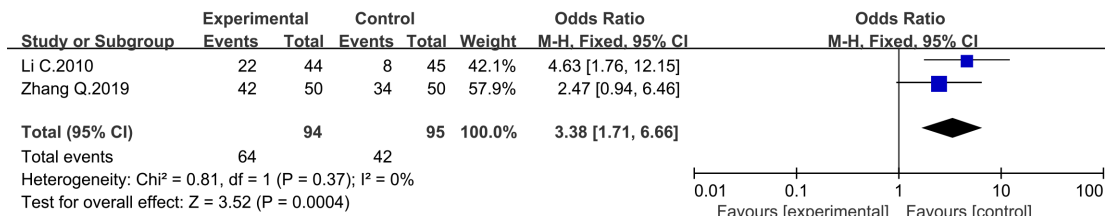


Figure 6 Forest plot of postoperative 2-year SR of patients. SR, survival rate; CI, confidence interval.

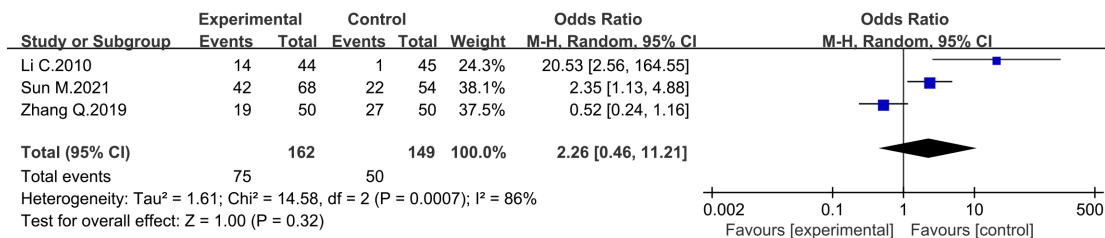


Figure 7 Forest plot of postoperative 3-year SR of patients. SR, survival rate; CI, confidence interval.

difference (P<0.05).

Effect of HIFU + TACE on liver function in patients with LC

Forest plots were drawn to illustrate the effect of HIFU + TACE treatment versus TACE alone on the liver function

of patients with LC (Figures 10,11). Figure 10 is a forest plot of AST levels after LC surgery, and Figure 11 is a forest plot of ALT levels after LC surgery. The AST and ALT levels of all patients showed poor homogeneity among the included articles (I²>50%), so a REM was adopted. The postoperative AST levels (MD = -17.94, 95% CI: -53.29, 17.40, P=0.32) and ALT levels (MD = -16.63, 95% CI: -49.00, 15.74,

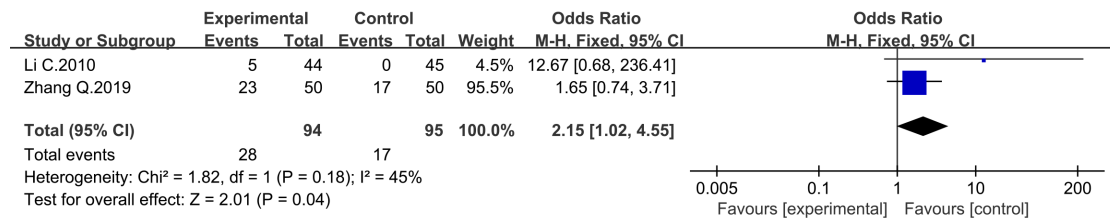


Figure 8 Forest plot of postoperative 5-year SR of patients. SR, survival rate; CI, confidence interval.

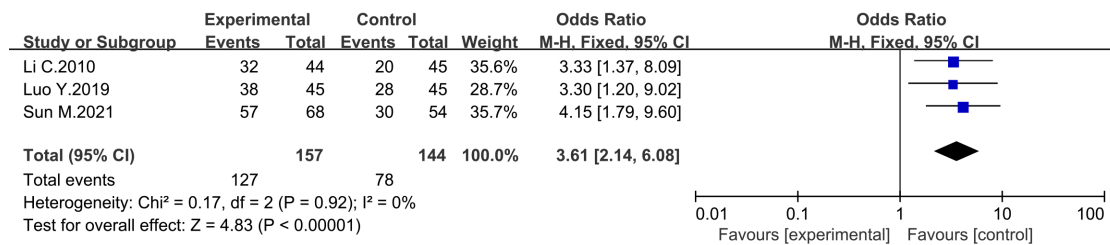


Figure 9 Forest plot of the TER of HIFU + TACE for LC. CI, confidence interval; TER, total effective rate; HIFU, high-intensity focused ultrasound; TACE, transarterial chemoembolization; LC, liver cancer.

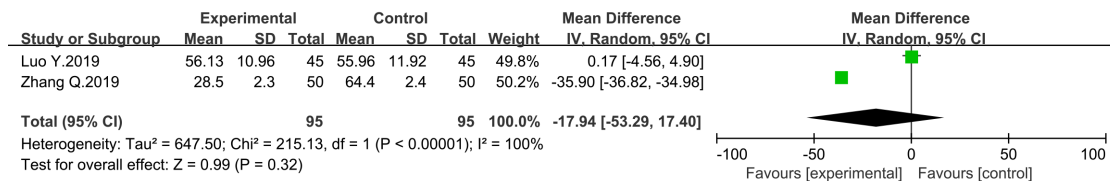


Figure 10 Forest plot of AST levels after LC surgery. SD, standard deviation; CI, confidence interval; AST, aspartate aminotransferase; LC, liver cancer.

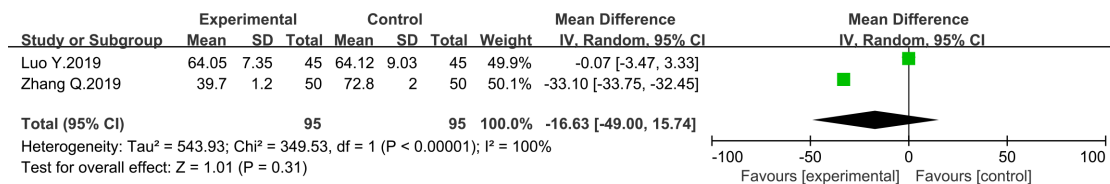


Figure 11 Forest plot of ALT levels after LC surgery. SD, standard deviation; CI, confidence interval; ALT, alanine aminotransferase; LC, liver cancer.

P=0.31) showed no observable difference between the 2 groups (P>0.05).

Effect of HIFU + TACE on immune function in patients with LC

Forest plots were drawn to illustrate postoperative

immune cell levels (CD3+, CD4+, CD8+, and NK cells) in patients with LC after HIFU + TACE versus TACE alone (Figures 12-15). The levels of the above indicators in all patients showed poor homogeneity among the articles (I²>50%), so a REM was adopted. The postoperative levels of CD3+ (MD =14.10, 95% CI: 10.60, 17.61, P<0.00001), CD4+ (MD =9.96, 95% CI: 2.42, 17.51, P=0.01), and NK

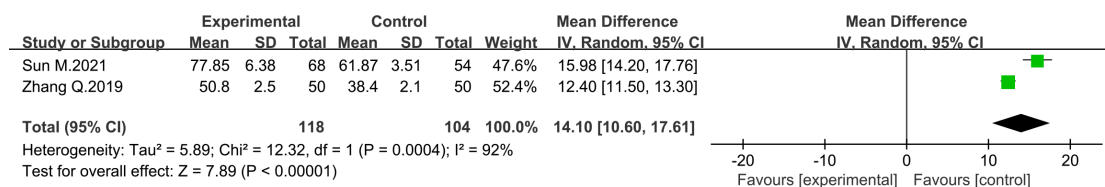


Figure 12 Forest plot of CD3+ cell level after LC surgery. SD, standard deviation; CI, confidence interval; LC, liver cancer.

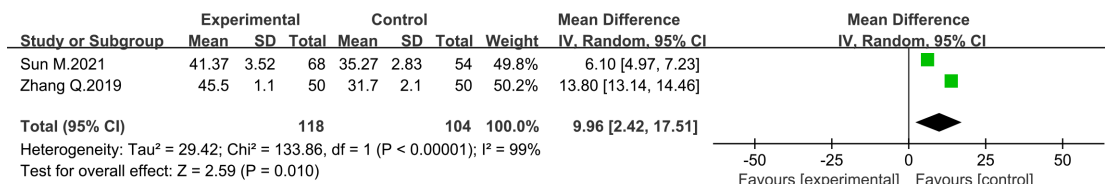


Figure 13 Forest plot of CD4+ cell level after LC surgery. SD, standard deviation; CI, confidence interval; LC, liver cancer.

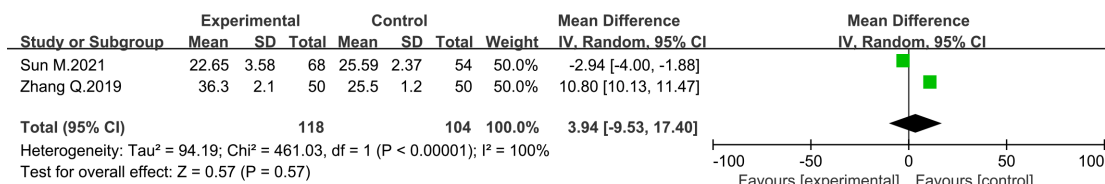


Figure 14 Forest plot of CD8+ cell level after LC surgery. SD, standard deviation; CI, confidence interval; LC, liver cancer.

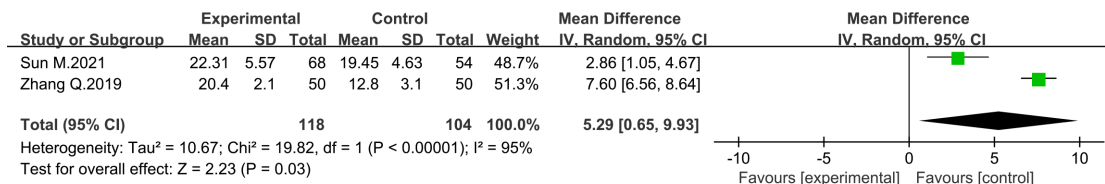


Figure 15 Forest plot of NK cell level after LC surgery. NK, natural killer; SD, standard deviation; CI, confidence interval; LC, liver cancer.

(MD =5.29, 95% CI: 0.65, 9.93, P=0.03) cells of patients in the experimental group were significantly higher than those of patients in the control group (P<0.05). The included articles showed no obvious difference in postoperative CD8+ levels between the 2 groups (MD =3.94, 95% CI: -9.53, 17.40, P=0.57>0.05).

Effect of HIFU + TACE on the incidence of adverse reactions in patients with LC

A forest plot was drawn to illustrate the effect of HIFU + TACE therapy versus TACE alone on the incidence of

adverse reactions in patients with LC (Figure 16). The incidence of adverse reactions showed good homogeneity among the articles (I²=0%), so a FEM was used. The incidence of postoperative adverse reactions in the experimental group was much lower than that in the control group, with a statistically significant difference (OR =0.57, 95% CI: 0.34, 0.96, P=0.03<0.05).

Results on publication bias

A funnel plot was used to assess the possibility of publication bias for the included articles (Figure 17). The funnel

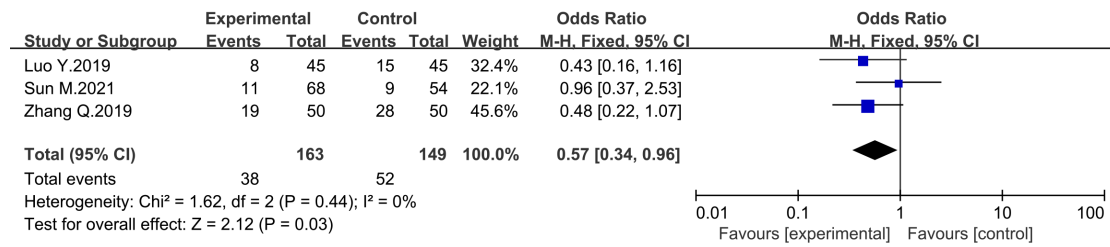


Figure 16 Forest plot of the effect of HIFU + TACE therapy and TACE alone on the incidence of adverse reactions in patients with LC. HIFU, high-intensity focused ultrasound; TACE, transarterial chemoembolization; CI, confidence interval; LC, liver cancer.

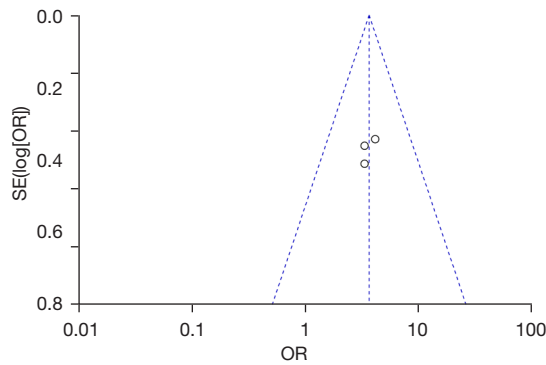


Figure 17 Funnel plot of publication bias. SE, standard error; OR, odds ratio.

plot showed that the circles of some of the articles were concentrated in and roughly symmetrical with the midline. This suggested that there was no publication bias, and that the conclusions of the articles were relatively reliable.

Discussion

HIFU focuses low-intensity ultrasonic energy on the tumor target area of patients with LC and rapidly increases the temperature of the treatment area to above 65 °C, thereby promoting coagulation necrosis of local tumor tissue (21). This treatment method is noninvasive and accurate, can perform real-time positioning and monitoring, can control the treatment range, and can kill local tumor cells in LC while enhancing the body’s anti-tumor immune function, thereby improving the treatment of LC (22).

Recent clinical studies have noted two advantages of combining TACE with HIFU in the treatment of malignant tumors. First, TACE can effectively improve the thermal effect during HIFU treatment and facilitate tumor targeting and tumor shape identification (23). Second, TACE helps

HIFU treatment to control the blood supply around the tumor, which improves the thermal damage to local tumor markers and can result in a better therapeutic effect than that of TACE alone (24).

A total of 6 articles were included in this systematic review. The purpose was to evaluate the efficacy of HIFU + TACE in the treatment of patients with LC compared with TACE alone. A risk-of-bias assessment was conducted, and the results showed that 5 articles used an RA method, 4 used allocation scheme concealment, and 4 used a blind method for the allocation of study subjects. Therefore, any bias in the studies might be caused by an unclear RA method or experimental error.

The results of this study showed that patients in the experimental group in the included articles had higher 1-year (OR =3.13, 95% CI: 1.92, 5.11, P<0.00001), 2-year (OR =3.38, 95% CI: 1.71, 6.66, P=0.0004), and 5-year (OR =2.15, 95% CI: 1.02, 4.55, P=0.04) postoperative SRs. The TER (OR =3.61, 95% CI: 2.14, 6.08, P<0.00001) in the experimental group was obviously better than that in the control group, and the difference was statistically significant. This suggested that compared with TACE alone, HIFU + TACE could greatly improve the short- and long-term SR of patients with LC and thereby provide better treatment. We also compared the postoperative AST and ALT levels of the 2 groups of patients, and the results showed no significant difference between patients who received the combined treatment and patients who received TACE alone. The postoperative CD3+ and CD4+ levels of patients in the HIFU + TACE treatment group were significantly higher than those of patients in the control group, while the postoperative CD8+ levels were not greatly different between the 2 groups. The levels of NK cells were much higher in the HIFU + TACE treatment group, with a statistically significant difference (P<0.05), which indicated that the combination therapy

improved the immune protection of patients with LC and enhanced the body's resistance to LC to a certain extent. In addition, HIFU + TACE significantly reduced the incidence of postoperative adverse reactions compared with TACE alone (OR =0.57, 95% CI: 0.34, 9.96, P=0.03). This was consistent with the findings of Zhang *et al.* (25). Future studies are required to further understand the efficacy of HIFU + TACE in the treatment of patients with different types of LC.

A publication bias assessment was conducted on the included studies comparing the efficacy of HIFU + TACE versus TACE alone in patients with LC. The results showed that there was no obvious bias and that the conclusions were credible.

Conclusions

A total of 6 relevant articles were included in this meta-analysis to explore the efficacy of HIFU + TACE therapy versus TACE alone in patients with LC. The results suggested that HIFU + TACE treatment of LC patients could improve the SR of patients to a certain extent. A limitation of this study was that some of the articles showed heterogeneity, which might have affected the results. Therefore, further research is needed to confirm the results of this study. In conclusion, this systematic review and meta-analysis could provide a reliable reference for the clinical study of HIFU + TACE in patients with LC.

Acknowledgments

Funding: None.

Footnote

Reporting Checklist: The authors have completed the PRISMA reporting checklist. Available at <https://tcr.amegroups.com/article/view/10.21037/tcr-22-1094/rc>

Conflicts of Interest: All authors have completed the ICMJE uniform disclosure form (available at <https://tcr.amegroups.com/article/view/10.21037/tcr-22-1094/coif>). The authors have no conflicts of interest to declare.

Ethical Statement: The authors are accountable for all aspects of the work in ensuring that questions related to the accuracy or integrity of any part of the work are appropriately investigated and resolved.

Open Access Statement: This is an Open Access article distributed in accordance with the Creative Commons Attribution-NonCommercial-NoDerivs 4.0 International License (CC BY-NC-ND 4.0), which permits the non-commercial replication and distribution of the article with the strict proviso that no changes or edits are made and the original work is properly cited (including links to both the formal publication through the relevant DOI and the license). See: <https://creativecommons.org/licenses/by-nc-nd/4.0/>.

References

1. Kudo M, Ueshima K, Ikeda M, et al. Randomised, multicentre prospective trial of transarterial chemoembolisation (TACE) plus sorafenib as compared with TACE alone in patients with hepatocellular carcinoma: TACTICS trial. *Gut* 2020;69:1492-501.
2. Wang Z, Ren Z, Chen Y, et al. Adjuvant Transarterial Chemoembolization for HBV-Related Hepatocellular Carcinoma After Resection: A Randomized Controlled Study. *Clin Cancer Res* 2018;24:2074-81.
3. Yoon SM, Ryoo BY, Lee SJ, et al. Efficacy and Safety of Transarterial Chemoembolization Plus External Beam Radiotherapy vs Sorafenib in Hepatocellular Carcinoma With Macroscopic Vascular Invasion: A Randomized Clinical Trial. *JAMA Oncol* 2018;4:661-9.
4. Kurilova I, Beets-Tan RGH, Ulaner GA, et al. 90Y Resin Microspheres Radioembolization for Colon Cancer Liver Metastases Using Full-Strength Contrast Material. *Cardiovasc Intervent Radiol* 2018;41:1419-27.
5. Chen L, Shi H, Che Y, et al. Efficacy of endostatin combined with continuous transcatheter arterial infusion and chemoembolization on gastric cancer with liver metastasis and analysis of prognosis. *J BUON* 2020;25:1469-75.
6. Fiorentini G, Sarti D, Nardella M, et al. Chemoembolization Alone or Associated With Bevacizumab for Therapy of Colorectal Cancer Metastases: Preliminary Results of a Randomized Study. *In Vivo* 2020;34:683-6.
7. Leslie T, Ritchie R, Illing R, et al. High-intensity focused ultrasound treatment of liver tumours: post-treatment MRI correlates well with intra-operative estimates of treatment volume. *Br J Radiol* 2012;85:1363-70.
8. Dupré A, Pérol D, Blanc E, et al. Efficacy of high-intensity focused ultrasound-assisted hepatic resection (HIFU-AR) on blood loss reduction in patients with liver metastases requiring hepatectomy: study protocol for a randomized

- controlled trial. *Trials* 2017;18:57.
9. Pernet S, Pellerin O, Artru P, et al. Intra-arterial hepatic beads loaded with irinotecan (DEBIRI) with mFOLFOX6 in unresectable liver metastases from colorectal cancer: a Phase 2 study. *Br J Cancer* 2020;123:518-24.
 10. Wu X, Chen R, Zheng W, et al. Comprehensive Analysis of Factors Affecting Clinical Response and Short-Term Survival to Drug-Eluting Bead Transarterial Chemoembolization for Treatment in Patients With Liver Cancer. *Technol Cancer Res Treat* 2018;17:1533033818759878.
 11. Sun J, Zhou G, Xie X, et al. Efficacy and Safety of Drug-Eluting Beads Transarterial Chemoembolization by CalliSpheres® in 275 Hepatocellular Carcinoma Patients: Results From the Chinese CalliSpheres® Transarterial Chemoembolization in Liver Cancer (CTILC) Study. *Oncol Res* 2020;28:75-94.
 12. Wang C, Liao Y, Qiu J, et al. Transcatheter arterial chemoembolization alone or combined with ablation for recurrent intermediate-stage hepatocellular carcinoma: a propensity score matching study. *J Cancer Res Clin Oncol* 2020;146:2669-80.
 13. Rösok BI, Høst-Brunsell T, Brudvik KW, et al. Characterization of early recurrences following liver resection by ALPPS and two stage hepatectomy in patients with colorectal liver-metastases and small future liver remnants; a translational substudy of the LIGRO-RCT. *HPB (Oxford)* 2019;21:1017-23.
 14. Yang X, Feng Y, Liu Y, et al. Fuzheng Jiedu Xiaoji formulation inhibits hepatocellular carcinoma progression in patients by targeting the AKT/CyclinD1/p21/p27 pathway. *Phytomedicine* 2021;87:153575.
 15. Gu L, Shen Z, Ji L, et al. High-intensity focused ultrasound alone or combined with transcatheter arterial chemoembolization for the treatment of hepatocellular carcinoma with unsuitable indications for hepatectomy and radiofrequency ablation: a phase II clinical trial. *Surg Endosc* 2022;36:1857-67.
 16. Li C, Zhang W, Zhang R, et al. Therapeutic effects and prognostic factors in high-intensity focused ultrasound combined with chemoembolisation for larger hepatocellular carcinoma. *Eur J Cancer* 2010;46:2513-21.
 17. Luo Y, Jiang Y. Comparison of Efficiency of TACE plus HIFU and TACE alone on Patients with Primary Liver Cancer. *J Coll Physicians Surg Pak* 2019;29:414-7.
 18. Sun M, Shang P, Bai J, et al. High-intensity focused ultrasound ablation combined with transcatheter arterial chemoembolization improves long-term efficacy and prognosis of primary liver cancer. *J Clin Lab Anal* 2021;35:e23633.
 19. Wu F, Wang ZB, Chen WZ, et al. Advanced hepatocellular carcinoma: treatment with high-intensity focused ultrasound ablation combined with transcatheter arterial embolization. *Radiology* 2005;235:659-67.
 20. Zhang Q, Bian SQ, Lv W, et al. Observation of efficacy of TACE combined with HIFU on patients with middle-advanced liver cancer. *Eur Rev Med Pharmacol Sci* 2019;23:239-46.
 21. Zhou B, He N, Hong J, et al. HIFU for the treatment of gastric cancer with liver metastases with unsuitable indications for hepatectomy and radiofrequency ablation: a prospective and propensity score-matched study. *BMC Surg* 2021;21:308.
 22. Li S, Shi S, Li A, et al. Diffusion-Weighted Magnetic Resonance Imaging in Assessment of Primary Liver Cancer after HIFU Treatment. *J Coll Physicians Surg Pak* 2019;29:305-8.
 23. Shiina S, Sato K, Tateishi R, et al. Percutaneous Ablation for Hepatocellular Carcinoma: Comparison of Various Ablation Techniques and Surgery. *Can J Gastroenterol Hepatol* 2018;2018:4756147.
 24. Zhai YP, Wang Y. Effect of the combination treatment of high-intensity focused ultrasound and cryocare knife in advanced liver cancer. *J BUON* 2017;22:495-9.
 25. Zhang Q, Wang Y, Zhang J, et al. TACE Combined with HIFU Versus Surgical Resection for Single Hepatocellular Carcinoma with Child-Pugh B Cirrhosis in Overall Survival and Progression-Free Survival: A Retrospective Study. *Technol Cancer Res Treat* 2021;20:15330338211060180.
- (English Language Editor: C. Gourlay)

Cite this article as: Hu J, Mao H, He Y. Systematic review and meta-analysis of the efficacy and safety of high-intensity focused ultrasound combined with transarterial chemoembolization and transarterial chemoembolization alone in the treatment of liver cancer. *Transl Cancer Res* 2022;11(6):1678-1688. doi: 10.21037/tcr-22-1094