



# Pilot clinical study on the prevention of complications after lung biopsy by the MIPP kit PNX device

Cosmo Damiano Gadaleta<sup>1</sup>, Roberto Iezzi<sup>2</sup>, Alessandro Tanzilli<sup>2</sup>, Giovanni Puppini<sup>3</sup>, Pier Luigi Carriero<sup>4</sup>, Antonino Amato<sup>4</sup>

<sup>1</sup>Interventional Oncology and Integrated Medicine Department, Istituto Tumori Giovanni Paolo II, Bari, Italy; <sup>2</sup>Diagnostic and General Interventional Radiology Department, Fondazione Policlinico Universitario A. Gemelli IRCCS, Rome, Italy; <sup>3</sup>Radiology Department, Verona University Hospital, Verona, Italy; <sup>4</sup>Betaglu Technologies SpA, Milan, Italy

*Contributions:* (I) Conception and design: A Amato, PL Carriero; (II) Administrative support: A Amato, PL Carriero; (III) Provision of study materials or patients: All authors; (IV) Collection and assembly of data: A Amato, PL Carriero; (V) Data analysis and interpretation: All authors; (VI) Manuscript writing: All authors; (VII) Final approval of manuscript: All authors.

*Correspondence to:* Dr. Antonino Amato. Betaglu Technologies SpA, Betaglu Technologies SpA, via San Primo 4, I-20121, Milan, Italy. Email: a.amato@betaglu.com.

**Background:** Pneumothorax (PNX), pulmonary hemorrhage, hemothorax and chest wall hematoma are the most commonly reported complications of percutaneous lung biopsy (PLB). Sealing the biopsy tract with different types of materials is an emerging way to prevent PLB complications.

**Methods:** To investigate the safety and efficacy of a new device, Minimally Invasive Percutaneous Procedure Kit for Pneumothorax (MIPP-Kit PNX), when used in association with a resorbable bio-compatible glue in the prevention of PLB complications. A prospective, multicenter, open-label, single-arm study was performed to evaluate the complication rate after glue administration by the new investigational device during PLBs.

**Results:** Forty-three patients were enrolled after informed consent signature (40 underwent PLB, while three were screening failures). Only 3 patients (7.5%, 95% CI: 0.0–15.7%) developed complications within 48 h after glue injection during PLB: two developed minor pneumothoraces and one a pulmonary hemorrhage. No patients who showed procedural complications before glue administration were reported with any recurrent or new complications after glue administration.

**Conclusions:** In comparison with the data reported in the literature, this trial results support the safe and effective use of the MIPP kit PNX in the prevention of PLB complications. These promising preliminary results warrant further confirmation in larger clinical trials.

**Trial Registration:** ClinicalTrials.gov identifier: NCT04071509.

**Keywords:** Percutaneous lung biopsy (PLB); pneumothorax (PNX); complications; lung cancer diagnosis

Submitted Apr 29, 2022. Accepted for publication Sep 25, 2022.

doi: 10.21037/tcr-22-1203

View this article at: <https://dx.doi.org/10.21037/tcr-22-1203>

## Introduction

Percutaneous lung biopsy (PLB) is a safe and effective method for obtaining a diagnosis in patients with lung masses (1). The decision to perform core biopsy (CB) or both CB and fine-needle aspiration (FNA), to establish a malignant or benign diagnosis, or to obtain material for culture, is multifactorial, mainly based on multidisciplinary criteria and

highly institution/operator dependent (2). The procedure should be performed with the support of imaging techniques, such as ultrasound or computed tomography (CT), in order to simplify and make the PLB practice safer (2-5).

Complications of PLB should be considered in the risk/benefit analysis before the beginning of the procedure. Pneumothorax (PNX), pulmonary hemorrhage, hemothorax

and chest wall hematoma are the most commonly reported complications; less frequently reported ones include hemomediastinum, cardiac tamponade, air embolism, seeding of the biopsy tract and even death (6). In most of the large published series, the reported incidence of post-biopsy PNX ranges from 15% to 54% (7-18) and are usually managed conservatively, with no long-term sequelae; however, in about 2–15% of patients, invasive maneuvers are required (19), such as the placement of a chest tube, which is associated with prolonged hospitalization. Hemorrhage has an overall incidence of up to 31% and can occur with or without hemoptysis, which presents in approximately 3% of patients (20).

Research is starting to emerge on new ways of preventing PLB complications. Some authors have investigated the feasibility and success rates of sealing the biopsy tract by different methods (21-25). Though plugging the biopsy tract shows promising results, its specific role is still not clear (21).

Bures *et al.* (26) had tested the application of an albumin-glutaraldehyde based glue, Bioglue® (Cryolife Inc.), to repair superficial lung defects, proving its efficacy for both inflated and deflated lung conditions. Bioglue® is currently indicated for use as an adjunct to standard methods of achieving hemostasis (such as sutures and staples) in adult patients in open surgical repair of large vessels (such as aorta, femoral, and carotid arteries) in the United States (27); it is also indicated alone to reinforce damaged parenchyma [such as pulmonary (28,29), genitourinary (30), gastro-intestinal (31), dural (32), pancreatic (33) and hepato-biliary (34)] when other conventional procedures are ineffective or impractical in several other countries, including Europe (27).

The above considerations led us to investigate the role of BioGlue® in association with the use of a minimally invasive percutaneous procedure kit (MIPP-Kit), as a potential tool to minimize post-PLB complications. The MIPP-Kit, a Conformite Européenne (CE)-marked tool with a dual-lumen catheter designed to facilitate the optimal application of fibrin sealants after diagnostic and therapeutic percutaneous procedures, had been tested in other indications (e.g., to prevent perihepatic bleeding and dissemination of cancer cells following biopsy and loco-regional treatments), with promising results (35,36). In these studies, the kit turned out to be rather easy to use, also allowing a more precise delivery of active agents to the targeted administration site.

Therefore, a prospective, multicenter, open-label, single-arm study was planned to assess the safety and feasibility of a specific version of the CE-marked MIPP kit, the MIPP-

Kit PNX, for the prevention of complications associated with diagnostic, CT-guided, PLB. We present the following article in accordance with the TREND reporting checklist (available at <https://tcr.amegroups.com/article/view/10.21037/tcr-22-1203/rc>).

## Methods

### *Study design, setting and participants*

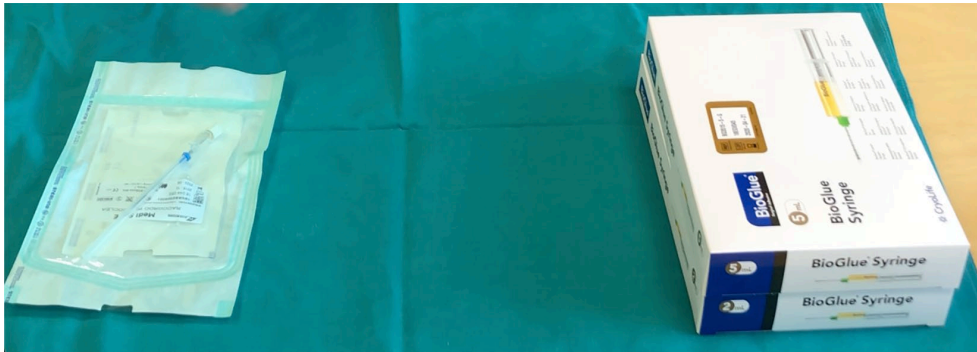
This multicenter, single arm, open-label trial was performed after obtaining approval by the local institutional review boards of three investigational sites (Istituto Tumori Giovanni Paolo II, Bari; Verona University Hospital, Verona; Fondazione Policlinico Universitario A. Gemelli, Roma).

All consecutive adult patients (age  $\geq 18$  and  $\leq 80$  years), admitted from February 2019 to February 2020 at three investigational sites with an indication for diagnostic PLB, were enrolled in the study, after informed consent (IC) signature.

The following criteria were defined for the exclusion of patient from the trial: pregnant or breastfeeding; participation in another clinical study in the month prior to the diagnostic PLB; known allergy to device components, sedative agents or anesthetics (if used); confirmed sensitivity to materials of bovine origin; contraindication to the procedure due to concomitant conditions and/or therapies.

Biopptic procedures were performed based on institution/operator standard procedures, without any technical requests in terms of a specific needle, access type, or particular approach. To use the MIPP-Kit PNX, its introducer was inserted into the lung under CT guidance, until it reached the lesion to be biopsied. After mandrel removal, the biopsy needle was inserted, tissue sample was collected and the biopsy needle was removed. The introducer was then retracted by approximately 1 or 2 cm and the BioGlue® adhesive dispensed via the MIPP Kit system, whilst simultaneously withdrawing the introducer from the patient's thorax.

Enrolled patients performed 5 study visits. The screening/baseline visit was performed, after the IC signature, to verify all the inclusion and exclusion criteria within 15 days before the PLB, along with a check of concomitant treatments, medical history and a full physical examination; an anesthesiology consultation was also performed (where necessary). After the PLB visit, the safety and efficacy data listed in the protocol were systematically collected at day 1, 2, at the discharge visit and after 30 days from PLB,



**Figure 1** Picture of the CE-marked MIPP-kit PNX (on the left) used to inject the surgical adhesive (BioGlue®; on the right) after CT-guided interventional thoracic procedures. CE, Conformance Européenne.

including: presence and onset of PNX, bleeding, embolism and/or other complications, based on clinical examination and imaging tests (e.g., ultrasound or CT). Any information regarding potential adverse events (AEs) and concomitant medications/treatments was recorded in the study case report forms (CRFs); the causality assessment of each AE was performed by the principal investigator or a qualified member of the investigational staff.

### **Ethical approval**

This study was conducted in conformity with the ethical principles set forth by the Declaration of Helsinki (as revised in 2013), Good Clinical Practice (GCP) principles, international standards for clinical investigation of medical devices ISO 14155:2011, the laws and regulations of the countries where the study took place, and indemnity/insurance requirements. The investigational plan, the informed consent form and any other study related requested documents were reviewed and approved by the appropriate Ethics Committee where the trial was conducted (Istituto Tumori Giovanni Paolo II, Bari (Italy); Verona University Hospital, Verona (Italy); Fondazione Policlinico Universitario A. Gemelli, Rome (Italy) (Prot. n.691/CE, Prot. n.39256 and Prot.n.sf 45195/19 ID:2649 respectively). Informed consent process was mandatory for participation in clinical investigation, and had to be obtained from all subjects and/or their legal representatives as per local regulations, prior to their participation in the study.

### **Investigational device**

Two MIPP-Kit PNX models (MIPP-KIT-PNX10 and

MIPP-KIT-PNX15), which differ as to the length (10 *vs.* 15 cm) and the outer caliber of the introducer (17G *vs.* 18G), were available for the trial. The investigators chose the MIPP-Kit PNX model to be used according to the characteristics of the lesion (location and depth), based on its pre-operative CT images.

The MIPP-Kit PNX system boasts a hollow steel introducer with graduated mandrel whose tip is provided with a Luer-lock connection and two poly-vinyl chloride (PVC) connectors, also provided with a Luer-lock connection (*Figure 1*); such components are used to inject a surgical adhesive (such as BioGlue®) after CT-guided interventional thoracic procedures in order to reduce the risk of PNX, hemorrhage or tumor seeding. BioGlue® is composed of bovine serum albumin and glutaraldehyde present in a two-chamber syringe, which are blended inside an applicator tip during its administration to the target tissue. Depending on the depth of the target lesion, the length and the outer caliber of the introducer (which can lead to an increase of residual BioGlue® amount), and according to the judgment of the investigators after the removal of the biopsy needle, one the following syringes with BioGlue® could be used: 2, 5 or 10 mL.

The use of the medical device was reserved to medical practitioners with expertise in diagnostic PLB. A training for the use of MIPP-Kit PNX was performed for all the staff involved in the trial.

### **Outcomes**

The primary endpoint of the study was to determine the complication rate after the administration of the surgical adhesive during diagnostic PLBs in the 48 h following

the procedure. Any AE, be it serious or otherwise, that occurred during the study after IC signature was recorded and its relationship with the MIPP-Kit PNX used for that patient was investigated. This included start and stop date/time, severity (yes/no), outcome (resolved, recovered, residual effects, fatal, unknown, etc.), severity (mild, moderate, severe), treatment required (none, drug, non-drug treatment), relationship to study device and action taken with study device (discontinued or interrupted).

Any new event/experience that was not present at baseline, or worsening of an event present at baseline, was considered an AE; it was monitored until it was adequately resolved or explained. Unchanged, chronic conditions were not considered AEs and were not required to be recorded onto the CRF.

The satisfaction of the investigators about the ease of use of the MIPP-Kit PNX during the PLB procedures was collected by a binary response questionnaire (yes/no), filled after each procedure had been performed, as was the impact of using the MIPP-Kit PNX on the costs of complications associated with diagnostic PLBs, by analyzing patient's post-procedure duration of hospitalization.

### Statistical analysis

Baseline continuous variables were presented as means and standard deviations, or as median values and Interquartile Ranges (IQR), as appropriate.

The analysis of the primary endpoint was presented as the percentage of complications after BioGlue<sup>®</sup> administration ("Post-Glue" complications) over the number of procedures performed ("Undertaken Biopsy" analysis set), with a 95% confidence interval (CI) calculated from the Wald test for binomial distribution. The percentage of complications (with 95% CI) occurring before glue injection ("Pre-Glue" complications) was also reported; a sensitivity analysis was performed on the primary endpoint, by excluding patients with "Pre-Glue" complications.

The secondary endpoints were analyzed by descriptive statistics. The association between complications, considered separately as "Pre-Glue" and "Post-Glue" complications, and patient characteristics, type of device used (MIPP-Kit-PNX10 or MIPP-Kit-PNX15) and type of lesion were analyzed by means of an ANOVA model for continuous variables, or of the Chi-Square test for categorical variables. All statistical analyses were performed using Statistical Analysis System (SAS) software version 9.4.

## Results

### Enrollment of patients

Forty-three patients were enrolled in the study. All patients were included in the "Planned Biopsy (PB)" analysis set, while the 40 patients undergoing the PLB procedure were included in the "Undertaken Biopsy (UB)" analysis set (*Figure 2*).

Three patients were excluded from "UB" analysis set because of screening failure. Another patient did not complete the follow-up part of the study because of a serious AE ("Cardiac failure and renal insufficiency"), that caused patient's death after the patient had been discharged from the hospital; this event was deemed not related to the MIPP-Kit PNX device, but related to the pre-existing pathological condition of the patient, i.e., cervical cancer with disseminated metastases (*Figure 2*).

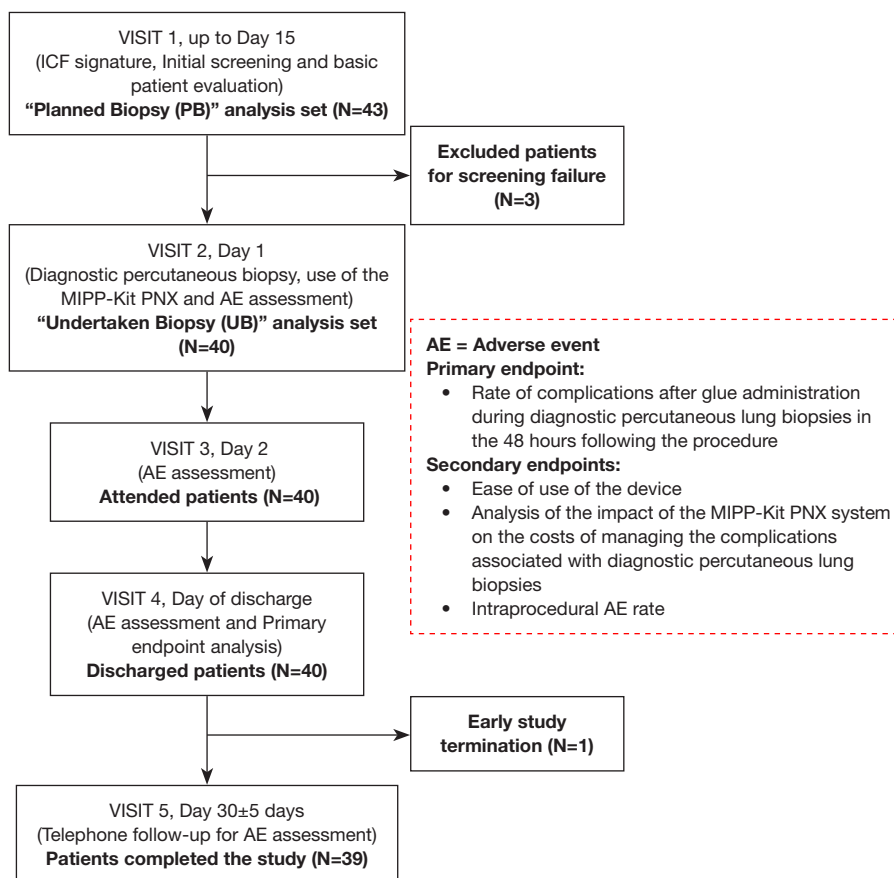
The mean age of patients was 68±8 years (median value, 70; IQR, 64–74 years); 27 (62.8%) patients were males, and all patients were Caucasians (*Table 1*). Thirty-nine (90.7%) patients of the PB analysis set were hospitalized, 11 (25.6%) had a previous history of allergy, and all patients performed an Eastern Cooperative Oncology Group (ECOG) score evaluation: 26 patients (60.5%) had values equal to 0, 14 patients (32.6%) had a value of 1, and 3 patients (7.0%) had a value of 2 (*Table 1*).

### Study treatment and procedures

The indication for lung biopsy was classified into 3 groups: diagnostic biopsy, staging biopsy and treatment choice biopsy. Thirty-four (79.1%) patients had a diagnostic indication for biopsy, 5 (11.6%) patients had a biopsy for staging, and 4 (9.3%) for their treatment choice selection.

The mean size of the target lesions was 38±27 mm, with a median value of 29 mm (IQR, 17–51 mm), while the mean depth of the target lesion from the skin was 6±3 cm, with a median value of 5 cm (IQR, 4–7 cm) (*Table 2*). The lesion location was classified as follows: 15 (37.5%) in the right upper lobe, 12 (30.0%) in the right lower lobe, 5 (12.5%) in the left upper lobe, 5 (12.5%) in the left lower lobe, and 3 (7.5%) in the right middle lobe (*Table 2*).

The mean amount of BioGlue<sup>®</sup> used at the end of the biopsy procedures was 1.45±1.09 mL, with a larger amount used at the Bari site compared to the other investigational sites: 2.47±0.99, 1.00±0.67 and 0.60±0.17 mL, respectively (*Table 2*). Thirty-three biopsies (82.5%) were performed



**Figure 2** Description of study flow, study analysis sets, planned procedures for each visit and endpoints of the study. IC, informed consensus; N, number; AE, adverse event.

with MIPP-Kit PNx10; 38 (95.0%) were performed using an introducer of 17G caliber and 34 (85.0%) with a BioGlue® 2 mL dosage form (Table 2).

### Evaluation of biopsy procedure complications

A total of three "Post-Glue" complications occurred after the administration of BioGlue® within 48 h from the biopsy procedure in 40 patients included in the "UB" analysis set, for an overall risk of complications of 7.5% (95% CI: 0.0–15.7%, Table 3). In particular, one patient in each of two sites had PNx (5.0%, 95% CI: 0.0–12.7%), none of which requiring a chest tube insertion, while another patient had pulmonary hemorrhage after administration of BioGlue® (2.5%, 95% CI: 0.0–7.3%), resolved with intra arterial embolization by synthetic fibrin; no embolism or other complications occurred (Table 3). All "Post-Glue" complications occurred within 3 hours from the biopsy

procedures.

Considering the above mentioned "UB" analysis set (40 patients), 14 (35.0%) complications occurred before the administration of BioGlue® during biopsy procedures ("Pre-Glue" complications). In particular, 11 (78.6%) PNx, 2 (14.3%) pulmonary hemorrhages and 1 (7.1%) hemothorax occurred in those patients. All such complications were treated conservatively and subsided before the glue was administered. None of the patients experiencing "Pre-Glue" complications also experienced "Post-Glue" complications. A sensitivity analysis excluded the 14 patients who had complications before the administration of BioGlue®, which was therefore performed on 26 patients. The overall risk of "Post-Glue" complications was equal to 11.5% (95% CI: 0.0–23.8%), and the risk of PNx and pulmonary hemorrhage, respectively, was equal to 7.7% (95% CI: 0.0–17.9%) and 3.8% (95% CI: 0.0–11.2%).

The mean duration of biopsies with no complication,

**Table 1** Demographics and other baseline characteristics of enrolled patients

Characteristics	Total (N=43)
Age (year)	
Mean ± SD	68±8
Median [IQR]	70 [64–74]
Hospitalized patient, n (%)	
Day hospital	4 (9.3)
Hospitalized	39 (90.7)
Sex, n (%)	
Female	16 (37.2)
Male	27 (62.8)
Ethnic group, n (%)	
Caucasian	43 (100.0)
Allergic patient (not device related), n (%)	
No	32 (74.4)
Yes	11 (25.6)
Medical comorbidities, n (%)	
Asthma	1 (2.3)
COPD	10 (23.2)
ILD	0 (0.0)
Prior pneumothorax	0 (0.0)
Bleeding	0 (0.0)
Dyspnea	2 (4.6)
Other	41 (95.3)
Score of ECOG, n (%)	
0	26 (60.5)
1	14 (32.6)
2	3 (7.0)

Patients have been recruited from 3 Italian investigational sites (Istituto Tumori Giovanni Paolo II in Bari, Verona University Hospital in Verona and Fondazione Policlinico Universitario A. Gemelli in Roma). SD, standard deviation; IQR, interquartile range; COPD, chronic obstructive pulmonary disease; ILD, interstitial lung disease. ECOG, Eastern Cooperative Oncology Group.

**Table 2** Radiographic and procedural characteristics

Characteristics	Total (N=40)
Size of lesion (mm)	
Mean ± SD	38±27
Median [IQR]	29 [17–51]
Range	10–124
Depth of lesion from skin (cm)	
Mean ± SD	6±3
Median [IQR]	5 [4–7]
Range	2–15
Amount of BioGlue® used (mL)	
Mean ± SD	1.45±1.09
Median [IQR]	1 [0.7–2]
Range	0.17–5
Location of biopsy procedure, n (%)	
Day hospital	4 (10.0)
Hospital	36 (90.0)
Type of MIPP kit device, n (%)	
MIPP-KIT-PNX10	33 (82.5)
MIPP-KIT-PNX15	7 (17.5)
Caliber of MIPP kit device, n (%)	
17G	38 (95.0)
18G	2 (5.0)
Type of BioGlue®, n (%)	
BioGlue®2ML	34 (85.0)
BioGlue®5ML	6 (15.0)
Lesion location, n (%)	
Right upper lobe	15 (37.5)
Right lower lobe	12 (30.0)
Left upper lobe	5 (12.5)
Left lower lobe	5 (12.5)
Middle lobe	3 (7.5)

SD, standard deviation; IQR, interquartile range.

“Pre-Glue” complication or “Post-Glue” complication were 44±30, 71±111 or 68±31 min respectively (*Table 4*). The MIPP-Kit-PNX15 was used in 2 (66.7%) “Post-Glue” complications, whereas the MIPP-Kit-PNX10 was

used in most of “Pre-Glue” complications and most of the procedures not showing any complications (P=0.041, Chi-Square test) (*Table 4*). No statistically significant associations were found in any analyses; a trend was present for depth of

**Table 3** “Post-Glue” complications

Variables	Total (N=40)
Number of “Post-Glue” complications within 48 h from biopsy procedure, n (%)	3 (7.5)
95% confidence interval	0.0–15.7
Pneumothorax, n (%)	2 (5.0)
95% confidence interval	0.0–12.7
Pulmonary hemorrhage, n (%)	1 (2.5)
95% confidence interval	0.0–7.3
Embolism, n (%)	0 (0.0)
Other, n (%)	0 (0.0)

lesion ( $P=0.08$ , ANOVA test) (Table 4).

#### Evaluation of MIPP-Kit PNX impact on investigational site costs

After PLB procedures the investigators were interviewed about the usability of the investigational device. All of them considered the MIPP-Kit PNX system suitable for the correct completion of the procedure.

To evaluate the cost impact of the device, patient hospitalization duration after the biopsy procedure was considered. Overall, the mean of post-biopsy hospitalization days was  $10 \pm 7$  days (median value 8 days; IQR, 6–13 days) in Bari,  $6 \pm 10$  days (median value 2 days; IQR, 0–33 days) in Verona, and  $2 \pm 1$  days (median value 2 days with IQR: 2–2 days) in Roma (Table 5). When we considered only patients with “Post-Glue” complications, the mean value of hospitalization days was  $21 \pm 11$  in Bari, while patient 1 in Verona was hospitalized for 8 days. No patient was hospitalized with “Post-Glue” complications in Roma site.

#### Discussion

PLB is considered a safe and effective method to obtain a diagnosis in patients with lung masses, but is charged by a sizeable number of complications that have financial implications for any public/private health system. The MIPP Kit PNX, a new medical device able to inject a surgical adhesive (such as BioGlue®) at the end of CT-guided thoracic biopsy procedures, can be a new promising tool able to reduce the risk of PLB-related PNX, hemorrhage or other complications.

In this multicenter, open-label, single-arm trial the complications occurring after glue administration at the end of PLB and within 48 h from the procedure were analyzed. Considering the 40 enrolled patients, a total of 3 (7.5%, 95% CI: 0.0–15.7%) “Post-Glue” complications were observed: two patients presented with minor PNX (5.0%, 95% CI: 0.0–12.7%), while one patient reported pulmonary hemorrhage (2.5%, 95% CI: 0.0–7.3%); no embolism or other complications were reported. This result, although obtained in an open label, single-arm study, provides initial and promising evidence of efficacy of the device under investigation in preventing clinically significant complications after lung biopsy. Indeed, a comparison between these results and those obtained in the large recent meta-analysis by Heerink *et al.* (6), shows that the risk of complications for both FNA (24.0%, 95% CI: 18.2–30.8%) and CB (38.8%, 95% CI: 34.4–43.5%) is higher than the risk observed in this study, for which the upper 95% CI limit is 15.7%. Similar conclusions can be reached considering also the review by Khan *et al.* (37).

In the last years, some medical devices with sealant-based mechanism of action were tested to reduce the PLB-related complications, with encouraging results. In 2017, Ahrar *et al.* (38) reported the results of a retrospective study comparing 318 patients who received BioSentry™ (a self-expanding tract sealant device) during PLB, with 1956 patients who did not. Chi-square contingency matched pair analysis showed that the treated group had significantly lower PNX (20.8% *vs.* 32.8%) and chest tube rates (8.2% *vs.* 20.8%), compared to controls. Zaetta *et al.* (23) evaluated the ability of an expanding hydrogel lung biopsy tract plug to reduce the rates of pneumothoraces and other complications during CT-guided lung biopsy. Compared with control subjects, treatment subjects had fewer pneumothoraces (18% *vs.* 31%), fewer chest tubes placed (4% *vs.* 11%), and fewer post-biopsy hospital admissions (9% *vs.* 14%). Petsas *et al.* (39) used fibrin glue as a sealant in 26 patients following PLB. PNX developed in 5 patients (19.2%) of the glue-treated group; in one instance, drainage was required (3.8%). In the control group, PNX was observed in 13 patients (40.6%) and in six instances (18.8%) drainage was required; the difference in chest-tube drainage was statistically significant between the two groups ( $P<0.025$ ).

Even if this clinical investigation is a hypothesis-generating one according to its design, the effect of the MIPP-kit PNX device, in association with a surgical sealant, in preventing and/or reducing the incidence of

**Table 4** Type of complications by ECOG score, type of device, caliber of device, location of biopsy procedure, depth of lesion from skin and biopsy procedure duration

Variables	No complication (N=23)	“Pre-Glue” complication (N=14)	“Post-Glue” complication (N=3)	P <sup>†</sup>	P <sup>‡</sup>
ECOG score, n (%)				0.79	0.70
0	13 (56.5)	8 (57.1)	2 (66.7)		
1	9 (39.1)	4 (28.6)	1 (33.3)		
2	1 (4.4)	2 (14.3)	0 (0.0)		
Type of device, n (%)				0.041	0.76
MIPP-KIT-PNX10	21 (91.3)	11 (78.6)	1 (33.3)		
MIPP-KIT-PNX15	2 (8.7)	3 (21.4)	2 (66.7)		
Caliber of device, n (%)				0.46	0.71
17G	21 (91.3)	14 (100.0)	3 (100.0)		
18G	2 (8.3)	0 (0.0)	0 (0.0)		
Location of biopsy procedure, n (%)				0.72	0.85
Day hospital	2 (8.7)	2 (14.3)	0 (0.0)		
Hospitalized	21 (91.3)	12 (85.7)	3 (100.0)		
Depth of lesion from skin (cm)				0.84	0.08
Mean ± SD	6±2	5±3	7±3		
Median [IQR]	6 [4–8]	5 [4–5]	7 [4–9]		
Min-Max	3–10	2–15	4–9		
Biopsy duration (min)				0.30	0.66
Mean ± SD	44±30	71±111	68±31		
Median [IQR]	30 [21–65]	35 [25–70]	75 [34–95]		
Min-Max	15–130	14–445	34–95		
Size of lesion (mm)				0.39	0.82
Mean ± SD	43±27	29±25	43±30		
Median [IQR]	43 [20–55]	19 [14–31]	36 [18–76]		
Range	10–124	12–85	18–76		

<sup>†</sup>, P value from Chi-Square test for ECOG score, type of device, caliber of device and location of biopsy procedure. P value from ANOVA model for mean value of depth of lesion from skin, biopsy duration and size of lesion; <sup>‡</sup>, P values from multivariate ANOVA model. ECOG, Eastern Cooperative Oncology Group; SD, standard deviation; IQR, interquartile range.

post-lung biopsy complications compares favourably with the previous ones, and was achieved with a low incidence of adverse events and a great sense of investigator satisfaction, emphasizing how promising this preliminary data is. Moreover, in a prospective and logical projection, it could be likely associated with a sizeable healthcare cost impact, a measure of which can be deduced from the data presented by Lokhandwala *et al.* (40). Using retrospective MEDICARE administrative claims data on

8,979 lung cancer diagnoses in patients with an abnormal CT scan, PLB-related AEs were reported in 19% of patients undergoing a PLB, with an average cost/patient of \$37,745±60,129 (median: \$14,824); this represented a 4-fold increase with respect to patients without AEs (\$8,869±15,312, median: \$2235).

In the present trial, patients with “Pre-Glue” complications (35%) did not experience any “Post-Glue” complications, suggesting a potential effect of the device



**Table 5** Length of hospital stay after percutaneous lung biopsy using MIPP-Kit PNx, based on investigational site

Hospitalization days	Total
Bari (N=15)	
Mean ± SD	10±7
Median [IQR]	8 [6–13]
Range	2–29
Verona (N=15)	
Mean ± SD	6±10
Median [IQR]	2 [0–7]
Range	0–33
Roma (N=10)	
Mean ± SD	2±1
Median [IQR]	2 [2–2]
Range	2–4

N, number of patients enrolled at indicated investigational site. SD, standard deviation; IQR, interquartile range.

in the prevention of such complications from worsening/recurring, despite the high risk inherent in such patients. In addition, the “Pre-Glue” complication rate was quite higher (35%) than the one observed “Post-Glue” (7.5%) in the most conservative analysis. This finding is at variance with what has been shown in two studies performed at a single institution, in which the incidence of early and late complications, comparable to “Pre-” and “Post-Glue” complications, were assessed in two cohorts of 388 and 594 patients, respectively (41,42). In fact, while the incidence of early and late complications, overall and with reference to PNx, was rather similar in these studies, the “Post-Glue” complications shown in the present study had a much lower incidence and were not occurring in patients with previous “Pre-Glue” complications (theoretically at a higher risk of developing post-operative complications). Even if indicative, in the last years prior to the study, PLB procedures at two investigational sites were associated with PNx in 18–20% of cases (unpublished data), with PNx requiring drainage and increasing post-biopsy hospitalization in 7%.

The current trial has some limitations. Its open-label, single-arm design was used to collect initial safety and performance evidence of the MIPP Kit PNx device in the PLB setting, without formal sample size calculations; its promising results, however, will be used to adequately power future controlled trials with a larger number of

subjects. Another limitation of this study is the absence of a thorough cost-impact analysis of the MIPP Kit PNx in clinical practice; at any rate, its preliminary results suggest a potential economical benefit of the MIPP Kit PNx to reduce the post-biopsy procedure complications, hence potentially minimizing their correlated healthcare costs. Future pharmaco-economic studies are needed for a complete evaluation of such an economical impact.

## Conclusions

In conclusion, the data from our multicenter, open-label, single-arm study support the use of MIPP kit PNx, in association with a surgical sealant such as BioGlue®, as safe and effective in the prevention of post-lung biopsy complications; these promising preliminary results warrant further confirmation in larger clinical trials.

## Acknowledgments

*Funding:* The study was supported by a research grant by BetaGlue Technologies SpA (No. MIPP-PNx1).

## Footnote

*Reporting Checklist:* The authors have completed the TREND reporting checklist. Available at <https://tcr.amegroups.com/article/view/10.21037/tcr-22-1203/rc>

*Data Sharing Statement:* Available at <https://tcr.amegroups.com/article/view/10.21037/tcr-22-1203/dss>

*Peer Review File:* Available at <https://tcr.amegroups.com/article/view/10.21037/tcr-22-1203/prf>

*Conflicts of Interest:* All authors have completed the ICMJE uniform disclosure form (available at <https://tcr.amegroups.com/article/view/10.21037/tcr-22-1203/coif>). PLC has been VP Clinical Operations at Betaglue after the study started until its completion. AA has been CEO/CMO at Betaglue for the entire duration of the study. The other authors have no conflicts of interest to declare.

*Ethical Statement:* The authors are accountable for all aspects of the work in ensuring that questions related to the accuracy or integrity of any part of the work are appropriately investigated and resolved. This study was conducted in conformity with the ethical principles set forth

by the Declaration of Helsinki (as revised in 2013), Good Clinical Practice (GCP) principles, international standards for clinical investigation of medical devices ISO 14155:2011, the laws and regulations of the countries where the study took place, and indemnity/insurance requirements. The investigational plan, the informed consent form and any other study related requested documents were reviewed and approved by the appropriate Ethics Committee where the trial was conducted (Istituto Tumori Giovanni Paolo II, Bari (Italy); Verona University Hospital, Verona (Italy); Fondazione Policlinico Universitario A. Gemelli, Rome (Italy) (Prot. n.691/CE, Prot. n.39256 and Prot.n.sf 45195/19 ID:2649 respectively). Informed consent process was mandatory for participation in clinical investigation, and had to be obtained from all subjects and/or their legal representatives as per local regulations, prior to their participation in the study.

*Open Access Statement:* This is an Open Access article distributed in accordance with the Creative Commons Attribution-NonCommercial-NoDerivs 4.0 International License (CC BY-NC-ND 4.0), which permits the non-commercial replication and distribution of the article with the strict proviso that no changes or edits are made and the original work is properly cited (including links to both the formal publication through the relevant DOI and the license). See: <https://creativecommons.org/licenses/by-nc-nd/4.0/>.

## References

- Lorenz J, Blum M. Complications of percutaneous chest biopsy. *Semin Intervent Radiol* 2006;23:188-93.
- Anzidei M, Porfiri A, Andrani F, et al. Imaging-guided chest biopsies: techniques and clinical results. *Insights Imaging* 2017;8:419-28.
- Wang J, Ni Y, Yang X, et al. Diagnostic ability of percutaneous core biopsy immediately after microwave ablation for lung ground-glass opacity. *J Cancer Res Ther* 2019;15:755-9.
- Khan RA, Kumar V, Taimur M, et al. Diagnostic Yield of Ultrasound-guided Trucut Biopsy in Diagnosis of Peripheral Lung Malignancies. *Cureus* 2019;11:e4802.
- Vestering MM, Braak SJ. Where are we on (preventing) pneumothorax after (cone-beam) computed tomography-guided lung biopsy? *J Thorac Dis* 2015;7:E341-3.
- Heerink WJ, de Bock GH, de Jonge GJ, et al. Complication rates of CT-guided transthoracic lung biopsy: meta-analysis. *Eur Radiol* 2017;27:138-48.
- Beşir FH, Altın R, Kart L, et al. The results of computed tomography guided tru-cut transthoracic biopsy: complications and related risk factors. *Wien Klin Wochenschr* 2011;123:79-82.
- Bozbas SS, Akcay S, Ergur FO, et al. Transthoracic lung and mediastinal biopsies obtained with the Tru-Cut technique: 10 years' experience. *Turkish J Med Sci* 2010;40:495-501.
- Lim CS, Tan LE, Wang JY, et al. Risk factors of pneumothorax after CT-guided coaxial cutting needle lung biopsy through aerated versus nonaerated lung. *J Vasc Interv Radiol* 2014;25:1209-17.
- Hiraki T, Mimura H, Gobara H, et al. Incidence of and risk factors for pneumothorax and chest tube placement after CT fluoroscopy-guided percutaneous lung biopsy: retrospective analysis of the procedures conducted over a 9-year period. *AJR Am J Roentgenol* 2010;194:809-14.
- Khan MF, Straub R, Moghaddam SR, et al. Variables affecting the risk of pneumothorax and intrapulmonary hemorrhage in CT-guided transthoracic biopsy. *Eur Radiol* 2008;18:1356-63.
- Kinoshita F, Kato T, Sugiura K, et al. CT-guided transthoracic needle biopsy using a puncture site-down positioning technique. *AJR Am J Roentgenol* 2006;187:926-32.
- Laurent F, Latrabe V, Vergier B, et al. CT-guided transthoracic needle biopsy of pulmonary nodules smaller than 20 mm: results with an automated 20-gauge coaxial cutting needle. *Clin Radiol* 2000;55:281-7.
- Maataoui A, Vogl TJ, Jacobi V, et al. Diagnostic accuracy of CT readings on coin lesions in the lung as compared with transthoracic CT-guided needle biopsy results. *Pneumologie* 2012;66:432-6.
- Mendiratta-Lala M, Sheiman R, Brook OR, et al. CT-guided core biopsy and percutaneous fiducial seed placement in the lung: can these procedures be combined without an increase in complication rate or decrease in technical success? *Eur J Radiol* 2014;83:720-5.
- Montaudon M, Latrabe V, Pariente A, et al. Factors influencing accuracy of CT-guided percutaneous biopsies of pulmonary lesions. *Eur Radiol* 2004;14:1234-40.
- Patel MV, Ahmed O, Jilani D, et al. Computed tomography-guided percutaneous lung biopsy: impact of lesion proximity to diaphragm on biopsy yield and pneumothorax rate. *J Thorac Imaging* 2014;29:344-9.
- Prosch H, Stadler A, Schilling M, et al. CT fluoroscopy-guided vs. multislice CT biopsy mode-guided lung biopsies: accuracy, complications and radiation dose. *Eur J*

- Radiol 2012;81:1029-33.
19. Gupta S, Wallace MJ, Cardella JF, et al. Quality improvement guidelines for percutaneous needle biopsy. *J Vasc Interv Radiol* 2010;21:969-75.
  20. Zhu J, Qu Y, Wang X, et al. Risk factors associated with pulmonary hemorrhage and hemoptysis following percutaneous CT-guided transthoracic lung core needle biopsy: a retrospective study of 1,090 cases. *Quant Imaging Med Surg* 2020;10:1008-20.
  21. Vestering MM, Braak SJ. Where are we on (preventing) pneumothorax after (cone-beam) computed tomography-guided lung biopsy? *J Thorac Dis* 2015;7:E341-3.
  22. Li Y, Du Y, Luo TY, et al. Usefulness of normal saline for sealing the needle track after CT-guided lung biopsy. *Clin Radiol* 2015;70:1192-7.
  23. Zaetta JM, Licht MO, Fisher JS, et al. A lung biopsy tract plug for reduction of postbiopsy pneumothorax and other complications: results of a prospective, multicenter, randomized, controlled clinical study. *J Vasc Interv Radiol* 2010;21:1235-43.e1-3.
  24. Moore EH, LeBlanc J, Montesi SA, et al. Effect of patient positioning after needle aspiration lung biopsy. *Radiology* 1991;181:385-7.
  25. Collings CL, Westcott JL, Banson NL, et al. Pneumothorax and dependent versus nondependent patient position after needle biopsy of the lung. *Radiology* 1999;210:59-64.
  26. Bures M, Zardo P, Länger F, et al. Improved application technique of albumin-glutaraldehyde glue for repair of superficial lung defects. *J Cardiothorac Surg* 2016;11:149.
  27. Summary of Safety and Effectiveness CryoLife, Inc., BioGlue® Surgical Adhesive. Available online: [https://www.accessdata.fda.gov/cdrh\\_docs/pdf/P010003b.pdf](https://www.accessdata.fda.gov/cdrh_docs/pdf/P010003b.pdf)
  28. Tsilimigras DI, Antonopoulou A, Ntanasis-Stathopoulos I, et al. The role of BioGlue in thoracic surgery: a systematic review. *J Thorac Dis* 2017;9:568-76.
  29. Belcher E, Dusmet M, Jordan S, et al. A prospective, randomized trial comparing BioGlue and Vivostat for the control of alveolar air leak. *J Thorac Cardiovasc Surg* 2010;140:32-8.
  30. Hidas G, Kastin A, Mullerad M, et al. Sutureless nephron-sparing surgery: use of albumin glutaraldehyde tissue adhesive (BioGlue). *Urology* 2006;67:697-700; discussion 700.
  31. Nandakumar G, Richards BG, Trencheva K, et al. Surgical adhesive increases burst pressure and seals leaks in stapled gastrojejunostomy. *Surg Obes Relat Dis* 2010;6:498-501.
  32. Qiu L, Qi See AA, Steele TWJ, et al. Bioadhesives in neurosurgery: a review. *J Neurosurg* 2019. [Epub ahead of print]. doi: 10.3171/2019.8.JNS191592.
  33. Fisher WE, Chai C, Hodges SE, et al. Effect of BioGlue on the incidence of pancreatic fistula following pancreas resection. *J Gastrointest Surg* 2008;12:882-90.
  34. Daniele E, Dissanaik S. BioGlue for traumatic liver laceration. *Int J Surg Case Rep* 2016;23:33-5.
  35. Izzo F, Palaia R, Albino V, et al. Hepatocellular carcinoma and liver metastases: clinical data on a new dual-lumen catheter kit for surgical sealant infusion to prevent perihepatic bleeding and dissemination of cancer cells following biopsy and loco-regional treatments. *Infect Agent Cancer* 2015;10:11.
  36. Izzo F, Albino V, Palaia R, et al. Hepatocellular carcinoma: preclinical data on a dual-lumen catheter kit for fibrin sealant infusion following loco-regional treatments. *Infect Agent Cancer* 2014;9:39.
  37. Khan MF, Straub R, Moghaddam SR, et al. Variables affecting the risk of pneumothorax and intrapulmonary hemorrhage in CT-guided transthoracic biopsy. *Eur Radiol* 2008;18:1356-63.
  38. Ahrar JU, Gupta S, Ensor JE, et al. Efficacy of a Self-expanding Tract Sealant Device in the Reduction of Pneumothorax and Chest Tube Placement Rates After Percutaneous Lung Biopsy: A Matched Controlled Study Using Propensity Score Analysis. *Cardiovasc Intervent Radiol* 2017;40:270-6.
  39. Petsas T, Siamblis D, Giannakenas C, et al. Fibrin glue for sealing the needle track in fine-needle percutaneous lung biopsy using a coaxial system: Part II--Clinical study. *Cardiovasc Intervent Radiol* 1995;18:378-82.
  40. Lokhandwala T, Bittoni MA, Dann RA, et al. Costs of Diagnostic Assessment for Lung Cancer: A Medicare Claims Analysis. *Clin Lung Cancer* 2017;18:e27-34.
  41. Yamagami T, Kato T, Hirota T, et al. Duration of pneumothorax as a complication of CT-guided lung biopsy. *Australas Radiol* 2006;50:435-41.
  42. Yamagami T, Terayama K, Yoshimatsu R, et al. Role of manual aspiration in treating pneumothorax after computed tomography-guided lung biopsy. *Acta Radiol* 2009;50:1126-33.

**Cite this article as:** Gadaleta CD, Iezzi R, Tanzilli A, Puppini G, Carriero PL, Amato A. Pilot clinical study on the prevention of complications after lung biopsy by the MIPP kit PNx device. *Transl Cancer Res* 2022;11(12):4338-4348. doi: 10.21037/tcr-22-1203