



# Long-term survival of a non-small cell lung cancer patient with *EGFR*-mutated brain metastases: a case report

Yuming Wan<sup>1</sup>, Feng Xu<sup>1,2</sup>, Jin Wang<sup>1</sup>

<sup>1</sup>Cancer Center, West China Hospital, Sichuan University, Chengdu, China; <sup>2</sup>Lung Cancer Center, West China Hospital, Sichuan University, Chengdu, China

**Contributions:** (I) Conception and design: F Xu, J Wang; (II) Administrative support: Y Wan, J Wang; (III) Provision of study materials or patients: All authors; (IV) Collection and assembly of data: Y Wan, J Wang; (V) Data analysis and interpretation: All authors; (VI) Manuscript writing: All authors; (VII) Final approval of manuscript: All authors.

**Correspondence to:** Jin Wang. Cancer Center, West China Hospital, Sichuan University, No. 37, Guoxue Lane, Chengdu, China.

Email: 18980601785@163.com.

**Background:** Lung cancer is the leading cause of cancer-related death worldwide. Up to 85% of lung cancer is non-small cell lung cancer (NSCLC) and most patients present with advanced disease at first diagnosis. Targeted therapy plays an important role in the treatment of advanced NSCLC. Epidermal growth factor receptor (*EGFR*) mutation is a predictive marker of sensitivity to *EGFR* tyrosine kinase inhibitors (TKIs). Patients with *EGFR*-mutated NSCLC are prone to developing central nervous system (CNS) metastasis and poor prognosis (4–6 months). Brain metastases (BMs) remain a tricky problem in NSCLC patients and impose a distinct challenge for clinicians.

**Case Description:** This article details a patient with *EGFR*-mutated BMs accepting a series of treatments but without chemotherapy, resulting in significantly prolonged survival with overall survival (OS) over 8 years and improved clinical symptoms. The patient in our case received four lines of treatments and the progression-free survival (PFS) in each line were longer than the previously reported without exception. It is worth noting that the combination of osimertinib and bevacizumab used in the fourth-line therapy has a PFS of 31 months and has not progressed so far.

**Conclusions:** Our case demonstrates that it is possible to achieve long-term survival in advanced *EGFR*-mutated NSCLC with multiple BMs and systemic progression through a reasonable therapeutic schedule.

**Keywords:** Non-small cell lung cancer (NSCLC); brain; metastases; epidermal growth factor receptor (*EGFR*); case report

Submitted Jun 14, 2022. Accepted for publication Nov 04, 2022.

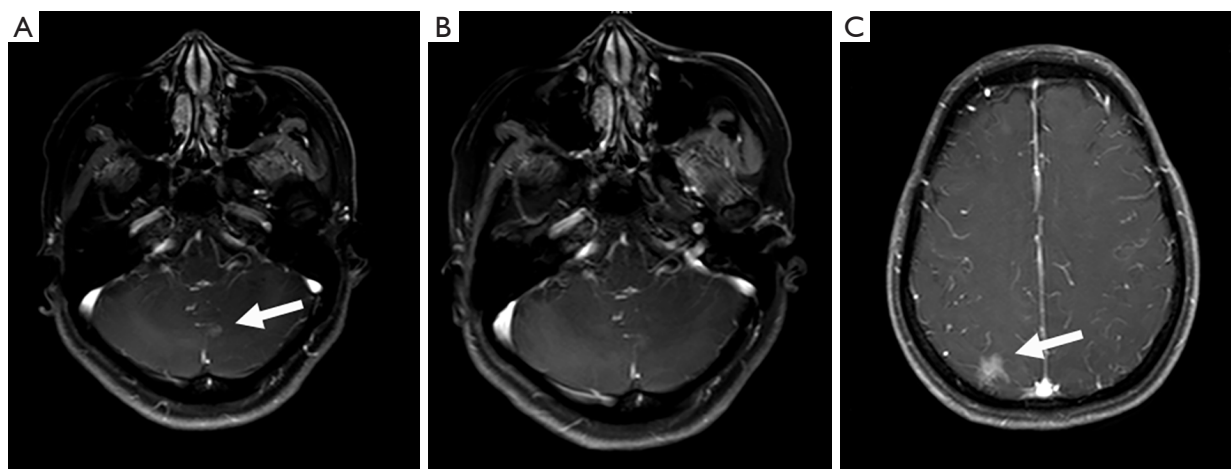
doi: 10.21037/tcr-22-1671

**View this article at:** <https://dx.doi.org/10.21037/tcr-22-1671>

## Introduction

Lung cancer is one of the most common cancers worldwide. A significant number of patients have advanced disease at the time of diagnosis. Targeted therapy plays an important role in the treatment of advanced lung cancer; epidermal growth factor receptor (*EGFR*)-mutations predict the response of *EGFR*-tyrosine kinase inhibitors (TKIs) such as gefitinib, erlotinib, afatinib, or dacomitinib, with response rates of around 70% (1). *T790M* mutation accounts for

approximately half of the acquired resistance to *EGFR*-TKI (2). Osimertinib has been developed to act against *T790M* resistance mutation. Brain metastases (BMs) cause morbidity and mortality in patients with non-small cell lung cancer (NSCLC) (3). It was reported that 10% to 20% of NSCLC patients have BMs at their first diagnosis, and 25% to 50% of NSCLC patients will ultimately develop BMs during the course of the disease (4). The median and 1-, 2-, and 3-year overall survival (OS) for NSCLC patients with BMs were 6 months and 29.9%, 14.3%, and 8.4% respectively (5).



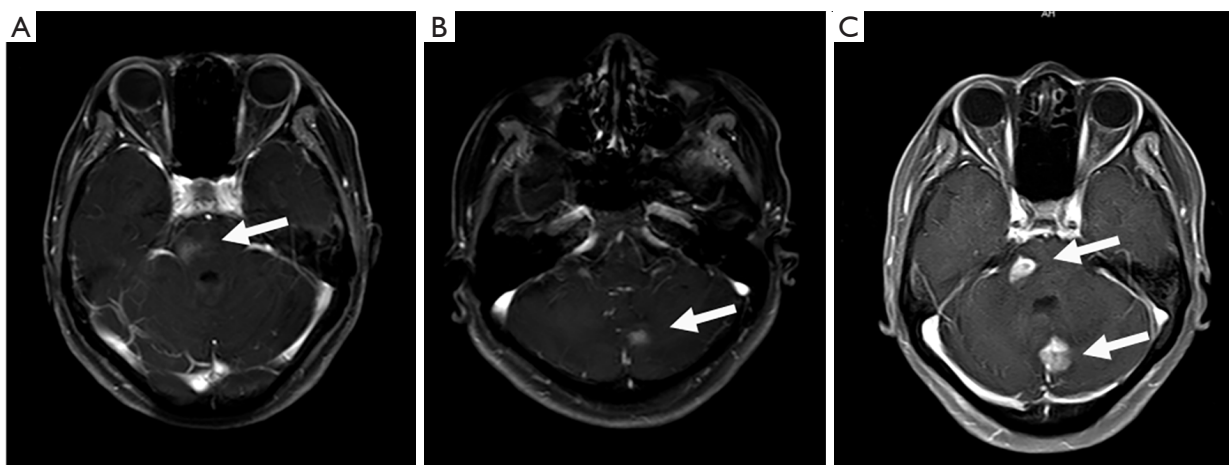
**Figure 1** The brain MRI of the patient during the course of disease. (A) Brain metastasis in left cerebellar hemisphere after lung cancer surgery. (B) The left cerebellar hemisphere metastasis was significantly reduced after 1 month of gefitinib treatment. (C) New lesion appeared in the right parietal lobe after 40 months of gefitinib treatment. The arrows indicate the location of BMs. MRI, magnetic resonance imaging; BMs, brain metastases.

BM's remain a tricky problem in NSCLC patients and impose a distinct challenge for clinicians. Several therapeutic schedules are efficacious for these patients which include third-generation *EGFR*-TKIs, *EGFR*-TKIs + anti-vascular endothelial growth factor receptor (VEGFR), *EGFR*-TKIs + stereotactic radiosurgery/whole brain radiotherapy (SRS/WBRT) and second-generation *EGFR*-TKI (6). Yet preferable treatments for *EGFR*-mutated NSCLC with BM's are elusive. Our case shares an NSCLC patient who achieved an OS over 8 years after brain metastasis through a range of therapies but without chemotherapy. We present the following case in accordance with the CARE reporting checklist (available at <https://tc.amegroups.com/article/view/10.21037/tcr-22-1671/rc>).

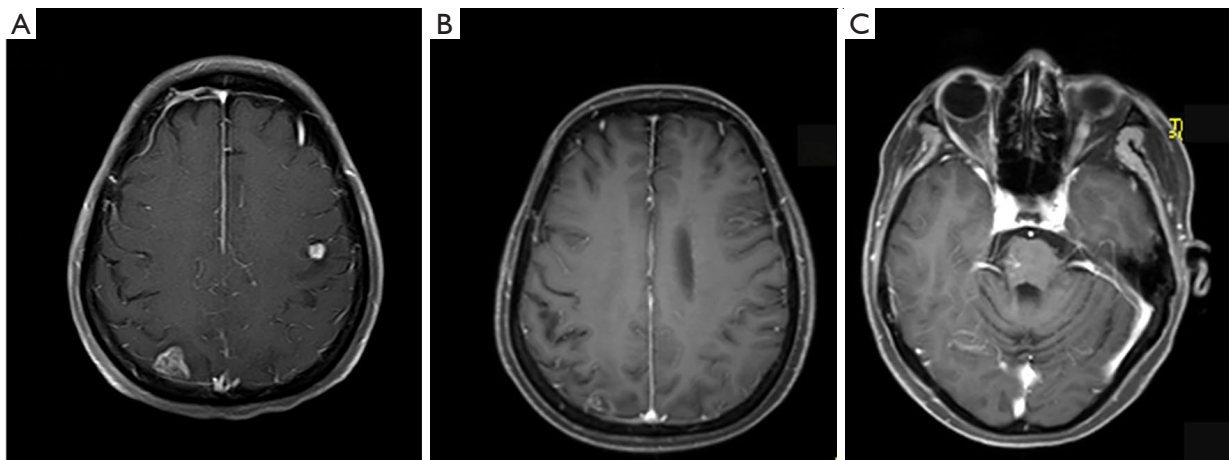
### Case presentation

A 53-year-old woman, never smoked, was diagnosed with *EGFR*-mutant (exon 19 deletion, diagnosis method: ADx-ARMs) NSCLC with asymptomatic solitary brain metastasis on March 15, 2014, merely 1 month after lung cancer surgery (Figure 1A). No brain metastasis was detected preoperatively by enhanced magnetic resonance imaging (MRI). The patient was postoperatively diagnosed as left upper lung adenosquamous carcinoma (predominant in adenocarcinoma component) with interlobar lymph node metastasis [American Joint Committee on Cancer (AJCC) version 7 staging pT2aN1M0]. Once diagnosed

with brain metastasis, the patient initiated gefitinib treatment (250 mg daily), and then the size of brain metastasis shrank significantly 1 month after treatment (Figure 1B). Gefitinib was initially well-tolerated with confirmation of disease response for 40 months, then MRI documented disease progression in the brain showing new lesions appeared in the right parietal lobe and right pons and the original lesion in left cerebellar hemisphere enlarged (Figures 1C, 2A, 2B). As no tumor site was suitable for biopsy while disease progression was merely limited to the brain, a digital polymerase chain reaction (PCR) assay for *EGFR T790M* mutation on plasma sample was performed and revealed a negative result. Chemotherapy and a cerebral spinal fluid (CSF) gene detection assay were recommended but both were refused by the patient. Considering no extracranial relapse, the patient was given erlotinib (150 mg/day) and whole brain radiotherapy (30 Gy in 10 fractions) followed by boosted dose to the gross tumor (10 Gy in 5 fractions for pons tumor and 15 Gy in 5 fractions for the rest of the metastatic tumor). Two months later, the patient developed serious neurologic symptoms of numbness in the left upper limb and brain edema, and a brain MRI documented disease progression demonstrating a new metastatic lesion in the left frontal lobe and enlargement of the previously irradiated brain lesions (Figures 2C, 3A). Meanwhile a bone scan revealed new metastasis in the sternum. A repeated plasma liquid biopsy showed the same *T790M* negative state as before.



**Figure 2** The brain MRI of the patient during the course of disease. (A) New lesion appeared in right pons after 40 months of gefitinib treatment. (B) The original lesion in left cerebellar hemisphere enlarged after 40 months of gefitinib treatment. (C) The lesions in right pons and left cerebellar hemisphere progressed after erlotinib and whole brain radiotherapy. The arrows indicate the location of BMs. MRI, magnetic resonance imaging; BMs, brain metastases.

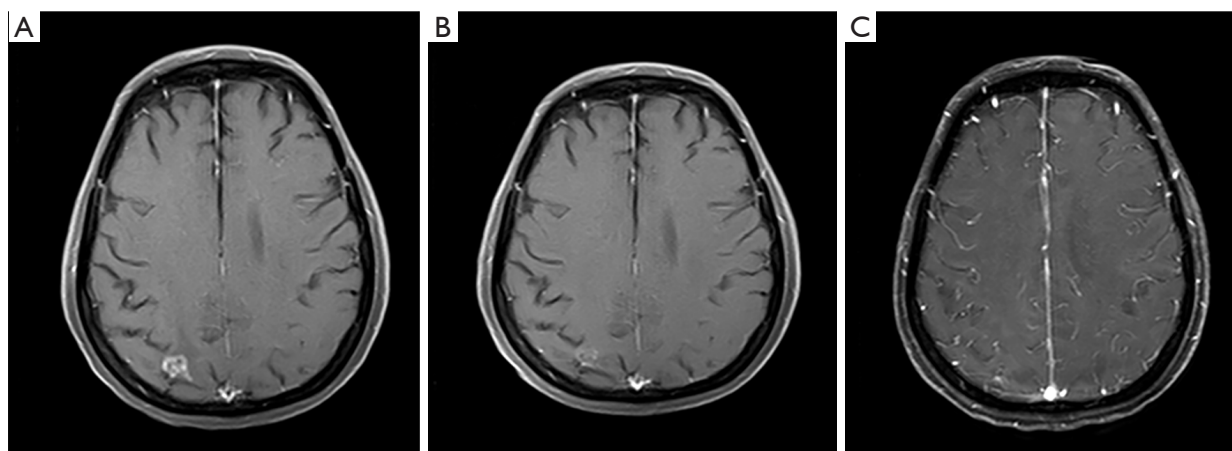


**Figure 3** The brain MRI of the patient during the course of disease. (A) The lesion in the right parietal lobe enlarged after erlotinib and whole brain radiotherapy. (B) The BM in the right parietal lobe nearly disappeared after osimertinib treatment. (C) The BM in the right pons and the original lesion in left cerebellar hemisphere nearly disappeared after osimertinib treatment. MRI, magnetic resonance imaging; BM, brain metastasis.

The off-label use for osimertinib was admitted and she was switched to osimertinib treatment (80 mg/day) on December 14, 2017. The patient then achieved disease control quickly, with her neurologic symptoms disappeared (Figure 3B,3C). The patient was diagnosed with the progression of brain disease with a newly developed brain mass after 22 months of osimertinib treatment (Figure 4A). Since then, she initiated bevacizumab (7.5 mg/kg i.v. every

21 day) without osimertinib interruption. The newly developed brain mass resolved after 1 month of treatment (Figure 4B,4C) and the disease is still responding until the last follow-up (May 2022). During the course, a next generation sequencing (NGS) assay for 23 NSCLC cancer-related genes on plasma samples was performed again on April 25, 2022 and revealed the same *EGFR*-mutant (exon 19 deletion).

In the case report, treatment consent was obtained from the



**Figure 4** The brain MRI of the patient during the course of disease. (A) The BM was enlarged again after 22 months of osimertinib treatment. (B) The BM was significantly relieved after 1 month of the combined treatment of osimertinib and bevacizumab. (C) The BM were nearly disappeared after 3 months of the combined treatment of osimertinib and bevacizumab. MRI, magnetic resonance imaging; BM, brain metastasis.

patient, and she is satisfied with the therapeutic schedule and the results so far. We have de-identified the details such that the identity of the patient may not be ascertained in any way. All procedures performed in this study were in accordance with the ethical standards of the institutional and/or national research committee(s) and with the Helsinki Declaration (as revised in 2013). Written informed consent was obtained from the patient for publication of this case report and accompanying images. A copy of the written consent is available for review by the editorial office of this journal.

## Discussion

In our case, the NSCLC patient with *EGFR*-mutated brain metastasis achieved long-term survival. The OS is more than 8 years and the progression-free survival (PFS) of gefitinib was 40 months, whereas the PFS of osimertinib monotherapy was 22 months, and the combination therapy of osimertinib and bevacizumab has a PFS of 31 months and has not progressed so far.

A prospective phase II study in Japan evaluated the efficacy of gefitinib alone without radiation therapy for the treatment of patients with brain metastasis from lung adenocarcinoma, the result showed an objective response rate (ORR) of 87.8%, a median PFS of 14.5 months (95% CI: 10.2–18.3 months) and a median OS of 21.9 months (95% CI: 18.5–30.3 months) (7). Compared with L858R, exon 19 deletion was associated with a better outcome for patients after treatment with

gefitinib in both PFS (10.2 *vs.* 17.5 months,  $P=0.003$ ) and OS (19.8 *vs.* 30.3 months,  $P=0.025$ ) (7). Another prospective clinical phase II study in Korea revealed that NSCLC patients harboring *EGFR* mutation with brain metastasis and receiving gefitinib or erlotinib achieved a disease control rate (DCR) of 93%, and the median PFS and OS were 6.6 months (95% CI: 3.8–9.3 months) and 15.9 months (95% CI: 7.2–24.6 months), respectively (8). In our case, the PFS of gefitinib was 40 months, which is significantly longer than the literature reported (14.5 months) (7).

In this case, when the disease progressed after gefitinib treatment, the lesions were intracranial, and the patient refused CSF biopsy. A liquid biopsy on plasma sample revealed negative for *T790M* mutation, thus there was no indication for the 3rd generation TKI. Under such circumstances, chemotherapy can be used after gefitinib treatment. However, the progression after gefitinib treatment was limited intracranial. A related study reported that after the failure of advanced NSCLC with gefitinib, erlotinib can achieve a good effect with 5–10% partial response (PR) and 40–60% stable disease (SD) (9), which could be explained by erlotinib's higher biological concentration and better permeability of the blood-brain barrier. Considering the synergetic efficacy of *EGFR*-TKIs + SRS/WBRT in *EGFR*-mutant NSCLC with brain metastasis (6), erlotinib was used in combination with brain radiotherapy to control brain metastasis. But it didn't work in our case.

Osimertinib had favorable blood-brain barrier permeability and showed significant efficacy in brain

metastasis (10). In the phase 3 FLAURA study, the median PFS of advanced NSCLC patients with *EGFR*-mutation and brain metastasis having received osimertinib (as first-line treatment) was 15.2 months (95% CI: 12.1–21.4 months), the ORR was 66% (11), among them, the *T790M* status were unknown. In the phase 1 AURA1-trial, 61 patients without *T790M* mutation achieved an ORR of 21%, DCR of 61% and a median PFS of 2.8 months (95% CI: 2.1–4.3 months) (12). The TREM-study is a multi-center, phase 2 clinical trial conducted in five Northern European countries, in the *T790M*-negative cohort treated with osimertinib after disease progression on at least one previous *EGFR*-TKI, patients had a response rate of 28% and PFS of 5.1 months (95% CI: 2.6–7.6 months), within the *T790M* negative group, the ORR for patients with BMs and without was 33% vs. 26% ( $P=0.718$ ) (1). The AURA1-trial was a dose expansion trial, 20 patients received daily doses lower than the recommended 80 mg, that might explain the lower efficacy compared to the latter study (12). Our results were in agreement with the real-world study which the application of osimertinib further improves survival outcomes regardless of *T790M* status (3).

In our case, after treatment with osimertinib, the PFS was 22 months, the survival time was significantly prolonged and clinical symptoms were improved. The mechanism for this observed activity of osimertinib in patients without *T790M*-mutation remains unclear, but might at least in part due to a false negative *T790M* situation caused by too low circulatory tumor DNA (ctDNA) concentration in peripheral blood to be detected; The mechanism of *T790M* resistance might be squamous cell transformation, pleomorphic transformation, and *EGFR* mutations (*L718Q* and *C797S*) (13). Other explanations suggested that there was difference in the timing of emergence of *T790M* mutation; some investigators demonstrated that the *T790M* status in an individual patient can be spatiotemporally and temporally heterogeneous due to selective pressure from *EGFR*-TKI (2). In our case, *T790M* mutation was negative by peripheral blood. Though the reliability of liquid biopsy of *T790M* on plasma sample is poor when the tumor burden is low, it is difficult to obtain a biopsy of tumor tissue when the disease is merely limited to the brain and the patient refused CSF biopsy, we chose liquid biopsy. The reported sensitivity of plasma genotyping for the detection of *T790M* was 70% and the false-negative rate was 30% (14), so we repeated blood biopsy to reduce the false-negative rate. During the treatment course, we performed a total of four genetic tests, and the technologies used in liquid biopsy include

droplet digital PCR and NGS. Tissue biopsy is the most accurate detection method to determine the status of *T790M*, but it involves numerous challenges in terms of availability, safety, and cost.

Both osimertinib and bevacizumab can cross the blood-brain barrier, and have comparable effectiveness in the central nervous system (CNS) (15). Combination treatment of osimertinib and bevacizumab may work against BMs. Yu *et al.* present a phase 1/2 study of bevacizumab and osimertinib as initial treatment for patients with *EGFR* mutant lung cancers with BMs and 49 patients were included, the results suggest that combination treatment may be efficacious and protective against CNS progression in which the CNS response rate was 100%, the ORR was 80%, the median PFS was 19 months (13). In our case, *T790M* mutation was not detected in the patient, osimertinib as the third line TKI achieved a long-term response before intracranial disease progression. At the time of the third intracranial disease progression, bevacizumab was added to osimertinib as a fourth-line treatment and achieved nearly complete response of the newly developed metastasis and long-term control of BMs with no overlapping toxic effects.

Overall, the patient in our case achieved a long-term survival with the OS over 8 years after brain metastasis through a range of therapies but without chemotherapy. Baek *et al.* reported that the overall median survival after BM development (BM-OS) was significantly longer in patients with *EGFR* mutation type (MT) than in those with *EGFR* wild type (WT) (25.7 vs. 3.8 months,  $P<0.001$ ), and in patients with metachronous BM, BM-OS in patients with *EGFR* mutations was 14.5 months (16). Lung-mol Graded Prognostic Assessment (GPA) is recommended as an index to prognosticate patients with BM from NSCLC. According to Lung-mol GPA, younger age, better performance status, absence of extracranial metastasis (ECM), a smaller number of BM, and the *EGFR* mutation or anaplastic lymphoma kinase (*ALK*) rearrangement predict a favorable survival (17). Patients with more CNS lesions had inferior outcomes, and the number of involved extracranial organs was an independent prognostic factor for NSCLC patients with BM. In patients with single-organ ECM, a better prognosis was observed in lung and bone metastasis, while liver metastasis showed the worst survival (4).

## Conclusions

Our case showed that *EGFR*-TKI (1<sup>st</sup> and 3<sup>rd</sup> generation TKI) alone is effective in the control of brain metastasis in

NSCLC. Osimertinib can be tried after 1<sup>st</sup> generation TKI resistance even if with no *EGFR T790M* detected by liquid biopsy, bevacizumab added to osimertinib is effective for disease control when the intracranial disease progressed with osimertinib alone. Our case also denotes that radiation therapy for patients with asymptomatic brain metastasis could be delayed for a better quality of life in NSCLC patients. Osimertinib has been recognized as an effective treatment for BMs, and osimertinib in combination with bevacizumab may benefit as an upfront treatment for NSCLC with *EGFR* mutation. The novelty of our case is prolonged use of osimertinib in combination with the 4<sup>th</sup> line bevacizumab that achieved a longer survival. However, the benefit of bevacizumab in patients with intracranial progression after osimertinib therapy is not universal. This is a case report and further studies are needed to demonstrate which patients may benefit from combination therapy. In conclusion, our case shares a patient with *EGFR*-mutated BMs accepting a series of treatments but without chemotherapy and resulting in significantly prolonged survival with an OS over 8 years and improved clinical symptoms; it is promising to achieve a long-term survival in advanced NSCLC with multiple brain metastasis as well as systemic progression.

### Acknowledgments

*Funding:* None.

### Footnote

*Reporting Checklist:* The authors have completed the CARE reporting checklist. Available at <https://tcr.amegroups.com/article/view/10.21037/tcr-22-1671/rc>

*Conflicts of Interest:* All authors have completed the ICMJE uniform disclosure form (available at <https://tcr.amegroups.com/article/view/10.21037/tcr-22-1671/coif>). The authors have no conflicts of interest to declare.

*Ethical Statement:* The authors are accountable for all aspects of the work in ensuring that questions related to the accuracy or integrity of any part of the work are appropriately investigated and resolved. All procedures performed in this study were in accordance with the ethical standards of the institutional and/or national research committee and with the Helsinki Declaration (as revised in 2013). Written informed consent was obtained from the

patient for publication of this case report and accompanying images. A copy of the written consent is available for review by the editorial office of this journal.

*Open Access Statement:* This is an Open Access article distributed in accordance with the Creative Commons Attribution-NonCommercial-NoDerivs 4.0 International License (CC BY-NC-ND 4.0), which permits the non-commercial replication and distribution of the article with the strict proviso that no changes or edits are made and the original work is properly cited (including links to both the formal publication through the relevant DOI and the license). See: <https://creativecommons.org/licenses/by-nc-nd/4.0/>.

### References

1. Eide IJZ, Helland Å, Ekman S, et al. Osimertinib in T790M-positive and -negative patients with EGFR-mutated advanced non-small cell lung cancer (the TREM-study). *Lung Cancer* 2020;143:27-35.
2. Hata A, Katakami N, Yoshioka H, et al. Spatiotemporal T790M Heterogeneity in Individual Patients with EGFR-Mutant Non-Small-Cell Lung Cancer after Acquired Resistance to EGFR-TKI. *J Thorac Oncol* 2015;10:1553-9.
3. Yu X, Sheng J, Pan G, et al. Real-world utilization of EGFR TKIs and prognostic factors for survival in EGFR-mutated non-small cell lung cancer patients with brain metastases. *Int J Cancer* 2021;149:1121-8.
4. Wang M, Wu Q, Zhang J, et al. Prognostic impacts of extracranial metastasis on non-small cell lung cancer with brain metastasis: A retrospective study based on surveillance, epidemiology, and end results database. *Cancer Med* 2021;10:471-82.
5. Waqar SN, Samson PP, Robinson CG, et al. Non-small-cell Lung Cancer With Brain Metastasis at Presentation. *Clin Lung Cancer* 2018;19:e373-7.
6. Zhao B, Wang Y, Wang Y, et al. Efficacy and safety of therapies for EGFR-mutant non-small cell lung cancer with brain metastasis: an evidence-based Bayesian network pooled study of multivariable survival analyses. *Aging (Albany NY)* 2020;12:14244-70.
7. Iuchi T, Shingyoji M, Sakaida T, et al. Phase II trial of gefitinib alone without radiation therapy for Japanese patients with brain metastases from EGFR-mutant lung adenocarcinoma. *Lung Cancer* 2013;82:282-7.
8. Park SJ, Kim HT, Lee DH, et al. Efficacy of epidermal growth factor receptor tyrosine kinase inhibitors for

- brain metastasis in non-small cell lung cancer patients harboring either exon 19 or 21 mutation. *Lung Cancer* 2012;77:556-60.
9. Singh N, Jindal A, Behera D. Erlotinib usage after prior treatment with gefitinib in advanced non-small cell lung cancer: A clinical perspective and review of published literature. *World J Clin Oncol* 2014;5:858-64.
  10. Nanjo S, Ebi H, Arai S, et al. High efficacy of third generation EGFR inhibitor AZD9291 in a leptomeningeal carcinomatosis model with EGFR-mutant lung cancer cells. *Oncotarget* 2016;7:3847-56.
  11. Soria JC, Ohe Y, Vansteenkiste J, et al. Osimertinib in Untreated EGFR-Mutated Advanced Non-Small-Cell Lung Cancer. *N Engl J Med* 2018;378:113-25.
  12. Jänne PA, Yang JC, Kim DW, et al. AZD9291 in EGFR inhibitor-resistant non-small-cell lung cancer. *N Engl J Med* 2015;372:1689-99.
  13. Yu HA, Schoenfeld AJ, Makhnin A, et al. Effect of Osimertinib and Bevacizumab on Progression-Free Survival for Patients With Metastatic EGFR-Mutant Lung Cancers: A Phase 1/2 Single-Group Open-Label Trial. *JAMA Oncol* 2020;6:1048-54.
  14. Oxnard GR, Thress KS, Alden RS, et al. Association Between Plasma Genotyping and Outcomes of Treatment With Osimertinib (AZD9291) in Advanced Non-Small-Cell Lung Cancer. *J Clin Oncol* 2016;34:3375-82.
  15. Offin M, Feldman D, Ni A, et al. Frequency and outcomes of brain metastases in patients with HER2-mutant lung cancers. *Cancer* 2019;125:4380-7.
  16. Baek MY, Ahn HK, Park KR, et al. Epidermal growth factor receptor mutation and pattern of brain metastasis in patients with non-small cell lung cancer. *Korean J Intern Med* 2018;33:168-75.
  17. Sperduto PW, Yang TJ, Beal K, et al. Estimating Survival in Patients With Lung Cancer and Brain Metastases: An Update of the Graded Prognostic Assessment for Lung Cancer Using Molecular Markers (Lung-molGPA). *JAMA Oncol* 2017;3:827-31.

**Cite this article as:** Wan Y, Xu F, Wang J. Long-term survival of a non-small cell lung cancer patient with *EGFR*-mutated brain metastases: a case report. *Transl Cancer Res* 2022;11(12):4448-4454. doi: 10.21037/tcr-22-1671