



# Combining immunotherapy and radiotherapy in hepatocellular carcinoma: the importance of irradiated tumor burden and the possible role of a low dose radiotherapy induction strategy

Clemens Grassberger<sup>1^</sup>, Gentry King<sup>2</sup>, Smith Apisarnthanarax<sup>1</sup>

<sup>1</sup>Department of Radiation Oncology, University of Washington, Seattle, WA, USA; <sup>2</sup>Fred Hutchinson Cancer Research Center, University of Washington School of Medicine, Seattle, WA, USA

*Correspondence to:* Clemens Grassberger, PhD. Research Associate Professor, Radiation Oncology, School of Medicine, UW Medicine, 1959 NE Pacific St., Box 356043, Seattle, WA 98195, USA. Email: clemensg@uw.edu.

*Comment on:* Juloori A, Katipally RR, Lemons JM, *et al.* Phase 1 Randomized Trial of Stereotactic Body Radiation Therapy Followed by Nivolumab plus Ipilimumab or Nivolumab Alone in Advanced/Unresectable Hepatocellular Carcinoma. *Int J Radiat Oncol Biol Phys* 2023;115:202-13.

**Keywords:** Hepatocellular carcinoma (HCC); radiotherapy (RT); checkpoint inhibition; combination therapy; tumor burden

Submitted Feb 13, 2023. Accepted for publication Mar 16, 2023. Published online Apr 04, 2023.

doi: 10.21037/tcr-23-192

View this article at: <https://dx.doi.org/10.21037/tcr-23-192>

We congratulate Juloori *et al.* for their recently published phase I study (1) on stereotactic body radiotherapy (SBRT) followed by nivolumab plus ipilimumab or nivolumab alone in hepatocellular carcinoma (HCC). Their results are an excellent example of both the promise of combining radiotherapy (RT) with immune checkpoint inhibitors (ICI) in HCC, as well the pitfalls of analyzing and interpreting the results of RT/ICI combination trials.

The authors report the outcomes of thirteen randomly assigned patients, six in the nivolumab alone and seven in the nivolumab/ipilimumab arm. They report a higher rate of toxicities and higher overall response rates (4/7 *vs.* 0/6) in the dual ICI arm, with two patients alive after at least 3 years without progression and a negative PET scan. As the trial was powered for evaluation of dose-limiting toxicity and enrolled less than a quarter of the planned 50 patients, these results cannot be used to accurately assess the absolute or relative efficacy of these two combination regimens. This point is well made by the authors, as they mention that the observed overall response rate in the SBRT + nivolumab arm (0%) was lower than the 15–20% observed in CheckMate-040 nivolumab monotherapy trial encompassing 262 patients (2). Particularly when evaluating

immunotherapy, where response varies widely, a few outliers in a small population can invalidate the assumption of proportional hazards required by the log-rank test.

However, we would like to look past the small cohort size and discuss the results of this trial despite its lack of statistical power. What can this trial teach us about the way forward for RT/ICI combination trials in HCC?

When comparing the populations in the two trial arms, there is a large discrepancy in the extent of disease, with 50% of patients in the nivolumab only arm presenting with extra-hepatic disease, compared to only 14% in the dual-ICI arm. This is particularly important for this trial because only intrahepatic disease was irradiated. Furthermore, the maximum GTV was mostly restricted to 100 cc and in the case of multiple lesions, the RT target was left to investigator discretion. This means that the fraction of tumor burden irradiated in these patients varied widely and was lower in the patients in the nivolumab arm, as half of them had extrahepatic metastases, which by design, were not included in the target volume. This is an important distinction, and crucial for two reasons.

First, these limitations restrict the usefulness of metrics such as overall response rate and waterfall plots. Relying

<sup>^</sup> ORCID: 0000-0002-4425-4489.

on the best overall response and corresponding change in sum of diameters to evaluate immunotherapeutic agents has already been subject to criticism (3)—irradiating various fractions of tumor burden invalidates the maximum reduction in disease burden as a metric entirely. HCC is fairly radioresponsive and one would expect a large reduction in size for 40 Gy delivered in 5 fractions. The local control rate for such a regimen with a biologically effective dose  $\sim 72$  Gy is expected to be at least 75% (4). This matches the observed outcomes in their small cohort, with 83% local control at 6 months [90% confidence interval (CI): 39% to 97%]. If non-irradiated, extra-hepatic disease is present and accounts for  $\sim 50\%$  of tumor burden, this may obscure a robust response in the RT target lesions. Future studies need to state the fraction of visible tumor burden irradiated, as this information is as important as the prescribed radiation dose or the number of cycles of a systemic agent.

Second, it could affect the systemic disease response to the combination treatment regimen, as it is well known that immunotherapy works better when the disease burden is smaller. In the preclinical setting it has been shown that ICI response correlates best to the ratio of activated cytotoxic T cells to melanoma tumor burden (5), and that PD-1 blockade works better in smaller lung squamous cell tumors (6). The reduced efficacy of ICIs with higher tumor burden has also been observed in patients, with clear correlations observed in both melanoma (7,8) as well as non-small cell lung cancer (9) patients.

We performed a computational modeling study to specifically evaluate this phenomenon in HCC patients treated with dual-ICI and SBRT, a regimen currently being explored in an on-going trial [NCT03482102 (10)]. We investigated various parameters of the RT/ICI combination regimen, such as sequencing, radiation dose, fractionation, and fraction of tumor burden irradiated. Our results showed that by far the most important variable for the success of the combination regimen is the fraction of the tumor burden that is irradiated (11). The clinical benefit (sum of stable disease, partial and complete response) doubles from 33% to 72% when increasing the irradiated tumor burden from 50% to 90%.

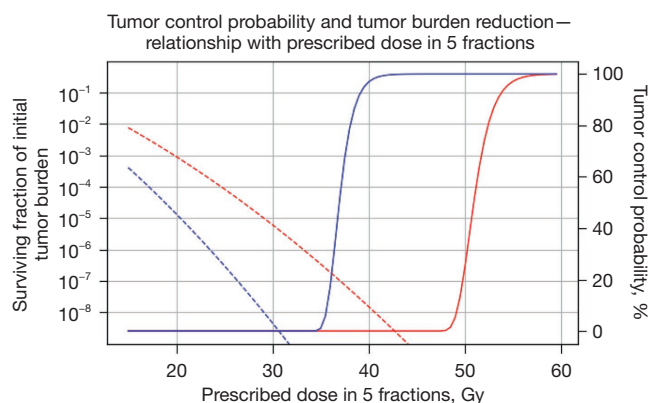
There are two underlying biological reasons for this strong synergy observed in our simulations, which do not include a mechanism of enhancing neo-antigen recognition as a result of RT tumor necrosis. On a first order, one can assume that for a given quanta of immune activation, a similar amount of appropriately activated effector T cells

were confronted with a significantly decreased tumor cell population, leading to higher response rates. A second order effect is that not only are there fewer tumor cells to eradicate, tumor-infiltrating T cells may also encounter a more accommodating immune microenvironment due to reduced tumor suppression—preclinical data support the notion that small tumors are less immunosuppressive compared to larger ones on both the systemic as well as the local level (6,12,13).

These inferences match the observation that in all of the randomized trials comparing ICI alone vs ICI/RT combinations, studies that irradiated only a small fraction of disease have invariably failed (14–17). This stands in contrast to the success of ICI/RT combination trials in which RT was delivered to the entire disease burden, such as PACIFIC in non-small lung cancer (18) or CheckMate-577 in esophageal or gastroesophageal junction cancer (19).

While this study demonstrated feasibility and preliminary signals of efficacy, there is significant toxicity associated when using SBRT in combination with dual-checkpoint inhibition. In particular, even in a population where 92% of the patients had Childs-Pugh A5 liver function, the authors observed 42.9% grade 3 hepatotoxicity in the dual-ICI arm compared to 16.7% for single-ICI treatment combined with SBRT. In comparison, the grade 3 hepatotoxicity rate for the nivolumab-ipilimumab combination arms in CheckMate-040 was approximately 20%. The study was also terminated early due to poor accrual, implicating a host of other undefined factors that may have influenced referral or perceived feasibility.

For external beam RT to find its appropriate role in the multi-modal treatment of advanced HCC, it may be appealing to apply it in a low-dose strategy in patients with large disease burden. This strategy requires a re-orientation with a focus on tumor burden reduction instead of local control. When applied to all sites of disease, radiation can lead to extensive tumor burden reduction, even at doses that are a fraction of those required for local control. *Figure 1* shows example calculations for a very radioresistant tumor, requiring  $\sim 60$  Gy in 5 fractions for local control, and a specimen of average radioresistance, for which  $\sim 40$  Gy would suffice. The dashed lines indicate the surviving fraction of tumor cells as a function of prescribed dose, indicating that even for a very radioresistant tumor,  $\sim 20$ – $30$  Gy in 5 fractions lowers the tumor burden to 0.01–0.0001% (*Figure 1*, red dotted line). Even accounting for repopulation during and in the weeks after radiation, the clonogenic population is not expected to expand more than



**Figure 1** Tumor control probability (full lines, right axis) and surviving fraction of initial tumor burden (dashed lines, left axis) for a very radioresistant patient (red) and one of average radioresistance (blue). Prescribed dose based on a 5-fraction regimen with varying per fraction dose, no re-population was assumed during the 5-fraction treatment.

an order of magnitude, i.e., ~3 volume doublings. For a tumor of average radioresistance (*Figure 1*, blue dotted line), the surviving fractions would even be two to three orders of magnitude lower.

As such, using a relatively low-dose RT regimen as induction therapy before ICIs has two advantages—it lowers the expected incidence of toxicity and it reduces radiation-induced lymphocyte depletion (20), which has been shown to correlate with response to ICIs (21,22). Induction low-dose RT has the potential to potentiate the ICI anti-tumor immune response by expanding effector T-cell repertoire while avoiding radiation mediated immune depletion. Longitudinal studies show that most patients, including non-responders, demonstrate a detectable effect of immune checkpoint blockade on T cells (5).

With this approach, it is crucial that RT can be safely delivered to the entire tumor burden—hitting a specific prescribed dose becomes less important. Giving a lesser dose to the entire tumor burden will always lead to a higher reduction in tumor cells than a higher dose to a fraction of visible disease. The focus away from local control makes sense particularly in a disease like advanced HCC, which we know is locally controllable, but may have a high risk of occult intrahepatic recurrence at the time of treatment.

In conclusion, this phase 1 study demonstrated the feasibility and encouraging long-term outcomes of SBRT and dual ICI treatment in advanced HCC. However, imbalance between disease burden and volume of disease

irradiated between the two treatment arms makes drawing definitive conclusions on efficacy challenging. Moving forward, key questions to address are how much disease to irradiate, and to what dose—the role of radiation in this context is unlikely to be black or white, but rather, in shades of Gray.

## Acknowledgments

*Funding:* None.

## Footnote

*Provenance and Peer Review:* This article was commissioned by the editorial office, *Translational Cancer Research*. The article did not undergo external peer review.

*Conflicts of Interest:* All authors have completed the ICMJE uniform disclosure form (available at <https://tcr.amegroups.com/article/view/10.21037/tcr-23-192/coif>). The authors have no conflicts of interest to declare.

*Ethical Statement:* The authors are accountable for all aspects of the work in ensuring that questions related to the accuracy or integrity of any part of the work are appropriately investigated and resolved.

*Open Access Statement:* This is an Open Access article distributed in accordance with the Creative Commons Attribution-NonCommercial-NoDerivs 4.0 International License (CC BY-NC-ND 4.0), which permits the non-commercial replication and distribution of the article with the strict proviso that no changes or edits are made and the original work is properly cited (including links to both the formal publication through the relevant DOI and the license). See: <https://creativecommons.org/licenses/by-nc-nd/4.0/>.

## References

1. Juloori A, Katipally RR, Lemons JM, et al. Phase 1 Randomized Trial of Stereotactic Body Radiation Therapy Followed by Nivolumab plus Ipilimumab or Nivolumab Alone in Advanced/Unresectable Hepatocellular Carcinoma. *Int J Radiat Oncol Biol Phys* 2023;115:202-13.
2. El-Khoueiry AB, Sangro B, Yau T, et al. Nivolumab in patients with advanced hepatocellular carcinoma (CheckMate 040): an open-label, non-comparative,

- phase 1/2 dose escalation and expansion trial. *Lancet* 2017;389:2492-502.
3. Mushti SL, Mulkey F, Sridhara R. Evaluation of Overall Response Rate and Progression-Free Survival as Potential Surrogate Endpoints for Overall Survival in Immunotherapy Trials. *Clin Cancer Res* 2018;24:2268-75.
  4. Kim N, Cheng J, Huang WY, et al. Dose-Response Relationship in Stereotactic Body Radiation Therapy for Hepatocellular Carcinoma: A Pooled Analysis of an Asian Liver Radiation Therapy Group Study. *Int J Radiat Oncol Biol Phys* 2021;109:464-73.
  5. Huang AC, Postow MA, Orlowski RJ, et al. T-cell invigoration to tumour burden ratio associated with anti-PD-1 response. *Nature* 2017;545:60-5.
  6. Guisier F, Cousse S, Jeanvoine M, et al. A rationale for surgical debulking to improve anti-PD1 therapy outcome in non small cell lung cancer. *Sci Rep* 2019;9:16902.
  7. Lee JHJ, Lyle M, Menzies AM, et al. Metastasis-specific patterns of response and progression with anti-PD-1 treatment in metastatic melanoma. *Pigment Cell Melanoma Res* 2018;31:404-10.
  8. Robert C, Ribas A, Hamid O, et al. Durable Complete Response After Discontinuation of Pembrolizumab in Patients With Metastatic Melanoma. *J Clin Oncol* 2018;36:1668-74.
  9. Joseph RW, Elassaiss-Schaap J, Kefford R, et al. Baseline Tumor Size Is an Independent Prognostic Factor for Overall Survival in Patients with Melanoma Treated with Pembrolizumab. *Clin Cancer Res* 2018;24:4960-7.
  10. A Phase II Trial of Durvalumab (MEDI4736) and Tremelimumab and Radiation Therapy in Hepatocellular Carcinoma and Biliary Tract Cancer. NCT03482102.
  11. Sung W, Hong TS, Poznanzsky MC, et al. Mathematical Modeling to Simulate the Effect of Adding Radiation Therapy to Immunotherapy and Application to Hepatocellular Carcinoma. *Int J Radiat Oncol Biol Phys* 2022;112:1055-62.
  12. Clark CE, Hingorani SR, Mick R, et al. Dynamics of the immune reaction to pancreatic cancer from inception to invasion. *Cancer Res* 2007;67:9518-27.
  13. Shabaneh TB, Molodtsov AK, Steinberg SM, et al. Oncogenic BRAFV600E Governs Regulatory T-cell Recruitment during Melanoma Tumorigenesis. *Cancer Res* 2018;78:5038-49.
  14. Theelen WSME, Peulen HMU, Lalezari F, et al. Effect of Pembrolizumab After Stereotactic Body Radiotherapy vs Pembrolizumab Alone on Tumor Response in Patients With Advanced Non-Small Cell Lung Cancer: Results of the PEMBRO-RT Phase 2 Randomized Clinical Trial. *JAMA Oncol* 2019;5:1276-82.
  15. Monjazebe AM, Giobbie-Hurder A, Lako A, et al. A Randomized Trial of Combined PD-L1 and CTLA-4 Inhibition with Targeted Low-Dose or Hypofractionated Radiation for Patients with Metastatic Colorectal Cancer. *Clin Cancer Res* 2021;27:2470-80.
  16. Schoenfeld JD, Giobbie-Hurder A, Ransinghe S, et al. Durvalumab plus tremelimumab alone or in combination with low-dose or hypofractionated radiotherapy in metastatic non-small-cell lung cancer refractory to previous PD(L)-1 therapy: an open-label, multicentre, randomised, phase 2 trial. *Lancet Oncol* 2022;23:279-91.
  17. McBride S, Sherman E, Tsai CJ, et al. Randomized Phase II Trial of Nivolumab With Stereotactic Body Radiotherapy Versus Nivolumab Alone in Metastatic Head and Neck Squamous Cell Carcinoma. *J Clin Oncol* 2021;39:30-7.
  18. Spigel DR, Faivre-Finn C, Gray JE, et al. Five-Year Survival Outcomes From the PACIFIC Trial: Durvalumab After Chemoradiotherapy in Stage III Non-Small-Cell Lung Cancer. *J Clin Oncol* 2022;40:1301-11.
  19. Kelly RJ, Ajani JA, Kuzdzal J, et al. Adjuvant Nivolumab in Resected Esophageal or Gastroesophageal Junction Cancer. *N Engl J Med* 2021;384:1191-203.
  20. De B, Ng SP, Liu AY, et al. Radiation-Associated Lymphopenia and Outcomes of Patients with Unresectable Hepatocellular Carcinoma Treated with Radiotherapy. *J Hepatocell Carcinoma* 2021;8:57-69.
  21. Diehl A, Yarchoan M, Hopkins A, et al. Relationships between lymphocyte counts and treatment-related toxicities and clinical responses in patients with solid tumors treated with PD-1 checkpoint inhibitors. *Oncotarget* 2017;8:114268-80.
  22. Pike LRG, Bang A, Mahal BA, et al. The Impact of Radiation Therapy on Lymphocyte Count and Survival in Metastatic Cancer Patients Receiving PD-1 Immune Checkpoint Inhibitors. *Int J Radiat Oncol Biol Phys* 2019;103:142-51.

**Cite this article as:** Grassberger C, King G, Apisarnthanarax S. Combining immunotherapy and radiotherapy in hepatocellular carcinoma: the importance of irradiated tumor burden and the possible role of a low dose radiotherapy induction strategy. *Transl Cancer Res* 2023;12(4):701-704. doi: 10.21037/tcr-23-192