



A case report of T-LGL leukemia-associated pure red cell aplasia harboring *STAT3*, *TNFAIP3*, and *KMT2D* mutation

Meixiao Shen

Department of Hematology, Affiliated Haikou Hospital of Xiangya Medical College, Central South University, Haikou, China

Correspondence to: Meixiao Shen. Department of Hematology, Affiliated Haikou Hospital of Xiangya Medical College, Central South University, Haikou 570208, China. Email: shenmeixiao1108@163.com.

Background: T-large granular lymphocyte (T-LGL) leukemia is a rare clonal lymphoproliferative disorder, which has a favorable prognosis. There are different complications between Asian and Western patients diagnosed with LGL leukemia. In Asians, pure red cell aplasia (PRCA) is the most common hematological compatible clinical feature of LGL leukemia, whereas in Western patients, rheumatoid arthritis and neutropenia are more commonly seen. Herein, a rare case of T-LGL leukemia associated PRCA was reported.

Case Description: A 72-year-old man, presenting with anemia and leukopenia, was admitted to hospital. The bone marrow (BM) smear revealed that erythroid series were suppressed with only 4%, mature lymphocytes constituting up to 23% of the marrow cells. The results of T-cell receptor (TCR) arrangement revealed mutations in the *TCR-β* and *TCR-γ* genes. Further, *STAT3* mutation (p. [D661Y; N664T] and p.N647I), *TNFAIP3* mutation (p.L48fs), and *KMT2D* mutation (p.E5291K) were confirmed. The patient was diagnosed with CD8+ *TCRαβ* T-LGL leukemia-associated PRCA, harboring *STAT3*, *TNFAIP3* and *KMT2D* mutation. The BM smear, immunophenotype, gene rearrangement and karyotype were consistent with those of the first diagnosis. Cyclosporine A (CyA) based regimens were effective, even in a cessation of discontinued treatment. The patient refused BM-related examinations and has remained in hematological complete remission (CR) until the time of writing (at least 3 years).

Conclusions: The administration of CyA yielded a CR in this case. However, the standard therapy for T-LGL leukemia-associated PRCA is not clear, and more prospective studies are needed to ascertain the underlying mechanism of pathogenesis.

Keywords: T-large granular lymphocyte leukemia; TCR arrangement; *STAT3* mutation; immunosuppressors; case report

Submitted Dec 05, 2022. Accepted for publication Mar 30, 2023. Published online Apr 10, 2023.

doi: 10.21037/tcr-23-326

View this article at: <https://dx.doi.org/10.21037/tcr-23-326>

Introduction

Large granular lymphocyte (LGL) leukemia is a rare clonal lymphoproliferative disorder, which involves expansion of cytotoxic T-lymphocytes or natural killer (NK) cells that configure T-LGL leukemia or NK-LGL leukemia [the chronic lymphoproliferative disease of NK cells in the 2016 revision of the World Health Organization (WHO) classification] (1-3). T-LGL leukemia and NK-LGL leukemia are the common indolent subtypes, whereas aggressive NK-cell leukemia has been rarely reported

and has a very poor prognosis (2). A definite diagnosis of T-LGL leukemia relies on (I) clinical presentations: neutropenia, anemia, lymphocytosis, splenomegaly, and other autoimmune conditions. (II) Cellular morphology and amounts: LGLs are large, about 15–18 μm in diameter, which have a round-to-reniform nucleus and a large cytoplasm and azurophilic granules. Chronic LGL peripheral blood expansion (mostly 2–20×10⁹/L), usually lasting for over 6 months. (III) Classical immunophenotype, mostly CD3+CD8+CD57+TCRαβ+, CD3+CD4+CD8-

CD57+ T-cell receptor (TCR) $\alpha\beta+$, and CD3+CD4-CD8-CD57+TCR $\gamma\delta+$. (IV) T-cell receptor (TCR) clonality is demonstrated by TCR rearrangement using polymerase chain reaction (PCR) or V β repertoire via flow cytometry (4-6). If clonality exists, the abnormal lymphocytic expansion may be not essential for a diagnosis of LGL leukemia. The number of LGL in peripheral blood can be at a low level when seen in combination with evidence of T-cell clonality and compatible clinical or hematological features such as autoimmune diseases or cytopenia (4). The prognosis is favorable, with a median overall survival (OS) greater than 10 years (7).

Pure red cell aplasia (PRCA) presents normocytic normochromic anemia, characterized by severe reduction or absence of erythroid precursors from the bone marrow (BM). PRCA can be classified into congenital PRCA, primary acquired PRCA, and secondary acquired PRCA (8). Acquired PRCA may present secondary to thymoma, autoimmune/collagen vascular disorders, lymphoproliferative disorders, infections, after exposure to various drugs or chemicals, or even pregnancy (9). There are different complications between Asian and Western patients diagnosed with LGL leukemia. In Asians, PRCA is the most common hematological compatible clinical feature of LGL leukemia, whereas in Western patients, rheumatoid arthritis and neutropenia are more commonly seen (10-12). These differences might be partly due to ethnicity (11). Therefore, it is intriguing to explore the possible pathophysiological

mechanisms, such as the genetic background. Herein, a rare case of T-LGL leukemia associated PRCA harboring Signal transducer and activator of transcription 3 (STAT3), TNF α -induced protein 3 (TNFAIP3), and KMT2D mutation was reported. Currently, STAT3 mutations are the most commonly mutations in T-LGL leukemia patients. The Src-like homology 2 (SH2) domain of STAT3 that plays a crucial role in STAT activation, leading the proliferation and extend survival of the leukemic T cells (13). TNFAIP3 mutation is another common gene mutation in T-LGL leukemia, which is a favorable factor for overall survival (14). The study about KMT2D mutation is scared and the meaning is not clear. We present the following article in accordance with the CARE reporting checklist (available at <https://tcr.amegroups.com/article/view/10.21037/tcr-23-326/rc>).

Case presentation

A 72-year-old man, who was accompanied by persistent fatigue, pallor, and dizziness for more than 6 months, was admitted into local hospital. After transfusion, the patient's anemia-related symptoms had improved. Half a year later, he was transferred to this hospital for further diagnosis and treatment because of severe anemia. He felt fatigued and dizzy, especially after activity. He had no joint pain, no fever, no night sweats, or weight loss, and returned negative results in stool occult-blood testing. Complete blood cell (CBC) revealed white blood cell (WBC) counts of $2.57 \times 10^9/L$, with 54.5% lymphocyte, hemoglobin (Hb) level of 28 g/L, mean corpus volume (MCV) of 120.3 fl, reticulocyte counts at $0.005 \times 10^{12}/L$, and platelets at $174 \times 10^9/L$. Ferritin was at 1,592 ng/mL. Physical examination did not reveal splenomegaly, hepatomegaly, or lymphadenopathy. The BM smear revealed that the proliferation of BM was obviously active, myeloid series were active, which constituted 68% of marrow cells, erythroid series were suppressed, at only 4%. Analysis of BM by flow cytometry showed an abnormal ratio of the mature T lymphocytes with 46.8%, the immunophenotype was CD3+, CD2- partly, CD5-, CD7- partly, CD8+, CD4-, TCRab+, TCRcd-, and CD4:CD8 = 0.07 (Figure 1). The results of TCR arrangement showed clonalities in the *TCR- β* and *TCR- γ* genes. The karyotype was 46 XY (15). *STAT3* mutations (p. [D661Y; N664T] and p.N647I), *TNFAIP3* mutation, and *KMT2D* mutation were identified by whole-exome sequencing (covering the genomic landscape of NK/T lymphoma relating 30 genes). Other identified gene mutations included *JAK3* and *KMT2A*

Highlight box

Key findings

- A case of a rare T-LGL leukemia-associated PRCA was reported, the characteristics of molecular genetics were described, and the possible mechanisms were also explained.

What is known and what is new?

- *STAT3* might lead to proliferation and anti-apoptosis of the leukemic T cells.
- T-LGL leukemia-associated PRCA is so rare that etiological studies are lacking. Constitutive activation of *STAT3* was probably the driver in T-LGL leukemia and *STAT3* mutation demonstrated worse prognosis. This case suggested that the presence of *TNFAIP3* and *KMT2D* mutations might alleviate the less favorable prognosis of *STAT3* mutation.

What is the implication, and what should change now?

- The standard therapy is not clear and more prospective studies are needed to find the underlying molecular mechanism of pathogenesis.

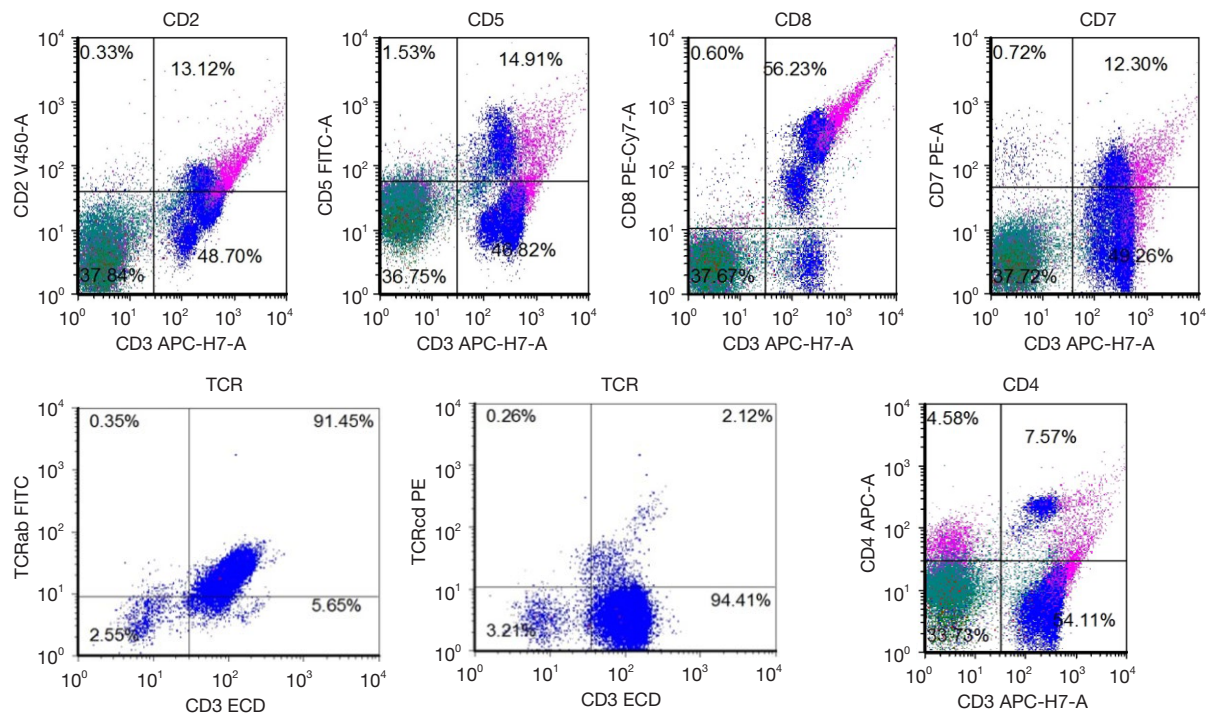


Figure 1 The results of bone marrow flow cytometry: CD3+, CD2- partly, CD5-, CD7- partly, CD8+, CD4-, TCRab+, TCRcd-, CD4:CD8 =0.07. TCR, T-cell receptor.

Table 1 The results of whole-exome sequencing (mature T/NK cell lymphoma pale)

Gene	Reference sequence accession number and sequence changes	The frequency of mutation
STAT3	NM_139276.2:c.[1981G>T;1991A>C],p.[D661Y;N664T]	2.7%
	NM_139276.2:c.[1940A>T(p.N647I)]	19.5%
TNFAIP3	NM_006290.3:c.143delinsGG(p.L48fs)	9.4%
JAK3	NM_000215.3:c.829G>A(p.G277S)	47.6%
KMT2A	NM_001197104.1:c.2263A>T(p.M755L)	1.6%
KMT2D	NM_003482.3:c.15871G>A(p.E5291K)	9%

NK, natural killer.

(Table 1). Mature lymphocytes constituted up to 23% of the marrow cells, some of which had azurophilic granules. Megakaryocytic series was normal. The immunophenotype of BM biopsy revealed that T cells occupied 30% of the nucleus cells (CD20+ minority, PAX5+ minority, CD2+ majority, CD3+, CD5+ major, CD7+ partly, CD4+ minority, CD8+ major, CD30-, CD56-). The patient's serum chemistry panel, vitamin B12, folic acid, coagulation test, tumor markers, and lactate dehydrogenase were measured in the normal range. Double-strain DNA and

anti-smith antibody were dim positive, whereas rheumatoid factor, anti-nuclear antibodies, thyroid function, B19 DNA, and Epstein-Barr virus (EBV) DNA were negative. A computed tomography (CT) scan of the chest did not indicate thymoma or lymphadenopathy. With the above typical clinical presentations and examination results, the patient was given a definite diagnosis of T-LGL leukemia, with secondary PRCA. After receiving the treatment of Cyclosporin A (CyA; 100 mg q12h po, the blood concentration was 159.2–176.8 ng/mL) and testosterone

undecanoic acid (80 mg bid po) for 3 months, the patient was identified as exhibiting hematological complete response (CR). The CBC revealed WBC at $4.68 \times 10^9/L$, with 44.4% lymphocyte, Hb level of 110 g/L, MCV at 110 fl, and platelets at $184 \times 10^9/L$. Then, the patient discontinued the treatment for several months, after which time severe anemia reappeared. The BM smear, immunophenotype, gene rearrangement, and karyotype were consistent with those of the first diagnosis. The hospital was out of stock of androgen, so CyA was administered alone, which was also effective. The patient then refused BM-related examinations and retained hematological CR until the time of this report, which was at least 3 years. All procedures performed in this study were in accordance with the ethical standards of the institutional and/or national research committee(s) and with the Declaration of Helsinki (as revised in 2013). Written informed consent was obtained from the patient for publication of this case report and accompanying images. A copy of the written consent is available for review by the editorial office of this journal.

Discussion

In this case, a diagnosis of T-LGL leukemia with PRCA was made according to the manifestations of anemia, neutropenia, morphology, flow cytometry, gene mutations, and TCR rearrangement of bone marrow. Differential diagnosis including B19 virus and thymoma-induced PRCA were excluded. The *TCR-β* and *TCR-γ* rearrangements were demonstrated by TCR gene clonality using PCR, which can distinguish reactive lymphocytic expansion and T-cell clonality. Janus kinase (JAK)-STAT pathway were detected and involved *STAT3* (p.[D661; N664T] and p.N647I) and *JAK3* (p.G277S). Additionally, *TNFAIP3* and *KMT2D* mutations were identified. Treatment with CyA, with or without testosterone, was effective in this case. After 3 months, the patient attained hematological CR. His disease relapsed following cessation of treatment, whereas resuming CyA therapy led to hematological CR.

In recent years, several reports have revealed that the presence of mutations in *STAT3*, which encodes a key signaling protein in the JAK-STAT pathway, might led to proliferation and anti-apoptosis of the leukemic T cells (16). *STAT3* mutations are reportedly also more frequently present in T-LGL leukemia-associated PRCA patients (77%), compared to idiopathic PRCA subtype patients (33%) (17). Chinese researchers have reported that the incidence of *STAT3* mutations and PRCA in T-LGL

leukemia patients was 21.4–72% and 20–75%, respectively (10,18,19). There were significant differences between *STAT3* mutations status and high beta2-microglobulin level, neutropenia, and PRCA. Compared to wild-type *STAT3*, *STAT3* mutations demonstrate a worse prognosis (18), lower hemoglobin (20), and greater tumor burden (15). Further, constitutive activation of *STAT3*, which is observed not only in *STAT3* mutated but also in *STAT3* wide-type T-LGL leukemia patients, are likely to be involved in proliferation and extend survival of the leukemic T cells (21). Based on the previous studies, constitutive activation of *STAT3* was probably the driver in T-LGL leukemia, and *STAT3* mutation contributed to the worse prognosis.

Due to the low morbidity of T-LGL leukemia, the etiology has not been thoroughly investigated. The JAK-STAT signaling pathway, the nuclear factor kappa β (NF- κ B) signaling pathway, and the FAS/FAS-L pathway have been implicated in the pathogenesis of LGL leukemia (22,23). A genomic landscape of T-LGL leukemia, which included 105 patients, revealed that *KMT2D* mutation (a chromatin and epigenetic modifying gene) co-occurring with *STAT3* (being observed in 10 out of 11 total *KMT2D* mutant patients), and *TNFAIP3* mutations should be considered a recurrently-mutated putative driver in LGL leukemia (20). *TNFAIP3* was detected in 4 cases within a cohort of 39 patients with T-LGL leukemia, 3 of which simultaneously harbored *TNFAIP3* and *STAT3* mutations (24). *TNFAIP3* mutation was thought to negatively regulate the activity of NF- κ B to inhibit tumor development, which might represent a favorable prognosis for patient with T-LGL leukemia (14). This case suggested that the presence of *TNFAIP3* and *KMT2D* mutations might alleviate the worse prognosis of *STAT3* mutation.

T-LGL leukemia is so rare that no standard therapy has been established due to few large prospective trials and the lack of accurate treatment targets. The most common therapeutic regimens are the immunosuppressors, monotherapy, or multitherapy comprising methotrexate, CyA, and cyclophosphamide, with response rate ranging from 61.5% to 74.4%, without evidence of cross-resistance among them (25). Some 86% of the patients with T-LGL leukemia should relapse at a median of 3 months if treatment is discontinued or dosages reduced, whereas only 11% of the patients diagnosed with T-LGL leukemia will relapse during CsA-containing maintenance therapy. Thus, there is a strong correlation between the discontinuance of maintenance therapy and relapse ($P < 0.001$) (26). Original regimen, other immunosuppressors, purine analogs,

anti-human T lymphocyte rabbit immunoglobulin, immunotherapy (alemtuzumab, rituximab) are also recommended as second-line therapy (16). Trials of targeted therapy against membrane receptors, JAK-STAT inhibitors, and NF- κ B are particularly promising (2). A prospective multi-center phase II study suggested that a mutated *STAT3* Y640F genotype might be a predictive biomarker of response to methotrexate, which requires further investigation (27). The clonality have replaced the number of T-LGL counts as one of important evidence in the diagnosis of T-LGL leukemia. With the development of molecular genetics, pathogenesis could be described further clearly and make great improvement in treatment of this rare disease.

Conclusions

Patients with T-LGL leukemia have an indolent clinical course and a relatively long OS. Causes of death commonly include granulocytopenia-induced severe infections and sepsis, rather than disease progression (12). The immunosuppressors have unsatisfying responses (28), thus the purpose of treatment is to correct cytopenia and reduce the proliferation of clonality, rather than eliminate the LGL clone. The standard therapy is not clear and more prospective studies are needed to find the underlying molecular mechanism of pathogenesis.

Acknowledgments

The author would like to thank all the investigators of the primary studies.

Funding: None.

Footnote

Reporting Checklist: The author has completed the CARE reporting checklist. Available at <https://tcr.amegroups.com/article/view/10.21037/tcr-23-326/tc>

Conflicts of Interest: The author has completed the ICMJE uniform disclosure form (available at <https://tcr.amegroups.com/article/view/10.21037/tcr-23-326/coif>). The author has no conflicts of interest to declare.

Ethical Statement: The author is accountable for all aspects of the work in ensuring that questions related to the accuracy or integrity of any part of the work are

appropriately investigated and resolved. All procedures performed in this study were in accordance with the ethical standards of the institutional and/or national research committee(s) and with the Declaration of Helsinki (as revised in 2013). Written informed consent was obtained from the patient for publication of this case report and accompanying images. A copy of the written consent is available for review by the editorial office of this journal.

Open Access Statement: This is an Open Access article distributed in accordance with the Creative Commons Attribution-NonCommercial-NoDerivs 4.0 International License (CC BY-NC-ND 4.0), which permits the non-commercial replication and distribution of the article with the strict proviso that no changes or edits are made and the original work is properly cited (including links to both the formal publication through the relevant DOI and the license). See: <https://creativecommons.org/licenses/by-nc-nd/4.0/>.

References

1. Alaggio R, Amador C, Anagnostopoulos I, et al. The 5th edition of the World Health Organization Classification of Haematolymphoid Tumours: Lymphoid Neoplasms. *Leukemia* 2022;36:1720-48.
2. Lamy T, Moignet A, Loughran TP Jr. LGL leukemia: from pathogenesis to treatment. *Blood* 2017;129:1082-94.
3. Swerdlow SH, Campo E, Pileri SA, et al. The 2016 revision of the World Health Organization classification of lymphoid neoplasms. *Blood* 2016;127:2375-90.
4. Semenzato G, Zambello R, Starkebaum G, et al. The lymphoproliferative disease of granular lymphocytes: updated criteria for diagnosis. *Blood* 1997;89:256-60.
5. Lamy T, Loughran TP Jr. How I treat LGL leukemia. *Blood* 2011;117:2764-74.
6. Steinway SN, LeBlanc F, Loughran TP Jr. The pathogenesis and treatment of large granular lymphocyte leukemia. *Blood Rev* 2014;28:87-94.
7. Dhodapkar MV, Li CY, Lust JA, et al. Clinical spectrum of clonal proliferations of T-large granular lymphocytes: a T-cell clonopathy of undetermined significance? *Blood* 1994;84:1620-7.
8. Means RT Jr. Pure red cell aplasia. *Blood* 2016;128:2504-9.
9. Hirokawa M. Progress in the clinical management of pure red cell aplasia and future prospects. *Rinsho Ketsueki* 2016;57:110-6.
10. Zhu Y, Gao Q, Hu J, et al. Clinical features and

- treatment outcomes in patients with T-cell large granular lymphocytic leukemia: A single-institution experience. *Leuk Res* 2020;90:106299.
11. Qiu ZY, Qin R, Tian GY, et al. Pathophysiologic Mechanisms And Management Of Large Granular Lymphocytic Leukemia Associated Pure Red Cell Aplasia. *Onco Targets Ther* 2019;12:8229-40.
 12. Bateau B, Rey J, Hamidou M, et al. Analysis of a French cohort of patients with large granular lymphocyte leukemia: a report on 229 cases. *Haematologica* 2010;95:1534-41.
 13. Koskela HL, Eldfors S, Ellonen P, et al. Somatic STAT3 mutations in large granular lymphocytic leukemia. *N Engl J Med* 2012;366:1905-13.
 14. Chen C, Chen Z, Huang L, et al. TNFAIP3 mutation may be associated with favorable overall survival for patients with T-cell lymphoma. *Cancer Cell Int* 2021;21:490.
 15. Shi M, He R, Feldman AL, et al. STAT3 mutation and its clinical and histopathologic correlation in T-cell large granular lymphocytic leukemia. *Hum Pathol* 2018;73:74-81.
 16. Matutes E. Large granular lymphocytic leukemia. Current diagnostic and therapeutic approaches and novel treatment options. *Expert Rev Hematol* 2017;10:251-8.
 17. Kawakami T, Sekiguchi N, Kobayashi J, et al. Frequent STAT3 mutations in CD8(+) T cells from patients with pure red cell aplasia. *Blood Adv* 2018;2:2704-12.
 18. Qiu ZY, Fan L, Wang L, et al. STAT3 mutations are frequent in T-cell large granular lymphocytic leukemia with pure red cell aplasia. *J Hematol Oncol* 2013;6:82.
 19. Qiu ZY, Fan L, Wang R, et al. Methotrexate therapy of T-cell large granular lymphocytic leukemia impact of STAT3 mutation. *Oncotarget* 2016;7:61419-25.
 20. Cheon H, Xing JC, Moosic KB, et al. Genomic landscape of TCR $\alpha\beta$ and TCR $\gamma\delta$ T-large granular lymphocyte leukemia. *Blood* 2022;139:3058-72.
 21. Jerez A, Clemente MJ, Makishima H, et al. STAT3 mutations unify the pathogenesis of chronic lymphoproliferative disorders of NK cells and T-cell large granular lymphocyte leukemia. *Blood* 2012;120:3048-57.
 22. Rahul E, Ningombam A, Acharya S, et al. Large granular lymphocytic leukemia: a brief review. *Am J Blood Res* 2022;12:17-32.
 23. Zawit M, Bahaj W, Gurnari C, et al. Large Granular Lymphocytic Leukemia: From Immunopathogenesis to Treatment of Refractory Disease. *Cancers (Basel)* 2021;13:4418.
 24. Johansson P, Bergmann A, Rahmann S, et al. Recurrent alterations of TNFAIP3 (A20) in T-cell large granular lymphocytic leukemia. *Int J Cancer* 2016;138:121-4.
 25. Dong N, Castillo Tokumori F, Isenalumhe L, et al. Large granular lymphocytic leukemia - A retrospective study of 319 cases. *Am J Hematol* 2021;96:772-80.
 26. Sawada K, Hirokawa M, Fujishima N, et al. Long-term outcome of patients with acquired primary idiopathic pure red cell aplasia receiving cyclosporine A. A nationwide cohort study in Japan for the PRCA Collaborative Study Group. *Haematologica* 2007;92:1021-8.
 27. Loughran TP Jr, Zickl L, Olson TL, et al. Immunosuppressive therapy of LGL leukemia: prospective multicenter phase II study by the Eastern Cooperative Oncology Group (E5998). *Leukemia* 2015;29:886-94.
 28. Moignet A, Lamy T. Latest Advances in the Diagnosis and Treatment of Large Granular Lymphocytic Leukemia. *Am Soc Clin Oncol Educ Book* 2018;38:616-25.

(English Language Editor: J. Jones)

Cite this article as: Shen M. A case report of T-LGL leukemia-associated pure red cell aplasia harboring STAT3, TNFAIP3, and KMT2D mutation. *Transl Cancer Res* 2023;12(4):1054-1059. doi: 10.21037/tcr-23-326