



Detection of thyroglobulin for diagnosis of metastatic lateral cervical lymph nodes in papillary thyroid carcinoma: accuracy and application in clinical practice

Baolin Chen^{1,2^}, Zhongliang Yan¹, Yuxiang Bao¹, Jiayang Li³, Chengmin Luo¹, Guangxu Yang⁴, Taolang Li¹, Xiaoming Cheng¹, Junyuan Lv^{1,5^}

¹Department of General Surgery, The Affiliated Hospital of Zunyi Medical University, Zunyi, China; ²Department of General Surgery, The People's Hospital of Fengcheng, Fengcheng, China; ³Office of Drug Clinical Trial Institution, The Affiliated Hospital of Zunyi Medical University, Zunyi, China; ⁴Department of Ultrasound, The Affiliated Hospital of Zunyi Medical University, Zunyi, China; ⁵Key Laboratory of Basic Pharmacology of Ministry of Education and Joint International Research Laboratory of Ethnomedicine of Ministry of Education, Zunyi Medical University, Zunyi, China

Contributions: (I) Conception and design: J Lv; (II) Administrative support: X Cheng; (III) Provision of study materials or patients: J Lv, T Li; (IV) Collection and assembly of data: B Chen, J Li, G Yang; (V) Data analysis and interpretation: Y Bao, C Luo, Z Yan; (VI) Manuscript writing: All authors; (VII) Final approval of manuscript: All authors.

Correspondence to: Junyuan Lv, MD, PhD. Department of General Surgery, The Affiliated Hospital of Zunyi Medical University, No. 149 Dalian Road, Huichuan District, Zunyi 563099, China; Key Laboratory of Basic Pharmacology of Ministry of Education and Joint International Research Laboratory of Ethnomedicine of Ministry of Education, Zunyi Medical University, No. 1 Xiaoyuan Road, Zunyi 563006, China. Email: junyuanlv@zmu.edu.cn.

Background: Accurate assessment of lateral cervical lymph node metastasis (LLNM) involvement is important for treating papillary thyroid carcinoma (PTC). Thyroglobulin is associated with LLNM, but there may be differences in the diagnostic value of serum thyroglobulin (sTg) and fine needle aspiration washout fluid thyroglobulin (FNA-Tg). Herein, we investigated the optimal cutoff value (OCV) of sTg and FNA-Tg and their diagnostic performance.

Methods: We enrolled 116 PTC patients who underwent radical resection of thyroid carcinoma with lateral cervical lymph node dissection at the Affiliated Hospital of Zunyi Medical University from June 2018 to July 2022. We used the receiver operating characteristic (ROC) curve analysis to determine the OCV for sTg and FNA-Tg to diagnose LLNM in PTC patients. We also evaluated the performance of FNA-Tg, sTg, fine needle aspiration cytology (FNAC), and their combinations for diagnosis. Pathological results were the gold standard.

Results: We performed 125 lymph node dissections, 106 had metastasis, and 19 did not. The OCV for sTg was 17.31 ng/mL [area under the curve (AUC) =0.760, sensitivity =78.30%, specificity =73.68%, and accuracy =77.60%]. Meanwhile, the OCV for FNA-Tg was 4.565 ng/mL (AUC =0.948, sensitivity =89.62%, specificity =100%, and accuracy =91.20%). The combination of FNAC and FNA-Tg presented the greatest diagnostic performance for LLNM detection in PTC patients. Moreover, serum antithyroglobulin antibody (TgAb) was not correlated with sTg or FNA-Tg levels.

Conclusions: The cutoff value for the diagnosis of LLNM in PTC are sTg >17.31 ng/mL or FNA-Tg >4.565 ng/mL. The combination method of FNA-Tg and FNAC is the most optimal choice for the diagnosis of LLNM and is highly recommended for further clinical application.

Keywords: Papillary thyroid carcinoma (PTC); lateral cervical lymph node metastasis (LLNM); fine needle aspiration; thyroglobulin (Tg)

[^] ORCID: Baolin Chen, 0000-0002-6086-0841; Junyuan Lv, 0000-0001-8467-6603.

Submitted Aug 16, 2023. Accepted for publication Dec 07, 2023. Published online February 02, 2024.

doi: 10.21037/tcr-23-1490

View this article at: <https://dx.doi.org/10.21037/tcr-23-1490>

Introduction

As a common pathological type of thyroid carcinoma (TC), papillary thyroid carcinoma (PTC) is the most frequently diagnosed TC (approximately 80–90%) (1). Despite the good prognosis and low mortality rate of PTC, 20–50% of PTC patients present cervical lymph node metastasis at the early stage, but the vast majority are central lymph node metastases (2). The incidence of lateral cervical lymph node metastasis (LLNM) is low; however, compared to PTC patients with central lymph node metastasis, those with LLNM exhibit higher local recurrence and lower survival time (3). Prophylactic lateral cervical lymph node dissection is not recommended for PTC patients (4). Hence, accurate preoperative evaluation of LLNM plays a decisive role in the extent of lymph node dissection in PTC patients, which helps select the appropriate surgical approach. Therefore, preoperative LLNM identification in PTC patients is crucial.

Ultrasound (US) is the most common auxiliary examination used for preoperative evaluation of lymph node status and has an important guiding value in clinical

diagnosis. However, US highly relies on the radiologists' experience and skill level (5). Fine needle aspiration cytology (FNAC) is widely used to evaluate lymph node metastasis in PTC patients, providing diagnostic cytology support for suspicious lymph nodes in the lateral cervical region. However, FNAC has some challenges due to small-diameter lymph nodes or cystic lesions (6). Thyroglobulin (Tg) is a thyroid follicular cell-secreted glycoprotein stored in the follicular lumen. Tg has tissue specificity and is highly expressed in metastatic lymph nodes, well-differentiated TCs, and normal thyroid tissues (7). Huang *et al.* (8) showed that PTC patients with preoperative serum Tg (sTg) ≤ 77 ng/mL might skip cervical lymph node metastases, and preoperative sTg levels might help predict LLNM. In 1992, Pacini *et al.* (9) first proposed that fine needle aspiration washout fluid thyroglobulin (FNA-Tg) improved the diagnosis rate of cervical lymph node metastasis (CLNM) in differentiated TC. Until now, no consensus on the diagnostic cutoff value for FNA-Tg is available, ranging from 0.2–100 ng/mL (10). Therefore, determining the optimal cutoff value (OCV) for FNA-Tg is important for LLNM diagnosis in PTC patients. Hence, in the present study, we determined the OCV for sTg and FNA-Tg to diagnose LLNM in PTC patients. We present this article in accordance with the STARD reporting checklist (available at <https://tcr.amegroups.com/article/view/10.21037/tcr-23-1490/rc>).

Methods

Patients

We retrospectively analyzed 116 PTC patients who underwent radical resection of thyroid carcinoma with lateral cervical lymph node dissection at the Affiliated Hospital of Zunyi Medical University from June 2018 to July 2022. Patients included 39 males with 42 lymph nodes and 77 females with 83 lymph nodes. The average age was 42.92 ± 12.01 years, ranging from 17 to 77 years. The study was conducted in accordance with the Declaration of Helsinki (as revised in 2013). The Research Ethics Committee of the Affiliated Hospital of Zunyi Medical University reviewed and approved this study (No. KLLY-

Highlight box

Key findings

- Fine needle aspiration washout fluid thyroglobulin (FNA-Tg) showed good diagnostic performance with a cutoff value of 4.565 ng/mL, representing an effective procedure for lateral cervical lymph node metastasis (LLNM) diagnosis in papillary thyroid carcinoma (PTC) patients preoperatively.
- FNA-Tg combined with fine needle aspiration cytology (FNAC) reduced the rate of missed diagnosis and improved the detection rate of suspicious LLNM in PTC patients.

What is known and what is new?

- FNA-Tg has improved the detection rate of LLNM in PTC patients, but there is still no consensus on the diagnostic cutoff value for FNA-Tg.
- The combination of FNA-Tg and FNAC has a better diagnostic performance in detecting LLNM of PTC.

What is the implication, and what should change now?

- As an effective procedure for the diagnosis of LLNM in PTC patients preoperatively, the combination of FNA-Tg and FNAC should be recommended for further use in clinics.

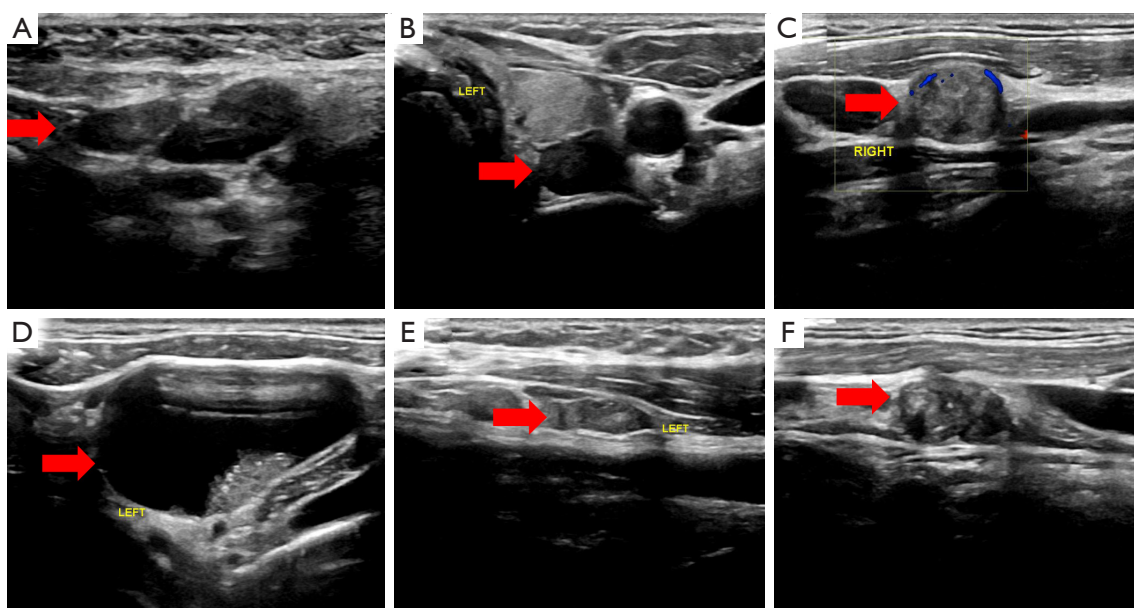


Figure 1 Ultrasonography is used to evaluate lateral cervical lymph nodes. The arrow refers to cervical lymph nodes. (A) Normal lymph nodes; (B) irregular shape; (C) $L/S \leq 1.5$; (D) cystic necrosis; (E) lymph hilar structure disappeared; (F) calcification. L/S, long diameter/short diameter.

2021-010). The requirement for patient informed consent was waived due to the retrospective nature of the study. The inclusion criteria were: patients diagnosed using a pathological method; complete clinicopathologic data; underwent lateral cervical dissection and first-time surgery. Meanwhile, we excluded patients with other tumors or who received chemotherapy or radiotherapy.

Measurement of sTg and antithyroglobulin antibody (TgAb)

After venous blood extraction (3–5 mL), we applied an automated electrochemiluminescence immunoassay to measure the blood samples for each patient. The value ranges of the sTg assay were the same as the FNA-Tg assay. A relative TgAb value >115 IU/mL was considered positive (normal, 0–115 IU/mL).

FNA-Tg and FNAC analysis

All enrolled patients signed the informed consent form before the puncture process. The US was conducted to evaluate the cervical lymph node status and mark suspicious lymph nodes on the body surface, which included irregular shape, calcification, long diameter/short diameter (L/S) ≤ 1.5 , cystic necrosis, and lymph hilar structure disappeared

(Figure 1) (11). After routine disinfection, we laid the drapes and performed local anesthesia (2% lidocaine, 2 mL). Under US guidance, we punctured the target lymph nodes using 22G needles. Needle retraction and insertion were performed several times forth and back in different needle channels. Punctuation was performed for each lymph node at least three times. Subsequently, the aspirated tissues were smeared and fixed on the slide for pathological examination after pulling out the puncture needle. After fine needle aspiration tissue acquisition, we flushed each needle with 2 mL of 0.9% normal saline and prepared washout fluid. The automated electrochemiluminescence immunoassay was used to detect Tg level with a range of 0.04–500 ng/mL.

Statistical analysis

Statistical analyses were performed using Statistical Package for Social Science (SPSS) software (v. 18.0). The χ^2 and Fisher's exact tests were used to compare groups. Using the pathological results as the gold standard, we conducted the receiver operating characteristic (ROC) curve analysis and calculated the area under the curve (AUC) to determine the OCV of FNA-Tg, sTg, and FNAC. Diagnostic performance was evaluated using the AUC, accuracy, negative predictive value (NPV), positive predictive value

Table 1 Clinical characteristics of the 125 lymph nodes

Characteristics	Pathology results		P value
	Metastatic	Nonmetastatic	
Sex			0.128
Male	39	3	
Female	67	16	
Age (years)			0.755
≥55	16	4	
<55	90	15	
Tumor size (cm)			<0.001
≥1.0	90	9	
<1.0	16	10	
Multifocality			0.037
Yes	61	6	
No	45	13	
FNAC			<0.001
Positive	71	0	
Negative	35	19	
Ultrasound feature of lymph nodes			
Calcification			0.29
Yes	39	4	
No	67	15	
Irregular shape			0.960
Yes	13	3	
No	93	16	
L/S ≤1.5			0.187
Yes	82	12	
No	24	7	
Cystic necrosis			0.041
Yes	20	0	
No	86	19	
Lymph hilar structure disappeared			1.00
Yes	93	17	
No	13	2	

FNAC, fine needle aspiration cytology; L/S, long diameter/short diameter.

(PPV), specificity, and sensitivity. Results were calculated with 95% confidence intervals. A $P < 0.05$ was set as the significant difference.

Results

Clinical and cytopathological characteristics

We collected 125 lymph nodes, 106 were diagnosed as metastatic and 19 as nonmetastatic by postoperative pathology; their clinical characteristics are shown in *Table 1*. Positive LLNM groups presented significantly higher sTg and FNA-Tg levels than LLNM negative groups ($P = 0.016$, $P < 0.001$, *Figure 2A, 2B*). However, the serum TgAb level did not differ between the two groups ($P = 0.891$, *Figure 2C*).

Cutoff values of sTg for LLNM diagnosis

Furthermore, we constructed a ROC curve for sTg based on the pathological results and obtained an OCV of 17.31 ng/mL (*Figure 3*). Then, the sTg cutoff value revealed that among the 83 lymph nodes metastasized, 23 had missed diagnoses, representing a diagnostic accuracy of 77.60% (*Table S1*).

Cutoff value of FNA-Tg for LLNM diagnosis

Regarding the FNA-Tg cutoff value, no uniform standard is currently available, but it mainly comprises three types: (I) FNA-Tg > 1.00 ng/mL (12); (II) FNA-Tg/sTg > 1 (13); (III) using ROC curves, we can calculate the OCV of FNA-Tg to diagnose LLNM in PTC patients (*Figure 4*). When the FNA-Tg cutoff value was set as 4.565 ng/mL, the AUC was 0.948, the Youden index was 0.896, the sensitivity was 89.62%, and the specificity was 100%. Meanwhile, using a 1.00 ng/mL cutoff, the sensitivity, specificity, and AUC were 93.40%, 84.21%, and 0.888, respectively. At an FNA-Tg/sTg cutoff value > 1 , the sensitivity, specificity, and AUC values were 72.64%, 94.74%, and 0.837, respectively (*Table 2*). Therefore, FNA-Tg showed the best diagnostic performance when the cutoff value was 4.565 ng/mL (*Table S2*).

Diagnostic performance of different procedures

Herein, we included 125 suspicious lymph nodes. Using pathological results, we constructed ROC curves for FNA-Tg + FNAC + sTg, FNA-Tg + sTg, FNA-Tg + FNAC, FNA-Tg, FNAC, and sTg (*Figure 5*). The combination of FNA-Tg and FNAC presented the best performance. The accuracy, sensitivity, and AUC value of combined FNA-Tg and FNAC were significantly higher than FNA-Tg, FNAC, and sTg. Additionally, compared to the FNA-Tg + FNAC + sTg and FNA-Tg + sTg, the combination of FNA-Tg and FNAC showed a significantly higher AUC value (*Table 3*).

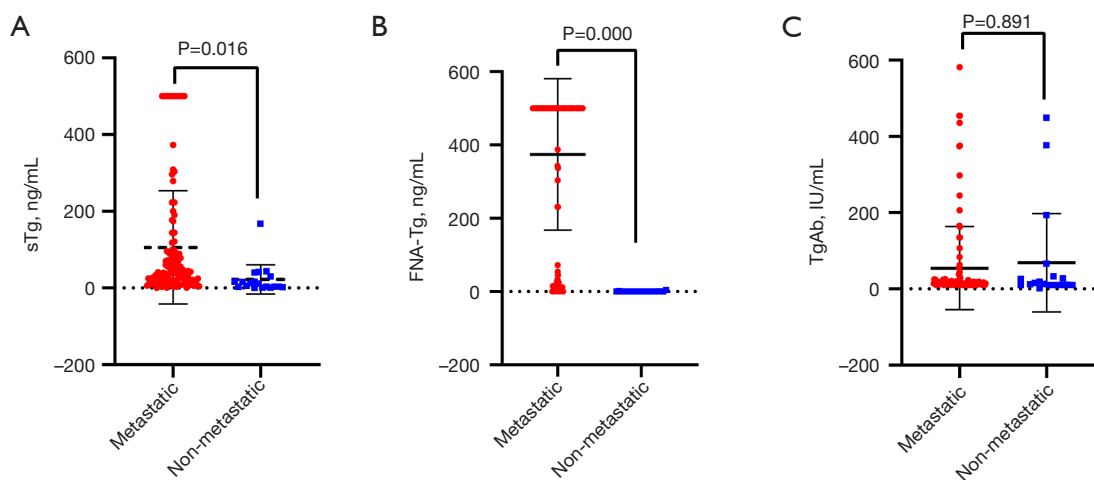


Figure 2 Preoperative indexes in metastatic and nonmetastatic LLNM: (A) sTg; (B) FNA-Tg; (C) TgAb. LLNM, lateral cervical lymph node metastasis; sTg, serum thyroglobulin; FNA-Tg, fine needle aspiration washout fluid thyroglobulin; TgAb, antithyroglobulin antibody.

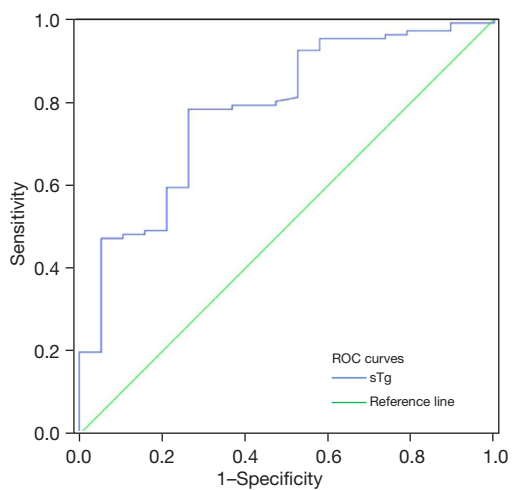


Figure 3 ROC curve of sTg in PTC patients. ROC, the receiver operating characteristic; sTg, serum thyroglobulin; PTC, papillary thyroid carcinoma.

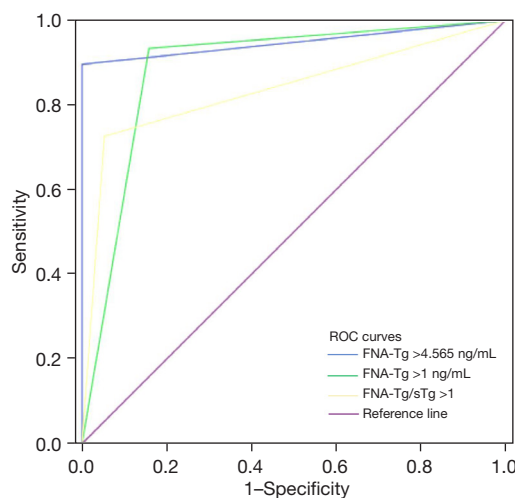


Figure 4 FNA-Tg ROC curve with different cutoff values. FNA-Tg, fine needle aspiration washout fluid thyroglobulin; ROC, the receiver operating characteristic; sTg, serum thyroglobulin.

Table 2 FNA-Tg diagnostic performance with different cutoff values

Diagnostic procedures	AUC (95% CI)	PPV (%)	NPV (%)	Sensitivity (%)	Specificity (%)	Accuracy (%)
FNA-Tg >1.00 ng/mL	0.888 (0.788–0.988)	97.06	69.57	93.40	84.21	92.00
FNA-Tg/sTg >1	0.837 (0.754–0.919)	98.72	38.30	72.64	94.74	76.00
FNA-Tg >4.565 ng/mL	0.948 (0.911–0.985)	100	63.33	89.62	100	91.20

FNA-Tg, fine needle aspiration washout fluid thyroglobulin; AUC, area under the curve; CI, confidence interval; PPV, positive predictive value; NPV, negative predictive value; sTg, serum thyroglobulin.

Subgroup analysis

To analysis FNA-Tg-related factors of LLNM in PTC patients, we evaluated the correlation between sTg and TgAb levels. the Pearson correlation analysis indicated sTg and TgAb levels were not correlated ($r=-0.145$, $P=0.106$, *Figure 6A*). Similarly, we explored the connection between FNA-Tg and TgAb, the results indicated no significant correlation between these two factors ($r=-0.06$, $P=0.948$, *Figure 6B*).

Discussion

The incidence of TC has increased (20%) yearly, becoming

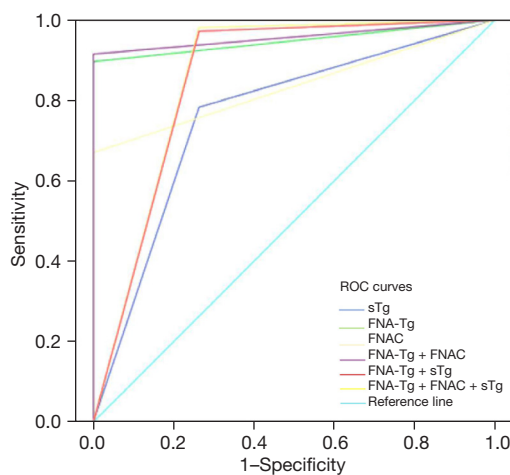


Figure 5 ROC curve of LLNM in PTC diagnosed by different procedures. ROC, the receiver operating characteristic; sTg, serum thyroglobulin; FNA-Tg, fine needle aspiration washout fluid thyroglobulin; FNAC, fine needle aspiration cytology; LLNM, lateral cervical lymph node metastasis; PTC, papillary thyroid carcinoma.

one of the most common malignant tumors in women in China (14). As a frequently diagnosed TC type, the 10-year overall survival rate of PTC is 97% (15). Lymph node metastasis is an independent survival risk factor, and approximately 20% of PTC patients present LLNM (16). However, PTC patients with LLNM commonly have a poor prognosis, with 10-year overall survival rates of 81% (17). Previous studies showed that the occurrence of LLNM in PTC patients is closely related to its clinical characteristics (18-20). We found that tumor size, multifocality, and cystic necrosis of lymph nodes were associated with lymph node metastasis in PTC patients. They may serve as an important predictor of lymph node metastasis for PTC patients.

As a popular procedure, FNAC can diagnose PTC preoperatively and evaluate cervical lymph nodes. The sensitivity of FNAC can decrease from 80.6% to 70.9%, influenced by lymph node size, puncture technique, and cystic changes (21). On the other hand, FNAC often leads to false negatives in 6% to 8% of cases and inconclusive results in 20% to 28.5% (22). Herein, the sensitivity of FNAC was 66.98%, the specificity was 100%, and 35 metastatic lymph nodes were missed. FNAC is regarded as the gold standard to diagnose lymph node metastasis preoperatively in PTC patients, but it generates false negatives. Thus, we hypothesized that the missed diagnosis case might be caused by insufficient puncture sample size and excessive red blood cells obscuring the visual field. Hence, exploring a procedure with higher diagnostic performance to improve the diagnostic rate of metastatic lymph nodes is essential.

When normal thyroid tissue becomes cancerous, the follicular lumen might be disrupted, releasing a small quantity of Tg into the blood. Preoperative sTg >188.5 ng/mL can be used as an effective tumor marker of differentiated TC (23). Meanwhile, Kim *et al.* (24) reported that

Table 3 Diagnostic performance of different procedures

Diagnostic procedures	AUC (95% CI)	PPV (%)	NPV (%)	Sensitivity (%)	Specificity (%)	Accuracy (%)
sTg	0.760 (0.636–0.884)	94.32	37.84	78.30	73.68	77.60
FNA-Tg	0.948 (0.911–0.985)	100	63.33	89.62	100	91.20
FNAC	0.835 (0.765–0.905)	100	35.19	66.98	100	72.00
FNA-Tg + FNAC	0.958 (0.924–0.991)	100	67.86	91.51	100	92.80
FNA-Tg + sTg	0.854 (0.734–0.975)	95.37	82.35	97.17	73.68	93.60
FNA-Tg + FNAC + sTg	0.859 (0.738–0.980)	95.41	87.50	98.11	73.68	94.40

AUC, area under the curve; CI, confidence interval; PPV, positive predictive value; NPV, negative predictive value; sTg, serum thyroglobulin; FNA-Tg, fine needle aspiration washout fluid thyroglobulin; FNAC, fine needle aspiration cytology.

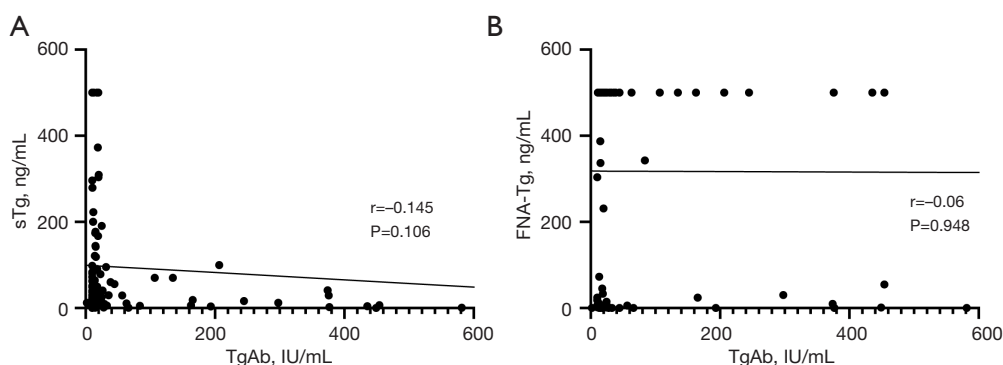


Figure 6 Scatter plots based on Pearson correlation analysis: (A) sTg levels and TgAb; (B) FNA-Tg levels and TgAb. sTg, serum thyroglobulin; TgAb, antithyroglobulin antibody; FNA-Tg, fine needle aspiration washout fluid thyroglobulin.

preoperative sTg levels were positively correlated with the number of lymph node metastasis in differentiated TC patients. In the present study, we confirmed that patients with lymph node metastasis showed increased preoperative sTg compared to those without. Preoperative sTg levels ≥ 17.31 ng/mL exhibited 78.30% sensitivity and 73.68% specificity, indicating a certain diagnostic value for LLNM detection in PTC patients. However, it presented lower sensitivity, with missed diagnoses of 23 lymph nodes and 5 misdiagnoses.

FNA-Tg is an additional examination procedure on FNAC, which is rarely affected by subjective factors. Due to the high concentration of Tg in metastatic lymph nodes, FNA-Tg can directly indicate the presence of metastasis. Jia *et al.* (25) reported that FNA-Tg has a high diagnostic value for PTC patients with LLNM, with a sensitivity of 96.25% and a specificity of 96.36%. Meanwhile, due to differences in sample size, Tg assay methods, and Tg assay kits, the OCV of FNA-Tg remained undetermined (22). Sigstad *et al.* (13) reported that an FNA-T/sTg ratio >1 had the highest sensitivity (100%) with 83.3% specificity. In contrast, Song *et al.* (12) documented that the OCV of FNA-Tg for LLNM diagnosis in PTC patients was 1.0 ng/mL. Here, FNA-Tg levels ≥ 4.565 ng/mL had the best diagnostic performance. Hence, the cutoff value calculated by the ROC curve is the optimal criterion for establishing FNA-Tg positivity compared to FNA-Tg/sTg >1 and FNA-Tg >1.00 ng/mL.

In the present study, FNA-Tg had the best diagnostic performance but presented 11 false negatives. Thus, some factors might also interfere with FNA-Tg results. Previous studies have reported that serum TgAb can influence the FNA-Tg level, with lower FNA-Tg levels in TgAb-positive patients than in TgAb-negative (26). However, consistent

with Wang *et al.* (27), TgAb and FNA-Tg levels were not correlated in our study. Possibly, there was an excessive binding of Tg to TgAb sites in patients with high FNA-Tg levels, eliminating the effect of TgAb (28). Baskin (29) suggested that due to no exposure of the intracellular Tg to circulating TgAb, TgAb cannot affect FNA-Tg levels.

The use of a combination of methods is useful in improving the diagnosis of LLNM in thyroid cancer (30). We demonstrated that the sensitivity of FNAC combined with FNA-Tg increased from 66.98% to 91.51% and greatly reduced the false negative rate. Al-Hilli *et al.* (31) reported that combining FNA-Tg and FNAC significantly increased the detection rate of metastatic lymph nodes in PTC patients by 13%. However, FNA-Tg combined with sTg was not optimal for detecting LLNM in PTC patients. Compared to the combination of FNA-Tg with FNAC, the combination of sTg, FNAC, and FNA-Tg showed significantly lower diagnostic performance. Thus, combining FNAC with FNA-Tg was the best option for diagnosing LLNM in PTC patients.

Conclusions

In conclusion, FNA-Tg showed good diagnostic performance with a cutoff value of 4.565 ng/mL, representing an effective procedure for LLNM diagnosis in PTC patients preoperatively. Also, FNA-Tg combined with FNAC reduced the rate of missed diagnosis and improved the detection rate of suspicious LLNM in PTC patients.

Acknowledgments

Funding: This study was supported by Doctor Foundation of the Affiliated Hospital of Zunyi Medical University

(No. 201712), the Science and Technology Foundation of Guizhou Province (No. LC[2022]019) and the Science and Technology Foundation Project of Guizhou Provincial Health and Wellness Commission (No. gzwkj2022-189).

Footnote

Reporting Checklist: The authors have completed the STARD reporting checklist. Available at <https://tcr.amegroups.com/article/view/10.21037/tcr-23-1490/rc>

Data Sharing Statement: Available at <https://tcr.amegroups.com/article/view/10.21037/tcr-23-1490/dss>

Peer Review File: Available at <https://tcr.amegroups.com/article/view/10.21037/tcr-23-1490/prf>

Conflicts of Interest: All authors have completed the ICMJE uniform disclosure form (available at <https://tcr.amegroups.com/article/view/10.21037/tcr-23-1490/coif>). The authors have no conflicts of interest to declare.

Ethical Statement: The authors are accountable for all aspects of the work in ensuring that questions related to the accuracy or integrity of any part of the work are appropriately investigated and resolved. The study was conducted in accordance with the Declaration of Helsinki (as revised in 2013). The study was approved by the Research Ethics Committee of the Affiliated Hospital of Zunyi Medical University (No. KLLY-2021-010). The requirement for patient informed consent was waived due to the retrospective nature of the study.

Open Access Statement: This is an Open Access article distributed in accordance with the Creative Commons Attribution-NonCommercial-NoDerivs 4.0 International License (CC BY-NC-ND 4.0), which permits the non-commercial replication and distribution of the article with the strict proviso that no changes or edits are made and the original work is properly cited (including links to both the formal publication through the relevant DOI and the license). See: <https://creativecommons.org/licenses/by-nc-nd/4.0/>.

References

- Mao Y, Xing M. Recent incidences and differential trends of thyroid cancer in the USA. *Endocr Relat Cancer* 2016;23:313-22.
- Kim YS, Park WC. Clinical predictors of right upper paraesophageal lymph node metastasis from papillary thyroid carcinoma. *World J Surg Oncol* 2012;10:164.
- de Meer SG, Dauwan M, de Keizer B, et al. Not the number but the location of lymph nodes matters for recurrence rate and disease-free survival in patients with differentiated thyroid cancer. *World J Surg* 2012;36:1262-7.
- Haugen BR, Alexander EK, Bible KC, et al. 2015 American Thyroid Association Management Guidelines for Adult Patients with Thyroid Nodules and Differentiated Thyroid Cancer: The American Thyroid Association Guidelines Task Force on Thyroid Nodules and Differentiated Thyroid Cancer. *Thyroid* 2016;26:1-133.
- Colakoglu B, Alis D, Seymen H. Diagnostic Accuracy of Ultrasound for the Evaluation of Lateral Compartment Lymph Nodes in Papillary Thyroid Carcinoma. *Curr Med Imaging* 2020;16:459-65.
- Zhong LC, Lu F, Ma F, et al. Ultrasound-guided fine-needle aspiration of thyroid nodules: does the size limit its efficiency? *Int J Clin Exp Pathol* 2015;8:3155-9.
- Ritter A, Mizrachi A, Bachar G, et al. Detecting Recurrence Following Lobectomy for Thyroid Cancer: Role of Thyroglobulin and Thyroglobulin Antibodies. *J Clin Endocrinol Metab* 2020;105:dga152.
- Huang Z, Song M, Wang S, et al. Preoperative serum thyroglobulin is a risk factor of skip metastasis in papillary thyroid carcinoma. *Ann Transl Med* 2020;8:389.
- Pacini F, Fugazzola L, Lippi F, et al. Detection of thyroglobulin in fine needle aspirates of nonthyroidal neck masses: a clue to the diagnosis of metastatic differentiated thyroid cancer. *J Clin Endocrinol Metab* 1992;74:1401-4.
- Sohn YM, Kim MJ, Kim EK, et al. Diagnostic performance of thyroglobulin value in indeterminate range in fine needle aspiration washout fluid from lymph nodes of thyroid cancer. *Yonsei Med J* 2012;53:126-31.
- Li F, Pan D, He Y, et al. Using ultrasound features and radiomics analysis to predict lymph node metastasis in patients with thyroid cancer. *BMC Surg* 2020;20:315.
- Song Y, Xu G, Wang T, et al. Lateral neck multilevel fine-needle aspiration cytology and thyroglobulin estimation in papillary thyroid carcinoma. *Laryngoscope Investig Otolaryngol* 2021;6:570-5.
- Sigstad E, Heilo A, Paus E, et al. The usefulness of detecting thyroglobulin in fine-needle aspirates from patients with neck lesions using a sensitive thyroglobulin assay. *Diagn Cytopathol* 2007;35:761-7.
- Zheng R, Zhang S, Zeng H, et al. Cancer incidence and

- mortality in China, 2016. *J Natl Cancer Cent* 2022;2:1-9.
15. Ito Y, Miyauchi A, Kihara M, et al. Overall Survival of Papillary Thyroid Carcinoma Patients: A Single-Institution Long-Term Follow-Up of 5897 Patients. *World J Surg* 2018;42:615-22.
 16. So YK, Kim MJ, Kim S, et al. Lateral lymph node metastasis in papillary thyroid carcinoma: A systematic review and meta-analysis for prevalence, risk factors, and location. *Int J Surg* 2018;50:94-103.
 17. Lombardi D, Paderno A, Giordano D, et al. Therapeutic lateral neck dissection in well-differentiated thyroid cancer: Analysis on factors predicting distribution of positive nodes and prognosis. *Head Neck* 2018;40:242-50.
 18. Feng JW, Wu WX, Qi GF, et al. Nomograms based on sonographic and clinicopathological characteristics to predict lateral lymph node metastasis in classic papillary thyroid carcinoma. *J Endocrinol Invest* 2022;45:2043-57.
 19. Liu Q, Pang WT, Dong YB, et al. Analysis of risk factors for lateral lymph node metastasis in papillary thyroid carcinoma: A retrospective cohort study. *World J Otorhinolaryngol Head Neck Surg* 2022;8:274-8.
 20. Liu WQ, Yang JY, Wang XH, et al. Analysis of factors influencing cervical lymph node metastasis of papillary thyroid carcinoma at each lateral level. *BMC Surg* 2022;22:228.
 21. Chung SR, Baek JH, Choi YJ, et al. Diagnostic Algorithm for Metastatic Lymph Nodes of Differentiated Thyroid Carcinoma. *Cancers (Basel)* 2021;13:1338.
 22. Wang Y, Duan Y, Zhou M, et al. The diagnostic value of thyroglobulin in fine-needle aspiration of metastatic lymph nodes in patients with papillary thyroid cancer and its influential factors. *Surg Oncol* 2021;39:101666.
 23. Kars A, Aktan B, Kilic K, et al. Preoperative Serum Thyroglobulin Level as a Useful Predictive Marker to Differentiate Thyroid Cancer. *ORL J Otorhinolaryngol Relat Spec* 2018;80:290-5.
 24. Kim H, Park SY, Choe JH, et al. Preoperative Serum Thyroglobulin and Its Correlation with the Burden and Extent of Differentiated Thyroid Cancer. *Cancers (Basel)* 2020;12:625.
 25. Jia X, Wang Y, Liu Y, et al. Thyroglobulin Measurement Through Fine-Needle Aspiration for Optimizing Neck Node Dissection in Papillary Thyroid Cancer. *Ann Surg Oncol* 2022;29:88-96.
 26. Jo K, Kim MH, Lim Y, et al. Lowered cutoff of lymph node fine-needle aspiration thyroglobulin in thyroid cancer patients with serum anti-thyroglobulin antibody. *Eur J Endocrinol* 2015;173:489-97.
 27. Wang J, Jiang X, Xiao G, et al. Excellent diagnostic performance of FNA-Tg in detecting lymph nodes metastases from papillary thyroid cancer. *Future Oncol* 2020;16:2735-46.
 28. Boi F, Baghino G, Atzeni F, et al. The diagnostic value for differentiated thyroid carcinoma metastases of thyroglobulin (Tg) measurement in washout fluid from fine-needle aspiration biopsy of neck lymph nodes is maintained in the presence of circulating anti-Tg antibodies. *J Clin Endocrinol Metab* 2006;91:1364-9.
 29. Baskin HJ. Detection of recurrent papillary thyroid carcinoma by thyroglobulin assessment in the needle washout after fine-needle aspiration of suspicious lymph nodes. *Thyroid* 2004;14:959-63.
 30. Sun J, Li P, Chen X, et al. The influence of thyroid status, serum Tg, TSH, and TgAb on FNA-Tg in cervical metastatic lymph nodes of papillary thyroid carcinoma. *Laryngoscope Investig Otolaryngol* 2021;7:274-82.
 31. Al-Hilli Z, Strajina V, McKenzie TJ, et al. Thyroglobulin Measurement in Fine-Needle Aspiration Improves the Diagnosis of Cervical Lymph Node Metastases in Papillary Thyroid Carcinoma. *Ann Surg Oncol* 2017;24:739-44.

Cite this article as: Chen B, Yan Z, Bao Y, Li J, Luo C, Yang G, Li T, Cheng X, Lv J. Detection of thyroglobulin for diagnosis of metastatic lateral cervical lymph nodes in papillary thyroid carcinoma: accuracy and application in clinical practice. *Transl Cancer Res* 2024;13(2):1043-1051. doi: 10.21037/tcr-23-1490

Supplementary

Table S1 Diagnosis results of sTg in PTC with LLNM

Diagnostic procedures	Outcome	Pathology results		Total
		Metastatic	Nonmetastatic	
sTg >17.31 ng/mL	Positive	83	5	88
	Negative	23	14	37
	Total	106	19	125

sTg, serum thyroglobulin; PTC, papillary thyroid carcinoma; LLNM, lateral cervical lymph node metastasis.

Table S2 FNA-Tg results with different cutoff value

Diagnostic procedures	Outcome	Pathology results		Total
		Metastatic	Nonmetastatic	
FNA-Tg >1.00 ng/mL	Positive	99	3	102
	Negative	7	16	23
	Total	106	19	125
FNA-Tg/sTg >1	Positive	77	1	78
	Negative	29	18	47
	Total	106	19	125
FNA-Tg >4.565 ng/mL	Positive	95	0	95
	Negative	11	19	30
	Total	106	19	125

FNA-Tg, fine needle aspiration washout fluid thyroglobulin; sTg, serum thyroglobulin.