



# Occurrence and distribution of bone metastases in 984 metastatic breast cancer patients

Huangchengyu Nie<sup>1,2</sup>, Yang Yuan<sup>1</sup>, Jianbin Li<sup>1,3</sup>, Fengrui Xu<sup>1,4</sup>, Tao Wang<sup>1</sup>, Li Bian<sup>1</sup>, Zefei Jiang<sup>1</sup>, Shaohua Zhang<sup>1</sup>

<sup>1</sup>Department of Breast Oncology, The Fifth Medical Center of Chinese PLA General Hospital, Beijing, China; <sup>2</sup>Department of Breast Oncology, PLA 307 Clinical College of Anhui Medical University, Beijing, China; <sup>3</sup>Department of Medical Molecular Biology, Beijing Institute of Biotechnology, Academy of Military Medical Sciences, Beijing, China; <sup>4</sup>Department of Breast Oncology, Academy of Military Medical Sciences, Beijing, China

**Contributions:** (I) Conception and design: Z Jiang; (II) Administrative support: Z Jiang; (III) Provision of study materials or patients: All authors; (IV) Collection and assembly of data: H Nie; (V) Data analysis and interpretation: Z Jiang, H Nie, J Li; (VI) Manuscript writing: All authors; (VII) Final approval of manuscript: All authors.

**Correspondence to:** Shaohua Zhang, Department of Breast Oncology, The Fifth Medical Center of Chinese PLA General Hospital, No. 8 Dong Street, Fengtai District, Beijing 100071, China. Email: zhangsh19760428@163.com.

**Background:** An analysis of occurrence and distribution of bone metastases in metastatic breast cancer patients.

**Methods:** This is a retrospective study of 984 metastatic breast cancer patients with bone metastases who were enrolled in our study from January 1, 2010 to December 31, 2019. The main observation indicators were the time of occurrence and the distribution of bone metastases.

**Results:** Computed tomography (CT) was the most common diagnostic method. The main molecular subtype of breast cancer patients with bone metastases was hormone-receptor positive, accounting for 87.2% (858/984) of the study group. Meanwhile, 72.2% (710/984) of the patients were diagnosed with bone metastases within 5 years after the initial diagnosis of breast cancer, and the proportion of patients with bone metastasis found in the 2 to 5 years was the highest. Most bone metastases of breast cancer were multiple osteolytic lesions, the distribution was regular, and axial bones such as chest bones and spine bones were more common than other bones. The most common metastatic site was the ribs (13.4%), followed by the thoracic vertebrae (12.4%), pelvis (12.2%), lumbar vertebrae (12.1%), and sternum (10.5%). Examination of treatment methods revealed that chemotherapy was the most common systemic comprehensive approach, accounting for 89.6% (883/984) of cases, while bone-modifying agents were the most commonly used local treatment for bone metastases, accounting for 86.5% (851/984) of cases.

**Conclusions:** Breast cancer bone metastases have certain clinical features, and understanding the occurrence time and distribution of bone metastases can help guide the clinical diagnosis and treatment of this condition.

**Keywords:** Occurrence; distribution; bone metastasis; metastatic breast cancer

Received: 02 December 2020; Accepted: 11 January 2021; Published: 31 January 2021.

doi: 10.21037/tbcr-20-64

View this article at: <http://dx.doi.org/10.21037/tbcr-20-64>

## Introduction

Bone is the most common metastatic site for breast cancer patients, and the incidence of bone metastasis in advanced breast cancer is as high as 65–75% (1). Breast tumor cells infiltrate the bone marrow microenvironment, and interact with normal bone cells under the mediation of tumor growth factors and cytokines, causing osteolysis and ultimately leading to bone pain, pathological fractures, spinal cord compression, and other skeletal-related symptoms (2). These complications caused by breast cancer bone metastasis (BCBM) can reduce the patient's quality of life, increase the medical burden, and affect subsequent treatment (3,4). Early diagnosis and treatment of bone metastasis is critical to breast cancer patients, and patients with bone metastasis need to receive systemic and local treatment. With the launch of denosumab, a human monoclonal antibody bone-modifying agent, the diagnosis and treatment of bone metastasis have received more attention. However, for the current diagnosis of BCBM, there is lack of the data on the time and location of the bone metastases.

In order to construct an evidence-based rationale for the clinical diagnosis and treatment of BCBM, we analyzed the clinical data of patients with breast cancer and bone metastasis in our medical center and examined the occurrence time and distribution of bone metastases in these patients. We present the following article in accordance with the STROBE reporting checklist (available at <http://dx.doi.org/10.21037/tbcr-20-64>).

## Methods

The study was conducted in accordance with the Declaration of Helsinki and the Harmonized Tripartite Guideline for Good Clinical Practice from the International Conference on Harmonization. This study was approved by the Institutional Review Board of the Affiliated Hospital of Qingdao University. Informed consent was obtained from all individual participants included in the study.

### *Study population*

Data related to initial diagnosis, disease characteristics, and treatment of breast cancer patients with bone metastasis in our center from January 1, 2010 to December 31, 2019 were collected. The data included patient's age, stage, and

molecular subtype of first diagnosis, time from the first diagnosis of breast cancer to confirmed bone metastasis, combined visceral metastasis, diagnostic methods, sites of bone metastasis, and systemic comprehensive and local treatment information.

### *Enrollment criteria and diagnostic criteria for bone metastasis*

Participants in the study needed to meet the following inclusion criteria: pathologically diagnosed with breast cancer, at least 1 bone metastasis diagnosed by imaging or pathological biopsy, and complete basic information with detailed diagnosis and bone metastasis treatment data.

The diagnostic criteria of bone metastasis defined in this study was computed tomography (CT) confirming bone destruction or bone biopsy confirming bone metastasis originating from the breast.

### *Statistical analysis*

Non-normally distributed data are described by medians, and categorical variables are described by percentages. All statistical data analyses were completed using SPSS 19.0 (SPSS Inc., IBM Corp., Armonk, NY, USA).

## Results

A total of 984 patients were included in the statistical analysis, with female patients accounting for 99.3% (977/984) of the total cases. All breast cancer patients in this study were diagnosed with bone metastasis by CT. Among these patients, 56.3% (554/984) underwent emission CT (ECT) examination, 55.7% (548/984) underwent magnetic resonance imaging (MRI), and 8.1% (80/984) underwent X-ray examination. Only 84 (8.5%) patients received of bone biopsy. The characteristics of the 984 breast cancer patients with bone metastasis are shown in *Table 1*.

The most common molecular subtype of breast cancer patients with bone metastasis was hormone-receptor positive (HR), accounting for 87.2% (858/984), followed by HER-2 positive, accounting for 14.6% (144/984), and triple-negative breast cancer patients, accounting for 7.4% (73/984). The median age of the patients at first diagnosis of bone metastasis was 48 years old, and the median time from the first diagnosis of breast cancer to confirmed bone metastasis was 36 months. Among all

**Table 1** Characteristics of 984 breast cancer patients with bone metastasis

Term	Number, n (%) or [range]
Age at first diagnosis (years)	43 [20–81]
Age of bone metastasis (years)	48 [22–83]
Time from initial diagnosis to bone metastasis (months)	36 [0–398]
≤60	710 (72.2)
>60	274 (27.8)
Symptoms at the time of bone metastasis diagnosis	
Yes	578 (58.7)
No	406 (41.3)
Number of bone metastases	
Single	123 (12.5)
Multiple	861 (87.5)
Bone metastasis characteristics	
Osteolytic changes	849 (86.3)
Osteogenic changes	5 (0.5)
Mixed changes	130 (13.2)
Combined visceral metastasis	
Liver	494 (50.2)
Lung	425 (43.2)
Brain	128 (13.0)
Other	8 (0.8)

patients, 11.5% (113/984) were first diagnosed with stage IV bone metastasis, and 88.5% (871/984) were diagnosed with recurrent bone metastasis. Among the recurrent and metastatic breast cancer patients with bone metastasis, 248 (25.2%) patients were diagnosed with bone metastasis within 2 years after the initial diagnosis, 349 (35.5%) patients were diagnosed within 2–5 years, and 200 (20.3%) patients were diagnosed within 5–10 years; a further 74 (7.5%) patients were diagnosed with bone metastasis more than 10 years after the initial diagnosis, with the longest period after initial diagnosis of 33 years occurring in 1 patient. *Figure 1* shows the times of bone metastasis of recurrent breast cancer.

The statistical analysis also revealed that 58.7% (578/984) of breast cancer patients were diagnosed with

bone metastasis after examination due to related symptoms, and the remaining 41.3% (406/984) of the patients were asymptomatic at the time of diagnosis. The vast majority of bone metastases in breast cancer patients were multiple lesions. The patients with multiple bone metastasis lesions accounted for 87.5% (861/984), and patients with single-bone metastasis lesions accounted for 12.5% (123/984). Almost all patients with bone metastasis had osteolytic manifestations; the mixed type of changes dominated by osteolytic changes accounted for 13.2% (130/984) of these cases, and only 0.5% (5/984) of the patients had osteogenic changes at initial diagnosis. Of all the enrolled breast cancer patients, 74.4% (732/984) had concurrent visceral metastasis, with 50.2% (494/984), 43.2% (425/984), and 13.0% (128/984) having liver metastasis, lung metastasis, and brain metastasis, respectively; other rare visceral metastasis accounted for 0.8% (8/984) of cases.

Among the 984 patients with bone metastasis included in the analysis, there were a total of 5,587 bone metastasis sites. The most common sites of totally involved bone metastasis included the axial bones, of which the ribs (13.4%) were the most common site, followed by the thoracic vertebrae (12.4%), pelvis (12.2%), lumbar vertebrae (12.1%), and sternum (10.5%). Metastasis of extremity bones and accessory bones, including the femur (7.2%), scapula (7.0%), humerus (5.8%), clavicle (4.0%), and tibia (0.3%), was relatively rare, while other bone metastasis sites, including the radial, metacarpal, and foot bones, accounted for a total of 0.1%. Data on the initial site of bone metastasis was available for 303 breast cancer patients, which revealed that the sternum (27.7%) was the most common initial metastatic site, followed by the pelvis (20.8%), ribs (17.5%), thoracic vertebrae (13.5%), and lumbar vertebrae (11.9%). The initial and final distribution of BCBMs are shown in *Figure 2* and *Figure 3*.

Relevant data on systemic comprehensive treatment indicated that the proportion of all the enrolled patients who had received chemotherapy was 89.7% (883/984). Among the hormone receptor-positive breast cancer patients with bone metastasis, 86.7% (744/858) received endocrine therapy; among the HER-2-positive breast cancer patients with bone metastasis, 79.2% (114/144) received HER-2-targeted therapy. In the local treatment of bone metastasis, 86.5% (851/984) of all patients received bone-modifying agents, 27.7% (273/984) received bone radiotherapy, and 7.5% (74/984) underwent orthopedic surgery.

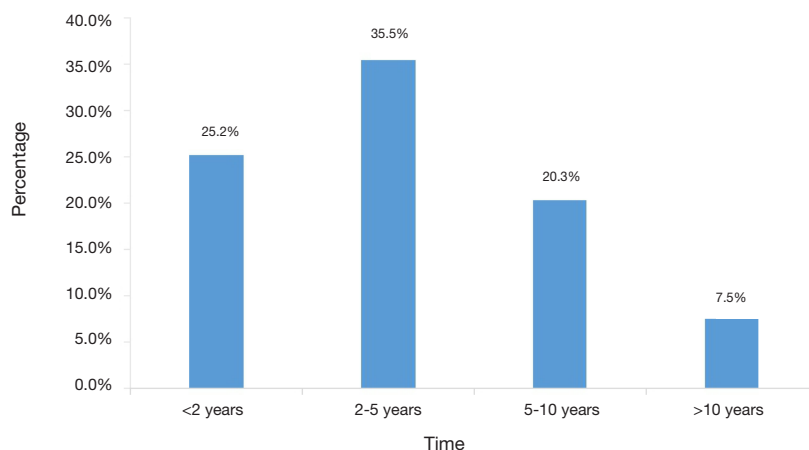


Figure 1 The times to bone metastasis of recurrent breast cancer (n=984).

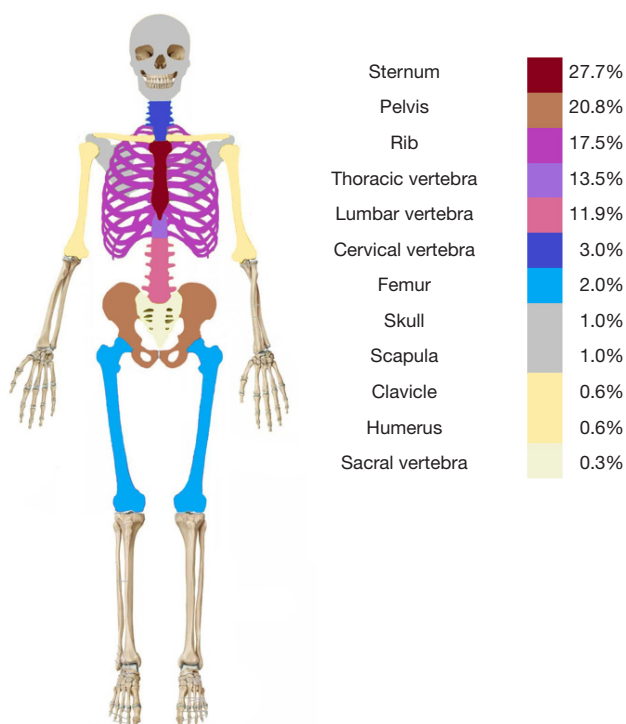
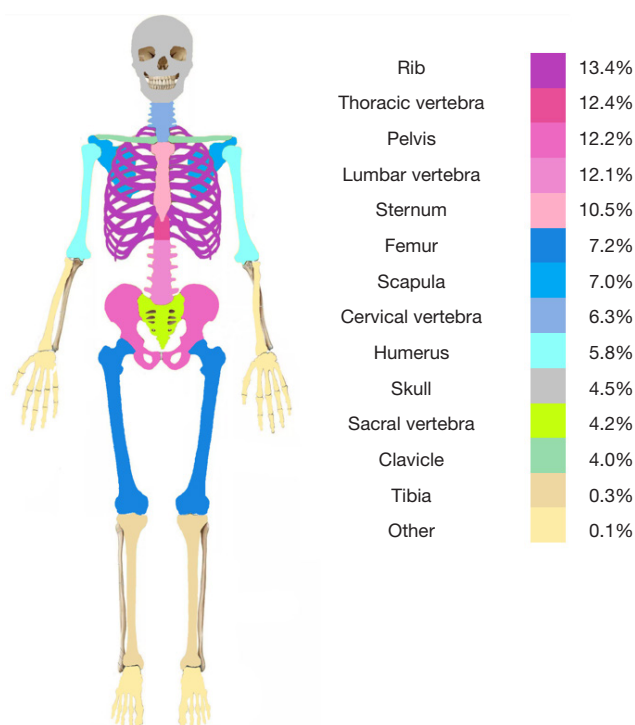


Figure 2 Distribution of initial involved sites of breast cancer bone metastases (n=303).

**Discussion**

The results of this study may provide important guiding significance for the diagnosis and treatment of bone metastasis in breast cancer patients. First, we found that CT is the most common method which can more accurately diagnose bone metastasis. Second, bone metastasis is more common 5 years after breast cancer diagnosis, and this may

help to better to monitor bone metastasis in breast cancer patients. Third, bone metastasis is more likely to occur in hormone receptor-positive breast cancer patients, the main sites of bone metastasis are the axial bones, and the ribs are the most common metastatic site. Fourth, chemotherapy is the most common systemic comprehensive treatment method, while bone-modifying agents are the most



**Figure 3** Distribution of totally involved sites of breast cancer bone metastases (n=5,587).

commonly used local treatment for bone metastasis.

As a preliminary screening examination, ECT has high sensitivity but insufficient specificity. CT has both high sensitivity and specificity, and can better diagnose bone metastases (5). Therefore, all patients in this study were diagnosed by CT to obtain more accurate diagnosis results. Of course, bone pathological biopsy is the gold standard for diagnosing bone metastases; however, bone pathological biopsy is an invasive examination, it is difficult to obtain bone metastasis tissue, and the patients' desires need to be considered in its implementation. Consequently, only a small portion cases (8.5%), in which the imaging diagnosis was not clear or not consistent with symptoms, received bone biopsy.

Most of the patients in this group were found to have bone metastasis within 5 years after the diagnosis of breast cancer, and the proportion of patients with bone metastasis found within 2–5 years was the highest, which is consistent with previous research (6). We did not retrieve any relevant research results clarifying why bone metastasis is common in the first 5 years after breast cancer diagnosis, but this finding supports strengthening the follow-up observation of bone metastasis in the 5 years after breast cancer diagnosis by rational application of bone CT and ECT. This measure

may not only improve the diagnosis bone metastasis, but may also prevent the unnecessary waste of medical resources. Those patients who are diagnosed with bone metastasis more than 10 years after the diagnosis of breast cancer may have a better prognosis, and the follow-up time for these patients can be extended appropriately.

In our study, bone metastasis was more likely to occur in hormone receptor-positive breast cancer patients, and other related literature report a similar result (7). This may be a consequence of hormone receptor-positive breast cancer patients having a better prognosis and a longer survival time, leading to more opportunities for discovering bone metastases.

Prior to initiating this study, we did not know the distribution of bone metastases. Based on the study results, we created two diagrams (*Figures 2 and 3*) which illustrate the distribution of bone metastases. It can be seen from these diagrams that the bone metastasis of breast cancer is more likely to occur in the axial bones, such as the chest bone and spine (8). Of the initial bone metastasis sites, the ribs and sternum of breast cancer patients are especially susceptible to invasion, perhaps because the breast is adjacent to the sternum and ribs. Furthermore, breast tumor cells can spread to the sternum through the

parasternal lymph nodes, or spread to the ribs through the aorta (9). Thus, strengthening the follow-up observation of these bones may allow for the more timely discovery of bone metastasis, and chest CT is a reasonable inclusion in routine breast cancer examination. For those patients with extensive bone metastases in whom the scope of the bone metastases continues to expand, the thoracic and lumbar vertebrae may replace the sternum as the more common sites of multiple bone metastases. This may be related to the vertebral venous plexus. The vertebral vein communicates with the major veins, and without a venous valve, reflux can easily occur, thus facilitating the spread of tumor cells (10). Breast tumor cells can easily migrate through the vertebral venous plexus to the adjacent ribs and spine, and due to the axial bones containing adult red bone marrow, the rich blood circulation and extracellular matrix may contribute to the formation of bone metastasis (11). This better explains why bone metastasis occurs more often in the axial bones. Most of the axial bones are load-bearing bones, and timely treatment and intervention (such as bone irradiation and bone surgery) of these bone metastases can reduce the occurrence of pathological fractures, spinal cord compression, and other skeletal-related events, which is vital for improving the quality of life of patients. Overall, understanding the distribution of bone metastases in breast cancer patients is critical for optimizing the diagnosis and treatment of this condition.

We further collected the relevant data concerning bone metastasis treatment in our research. The results indicate that chemotherapy is the most commonly used systemic comprehensive treatment method. According to the principle of breast cancer classification treatment (12), hormone receptor-positive patients should be given priority in receiving endocrine therapy. However, most of these patients also have visceral metastases, and also receive chemotherapy (excluding endocrine therapy). A few HER-2-positive patients in our study did not receive relevant targeted therapy perhaps due to the patients' financial ability and regional medical insurance policy (13). Bone-modifying agents are the cornerstone for the prevention and treatment of skeletal-related events. Related studies indicate that bone-modifying agents can reduce the incidence of skeletal-related events and extend the time until their first occurrence (14,15). Consequently, the Chinese Society of Clinical Oncology (CSCO) guidelines (16) and the National Comprehensive Cancer Network (NCCN) guidelines (17) recommend that breast cancer patients be treated with bone-modifying agents when they are diagnosed with bone

metastasis, as was the case with most of the patients in our study. It is clear that the guidelines have played a prominent role in standardizing treatment. Bone radiotherapy and orthopedic surgery have specific clinical indications (18), and they are non-essential treatments for breast cancer patients with bone metastasis. Therefore, we found that the proportion of the patients receiving bone radiotherapy was not high, with the proportion undergoing bone surgery being even lower.

Several shortcomings to our research should be addressed. For one, the process of patient enrollment might have introduced possible selection bias, while missing follow-up data might have produced observation bias. Together, these biases might have led to a certain deviation in the results of this study. In the future, we will further strengthen the follow-up observation of patients and expand the volume of data to reduce the impact of bias on the results.

## Conclusions

Bone metastasis from breast cancer usually occurs within 5 years after the initial diagnosis of breast cancer, with the axial bones being the main site of BCBM. Therefore, routine chest CT examinations for patients diagnosed with breast cancer within 5 years may aid in the timely diagnosis of bone metastasis, while adopting appropriate treatment methods will greatly improve the prognosis of these patients.

## Acknowledgments

*Funding:* None.

## Footnote

*Reporting Checklist:* The authors have completed the STROBE checklist. Available at <http://dx.doi.org/10.21037/tbcr-20-64>

*Data Sharing Statement:* Available at <http://dx.doi.org/10.21037/tbcr-20-64>

*Conflicts of Interest:* All authors have completed the ICMJE uniform disclosure form (available at <http://dx.doi.org/10.21037/tbcr-20-64>). ZJ serves as an Editor-in-Chief of *Translational Breast Cancer Research*. JL serves as an unpaid Managing Editor of *Translational Breast Cancer Research*.

The other authors have no conflicts of interest to declare.

**Ethical Statement:** The authors are accountable for all aspects of the work in ensuring that questions related to the accuracy or integrity of any part of the work are appropriately investigated and resolved. The study was conducted in accordance with the Declaration of Helsinki (as revised in 2013). This study was approved by the Institutional Review Board of the Affiliated Hospital of Qingdao University (QYFYKYL221311920). Informed consent was obtained from all individual participants included in the study.

**Open Access Statement:** This is an Open Access article distributed in accordance with the Creative Commons Attribution-NonCommercial-NoDerivs 4.0 International License (CC BY-NC-ND 4.0), which permits the non-commercial replication and distribution of the article with the strict proviso that no changes or edits are made and the original work is properly cited (including links to both the formal publication through the relevant DOI and the license). See: <https://creativecommons.org/licenses/by-nc-nd/4.0/>.

## References

- Li S, Peng Y, Weinhandl ED, et al. Estimated number of prevalent cases of metastatic bone disease in the US adult population. *Clin Epidemiol* 2012;4:87-93.
- Weidle UH, Birzele F, Kollmorgen G, et al. Molecular Mechanisms of Bone Metastasis. *Cancer Genomics Proteomics* 2016;13:1-12.
- Walker MS, Miller PJ, Namjoshi M, et al. Relationship between incidence of fracture and health-related quality-of-life in metastatic breast cancer patients with bone metastases. *J Med Econ* 2013;16:179-89.
- Stopeck A, Rader M, Henry D, et al. Cost-effectiveness of denosumab vs zoledronic acid for prevention of skeletal-related events in patients with solid tumors and bone metastases in the United States. *J Med Econ* 2012;15:712-23.
- Talbot JN, Paycha F, Balogova S. Diagnosis of bone metastasis: recent comparative studies of imaging modalities. *Q J Nucl Med Mol Imaging* 2011;55:374-410.
- Yan M, Song ST, Jiang ZF, et al. The clinical course of bone metastasis of breast cancer. *Chinese Journal of Bone Tumor and Bone Disease* 2003;2:221-24.
- Molnár IA, Molnár B, Vízkeleti L, et al. Breast carcinoma subtypes show different patterns of metastatic behavior. *Virchows Arch* 2017;470:275-83.
- Chen WZ, Shen JF, Zhou Y, et al. Clinical characteristics and risk factors for developing bone metastases in patients with breast cancer. *Sci Rep* 2017;7:11325.
- Wang CY, Wu GY, Shen MJ, et al. Comparison of distribution characteristics of metastatic bone lesions between breast and prostate carcinomas. *Oncol Lett* 2013;5:391-7.
- Zhu M, Liu X, Qu Y, et al. Bone metastasis pattern of cancer patients with bone metastasis but no visceral metastasis. *J Bone Oncol* 2019;15:100219.
- Coleman RE. Clinical features of metastatic bone disease and risk of skeletal morbidity. *Clin Cancer Res* 2006;12:6243s-6249s.
- Xu F, Jiang Z. CSCO BC guideline: updates for hormone receptor-positive breast cancer in 2020. *Transl Breast Cancer Res* 2020;1:3.
- Li J, Wang S, Wang Y, et al. Disparities of Trastuzumab Use in Resource-Limited or Resource-Abundant Regions and Its Survival Benefit on HER2 Positive Breast Cancer: A Real-World Study from China. *Oncologist* 2017;22:1333-8.
- Desautels DN, Harlos CH, Jerzak KJ. Role of bone-modifying agents in advanced cancer. *Ann Palliat Med* 2020;9:1314-23.
- Tanaka R, Yonemori K, Hirakawa A, et al. Risk Factors for Developing Skeletal-Related Events in Breast Cancer Patients With Bone Metastases Undergoing Treatment With Bone-Modifying Agents. *Oncologist* 2016;21:508-13.
- Guidelines of Chinese society of clinical oncology breast cancer. Beijing: People's Medical Publishing House, 2020.
- NCCN. Clinical practice guidelines in oncology (NCCN guidelines) 2020.V2, breast cancer. Available online: [http://www.nccn.org/professionals/physician\\_gls/default.aspx#breast](http://www.nccn.org/professionals/physician_gls/default.aspx#breast)
- Manabe J, Kawaguchi N, Matsumoto S, et al. Surgical treatment of bone metastasis: indications and outcomes. *Int J Clin Oncol* 2005;10:103-11.

(English Language Editor: J. Gray)

doi: 10.21037/tbcr-20-64

**Cite this article as:** Nie H, Yuan Y, Li J, Xu F, Wang T, Bian L, Jiang Z, Zhang S. Occurrence and distribution of bone metastases in 984 metastatic breast cancer patients. *Transl Breast Cancer Res* 2021;2:4.