



# Metastatic breast cancer in a transgender female with history of mantle field radiation and free silicone breast injections: case report

Maxwell Phillips<sup>1</sup>, Ewa Timek<sup>2</sup>

<sup>1</sup>Michigan State University, College of Human Medicine, Grand Rapids, MI, USA; <sup>2</sup>Advanced Plastic Surgery, Grand Rapids, MI, USA

Correspondence to: Maxwell Phillips, MD. Michigan State University, College of Human Medicine, Grand Rapids, MI 49505, USA.

Email: phill812@msu.edu.

**Background:** In today's world, the concept of gender has been scrutinized and an appreciation for those who experience dysphoria with their birth sex and gender classification is becoming more commonplace. Keeping in mind the patients gender orientation in addition to their birth sex is necessary when assessing health conditions more prevalent in one sex, such as breast cancer.

**Case Description:** In this report, we present a 51-year-old African American transgender female with history of chemotherapy and mantle-field radiation treatment for sub-clavicular and mediastinal Hodgkin's lymphoma 24 years prior to presentation of a new left neck mass. The enlarged lymph node was removed revealing metastatic salivary adenocarcinoma with features corresponding to metastatic breast carcinoma. Computed tomography (CT) of the chest, abdomen, and pelvis detected metastasis to the pelvis and a few lucent bone lesions in the lumbar spine. Of note, the patient underwent free silicone injections into both breasts to emphasize her desired gender three years after treatment for Hodgkin's lymphoma. Based on her history of metastatic disease and history of mantle radiation, it was determined that her previous cancer diagnoses were likely due to metastatic breast cancer that was obscured by silicone injections. Bilateral skin-sparing mastectomy was performed, patient recovered well, and continued with palliative care at follow up.

**Conclusions:** Even though there is significant data regarding the incidence of breast cancer in the separate female and male populations, review of the literature shows minimal information regarding incidence in the transgender population. Our hope is that this report will contribute to the current base of knowledge present in the literature while also bringing attention to the need for further investigation of sex-specific diseases in transgender individuals.

**Keywords:** Breast cancer; breast reconstruction; transgender; gender reassignment procedures; adult Hodgkin lymphoma

Received: 23 May 2022; Accepted: 22 July 2022; Published: 30 July 2022.

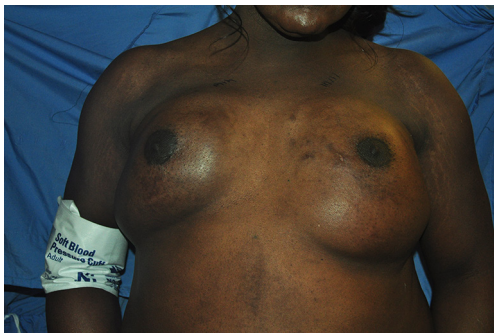doi: 10.21037/tbcr-22-25

View this article at: <https://dx.doi.org/10.21037/tbcr-22-25>

## Introduction

In today's world, the concept of gender has been scrutinized and an appreciation for those who experience dysphoria with their birth sex and gender classification is becoming more commonplace (1). Gender reassignment is associated with a profound change in one's well-being but is also related with unique healthcare needs and challenges (2). When providing care to transgender patients, it is vital

to not only recognize their gender identity but to also keep in mind their birth sex. The utility of this thought process is particularly beneficial when assessing health conditions more prevalent in one sex, such as breast cancer. In this report, we present a case of an African American transgender female who developed metastatic breast and salivary carcinoma after chest irradiation for Hodgkin's lymphoma and free silicone injections into the breasts.

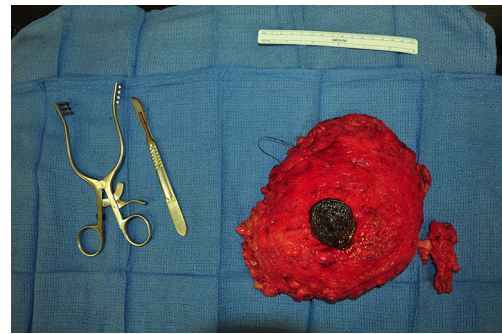


**Figure 1** A pre-operative photo displaying nonuniform breast size bilaterally as well as subcutaneous masses visible upon physical examination.

The purpose of this case report is to not only highlight the uniqueness of this scenario but also to serve as a message regarding the necessity of thinking outside of the normal mindset physicians develop through their care of patients that adhere to the traditional gender binary. Therefore, we present the following case report in accordance with the CARE reporting checklist (available at <https://tbc.amegroups.com/article/view/10.21037/tbcr-22-25/rc>).

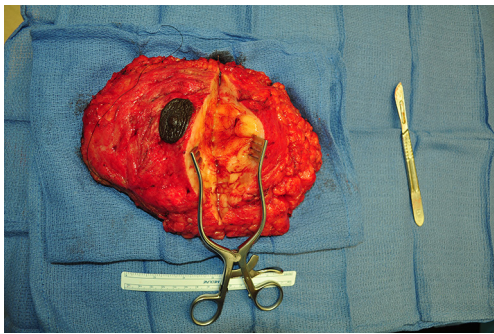
### Case description

The patient is a 51-year-old Male-to-Female (MtF) with history of chemotherapy and mantle-field radiation treatment for sub-clavicular and mediastinal Hodgkin's lymphoma 24 years prior to presentation with a new left neck mass of 5-week duration. Twenty-one years prior to presentation, she underwent free silicone injections into both breasts to emphasize her desired gender. On physical examination, a hard lymph node-like mass was palpated in the submandibular region and was confirmed by ultrasound to be  $2.1 \times 1.3 \times 1.7 \text{ cm}^3$ . The enlarged lymph node was subsequently removed revealing a metastatic salivary adenocarcinoma with features corresponding to metastatic breast carcinoma including estrogen receptor (ER) positive 40%, progesterone receptor (PR) positive 5%, and human epidermal growth factor receptor-2 (HER2) negative receptors by fluorescence in situ hybridization (FISH). Computed tomography (CT) of the chest, abdomen, and pelvis detected nodular foci in the subcutaneous tissue of the pelvis and a few lucent bone lesions with similar morphology to the initial submandibular gland carcinoma. These lesions were treated with partial excision and radiation therapy.



**Figure 2** A post-operative photo displaying right breast tissue removed through meticulous sharp dissection.

In addition to complaints associated with nodal and bony metastasis, the patient reported increasing breast pain for 2 years preceding the current presentation. Review of the EMR showed that she had not received any imaging or screening testing during that 2-year period. She indicated a positive family history of breast cancer in her mother at the age of 70. Physical examination of the breasts showed large uniform, firm, and painful masses occupying the entirety of both breast mounds with tented and thin skin envelope (*Figure 1*). Magnetic resonance imaging (MRI) of the breasts revealed bilateral skin thickening and subcutaneous low signal material, which presumably represented the free silicone but no particular abnormal enhancement to suggest malignancy. Based on her history of metastatic disease and history of mantle radiation, it was determined that her previous cancer diagnoses were likely due to metastatic breast cancer that was obscured by silicone injections on chest imaging. Bilateral skin-sparing mastectomy was planned. Due to altered skin morphology and potentially impaired skin viability, meticulous sharp dissection was carried out to isolate the skin envelope from the underlying silicone masses (*Figure 2*). The skin flaps appeared well vascularized. The skin flaps were reduced, and the wounds closed in a complex fashion. Gross tissue examination at the time of surgery showed significantly fibrotic and thickened tissue of the breast with silicone present in the dermis and extending posteriorly (*Figure 3*) with portions of silicone within the pectoralis muscle. Further pathology of tissue of bilateral breasts showed extensive vacuolated histiocytic reaction associated with hyalinized collagenous fibrosis, focal mild chronic inflammation and scattered multinucleated foreign body giant cells, and no evidence of malignancy. The patient recovered well. She continued



**Figure 3** A post-operative photo displaying fibrotic right breast tissue interwoven with previously injected free silicone product.

with palliative care at follow up. All procedures performed in this study were in accordance with the ethical standards of the institutional and/or national research committee(s) and with the Helsinki Declaration (as revised in 2013). Written informed consent was obtained from the patient for publication of this case report and accompanying images. A copy of the written consent is available for review by the editorial office of this journal.

## Discussion

Breast cancer in birth sex males contributes to approximately 1% of breast cancer diagnosis (3). Data from 2020 indicated that of the approximate 2,620 men diagnosed, an estimated 520 men were expected to die from breast cancer (4). Although the incidence of breast cancer is lower in birth sex males, it is believed that men are likely to have a high chance of developing stage IV breast cancer with data showing a percentage of 5.8% of males and 3.8% of females ultimately developing stage IV breast cancer (5). In addition to this, a study conducted by Dr. Shu *et al.* that reviewed the National Cancer Database showed lower survival rates in men as compared with women, with a 5-year overall survival rate after a diagnosis of breast cancer of 77.6% for men, compared to 86.4% for women.

Even though there is significant data regarding the incidence of breast cancer in the separate female and male populations, review of the literature shows minimal information regarding incidence in the transgender population (6). A recent article published in December 2020 performed an in-depth review of the literature regarding cancer screening guidelines and protocols for transgender individuals. Their report generated only 85 articles

pertaining to this topic with an absence of any clear direction or information to formulate meaningful guidelines (7). The World Professional Association of Transgender Health (WPATH) has also made a statement that “In the absence of large-scale prospective studies, providers are unlikely to have enough evidence to determine the appropriate type and frequency of screening...Patients may find cancer screening gender affirming, or both physically and emotionally painful” (8). Furthermore, the use of large databases and directories, which has become more prevalent in recent years, fails to capture meaningful information for the transgender population since they often utilize binary genders when recording patient data (8,9). Specific screening protocols for breast cancer parallel that of cis-females which recommends annual chest wall exams, mammography, and possible ultrasound or MRI. There is also a recommendation that MtF individuals over the age of 50 who have received 5–10 years of hormonal therapy should have mammograms every 2 years (10). However, this is currently not evidence based and surveillance can differ greatly based on different providers and patients. The use of hormonal medications to aid in the transitioning process for transgender individuals is suspected to influence the probability of developing breast cancer since most cases of breast cancer in females is due to an increased exposure to estrogen, however this has yet to be verified (11). A case study involving a MtF individual with a similar presentation to our patient, received intramuscular injections of estrogen and had breast implantation with silicone implants prior to presenting with low back pain which was later diagnosed as metastatic disease to the cervical, thoracic, and lumbar vertebral bodies (12). A case report from Pritchard *et al.*, showed the development of a high-grade infiltrating ductal carcinoma in a 35-year-old who had received oral estrogen therapy for 10 years prior to the discovery of a mass in her breast. The report also cites an additional case where a transgender female in her 30s developed breast cancer following use of estrogen supplementation for gender transformation (1). Ganly *et al.*'s case report regarding a 36-year-old MtF patient painted a similar picture which involved gender reassignment surgery followed by 14 years of oral estrogen therapy prior to the development of a painful breast mass which was identified as invasive ductal carcinoma (13). Even though there is no conclusive evidence, Teoh *et al.* suggested that in the few reported cases of breast cancer in MtF transgender patients, there appears to be a higher prevalence of hormone receptor-negative and triple-negative tumors (14). Due to limited population

group and occurrence, the incidence of breast cancer in transgender females is not well documented. Through limited data, Hartley *et al.* found that the incidence of breast cancer in transgender females is comparable to natal males (15). However, the authors did not recommend any specific strategies to risk stratification or screening. In the absence of the population data necessary to develop robust screening methods, suggestions have been made that MtF transgender individuals who undergo mastectomy will likely incur the same 90% breast cancer risk reduction as biological females (16). Also, MtF transgender individuals are advised to adhere to mammographic screening protocols that are comparable to that of their female counterparts (16).

The probability of breast cancer development in our patient was extremely rare. The patient's age when she was first diagnosed with metastatic cancer is also noteworthy since this age range is significantly lower than the typical age that breast cancer develops in the male population. However, this is in line with the findings of Hartley *et al.* systematic review that reported MtF patients being diagnosed at a younger age (median 51.5 years) versus natal male median age of 68 years (15). The patient's history of mantle radiation is also of particular interest when assessing her risk of developing breast malignancy. In birth sex females, mantle radiation for Hodgkin's lymphoma increases the risk for development of breast cancer to 4- to 56-fold (17). Similarly, researchers have acknowledged that men are at an increased risk of developing breast cancer following radiation therapy (3). However, there is a lack of meaningful data to definitively support this statement. Salivary adenocarcinoma is rarely precipitated by radiation therapy for Hodgkin's lymphoma. However, breast cancer is the most common secondary cancer found in individuals who undergo mantle cell radiation for treatment of Hodgkin's lymphoma (17). The patient's exposure to radiation therapy at a young age, along with her use of medical and procedural steps of transitioning, likely led to the development of metastatic breast cancer (18).

In estrogen-receptor positive cancer, BRCA testing has been shown beneficial due to higher prevalence with genetic predisposition (19). Review of the patient's health record did not show any testing for BRCA1 or BRCA2 mutations which would be helpful in determining if her disease were due to genetic or environmental (estrogenic exposure) factors. As previously discussed, no guidelines for the transgender population exist, but correlating this to the cis female population may have provided an additional data point to quantify the patient's risk profile. Her history

of free silicone injections to aid in breast augmentation should also be considered when attempting to identify all factors that increase risk or interfere with imaging protocols that could have identified potential cancers. Free silicone injections although they themselves do not have a proven inherent risk, have been shown to manifest with a wide variety of complications. It is illegal to perform these types of injections in the United States, and they are often performed in unsupervised settings (20). A link between silicone injections and development of breast cancer has been suggested due to its potential to obscure malignancy on imaging (21). Guidelines for screening in patients who have received free silicone injections are not present in the literature. Some authors do suggest that water selective MRI is a superior method for investigating possible malignancy in breast tissue that is obscured due to its ability to suppress fat and silicone product for clearer images (22). However, the literature does not contain persuasive data regarding this and has yet to be verified.

Based on the information discussed above, it is evident that breast cancer surveillance in transgender individuals is underrepresented. Still, physicians should consider genetic predisposition to cancer when offering gender affirming surgery as well as keeping in mind the development of disease later in life—according to genetic predisposition and biologic sex. Our hope is that this report will contribute to the current base of knowledge present in the literature while also bringing attention to the need for further investigation of sex-specific diseases in transgender individuals.

## Acknowledgments

*Funding:* None.

## Footnote

*Reporting Checklist:* The authors have completed the CARE reporting checklist (available at <https://tbc.amegroups.com/article/view/10.21037/tbc-22-25/rc>).

*Conflicts of Interest:* Both authors have completed the ICMJE uniform disclosure form (<https://tbc.amegroups.com/article/view/10.21037/tbc-22-25/coif>). The authors have no conflicts of interest to declare.

*Ethical Statement:* The authors are accountable for all aspects of the work in ensuring that questions related to the accuracy or integrity of any part of the work are

appropriately investigated and resolved. All procedures performed in this study were in accordance with the ethical standards of the institutional and/or national research committee(s) and with the Helsinki Declaration (as revised in 2013). Written informed consent was obtained from the patient for publication of this case report and accompanying images. A copy of the written consent is available for review by the editorial office of this journal.

*Open Access Statement:* This is an Open Access article distributed in accordance with the Creative Commons Attribution-NonCommercial-NoDerivs 4.0 International License (CC BY-NC-ND 4.0), which permits the non-commercial replication and distribution of the article with the strict proviso that no changes or edits are made and the original work is properly cited (including links to both the formal publication through the relevant DOI and the license). See: <https://creativecommons.org/licenses/by-nc-nd/4.0/>.

## References

- Pritchard TJ, Pankowsky DA, Crowe JP, et al. Breast cancer in a male-to-female transsexual. A case report. *JAMA* 1988;259:2278-80.
- Lerner JE, Robles G. Perceived Barriers and Facilitators to Health Care Utilization in the United States for Transgender People: A Review of Recent Literature. *J Health Care Poor Underserved* 2017;28:127-52.
- Male Breast Cancer. (2020) Breastcancer.Org. Available online: [https://www.breastcancer.org/symptoms/types/male\\_bc](https://www.breastcancer.org/symptoms/types/male_bc)
- American Cancer Society | Cancer Facts & Statistics. (n.d.). American Cancer Society | Cancer Facts & Statistics. Available online: <http://cancerstatisticscenter.cancer.org/>
- Men with Breast Cancer Have Higher Mortality than Women—National Cancer Institute (nciglobal, ncicenterprise). (2019) (CgvBlogPost) Available online: <https://www.cancer.gov/news-events/cancer-currents-blog/2019/male-breast-cancer-higher-mortality>
- Joint R, Chen ZE, Cameron S. Breast and reproductive cancers in the transgender population: a systematic review. *BJOG* 2018;125:1505-12.
- Sterling J, Garcia MM. Cancer screening in the transgender population: a review of current guidelines, best practices, and a proposed care model. *Transl Androl Urol* 2020;9:2771-85.
- World Professional Association for Transgender Health EMRWG. Standards of care for health of transsexual, transgender, and gender nonconforming people, 7th version. 2011. Available online: [https://www.wpath.org/media/cms/Documents/SOC%20v7/SOC%20V7\\_English.pdf](https://www.wpath.org/media/cms/Documents/SOC%20v7/SOC%20V7_English.pdf)
- Arcelus J, Bouman WP, Van Den Noortgate W, et al. Systematic review and meta-analysis of prevalence studies in transsexualism. *Eur Psychiatry* 2015;30:807-15.
- Deutsch MB, Radix A, Wesp L. Breast Cancer Screening, Management, and a Review of Case Study Literature in Transgender Populations. *Semin Reprod Med* 2017;35:434-41.
- Patel H, Arruarana V, Yao L, et al. Effects of hormones and hormone therapy on breast tissue in transgender patients: a concise review. *Endocrine* 2020;68:6-15.
- Dhand A, Dhaliwal G. Examining patient conceptions: a case of metastatic breast cancer in an African American male to female transgender patient. *J Gen Intern Med* 2010;25:158-61.
- Ganly I, Taylor EW. Breast cancer in a trans-sexual man receiving hormone replacement therapy. *Br J Surg* 1995;82:341.
- Teoh ZH, Archampong D, Gate T. Breast cancer in male-to-female (MtF) transgender patients: is hormone receptor negativity a feature? *BMJ Case Rep* 2015;2015:bcr2015209396.
- Hartley RL, Stone JP, Temple-Oberle C. Breast cancer in transgender patients: A systematic review. Part 1: Male to female. *Eur J Surg Oncol* 2018;44:1455-62.
- Macdonald HR. Managing breast cancer risk in transgender men and women: Emerging safety data and a need for more research. *Breast J* 2019;25:1063-5.
- Hill DA, Gilbert E, Dores GM, et al. Breast cancer risk following radiotherapy for Hodgkin lymphoma: modification by other risk factors. *Blood* 2005;106:3358-65.
- Conway JL, Connors JM, Tyldesley S, et al. Secondary Breast Cancer Risk by Radiation Volume in Women With Hodgkin Lymphoma. *Int J Radiat Oncol Biol Phys* 2017;97:35-41.
- Tung N, Wang Y, Collins LC, et al. Estrogen receptor positive breast cancers in BRCA1 mutation carriers: clinical risk factors and pathologic features. *Breast Cancer Res* 2010;12:R12.
- Stowell JT, Grimstad FW, Kirkpatrick DL, et al. Imaging Findings in Transgender Patients after Gender-affirming Surgery. *Radiographics* 2019;39:1368-92.
- Ko C, Ahn CY, Markowitz BL. Injected liquid silicone, chronic mastitis, and undetected breast cancer. *Ann Plast*

- Surg 1995;34:176-9.
22. Po J, Margolis DJ, Cunningham CH, et al. Water-selective spectral-spatial contrast-enhanced breast MRI for cancer

detection in patients with extracapsular and injected free silicone. *Magn Reson Imaging* 2006;24:1363-7.

doi: 10.21037/tbcr-22-25

**Cite this article as:** Phillips M, Timek E. Metastatic breast cancer in a transgender female with history of mantle field radiation and free silicone breast injections: case report. *Transl Breast Cancer Res* 2022;3:28.