



Transbronchial microwave ablation of lung nodules with electromagnetic navigation bronchoscopy guidance—a novel technique and initial experience with 30 cases

Joyce W. Y. Chan¹, Rainbow W. H. Lau¹, Jenny C. L. Ngai², Carita Tsoi³, Cheuk Man Chu³, Tony S. K. Mok⁴, Calvin S. H. Ng¹

¹Division of Cardiothoracic Surgery, Department of Surgery, Prince of Wales Hospital, the Chinese University of Hong Kong, Hong Kong, China;

²Department of Medicine and Therapeutics, Prince of Wales Hospital, the Chinese University of Hong Kong, Hong Kong, China; ³Department of Imaging and Interventional Radiology, Prince of Wales Hospital, the Chinese University of Hong Kong, Hong Kong, China; ⁴State Key Laboratory of Translational Oncology, Department of Clinical Oncology, Prince of Wales Hospital, the Chinese University of Hong Kong, Hong Kong, China

Contributions: (I) Conception and design: CSH Ng, JWY Chan, RWH Lau; (II) Administrative support: CSH Ng, RWH Lau, CM Chu, C Tsoi, TSK Mok, JCL Ngai; (III) Provision of study materials or patients: CSH Ng, RWH Lau; (IV) Collection and assembly of data: JWY Chan, RWH Lau, CSH Ng; (V) Data analysis and interpretation: JWY Chan, RWH Lau, CSH Ng; (VI) Manuscript writing: all authors; (VII) Final approval of manuscript: all authors.

Correspondence to: Dr. Calvin S. H. Ng, MD, FRCS. Professor, Division of Cardiothoracic Surgery, Department of Surgery, The Chinese University of Hong Kong, Prince of Wales Hospital, Hong Kong, China. Email: calvinng@surgery.cuhk.edu.hk.

Background: Microwave ablation of lung nodules may provide a faster, larger and more predictable ablation zone than other energy sources, while bronchoscopic transbronchial ablation has theoretical advantage of fewer pleural-based complications than percutaneous approach. Our study aims to determine whether the novel combination of bronchoscopic approach and microwave ablation in management of lung nodules is technically feasible, safe and effective.

Methods: This is a retrospective analysis of a single center experience in electromagnetic navigation bronchoscopy microwave ablation in hybrid operating room. Patients had high surgical risks while lung nodules were either proven malignant or radiologically suspicious. Primary endpoints include technical feasibility and safety.

Results: Total of 30 lung nodules from 25 patients were treated. Mean nodule size was 15.1 mm, and bronchus directly leads to the nodules (bronchus sign positive) in only half of them. Technical success rate was 100%, although some nodules required double ablation for adequate coverage. Mean minimal ablation margin was 5.51 mm. The mean actual ablation zone volume was –21.4% compared to predicted, likely due to significant tissue contraction ranging from 0–43%. There was no significant heat sink effect. Mean hospital stay was 1.73 days, and only 1 patient stayed for more than 3 days. Complications included pain (13.3%), pneumothorax requiring drainage (6.67%), post-ablation reaction (6.67%), pleural effusion (3.33%) and hemoptysis (3.33%). After median follow up of 12 months, none of the nodules had evidence of progression.

Conclusions: Bronchoscopic transbronchial microwave ablation is safe and feasible for treatment of malignant lung nodules. Prospective study on clinical application of this novel technique is warranted.

Keywords: Microwave ablation; transbronchial ablation; lung cancer; electromagnetic navigation bronchoscopy; hybrid operating room

Submitted Dec 03, 2020. Accepted for publication Feb 09, 2021.

doi: 10.21037/tlcr-20-1231

View this article at: <http://dx.doi.org/10.21037/tlcr-20-1231>

Introduction

With strong evidence for low-dose computer tomography (CT) scans screening in high risk populations (1), incidental discovery of lung nodule is becoming more common. Many of them are small, sub-solid, and harbour pre-malignant or early stage tumours. Local therapies as definitive treatment of these lesions is among the standard managements, especially in patients with surgical contraindications, for instance prohibitive cardiorespiratory risks or inadequate lung function. Among patients newly diagnosed with early stage lung cancer, 5–10% have absolute or relative contraindications to surgery (2,3), but the percentage could be as high as 28% in octogenarians (4). Treatment modalities such as stereotactic body radiation therapy (SBRT) (5), percutaneous ablation techniques for instance radiofrequency (RFA) (6), microwave (MWA) (7) and cryotherapy (8) are highly effective and are associated with reasonable local control rates ranging from 64% to 69.8% at 2 years. However, these procedures are also associated with complications: SBRT carries up to 22.3% risk of radiation pneumonitis and pneumonia (9), while percutaneous ablation techniques carry 11–52% risk of pneumothorax and bronchopleural fistula (BPF) (10). In terms of energy source, radiofrequency relies heavily on electrical conductance of tissues, thus the high impedance of human lung tissue may limit its effectiveness (11).

Bronchoscopic transbronchial ablation techniques utilizing radiofrequency energy for eradication of tumor cell have been described (12), with theoretical advantages of less pneumothorax/BPF due to non-trans-pleural route of entry, being able to reach peri-bronchial tissues easily, and having access to particular locations in lung which are otherwise difficult or impossible to reach. Meanwhile, microwave energy produces a larger and more predictable ablation zone, as it is minimally affected by impedance and has less heat-sink effects (11). Building upon our institute's experience in lung nodule dye-marking and biopsy via electromagnetic navigation bronchoscopy (ENB) (13,14), we identified a selected group of cases which are suitable for bronchoscopic transbronchial microwave ablation under ENB guidance. Being one of the first centres to perform ENB microwave ablation in clinical setting, we retrospectively analyze data from the first cohort of patients who had completed the procedure. Primary objective of this study is to assess the safety, feasibility and efficacy in reference to ablative effects and treatment outcomes. We present the following article in accordance with the STROBE reporting checklist (available at <http://dx.doi.org/10.21037/tlcr-20-1231>).

<http://dx.doi.org/10.21037/tlcr-20-1231>).

Methods

Trial design

This study is a single-centre retrospective analysis of patients who underwent bronchoscopic transbronchial microwave ablation of malignant or suspicious lung nodules. The study was conducted in compliance with the Declaration of Helsinki (as revised in 2013) and approved by local institutional review board (the Joint Chinese University of Hong Kong – New Territories East Cluster Clinical Research Ethics Committee), CREC reference number of 2020.524. All cases were discussed in multi-disciplinary meetings with oncologists' input, and all study participants gave informed consent before taking part in the study.

Enrolment criteria

Patients with radiologically suspicious lung nodules on CT scans and carried high surgical risk or have refused surgery were eligible for evaluation for ENB microwave ablation. Favourable radiologic features for selection included presence of bronchus sign (presence of bronchus directly leading to nodule), peripheral location, tumor size less than 3 cm, and at least 5 mm away from large blood vessels or mediastinal structures to avoid significant heat sink effect or thermal injury to other visceral organs. Special attention should be paid to avoid including brachial plexus or phrenic nerve into the designed ablation zone. Patients with biopsy-proven lung cancer must have CT or PET/CT scans for exclusion of distant metastases, while nodal involvements were ruled out with endobronchial ultrasound biopsy if lymph nodes were large or hypermetabolic, such that eligible nodules are effectively T1N0M0. Ablation was offered to biopsy-proven lung metastasis if the primary tumour was treated with curative intent and all oligometastases in body could be treated. For the nodules which did not have histology either due to failed or refused biopsy, ablation was only offered if they were radiologically suspicious on serial imaging, and with patients' prior informed consent. During the period from March 2019 to June 2020, 25 patients with 30 nodules were included in the study.

ENB microwave ablation procedure

All patients had a plain fine-cut CT scan within 3 months from the scheduled ablation date for pre-operative planning

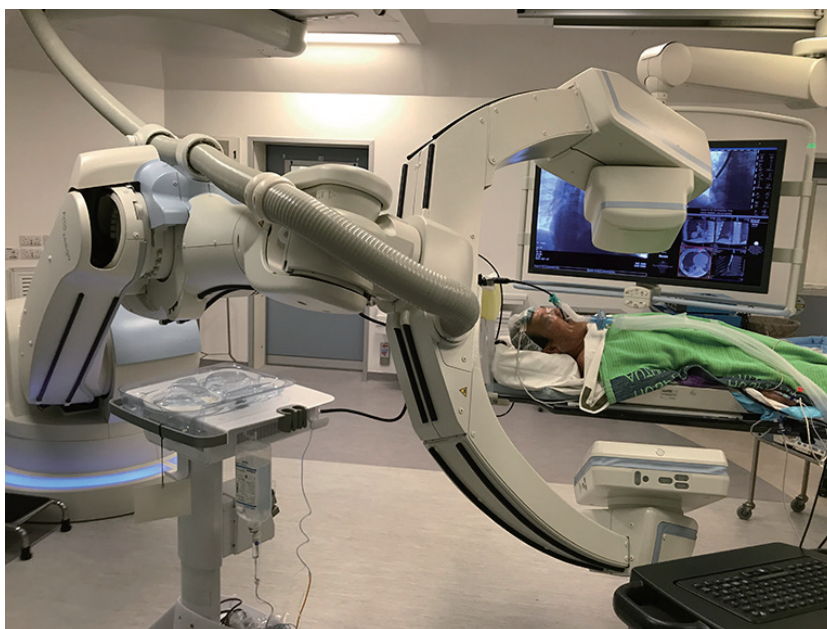


Figure 1 Set-up in the hybrid theatre is shown. The microwave catheter is connected to the microwave ablation console at the lower left in a particular direction such the C-arm was still able to rotate around the table to perform CBCT.

of ENB pathway.

Treatment procedure is summarized in [Table S1](#). On the day of procedure, the patient was intubated inside our hybrid theatre with cone-beam CT (CBCT) and fluoroscopy capabilities. After the first CBCT, navigation to the target lung lesions was performed under ENB with SuperDimension™ Navigation System (Covidien™, Plymouth, MN, USA) as per previously described (15) ([Figure S1](#)). Upon reaching segmental bronchus, a locatable guide (LG) within an extended working channel (EWC) was advanced through the bronchoscope following the navigational route until reaching the target ([Figure S2](#)). In cases where bronchus sign was absent and transbronchial access was required, CrossCountry™ Transbronchial Access Tool (Covidien™, Plymouth, MN, USA) was utilized ([Video 1](#)). A needle was deployed into the lesion and a second CBCT was done to confirm desired location of needle tip within or closely abutting lesion. The CrossCountry™ dilator was then used to create the transbronchial access ([Video 2](#)). Biopsy was performed at this stage if necessary.

The needle and dilator were then exchanged to the Emprint™ Ablation Catheter with Thermosphere™ technology (Covidien™, Plymouth, MN, USA) ([Figure S3](#)). The EWC was retracted to unsheath the tip of microwave catheter ([Videos 3,4](#)), and a third CBCT was performed to

confirm accurate positioning of the catheter. An appropriate ablation energy was determined and predicted margin was measured. Microwave ablation was then carried out ([Figure 1](#), [Figure S3](#)). After cooling for 10 minutes, the first post-ablation CT scan was done to assess the inclusion of lesion into ablation zone, the size of ablation zone and the minimal margin achieved. Double ablation may be performed by either re-ablating in same position, pull-back and re-ablate, or re-navigation and re-ablate (termed as “bracket ablation”) ([Figure S4](#)).

Follow up, response evaluation and data analysis

Chest X-rays were performed on post-operative day 0 and 1, and patients were discharged earliest at 1 day after ablation if no complications arose. Post-ablation fine-cut plain CT scans were arranged at first month, 3rd month, 6th month, 9th month and 12th month, but the full set was not possible for some cases due to patient default or resource restrictions in our public hospital centre. Additional CT scans were done in case of any significant complications. Private scans including PET/CT or CT thorax with contrast were also evaluated if they were available for review. The response to ablation was evaluated by qualified radiologists for local control using the modified Response Evaluation

Criteria in Solid Tumours (mRECIST). Statistical analyses were performed with Microsoft Excel 2010 and IBM® SPSS® Statistics 20. Sample size was not estimated due to the retrospective nature of study. Patient and nodule characteristics were summarized with descriptive statistics, while post-ablation CT appearances and clinical outcomes were compared using Student's t test and chi-square test as appropriate. A P value of ≤ 0.05 was considered significant.

Results

Baseline characteristics

Total of 25 patients were enrolled between March 2019 and June 2020. Patient characteristics are summarized in *Table 1* and *Table S2*. Thirty lung nodules were ablated, in which 5 patients had more than one lung nodule ablated. Concomitant ENB biopsy of target lesion was performed in 6 cases.

All patients had absolute or relative contraindications to surgery, including poor lung reserve or previous contralateral lobectomy, or comorbidities limiting survival, for instance significant cardiopulmonary disease or known metastatic disease. Fourteen patients (56%) had previous lung operations, 78.6% of those had previous contralateral lobectomies making single-lung ventilation potentially problematic. Patients included in the study had significant multiple comorbidities and the median Charlson comorbidity index was 6.

The mean maximal diameter of lung nodule size was 15.1 mm (range, 7 to 29 mm). Biopsy of lung nodules were either performed pre-operatively using CT-guided percutaneous biopsy, or during ENB procedure just before ablation. Pre-operative biopsy was not performed for 10 lung nodules mostly due to difficult access or patient refusal of biopsy. The histological types included lung adenocarcinomas (13.3%), atypia/pre-malignant (33.3%) and metastatic cancer (3.33%). Total of 15 nodules (50%) were negative for malignancy or no biopsy done but still radiologically suspicious. The mean distance between nodule and pleura is only 7.46 mm. Total of 6 nodules were abutting the pleura and 14 nodules were within 5 mm from pleura, making pneumothorax a potential concern.

Procedural characteristics

Procedural characteristics were summarized in *Table 2*. After excluding cases with concomitant biopsy, the mean

total procedural time (from intubation to extubation) was 126.3 minutes. Intra-operative CBCT scans were used to plan, guide and adjust catheter locations, and the median number of CBCT required is 7.

Four nodules (13.3%) required planned or unplanned double ablation to include the nodule in a satisfactory ablation zone with adequate margin. Mean procedure time for single ablation was 116 minutes while that for double ablation was 160 minutes. Concomitant biopsy also significantly lengthens procedural time to mean of 165 minutes.

Immediate post-ablation statistics

A minimum of 5mm margin was planned for each ablated nodule. The expected ablation zone border was drawn using PURE® platform (Siemens Healthineers, Germany) software and the minimum predicted margin was measured (*Figure 2*), which had a mean (\pm SD) of 6.63 (± 2.89) mm. The mean (\pm SD) minimal actual margin after ablation was 5.51 (± 2.48) mm (*Table 3*), and there was no significant difference between the predicted and actual minimal margin ($P=0.086$). Technical success rate, defined as inclusion of lesion into ablation zone with adequate margin, was 100%.

Tissue contractions occur after ablation, and should be taken into consideration when determining whether adequate margin had been achieved. The contraction percentage is not a constant, but rather is inversely proportional to the distance from the centre of ablation (*Figure 3A*). This is the so-called “black hole” theory, meaning that contraction is more pronounced when a reference point is closer to the centre of ablation, in analogy of a black hole where objects closer to the centre experience a stronger attraction force. Each patient had different contraction curves, with examples shown in *Figure 3B*. When all patient's data was pooled on a scatter plot (*Figure 3C*), there is a rough maximal contraction percentage for each distance, for example a maximum of 40% contraction for a 20 mm distance from centre. In general, the contraction percentage ranges from 0–43%.

The post-ablation zone volume was generally smaller than the predicted volume, with a mean of -21.4% (SD $=38.9\%$), but this was without consideration of contraction. The actual ablation zones were as predicted (9 cases) or larger (5 cases) in 46.7% of cases. The cases with smaller-than-predicted ablation zone were analyzed against possible factors affecting the ablation zone size, including presence of COPD, solidity of lesion, and presence of ≥ 3 mm blood vessels close to nodules, but none show statistically

Table 1 Summary of patients and lung nodules characteristics

		Counts (%)	Mean	Range
Patients characteristics (25 patients)				
Age (years)			68.8	51–86
Sex	Male	12 (48%)		
	Female	13 (52%)		
COPD		6 (24%)		
Smoking status	Current smoker	1 (4%)		
	Ex-smoker	6 (24%)		
	Never-smoker	17 (68%)		
Lung function	FVC		98.1% predicted	
	FEV1		94.4% predicted	
	FEV1/FVC ratio		0.732	
	DLCO		81.3% predicted	
Charlson comorbidity index			5.73	
Reason for ablation	Previous major lung resection	14 (56%)		
	History of non-pulmonary cancers	9 (36%)		
	History of major operation	22 (88%)		
	COPD stage 2 or above	4 (16%)		
	Expected limited survival / known metastatic disease	5 (20%)		
	Frailty/age >80 years	4 (16%)		
Lung nodules characteristics (30 lung nodules)				
Maximum nodule size (mm)			15.1	7–29
Lobe	RUL	9 (30%)		
	RML	3 (10%)		
	RLL	4 (13.3%)		
	LUL	8 (26.7%)		
	LLL	6 (20%)		
Location in lung	Periphery	22 (73.3%)		
	Middle one-third	8 (26.7%)		
	Innermost one-third	0		
Histology	Lung cancer	4 (13.3%)		
	Proven metastasis	1 (3.33%)		
	Atypia/pre-malignant	10 (33.3%)		
	Negative for malignancy	5 (16.7%)		
	Not available	10 (33.3%)		

Table 1 (continued)

Table 1 (*continued*)

		Counts (%)	Mean	Range
Suzuki class	Class 1–4	17 (56.7%)		
	Class 5–6 (predominantly solid)	12 (40%)		
	Cavitatory	1 (3.33%)		
Bronchus sign	positive	15 (50%)		
	negative	15 (50%)		
Distance to fissure (mm)			27.8	0–58.5
Distance to pleura (mm)			7.46	0–27.4
Blood vessel (diameter >3 mm)	Inside nodule	6 (20%)		
	Within 5 mm of nodule	12 (40%)		

LUL, left upper lobe; RUL, right upper lobe; RML, right middle lobe; LLL, left lower lobe; RLL, right lower lobe. COPD, chronic obstruction pulmonary disease. FVC, forced vital capacity; FEV1 forced expiratory volume in 1 second; DLCO, diffusing capacity for carbon monoxide

Table 2 Complications from bronchoscopic microwave ablation

Complications	Counts (per-lesion basis)	CTCAE grade
Pain	4 (13.3%)	1
Pneumothorax ^{1,2} requiring chest drain insertion	2 (6.67%)	3
Post-ablation reaction/fever	2 (6.67%)	1
Hemoptysis	1 (3.33%)	1
Infected effusion	1 (3.33%)	1
Abscess	0	–
Bronchopleural fistula	0	–
Hemothorax	0	–
Arrhythmia	0	–
Pneumonia	0	–
Pulmonary edema	0	–
Complications related to intubation and bronchoscopic manipulation (e.g., hoarseness, tracheobronchial injury)	0	–
Unintended microwave burn (e.g., skin burn, vessel thrombosis, embolism, diaphragmatic paresis)	0	–
Procedure-related mortality	0	–

¹Case 8 had intra-operative pneumothorax, required intra-operative chest drain insertion, which was removed on post-operative day 1 and discharged the same day. The peripheral lesion touched both the pleura and fissure, and review of CBCT showed inadvertent puncture of pleura during unsheathing (and unintentional advancement) of microwave ablation catheter. ²Case 9 had pneumothorax on post operative day 1 and also required chest drain insertion. The initial lesion was cavitatory, and the ablation zone is much larger than expected (reaching pleura). He was later complicated by bacillus infection of pleural fluid and completed a course of intravenous antibiotics. Duration of stay was 16 days. CTCAE, common terminology criteria for adverse events.

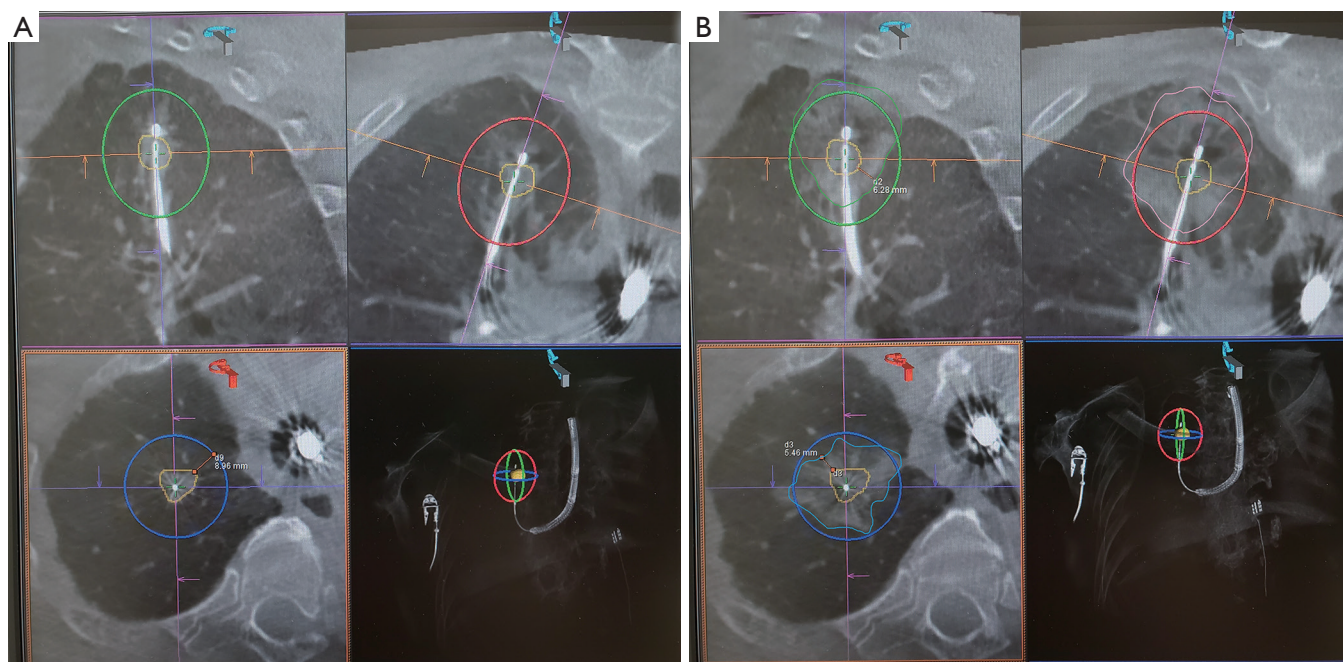


Figure 2 (A) This shows the target lung lesion (yellow tracing) in 3 axes before ablation. With ablation energy of 100 W × 10 minutes, the predicted ablation zone (red, green and blue ovals) is a spheroid measuring 42×35×35 mm, and the minimal predicted margin is 8.96 mm. (B) Figure is the 10-minute post-ablation scan, showing a minimal actual margin of 5.46 mm due to irregular shape of resultant ablation zone (red, green and blue irregular contour tracings), although the total ablation zone volume is similar to prediction.

significant results.

Regarding heat sink effect, there is no statistically significant correlation between a smaller ablation zone with the presence of a sizeable blood vessel (diameter ≥ 3 mm) within 5mm of nodule. Presence or absence of bronchus sign does not significantly affect fluoroscopy time, radiation dose, procedure time or the number of CBCT performed. In terms of learning curve, the first and second half of 22 ablation-only cases were compared. There was a trend towards shorter mean procedural time in the latter half of cases (139 vs. 111 minutes, $P=0.075$) (Figure S5).

Discharge statistics, safety and complications

The median length of hospital stay is 1 day, while the mean is 1.73 days. The great majority of cases (23 cases) were discharged on post-operative day 1, while 6 cases stayed for 2–3 days due to frailty or unrelated complaints.

There was a low rate of complications (Table 2). Mild immediate or delayed pleuritic chest pain was present in 4 cases (13.3%) and responded to common oral analgesics and did not prolong hospital stay. All 4 of the lesions were

close to pleura, and the mechanism of pain could be due to pleural irritation after ablation of peripherally located lung nodules. No referred pain to shoulder due to phrenic nerve injury, or referred pain to arm due to brachial plexus injury occurred. Pneumothorax occurred in 2 cases (6.67%) and both required chest drain insertion. Post ablation reaction including fever occurred in 2 cases (6.67%); while mild hemoptysis was noted in 1 case (3.33%). There were only 2 CTCAE (common terminology criteria for adverse events) grade 3 events.

Follow up and response

Median duration of follow up was 349 days (range from 132 to 615 days). Fifteen cases have completed at least 6-month post-ablation CT scans, with 8 of them already had post-ablation 1 year CT (Table 4). Complete response was achieved in 1 patient, partial response in 12 patients, and stable disease in the remaining 2 patients. There was no progressive disease identified. One unrelated death (case 2) occurred at 12 months after ablation. Morphology of ablated tumour on CT at one month post-ablation is

Table 3 Ablation statistics

	Counts	Mean	Range
Single ablation	26		
Double ablation			
Re-ablate in same location	2		
Pull-back & ablate	1		
Re-navigate & ablate	1		
Number of ablations per lesion		1.13	1–2
Concomitant biopsy	6		
Adenocarcinoma	1		
Atypia	4		
Negative for malignancy	1		
Procedural time (minutes)			
All cases		134.5	70–200
Ablation-only		126.3	70–200
Single ablation		116.2	70–160
Number of CT			
All cases		7.6	4–12
Ablation-only		7.4	4–12
Single ablation		7.1	4–10
With biopsy		8.3	4–11
Catheter position			
Within centre of nodule	17		
Touching nodule border	10		
Outside nodule	3		
Ablation energy (J)		46,803	24,000–120,000
Duration of ablation (minute)		8.32	4–20
Power of ablation (Watt)		97.8	45–100
Radiation dose ($\mu\text{Gy}\cdot\text{m}^3$), all cases		27,869	13,958–44,867
Margin (mm)			
Minimal predicted		6.63	3–14
Minimal actual ¹		5.51	3–10
Maximal actual		16.5	13–19
Actual AZ compared to predicted AZ			
Similar	9 (30%)		
Smaller	16 (53.3%)		
Larger	5 (16.7%)		

AZ, ablation zone. ¹Minimal actual margin is defined as the shortest distance between tumour border and ablation zone edge after 3-dimensional overlaying of ablated region on pre-ablation CT scan.

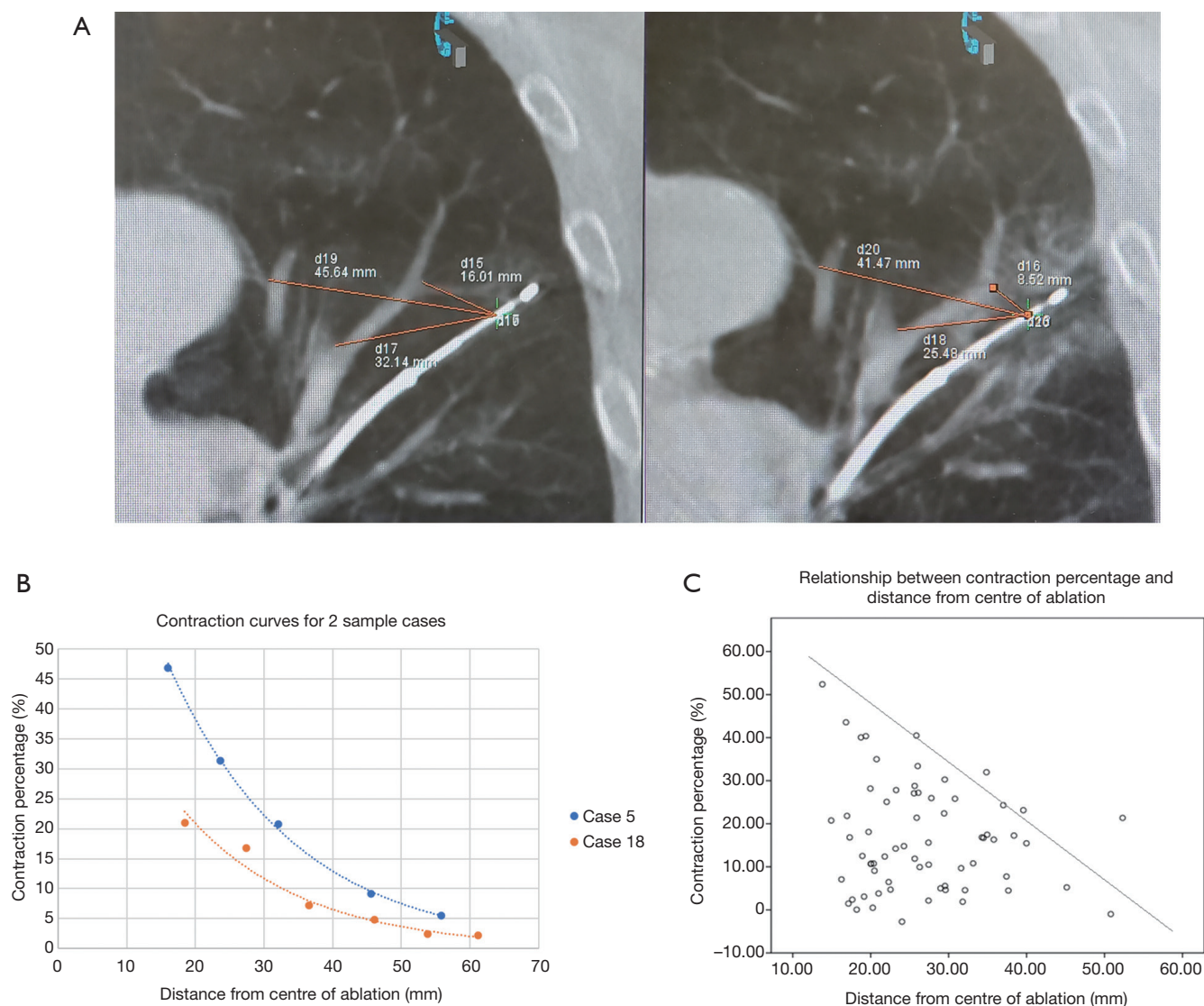


Figure 3 (A) shows the pre-ablation (left) and post-ablation (right) CBCT appearances. The centre of ablation (green cross) is 1cm from the tip of the microwave catheter as defined by the manufacturer. The distance between the centre of ablation and reference points (usually the bifurcation of recognizable neighbouring blood vessels) are measured pre- and post-ablation respectively. The contraction percentage for a particular distance from centre is calculated by $(\text{Pre-ablation distance} - \text{Post-ablation distance}) / \text{Pre-ablation distance} \times 100\%$. For example, contraction percentage is $(32.14 - 25.48) / 32.14 \times 100\% = 20.7\%$ for the point d17. (B) shows the contraction percentages measured at 5–6 reference points for two cases. References points are usually recognizable bifurcations of adjacent blood vessels which can be identified in both pre- and post-ablation CTs. The contraction percentage and distance from centre of ablation demonstrates an inverse relationship. Each patient has a different contraction curve due to differences in lung and lesion properties and amount of ablation energy used, although the shape of curve should be similar. (C) shows a scatter plot of contraction percentage against distance from centre of ablation when data from all patients are pooled together. It is not a linear relationship, but there is a maximum possible contraction percentage for each distance. For instance, for reference points 20 mm from centre of ablation, a maximum of 40% contraction is observed. Likewise, for a reference point at 40 mm, a maximum of roughly 20% contraction is expected.

Table 4 Short to medium term follow up results

Case	Percentage change (%) of AZ volume compared with immediate post-ablation CT scan					mRECIST
	1m CT	3m CT	6m CT	9m CT	12m CT	
1	+78.9	−11.7	+29.4	−	+33.5	CR
2	−61.8	−	−85.4	−83.9	Death	PR
3	−81.1	−87.8	−	−	−82.7	PR
4	−	−63.8	−69.6	−	−	PR
5	−61.3	−	−	−	−89.1	PR
6	+34.6	−63.2	−	−66.0	−79.6	PR
7	−86.2	−	−	−89.5	−89.1	SD
8	−61.3	−73.2	−61.5	−	−69.5	SD
9	+166	−28.1	−79.6	−77.7	−59.3	PR
10	−16.4	−66.8	−74.9	−82.1	−	PR
11	−86.1	−	−	−	−	
12	−5.78	−	−68.2	−	−78.9	PR
13	−15.4	−69.6	−	−	−	
14	−71.2	−	−89.3	−	−	PR
15	−59.3	−77.0	−87.3	−	−	PR
16	−31.0	−30.1	−85.2	−	−	PR
17	−35.2	−	−56.8	−	−	PR
18	−72.9	−76.3	−	−	−	
19	−50.0	−84.0	−	−	−	
20	−3.85	−46.6	−	−	−	
21	−48.7	−74.8	−	−	−	
22	−53.1	−83.6	−	−	−	
23	+1.84	−	−	−	−	
24	−18.2	−	−	−	−	
25	−36.4	−	−	−	−	
26	−51.6	−	−	−	−	
27	−26.5	−62.3	−	−	−	
28	+17.1	−	−	−	−	
29	−	−	−	−	−	
30	−42.7	−	−	−	−	
Mean	−27.7	−62.4	−66.2	−79.8	−64.3	

AZ, ablation zone; mCT, months after ablation CT; mRECIST, modified response evaluation criteria in solid tumours; CR, complete response; PR, partial response; SD, stable disease.

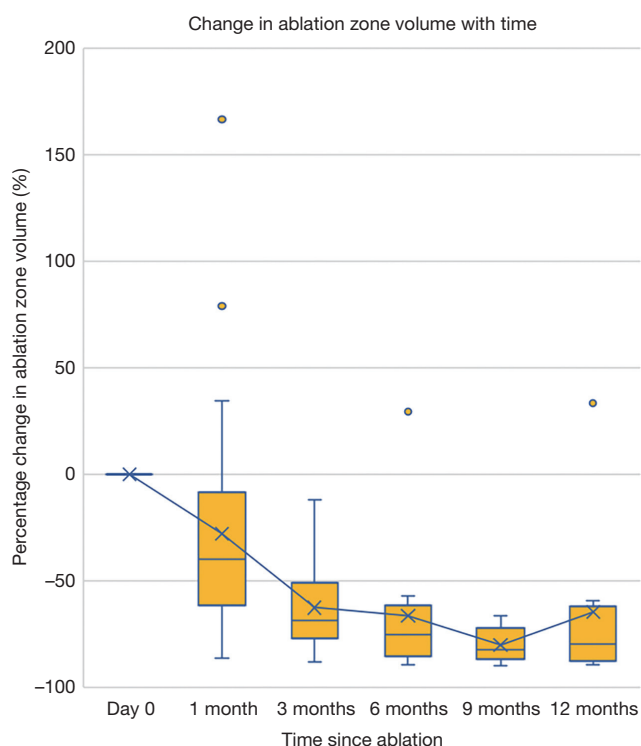


Figure 4 A box-plot showing percentage change in ablation zone from day 0 to 1 year after ablation. The rate of decrease in ablation zone volumes is initially fast and flattens out after 6 to 9 months, reaching a maximum of -79.8% at 9 months with our current data.

summarized in Table S3.

Regarding the ablation zone volumes in follow up CTs, there is a mean shrinkage of 27.8% when comparing first month CT to immediate post-ablation CT, however the variance is quite large. 60% of cases became smaller, 23.3% had static sizes. For the 10% of cases which got larger, on average there was a 93.4% increase in size, and were mostly those showing morphology of cavities. After that, the ablation zone continued to shrink, at a faster rate initially and slowing with time, eventually stabilizing in size by 9th to 12th month. In our series, compared to first month CT, ablation zone volume reduced by 66.2% at 6th month, and 64.3% by 12 months (Figure 4).

Discussion

This retrospective study has demonstrated safety and feasibility of bronchoscopic transbronchial microwave ablation in management of lung nodules. Microwave energy for lung ablation demonstrates superior properties over

its predecessor radiofrequency energy. Although both are electromagnetic energy that utilizes thermal heat to achieve tissue coagulation necrosis and cell death, radiofrequency energy induces frictional heating which occurs within only a few millimeters of the electrode, and the ablation zone size is mainly enlarged by thermal conductance, but charred and desiccated tissue surrounding the electrode increases electrical impedance (16). In contrast, microwave energy devices directly heat tissue to lethal temperatures through dielectric hysteresis (17). Being less dependent on electrical conductance, microwave energy deposition has less heat-sink effect (17), is less susceptible to tissue impedance, and is able to produce faster, larger and more predictable ablation zones (11). In our series, the presence of nearby blood vessel did not significantly affect ablation zone volumes, although a mild local reduction in ablated area can sometimes be seen in certain cases.

Percutaneous microwave ablation for lung tumours produced reasonable results, with cancer-specific survivals ranging between $69\text{--}84.3\%$ at 1 year, $42.1\text{--}61\%$ at 3 years, recurrence rate of 44% at 3 years, while median time to local tumour recurrence was between $22.6\text{--}62$ months (7,18-22). In a retrospective study comparing percutaneous microwave ablation and lobectomy for stage 1 non-small cell lung cancers (NSCLC), there was no significant difference in overall survival and disease-free survival (23).

Most of the thermal ablative techniques in literature applied the electrode in a percutaneous manner. Lately, transbronchial ablation techniques using different energy source have been researched in animal lung models (24-26). In humans, bronchoscopy-guided transbronchial ablation have been attempted by a Japanese and a Chinese group, utilizing RFA energy with reported safety (27-29). More recently, small case series of image-guided transbronchial microwave ablation of lung tumours have been reported by 2 separate groups with favourable benefit-risk profiles (30,31). Compared to percutaneous techniques, a major advantage of bronchoscopic ablation is avoidance of pleural puncture, and hence fewer pleural-based complications, including pneumothorax (6,10,32,33), bronchopleural fistulae (34) and needle tract pleural seeding (35). Another edge of bronchoscopic ablation is its ability to reach certain regions of lung which are otherwise difficult or dangerous for percutaneous route, for instance areas near mediastinal pleura or diaphragm, lung apex, and areas shielded by scapula. With evidence of safety and technical success of bronchoscopic microwave ablation in animal models (36),

the authors' institute is one of the first to have performed ENB-guided microwave ablation on patients.

Our data supports the safety of bronchoscopic ablation compared to percutaneous route. Only 2 cases (6.67%) developed pneumothorax, and one of the pneumothorax may have been avoided if the catheter had not been advanced so far in as to puncture the pleura. The other pneumothorax likely resulted from rupture of a rapidly-enlarging cavity. The ablation zone reached pleura in 66.7% of our cases, indicating that an ablated pleura, as long as not punctured, is generally safe and does not produce pneumothorax. There was only 1 case (3.33%) of pleural effusion necessitating drainage, lower than the 6–19% reported in percutaneous ablation (10). The rate of other complications, 6.67% for post-ablation reaction, 3.33% for hemoptysis/bronchopulmonary haemorrhage, and 3.33% for infective complications, were comparable to percutaneous ablation (10).

Only selective cases are suitable for bronchoscopic transbronchial microwave ablation. Numerous lung nodule ablation studies have correlated risk of local recurrence with nodule size, with cut-off of 1.5, 2 and 3 cm respectively (6,7,19). It should be noted that the typical early post-ablative morphology of concentric GGOs on CT actually contains an outer rim of denser GGO containing congested lung tissue that retains viability (37). The size seen on CT scan overestimate the area of true coagulation necrosis by 4.1 mm (38) or even up to 8–9 mm (39). Therefore, multiple authors recommended a margin of at least 5 mm on CT scan assessment to ensure adequate tumour kill (18,38,40). For the Emprint microwave catheter used in the present study, the spheroidal maximal ablation zone width is 35 mm at 100 W for 10 minutes, being derived from *in-vivo* experiments in healthy porcine lungs (Figure S6). Taking into consideration a desired margin of at least 5mm on either side of lesion, the maximal nodule size suitable for ablation should be about 25mm, unless double ablation is planned.

The actual ablation zone volumes immediately post-ablation were generally smaller by a mean of -21.4% when compared to the predicted ablation zone dimensions provided by the manufacturer. A further analysis of the one-month ablation zone volume revealed a large variance in ablation zone sizes, ranging from -86.2% to +166%. The size of tumors, solidity of nodules and the presence of nearby blood vessels were not predictive of ablation zone sizes. The predicted ablation zone dimensions were derived from manufacturer's pre-clinical study in living healthy

swine. The mismatch between predicted and actual ablation zone may be due to variations in lung properties between human and porcine lung (41), and differences in impedance and conductivity between normal lungs and tumour tissues.

It has been observed that tissue contraction occurred in most thermal ablation in different organs (16). To date only limited information on tissue contraction in human lung ablation is available. We found that contraction percentage is higher in the centre as opposed to periphery (black hole theory) (Figure 3B), but exact contraction percentage varies between individuals (Figure 3C). This may be explained by the differences in architecture and water content (16), lung nodule characteristics, and presence of surrounding blood vessels. Our findings may have significant implications on ablative margin and ultimately the technical success. By taking this phenomenon into account, clinicians may determine the ablative volume more accurately and reduce the risk of overcompensation with additional ablations.

Our study is limited by its retrospective nature, absence of parallel arm, and lack of histology for some lesions. Moreover, the contrasting effects of underestimation of ablation zone by CT due to tissue contraction and the overestimation of ablation zone by CT appearance indicates that CT is only fairly reliable in assessing and monitoring patient's response to ablation. Multi-phase contrast-enhanced CT, PET/CT and dynamic contrast-enhanced MRI are better imaging modalities (37,42) but are not employed in the current study due to their limited availability. Nevertheless, current data is encouraging and support future prospective study on bronchoscopic microwave ablation. It will also be important to investigate the key parameters affecting ablation zone size such as lung densitometry and water content measurements. Long term results including local control and survival rates are also key endpoints to observe. Combined with simultaneous intra-tumoural chemotherapy (43), or enhanced permeability and retention (EPR) effect via hyperthermia induced by ablation (44), transbronchial lung cancer ablation will likely become an important part of the armamentarium in an exciting era of personalized cancer treatment.

Conclusions

Bronchoscopic transbronchial microwave ablation is safe, feasible and potentially effective. This novel technique may represent a future treatment modality for early stage lung cancers and lung metastases. Together with ENB biopsy and intra-operative pathological evaluation, bronchoscopic

microwave ablation in the hybrid theater is capable of providing a one-stop diagnosis and treatment for suspicious lung nodules (45).

Acknowledgments

Funding: This work was supported by Research Grants Council (RGC) Hong Kong, General Research Fund (GRF) (no: 14119019). The Fund has no influence on the content of the present article.

Footnote

Reporting Checklist: The authors have completed the STROBE reporting checklist. Available at <http://dx.doi.org/10.21037/tlcr-20-1231>

Data Sharing Statement: Available at Available at <http://dx.doi.org/10.21037/tlcr-20-1231>

Peer Review File: Available at Available at <http://dx.doi.org/10.21037/tlcr-20-1231>

Conflicts of Interest: All authors have completed the ICMJE uniform disclosure form (available at Available at <http://dx.doi.org/10.21037/tlcr-20-1231>). CSHN is a consultant for Johnson and Johnson; Medtronic, USA; and Siemens Healthineer. RWHL is a consultant for Medtronic, USA; and Siemens Healthineer. TSKM has no potential conflicts of interest that exist with companies/organizations whose products or services are discussed in this article. The other authors have no conflicts of interest to declare.

Ethical Statement: The authors are accountable for all aspects of the work in ensuring that questions related to the accuracy or integrity of any part of the work are appropriately investigated and resolved. The study was conducted in compliance with the Declaration of Helsinki (as revised in 2013) and approved by local institutional review board (the Joint Chinese University of Hong Kong – New Territories East Cluster Clinical Research Ethics Committee), CREC reference number of 2020.524. All cases were discussed in multi-disciplinary meetings with oncologists' input, and all study participants gave informed consent before taking part in the study.

Open Access Statement: This is an Open Access article distributed in accordance with the Creative Commons

Attribution-NonCommercial-NoDerivs 4.0 International License (CC BY-NC-ND 4.0), which permits the non-commercial replication and distribution of the article with the strict proviso that no changes or edits are made and the original work is properly cited (including links to both the formal publication through the relevant DOI and the license). See: <https://creativecommons.org/licenses/by-nc-nd/4.0/>.

References

1. Aberle DR, Adams AM, Berg CD, et al. Reduced Lung-Cancer Mortality with Low-Dose Computed Tomographic Screening. *N Engl J Med* 2011;365:395-409.
2. Bryant AK, Mundt RC, Sandhu AP, et al. Stereotactic Body Radiation Therapy Versus Surgery for Early Lung Cancer Among US Veterans. *Ann Thorac Surg* 2018;105:425-31.
3. Puri V, Crabtree TD, Bell JM, et al. Treatment Outcomes in Stage I Lung Cancer: A Comparison of Surgery and Stereotactic Body Radiation Therapy. *J Thorac Oncol* 2015;10:1776-84.
4. Lee K, Kim HO, Choi HK, et al. Real-world treatment patterns for patients 80 years and older with early lung cancer: A nationwide claims study. *BMC Pulm Med* 2018;18:127.
5. Senthil S, Lagerwaard FJ, Haasbeek CJA, et al. Patterns of disease recurrence after stereotactic ablative radiotherapy for early stage non-small-cell lung cancer: A retrospective analysis. *Lancet Oncol* 2012;13:802-9.
6. Dupuy DE, Fernando HC, Hillman S, et al. Radiofrequency ablation of stage IA non-small cell lung cancer in medically inoperable patients: Results from the American College of Surgeons Oncology Group Z4033 (Alliance) trial. *Cancer* 2015;121:3491-8.
7. Healey TT, March BT, Baird G, et al. Microwave Ablation for Lung Neoplasms: A Retrospective Analysis of Long-Term Results. *J Vasc Interv Radiol* 2017;28:206-11.
8. Niu L, Xu K, Mu F. Cryosurgery for lung cancer. *J Thorac Dis* 2012;4:408-19.
9. Onishi H, Marino K, Yamashita H, et al. Case series of 23 patients who developed fatal radiation pneumonitis after stereotactic body radiotherapy for lung cancer. *Technol Cancer Res Treat* 2018;17:1533033818801323.
10. Hiraki T, Gobara H, Fujiwara H, et al. Lung cancer ablation: Complications. *Semin Intervent Radiol* 2013;30:169-75.
11. Brace CL, Hinshaw JL, Laeseke PF, et al. Pulmonary thermal ablation: Comparison of radiofrequency and microwave devices by using gross pathologic and CT

- findings in a swine model. *Radiology* 2009;251:705-11.
12. Harris K, Puchalski J, Sterman D. Recent Advances in Bronchoscopic Treatment of Peripheral Lung Cancers. *Chest* 2017;151:674-85.
 13. Ng CS, Zhao Z, Long H, et al. Electromagnetic Navigation Bronchoscopy Triple Contrast Dye Marking for Lung Nodule Localization. *Thorac Cardiovasc Surg* 2020;68:253-5.
 14. Zhao ZR, Lau RWH, Ng CSH. Electromagnetic navigation bronchoscopy in hybrid theater. *Front Surg* 2019;6:10.
 15. Zhao ZR, Lau RWH, Yu PSY, et al. Image-guided localization of small lung nodules in video-assisted thoracic surgery. *J Thorac Dis* 2016;8:S731-7.
 16. Kim C. Understanding the nuances of microwave ablation for more accurate post-treatment assessment. *Future Oncol* 2018;14:1755-64.
 17. Lubner MG, Brace CL, Hinshaw JL, et al. Microwave tumor ablation: Mechanism of action, clinical results, and devices. *J Vasc Interv Radiol* 2010;21:S192.
 18. Wolf FJ, Grand DJ, Machan JT, et al. Microwave ablation of lung malignancies: Effectiveness, CT findings, and safety in 50 patients. *Radiology* 2008;247:871-9.
 19. Vogl TJ, Worst TS, Naguib NNN, et al. Factors influencing local tumor control in patients with neoplastic pulmonary nodules treated with microwave ablation: A risk-factor analysis. *AJR Am J Roentgenol* 2013;200:665-72.
 20. Belfiore G, Ronza F, Belfiore MP, et al. Patients' survival in lung malignancies treated by microwave ablation: Our experience on 56 patients. *Eur J Radiol* 2013;82:177-81.
 21. Pusceddu C, Melis L, Sotgia B, et al. Usefulness of percutaneous microwave ablation for large non-small cell lung cancer: A preliminary report. *Oncol Lett* 2019;18:659-66.
 22. Ko WC, Lee YF, Chen YC, et al. CT-guided percutaneous microwave ablation of pulmonary malignant tumors. *J Thorac Dis* 2016;8:S659-65.
 23. Yao W, Lu M, Fan W, et al. Comparison between microwave ablation and lobectomy for stage I non-small cell lung cancer: a propensity score analysis. *Int J Hyperthermia* 2018;34:1329-36.
 24. Yoneda KY, Herth F, Spangler T, et al. Long-term Survival Results following Endobronchial RF Ablation in a Healthy-Porcine Model. *Annu Int Conf IEEE Eng Med Biol Soc* 2020;2020:5252-8.
 25. Sebek J, Kramer S, Rocha R, et al. Bronchoscopically delivered microwave ablation in an in vivo porcine lung model. *ERJ Open Res* 2020;6:00146-2020.
 26. Casal RF. Cone Beam CT-Guided Bronchoscopy. *J Bronchology Interv Pulmonol* 2018;25:255-6.
 27. Tanabe T, Koizumi T, Tsushima K, et al. Comparative study of three different catheters for CT imaging-bronchoscopy-guided radiofrequency ablation as a potential and novel interventional therapy for lung cancer. *Chest* 2010;137:890-7.
 28. Koizumi T, Tsushima K, Tanabe T, et al. Bronchoscopy-Guided Cooled Radiofrequency Ablation as a Novel Intervention Therapy for Peripheral Lung Cancer. *Respiration* 2015;90:47-55.
 29. Xie F, Zheng X, Xiao B, et al. Navigation Bronchoscopy-Guided Radiofrequency Ablation for Nonsurgical Peripheral Pulmonary Tumors. *Respiration* 2017;94:293-8.
 30. Lau K, Spiers A, Pritchett M, et al. P1.05-06 Bronchoscopic Image-Guided Microwave Ablation of Peripheral Lung Tumours – Early Results. *J Thorac Oncol* 2018;13:S542.
 31. Pritchett M, Reisenauer J, Kern R, et al. Image-Guided Transbronchial Microwave Ablation of Peripheral Primary Lung Tumors with a Flexible Probe: First in US Experience. *Chest* 2020;158:A1452-3.
 32. Zheng A, Wang X, Yang X, et al. Major complications after lung microwave ablation: A single-center experience on 204 sessions. *Ann Thorac Surg* 2014;98:243-8.
 33. Kashima M, Yamakado K, Takaki H, et al. Complications After 1000 Lung Radiofrequency Ablation Sessions in 420 Patients: A Single Center's Experiences. *AJR Am J Roentgenol* 2011;197:W576-80.
 34. Sakurai J, Hiraki T, Mukai T, et al. Intractable Pneumothorax Due to Bronchopleural Fistula after Radiofrequency Ablation of Lung Tumors. *J Vasc Interv Radiol* 2007;18:141-5.
 35. Hiraki T, Mimura H, Gobara H, et al. Two Cases of Needle-Tract Seeding after Percutaneous Radiofrequency Ablation for Lung Cancer. *J Vasc Interv Radiol* 2009;20:415-8.
 36. Yuan HB, Wang XY, Sun JY, et al. Flexible bronchoscopy-guided microwave ablation in peripheral porcine lung: A new minimally-invasive ablation. *Transl Lung Cancer Res* 2019;8:787-96.
 37. Chheang S, Abtin F, Guteirrez A, et al. Imaging features following thermal ablation of lung malignancies. *Semin Intervent Radiol* 2013;30:157-68.
 38. Yamamoto A, Nakamura K, Matsuoka T, et al. Radiofrequency Ablation in a Porcine Lung Model: Correlation Between CT and Histopathologic Findings. *AJR Am J Roentgenol* 2005;185:1299-306.

39. Meram E, Longhurst C, Brace CL, et al. Comparison of Conventional and Cone-Beam CT for Monitoring and Assessing Pulmonary Microwave Ablation in a Porcine Model. *J Vasc Interv Radiol* 2018;29:1447-54.
40. Anderson EM, Lees WR, Gillams AR. Early indicators of treatment success after percutaneous radiofrequency of pulmonary tumors. *Cardiovasc Intervent Radiol* 2009;32:478-83.
41. Judge EP, Hughes JML, Egan JJ, et al. Anatomy and bronchoscopy of the porcine lung: A model for translational respiratory medicine. *Am J Respir Cell Mol Biol* 2014;51:334-43.
42. Chen J, Lin ZY, Wu ZB, et al. Magnetic resonance imaging evaluation after radiofrequency ablation for malignant lung tumors. *J Cancer Res Ther* 2017;13:669-75.
43. Ueki A, Okuma T, Hamamoto S, et al. Combination therapy involving radiofrequency ablation and targeted chemotherapy with bevacizumab plus paclitaxel and cisplatin in a rabbit VX2 lung tumor model. *BMC Res Notes* 2018;11:251.
44. Golombek SK, May JN, Theek B, et al. Tumor targeting via EPR: Strategies to enhance patient responses. *Adv Drug Deliv Rev* 2018;130:17-38.
45. Chan JWY, Yu PSY, Lau RWH, et al. Hybrid operating room—one stop for diagnosis, staging and treatment of early stage NSCLC. *J Thorac Dis* 2020;12:123-31.

Cite this article as: Chan JWY, Lau RWH, Ngai JCL, Tsoi C, Chu CM, Mok TSK, Ng CSH. Transbronchial microwave ablation of lung nodules with electromagnetic navigation bronchoscopy guidance—a novel technique and initial experience with 30 cases. *Transl Lung Cancer Res* 2021;10(4):1608-1622. doi: 10.21037/tlcr-20-1231

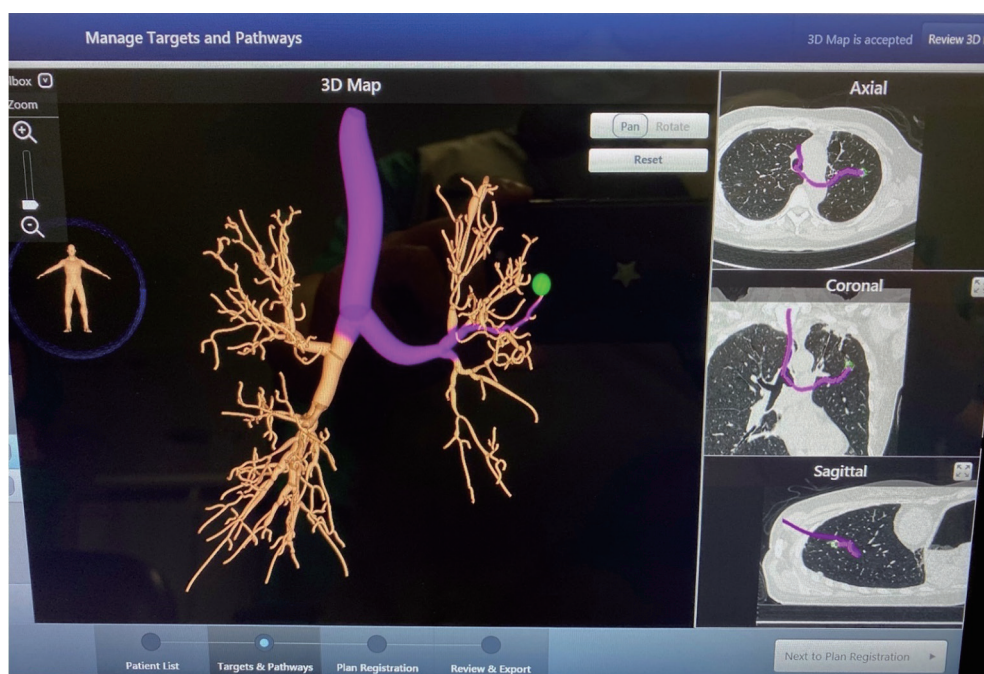


Figure S1 Figure shows the lung nodule (green ball) and the planned ENB pathway (pink route) using SuperDimension™ software.

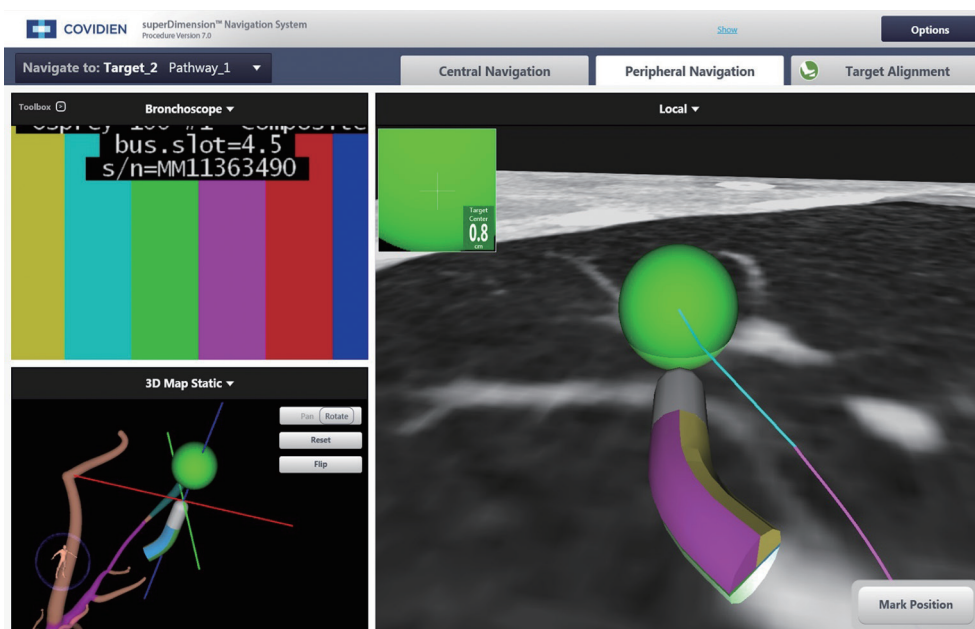


Figure S2 The right side panel shows the tip of locatable guide within 0.8cm from centre of target lesion (green ball).

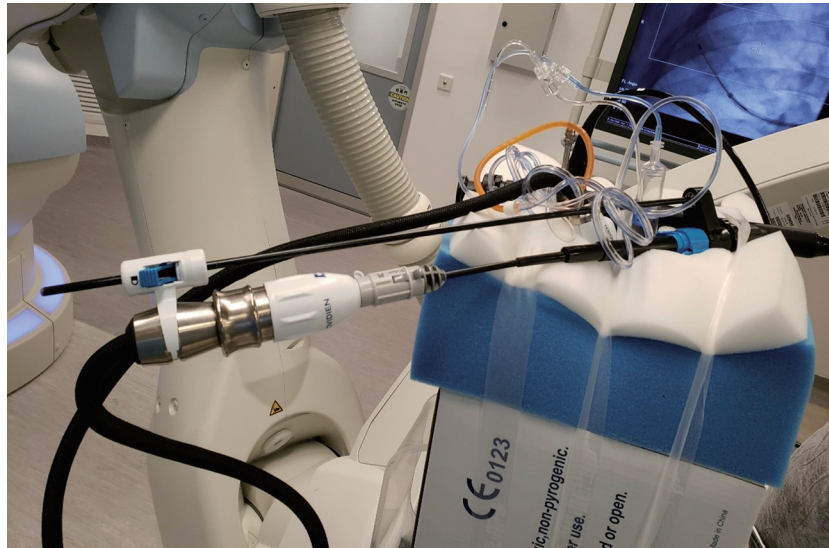

Figure S3 The microwave catheter was inserted into the extended working channel of the bronchoscope and fixed to the system with a long rod. The whole system is supported by a box and foam so that CBCT can be performed without a person holding the system.

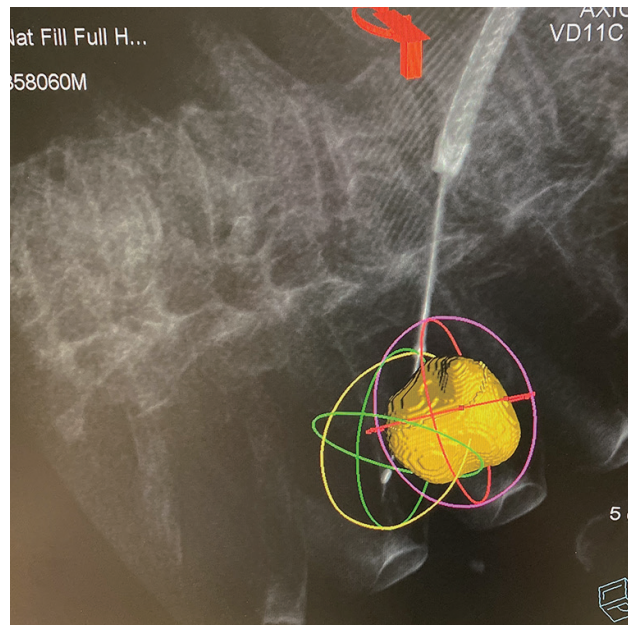


Figure S4 Figure shows a relatively large lung nodule planned for double ablation with re-navigation (bracket ablation). The two oval “cages” (yellow-green and pink-red rings) indicate the predicted ablation zones from the two ablations.

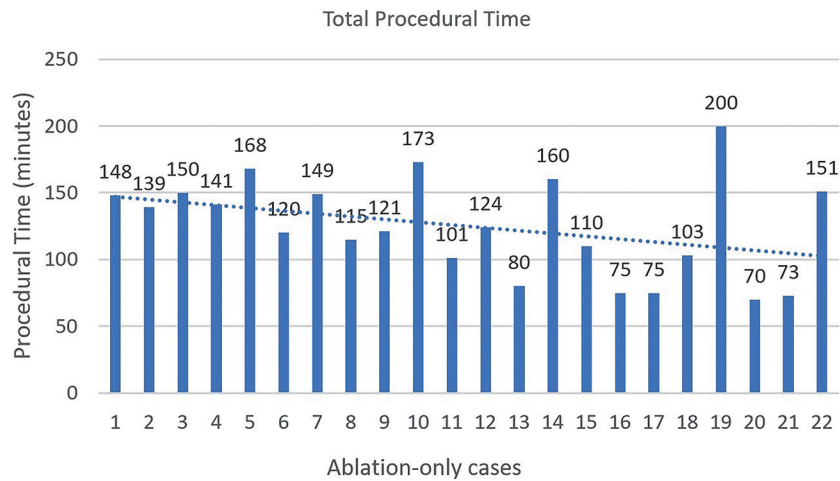


Figure S5 There was a trend towards shorter procedural time with experience.

A	45 W			75 W			100 W		
	MM:SS	B	C	MM:SS	B	C	MM:SS	B	C
1.6 cm	2:00	2.8 cm	0.6 cm						
1.9 cm	3:00	3.0 cm	0.7 cm	2:00	3.1 cm	0.8 cm			
2.2 cm	4:30	3.3 cm	0.8 cm	2:30	3.3 cm	0.9 cm			
2.5 cm	7:30	3.5 cm	0.9 cm	3:30	3.6 cm	0.9 cm	2:30	3.3 cm	0.7 cm
2.7 cm	10:00	3.6 cm	1.0 cm	4:30	3.8 cm	1.0 cm	3:00	3.5 cm	0.8 cm
2.9 cm				5:30	3.9 cm	1.1 cm	4:00	3.7 cm	0.8 cm
3.1 cm				7:00	4.0 cm	1.1 cm	5:00	3.9 cm	0.9 cm
3.3 cm				9:00	4.1 cm	1.1 cm	7:00	4.0 cm	1.0 cm
3.4 cm				10:00	4.2 cm	1.1 cm	8:30	4.1 cm	1.0 cm
3.5 cm							10:00	4.2 cm	1.0 cm

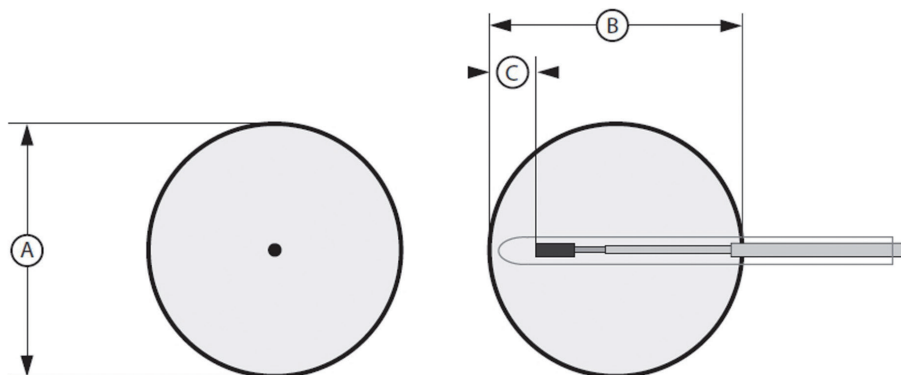


Figure S6 The upper panel shows the predicted ablation zone size provided by the manufacturer. It was developed using the ablation catheter kit in in-vivo porcine lungs. The table includes the ablation diameter (A), height (B) and distance from the tip (C) versus time for three power levels (45 watts, 75 watts and 100 watts). Time is represented as MM:SS (minutes: seconds). In the lower panel, the circular areas represent the ablation zone in cross-section, which is a spheroid shape 3-dimensionally.

Table S1 Procedural steps for ENB microwave ablation of lung nodules in hybrid operating theatre

Step	Descriptions	CBCT
1	Supine, general anesthesia, single lumen endotracheal intubation	
2	Bronchoscopic toileting	
3	Baseline CBCT at inspiratory hold	First
(4)	Lesion marked on fluoroscopy screen with iGuide (Siemens Healthineers, Germany) and 3-dimensional segmentation	
5	Registration of patient airway, verification of correct orientation with SuperDimension™ software	
6	Navigation to target lesion with ENB and/or fluoroscopic guidance.	
(7)	Transbronchial access adjuncts may be used, for example CrossCountry™ Transbronchial Access Tool (Covidien™, Plymouth, MN, USA); Soft-tip guidewires to enter small airways at an awkward angle if necessary.	
8	FNA or CrossCountry™ needle puncture of lesion, CBCT to confirm position and adjust if necessary	Second
(9)	Biopsy of lesion if indicated	
10	Exchange needle to Emprint™ microwave ablation set	
11	CBCT to confirm desirable location of catheter. Ablation energy decided with planning of predicted margin.	Third
12	Ablation performed. Fluoroscopy obtained every 3 minutes to detect any inadvertent movement of catheter. Cooling for 10 minutes	
13	CBCT at 10 minutes post-ablation with ablation catheter in-situ. Evaluation of ablation zone coverage, contraction and margin	Fourth
(14)	If ablation zone coverage suboptimal, options: 1) Repeat CBCT 10-20 minutes later and re-evaluate 2) Re-ablate at same location 3) Re-ablate after pull-back of catheter 4) Re-ablate after re-navigation via a different route	
15	Removal of ablation catheter, EWC and bronchoscope. Bronchial toileting. Extubation.	

CBCT, bone beam computer tomography scan; ENB, electromagnetic navigation bronchoscopy; FNA, fine needle aspiration. A minimum of 4 CBCT required to complete ablation. Bracketed steps are optional. The microwave output frequency is 2.45GHz ± 5MHz, the active ablation tip is 1.8cm in length and 2mm in diameter. The system is water-cooled.

Table S2 Clinical characteristics of patients and lung nodules

Case	Patient	Sex	Age (years)	CCI	Lobe	Histology	Maximum Nodule size (mm)	Suzuki Class	Comorbid or history
1	A	F	55	3	LLL	atypia	17	6	Previous LUL lobectomy for lung cancer
2	B	F	83	6	LUL	atypia	24	6	Previous RUL and RML lobectomy for lung cancer, COPD GOLD stage 2
3	C	F	69	4	RUL	AAH	16	3	Previous LUL lobectomy for lung cancer
4	D	F	69	5	LUL	NFM	10	2	Previous RUL lobectomy for lung cancer
5	E	M	77	8	LUL	atypia	22	3	COPD GOLD stage 2
6	A				RLL	adenoCA	27	5	(see patient A)
7	C				RML	atypia	15	3	(see patient C)
8	F	M	69	8	RUL	adenoCA	13	4	Sigmoid cancer with liver metastasis resected
9	G	M	59	8	LUL	n/a	13	cavitary	Previous anterior resection for rectal cancer
10	H	M	63	4	RUL	NFM	22	3	Previous LLL lobectomy for lung cancer
11	I	F	60	5	LUL	NFM	20	3	Previous RML lobectomy for lung cancer, poor lung function
12	J	M	77	6	LLL	atypia	14	6	COPD GOLD stage 2
13	K	M	86	8	RLL	adenoCA	29	6	Frail, history of stroke, dementia, previous thymectomy for thymoma
14	H				RLL	n/a	8	1	(see patient H)
15	L	F	85	6	LLL	NFM	18	3	Frail, Previous RLL lobectomy for lung cancer
16	M	M	68	8	RUL	n/a	7	6	Salvage liver transplant for liver cancer
17	N	M	74	8	RLL	atypia	16	3	Previous LUL and LLL sublobar resection for lung cancer
18	O	F	65	4	LUL	n/a	11	3	Previous LLL lobectomy for lung cancer
19	P	F	60	5	LLL	atypia	13	1	Previous RUL lobectomy and RML wedge resection for lung cancers
20	Q	M	82	7	RUL	adenoCA	15	6	Frail, Previous Hartmann operation for rectal cancer, with complicated post-operative course
21	R	F	65	4	LUL	atypia	14	1	Nasopharyngeal carcinoma with chemoradiation
22	G				LLL	n/a	9	6	(see patient G)
23	S	M	64	4	LUL	n/a	16	1	Previous RUL lobectomy for lung cancer
24	T	F	67	8	RUL	n/a	9	6	Colonic cancer with liver metastasis with primary and metastasis resected
25	T				RUL	n/a	11	6	(see patient T)
26	U	M	70	5	LLL	n/a	18	3	Previous RML lobectomy, LUL lobectomy, RLL and LLL wedge resection for lung cancer
27	V	F	66	4	RUL	NFM	10	6	Previous RML lobectomy and hemicolectomy for colonic cancer
28	W	F	73	6	RML	atypia	12	1	Previous right total hip replacement, moderate mitral stenosis
29	X	M	51	7	RML	Metastasis	19	6	Previous thyroidectomy for thyroid cancer (known lung metastasis)
30	Y	F	63	4	RUL	n/a	7	1	Previous LLL lobectomy for lung cancer

© Translational Lung Cancer Research. All rights reserved.

<http://dx.doi.org/10.21037/tlcr-20-1231>

CCI: Charlson Comorbidity Index. LUL, left upper lobe; RUL, right upper lobe; RML, right middle lobe; LLL, left lower lobe; RLL, right lower lobe. AdenoCA, adenocarcinoma; n/a, not available; NFM, negative for malignancy; AAH, atypical adenomatous hyperplasia. COPD, chronic obstruction pulmonary disease.

Table S3 Morphology of post-ablation CT at first month

	Value
GGO with air-bronchogram	
With solid component	4 (13.3%)
Without solid component	12 (40%)
GGO	5 (16.7%)
Cavity	5 (16.7%)
Solid/soft tissue pre-dominant	4 (13.3%)
Linear or triangular shaped scars	0

GGO, ground-glass opacity. Linear or triangular shaped scars are usually seen several months after successful ablation.