

# Wolf in sheep's clothing – an odontogenic keratocyst clinically masquerading as a dentigerous cyst: a case report

Rahul Mohandas<sup>^</sup>, Madhura Shekatkar<sup>^</sup>, Roopa Yadahalli<sup>^</sup>, Supriya Kheur<sup>^</sup>

Department of Oral and Maxillofacial Pathology and Oral Microbiology, Dr. D.Y. Patil Dental College and Hospital, Dr. D.Y. Patil Vidyapeeth, Maharashtra, India

**Contributions:** (I) Conception and design: R Mohandas; (II) Administrative support: S Kheur, R Yadahalli; (III) Provision of study materials or patients: M Shekatkar; (IV) Collection and assembly of data: R Mohandas, M Shekatkar; (V) Data analysis and interpretation: S Kheur, R Yadahalli; (VI) Manuscript writing: All authors; (VII) Final approval of manuscript: All authors.

**Correspondence to:** Dr. Supriya Kheur, MDS, PhD. Department of Oral and Maxillofacial Pathology and Oral Microbiology, Dr. D.Y. Patil Dental College and Hospital, Dr. D.Y. Patil Vidyapeeth, Pimpri, Pune – 18, Maharashtra, India. Email: supriya.kheur@dpu.edu.in.

**Background:** Odontogenic keratocyst (OKC) is a developmental odontogenic cyst, infamous for its aggressive nature and high recurrence rate. Sometimes, an OKC may be misdiagnosed as any other maxillofacial cyst, based on the clinical and radiological presentation, especially when present in the tooth-bearing areas. A proper clinico-radiographico-pathological diagnostic workup is crucial for a definitive diagnosis and to reduce the chances of recurrence. Here, we report a case of an OKC closely associated with an impacted maxillary right third molar, clinically and radiographically resembling a dentigerous cyst.

**Case Description:** A 28-year-old male patient complained of pain, swelling, and fluid discharge in the upper right back tooth region. The cone-beam computed tomogram revealed a well-defined, corticated cystic radiolucency that appeared to be attached to the cervical aspect of the impacted maxillary right third molar, suggestive of dentigerous cyst. Under general anaesthesia, the entire cystic lining and the impacted maxillary third molar were surgically removed using the Caldwell-Luc procedure. The histopathology was consistent with features of an OKC. There were no adverse or unanticipated events post-surgery. The patient has been kept under close follow-up and has not shown any clinical or radiographic evidence of recurrence after six months of surgery.

**Conclusions:** A complete clinical, radiographic and histopathological correlation is imperative, along with advanced molecular analysis to arrive at the final diagnosis of an OKC which can help in understanding the pathogenesis and determining the treatment plan.

**Keywords:** Odontogenic keratocyst (OKC); dentigerous cyst; odontogenic cysts; diagnosis; case report

Received: 27 September 2022; Accepted: 10 February 2023; Published online: 15 March 2023.

doi: 10.21037/fomm-22-51

**View this article at:** <https://dx.doi.org/10.21037/fomm-22-51>

## Introduction

### Background

Odontogenic keratocyst (OKC) is an enigmatic developmental odontogenic cyst, with an incredible journey of its own (1).

After its initial description as an odontogenic cyst by Philipsen in 1956, OKC was renamed Keratocystic Odontogenic Tumour (KCOT) and classified as an odontogenic tumour by World Health Organization (WHO) in 2005 (2,3). However, due to a lack of evidence of it being a

<sup>^</sup> ORCID: Rahul Mohandas, 0000-0002-0609-8219; Madhura Shekatkar, 0000-0001-5602-2717; Roopa Yadahalli, 0000-0002-0481-2095; Supriya Kheur, 0000-0002-2440-3547.

tumour, OKC was reclassified as an odontogenic cyst in 2017 (4). Clinically, they manifest as swelling with pain or may be asymptomatic (5). On radiographs, they usually appear as small or large, round to ovoid, multilocular radiolucent masses with scalloped borders (6). In some cases, an OKC may be misdiagnosed as any other maxillofacial cyst, based on the clinical and radiological presentation (7).

### ***Rationale and knowledge gap***

The WHO classification (2017) states that OKC is often present in the posterior mandible and often surrounds the crown of a third molar, resulting in an appearance mimicking a dentigerous cyst. Therefore, OKCs should be also be considered, whenever a cyst is associated with an impacted tooth. However, there is a scarcity in the number of cases reported, with only six cases having been reported till date. An accurate diagnosis of an OKC is extremely crucial due to its aggressive nature and its propensity to recur (8).

### ***Objective***

The objective of this case report is to present a case of an OKC occurring in the posterior maxillary region, associated with the cervical aspect of an impacted third molar, giving an impression of a dentigerous cyst.

This article is written following the CARE reporting

checklist (available at <https://fomm.amegroups.com/article/view/10.21037/fomm-22-51/rc>).

### ***Case presentation***

All procedures performed in this report were in accordance with the ethical standards of the institutional research board and with the Helsinki Declaration (as revised in 2013). Written informed consent was obtained from the patient for publication of this case report and accompanying images. A copy of the written consent is available for review by the editorial office of this journal.

### ***Clinical findings***

A 28-year-old male reported to the out-patient department on 12<sup>th</sup> July 2022 with a complaint of pain, swelling, and fluid discharge in the upper right back tooth region. The patient gave a history of swelling and pain in the same region, 3 years ago, which had subsided after taking a course of analgesics. The swelling had then re-appeared fifteen days prior to the current presentation.

The intraoral examination revealed a swelling measuring approximately 3 cm × 3 cm × 3 cm in the greatest dimension, causing expansion of the buccal cortical plate in the right maxillary tuberosity region. The overlying mucosa appeared normal with no signs of inflammation. The swelling was hard in consistency and tender on palpation.

### ***Radiographic findings***

The cone-beam computed tomogram revealed a well-defined, corticated cystic radiolucency that appeared to be attached to the cervical aspect of the impacted maxillary right third molar. The lesion extended from the periapical region of the maxillary right second molar region up to the posterior border of the maxilla mesiodistally. The superoinferior extension of the lesion was from the periapical region of FDI tooth number 17 up to the right maxillary sinus cavity. The lesion measured approximately 31.7 mm anteroposteriorly × 34.40 superoinferiorly × 27.89 mm buccopalatally. The interior of the lesion appeared partially isodense, and partially hypodense and showed the presence of the crown of the impacted maxillary right third molar (*Figure 1*). Based on the clinical and radiographic findings, a provisional diagnosis of dentigerous cyst was made since the cystic lesion was attached to the cervix of the tooth.

#### ***Highlight box***

##### ***Key findings***

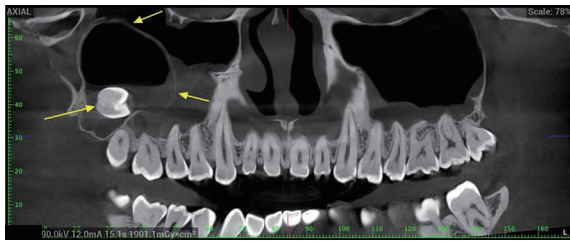
- This case report highlights an interesting case of an odontogenic keratocyst (OKC) occurring in the posterior maxillary region, associated with the cervical aspect of an impacted third molar, giving a clinical and radiographic impression of a dentigerous cyst.

##### ***What is known and what is new?***

- An OKC may be misdiagnosed as any other maxillofacial cyst, based on the clinical and radiological presentation
- Our case highlights the importance of a holistic clinical, radiographic and histopathological correlation aided by advanced molecular analysis to arrive at the final diagnosis of an OKC.

##### ***What is the implication, and what should change now?***

- Fine needle aspiration cytology of the cystic content can provide a clue of the diagnosis prior to tissue biopsy.
- Due to its aggressive and recurrent nature, OKC should be placed higher up on the list of differential diagnosis in the tooth-bearing region.



**Figure 1** A cone-beam computed tomogram of the lesion showing the radiolucent lesion (arrows) attached to the cervical portion of the impacted maxillary right third molar.

### *Surgical procedure*

Written informed consent was obtained from the patient. Under general anesthesia, the entire cystic lining and the impacted maxillary third molar were surgically removed using the Caldwell-Luc procedure. The entire specimen was sent for histopathological examination. No adverse or unanticipated events were noted post-operatively. The healing progressed regularly without any complications.

### *Gross pathology*

On gross examination, the specimen measured 4 cm × 3 cm in size, was whitish brown in colour, and soft to firm in consistency. The soft tissue was attached to the impacted tooth at the cemento-enamel junction (*Figure 2A,2B*).

### *Histopathology*

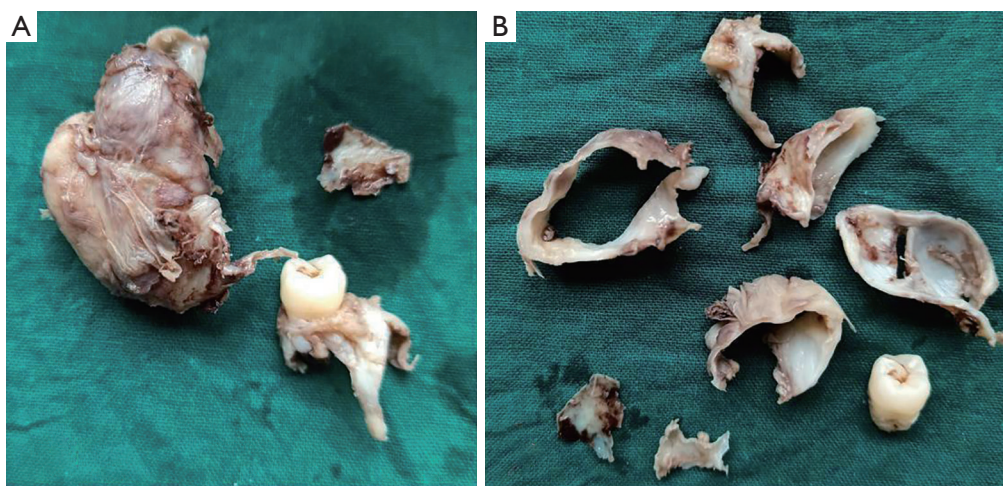
The hematoxylin and eosin-stained sections of the given specimen showed an epithelial lining and connective tissue wall (*Figure 3A*). The lining epithelium was parakeratinised stratified squamous epithelium of 6–8 cell thickness showing palisading of the basal cell layer (*Figure 3B*). The lining epithelium was corrugated and showed the presence of keratin. In places, there was a separation of epithelial lining from the underlying connective tissue wall (*Figure 3C*). The connective tissue capsule showed collagen bundles and moderate inflammatory cell infiltrate. In one area, there was evidence of a daughter cyst surrounded by intense inflammatory cell infiltration (*Figure 3D*). A histopathological diagnosis of OKC was made.

### *Follow-up*

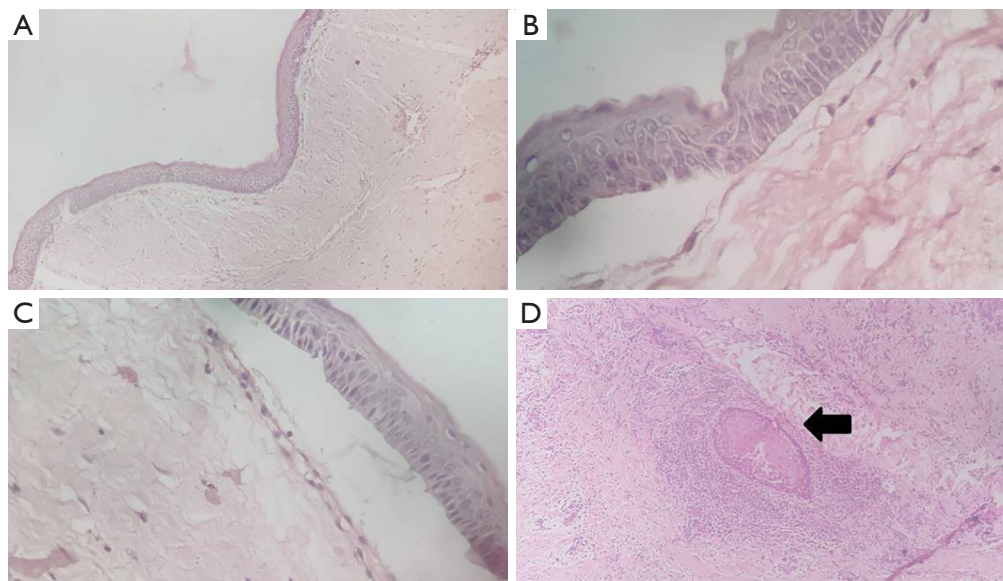
The patient has been kept under close follow-up and has not shown any clinical or radiographic evidence of recurrence after six months of surgery.

### *Literature review*

A review of the literature on OKC masquerading as the dentigerous cyst was performed. A comprehensive literature search was done using the PubMed, Medline, and Google scholar databases without any date filter. A manual search



**Figure 2** Gross picture of the received specimen (A) showing the lesion mass attached to the cervical portion of the tooth (B) showing the cystic lumen and cystic lining.



**Figure 3** Photomicrograph of the section showing (A) an epithelial lining and connective tissue wall (H&E,  $\times 10$ ), (B) the lining epithelium of 6–8 cell thickness showing palisading of the basal cell layer (H&E,  $\times 40$ ), (C) a separation of epithelial lining from the underlying connective tissue wall (H&E,  $\times 40$ ), (D) a daughter cyst surrounded by intense inflammatory cell infiltration (H&E,  $\times 10$ ). Black arrow indicates area of daughter cyst surrounded by intense inflammatory cell infiltration. H&E, hematoxylin and eosin.

was also done. MeSH terms like ‘Odontogenic keratocyst’, ‘Keratocystic Odontogenic Tumour’, ‘Dentigerous cyst’, and ‘Odontogenic cyst’ were used independently and in several combinations.

There were six case reports of OKC clinically mimicking a dentigerous cyst. The main demographic, clinical, and radiographic features of the reported cases are outlined in *Table 1*.

Six patients, including our patient, were males. The age ranged from 8 to 50 years. 83.3% of the cases involved the maxilla, including the present case. In 50% of cases, the cyst was in association with an impacted third molar. In all the cases, the radiographic findings were suggestive of a dentigerous cyst due to the proximity of the cystic lining to the cervical portion of the adjoining impacted tooth. In all the cases, the entire cyst was enucleated, along with the removal of the impacted tooth, and sent for histopathological evaluation.

## Discussion

### Key findings

The current report describes the case of a 28-year-old male

patient complained of pain, swelling, and fluid discharge in the upper right back tooth region. The radiographic features were suggestive of a dentigerous cyst associated with impacted maxillary right third molar. However, the histopathology was consistent with features of an OKC. The patient has been kept under close follow-up and has not shown any clinical or radiographic evidence of recurrence after six months of surgery.

### Strengths and limitations

Since only six cases have been reported in literature, this case is a useful addition to known documentation of an OKC clinically and radiographically mimicking a dentigerous cyst. Our report further substantiates that OKC should be placed up the order in the list of differential diagnosis, by both surgeons and pathologists, when considering similar patient findings.

A possible limitation of the present case was that fine needle aspiration cytology (FNAC) of the cystic content was not performed. An FNAC of the cystic fluid could have given a hint of the lesion. However, it was not performed to avoid a possibility of secondary infection and because of unfavourable anatomic site.



**Table 1** Demographic, clinical and radiographic features of the reported cases

Author, year	Age	Sex	Site	Radiographic findings	Impacted tooth (FDI tooth no.)
Mahireddy <i>et al.</i> , 2018 (9)	8 years	Male	Maxillary right premolar region	Large radiolucent lesion of 2 cm × 2 cm in size in relation to periapical region of 54 and 55	14, 15
Chaudhary <i>et al.</i> , 2013 (10)	11 years	Male	Left maxillary region (tooth number 22–26)	Well-defined radiolucent lesion adjoining the impacted left maxillary canine	23
Karikal <i>et al.</i> , 2018 (11)	24 years	Male	Left maxillary posterior region	Hazy radiolucent mass attached to the coronal section of impacted maxillary right third molar	18
Gunasekarana <i>et al.</i> , 2018 (12)	20 years	Male	Left mandibular posterior region	Oval shaped unilocular radiolucency partly surrounding the distal aspect of the crown of 38 and extending up to the middle third of the distal root of 38	38
Misra <i>et al.</i> , 2014 (13)	17 years	Female	Left maxillary premolar region	A diffuse radiolucency extending anteroposteriorly from the distal aspect of 24 to the distal aspect of 26	25
Shetty <i>et al.</i> , 2016 (14)	50 years	Male	Right maxillary anterior region	Radiolucency in relation to an impacted 13 and a supernumerary tooth adjacent to this radiolucent area	13

FDI, Fédération Dentaire Internationale.

### Comparison with similar researches

We searched for previously reported similar cases, and retrieved six cases. Six patients, including our patient, were males. 83.3% of the cases involved the maxilla, including the present case. In 50% of cases, including the current case, the cyst was associated with an impacted third molar. In all the cases, the entire cyst was enucleated, along with the removal of the impacted tooth, and sent for histopathological evaluation. The same treatment protocol was followed in our case.

### Explanation of findings

OKC is an odontogenic developmental cyst, infamous for its aggressive nature and high recurrence rate (15). It is commonly seen in posterior mandible, especially in the third molar region. The common clinical presentation include pain, swelling, bony expansion accompanied by gross facial asymmetry (4).

An orthopantomogram (OPG) is usually helpful in the preliminary assessment of odontogenic lesions like OKC. However, their use is limited due to two-dimensional view of the osseous structures, magnification, geometric distortion, and overlapping. Due to their ability to generate high-quality multiplanar reconstruction images, CBCT is considered superior to conventional panoramic radiography

in differentiating OKCs from other odontogenic lesions and in the pre-operative assessment. In the evaluation of odontogenic cysts, magnetic resonance imaging (MRI) is usually performed as an adjunct to CBCT in selected cases, to better demonstrate the internal features and soft tissue involvement. Diffusion kurtosis imaging (DKI) can be used as a quantitative evaluation tool to differentiate OKCs from other cystic lesions.

Histopathologically, OKC is characterized by a 6–8 cell layer thick lining epithelium composed of palisaded, polarized layer of basal cuboidal cells with hyper-chromatic nuclei, classically described as picket fence or tombstone appearance. There is also infolding of epithelium into the connective capsule by active proliferation. The connective tissue wall occasionally shows presence of daughter cysts or satellite cysts in the background of inflammatory cell infiltrate (1,10,16).

The recurrence rate of OKC ranges from 5% to 62% (17). The reasons for recurrence of OKC include (1,18–20):

- ❖ Incomplete removal of cystic lining;
- ❖ Thin and friable nature of the cystic lining;
- ❖ Higher cell proliferative activity;
- ❖ Basal cell offshoots;
- ❖ Bony perforations;
- ❖ Adherence to adjacent soft tissues;
- ❖ Weak epithelial-connective tissue interface;
- ❖ Presence of daughter cysts/satellite cysts.

Surgical management of OKC is a highly debated topic among oral and maxillofacial surgeons. The surgical treatment of OKC includes decompression, marsupilization, enucleation, and extensive resection, depending on the size of the lesion (21). Adjuvant treatment modalities like peripheral ostectomy, cryosurgery using liquid nitrogen, and chemical cauterization using Carnoy's solution have shown promising outcomes by reducing the recurrence rates (22).

A substantial number of solitary OKCs have been reported in the tooth-bearing areas, especially surrounding the third molars (23). It has been hypothesized that remnants of the dental lamina, including the distal offshoots, may be responsible for the occurrence of OKCs in relation to the third molars (24,25). An alternate theory involving the role of submucosal hamartias has also been proposed, especially in the OKCs located in the retromolar area of the mandible and the maxillary tuberosity (18).

### ***Implications and actions needed***

Occasionally, an OKC may clinically appear as any other odontogenic cyst in relation to an unerupted tooth. As the clinico-radiographic diagnosis of any circumscribed radiolucent cystic lesion surrounding the crown of an impacted tooth is usually a dentigerous cyst, it was not unusual in the present case as well. The histopathological examination of the cyst fitted well in favor of an OKC, thus, the possibility of considering this as a dentigerous cyst with a keratinized lining epithelium was ruled out. This case further substantiated the importance of a thorough histopathological examination for arriving at a definitive diagnosis. Moreover, FNAC can provide an evidence of OKC, prior to the excisional biopsy. Due to its aggressive and recurrent nature, OKC should be placed higher up on the list of differential diagnosis in the tooth-bearing region.

### **Clinical relevance**

OKC warrants for an aggressive treatment approach compared to any other cyst in the maxillofacial region, owing to its propensity to recur. Through this case report, we wish to raise the awareness about importance of histopathological examination of the incisional biopsy and FNAC for the definitive diagnosis of OKC.

### **Conclusions**

The diagnosis of an OKC is challenging, especially when it masquerades as any other odontogenic cyst enveloping the crown of the impacted tooth. A complete clinical, radiographic and histopathological correlation is imperative, along with advanced molecular analysis to arrive at the final diagnosis of an OKC which can help in understanding the pathogenesis and determining the treatment plan.

### **Acknowledgments**

*Funding:* None.

### **Footnote**

*Reporting Checklist:* The authors have completed the CARE reporting checklist. Available at <https://fomm.amegroups.com/article/view/10.21037/fomm-22-51/rc>

*Peer Review File:* Available at <https://fomm.amegroups.com/article/view/10.21037/fomm-22-51/prf>

*Conflicts of Interest:* All authors have completed the ICMJE uniform disclosure form (available at <https://fomm.amegroups.com/article/view/10.21037/fomm-22-51/coif>). The authors have no conflicts of interest to declare.

*Ethical Statement:* The authors are accountable for all aspects of the work in ensuring that questions related to the accuracy or integrity of any part of the work are appropriately investigated and resolved. All procedures performed in this report were in accordance with the ethical standards of the institutional research board and with the Helsinki Declaration (as revised in 2013). Written informed consent was obtained from the patient for publication of this case report and accompanying images. A copy of the written consent is available for review by the editorial office of this journal.

*Open Access Statement:* This is an Open Access article distributed in accordance with the Creative Commons Attribution-NonCommercial-NoDerivs 4.0 International License (CC BY-NC-ND 4.0), which permits the non-commercial replication and distribution of the article with

the strict proviso that no changes or edits are made and the original work is properly cited (including links to both the formal publication through the relevant DOI and the license). See: <https://creativecommons.org/licenses/by-nc-nd/4.0/>.

## References

- Nayak MT, Singh A, Singhvi A, et al. Odontogenic keratocyst: What is in the name? *J Nat Sci Biol Med* 2013;4:282-5.
- Scirp.org [Internet]. Philipsen, H.P. (1956) OM Keratocyster. Available online: <https://scirp.org/reference/referencespapers.aspx?referenceid=1811033>
- Thompson L. World Health Organization classification of tumours: pathology and genetics of head and neck tumours. *Ear Nose Throat J* 2006;85:74.
- Sabarinath B, Prottyusha GB, Dhanarathna S, et al. The Odontogenic Keratocyst Conundrum- Is There an Answer? *Iran J Pathol* 2022;17:108-9.
- Osterne RL, Brito RG, Alves AP, et al. Odontogenic tumors: a 5-year retrospective study in a Brazilian population and analysis of 3406 cases reported in the literature. *Oral Surg Oral Med Oral Pathol Oral Radiol Endod* 2011;111:474-81.
- MacDonald-Jankowski DS. Keratocystic odontogenic tumour: systematic review. *Dentomaxillofac Radiol* 2011;40:1-23.
- Borghesi A, Nardi C, Giannitto C, et al. Odontogenic keratocyst: imaging features of a benign lesion with an aggressive behaviour. *Insights Imaging* 2018;9:883-97.
- Mendes RA, Carvalho JF, van der Waal I. Characterization and management of the keratocystic odontogenic tumor in relation to its histopathological and biological features. *Oral Oncol* 2010;46:219-25.
- Madhireddy MR, Prakash AJ, Mahanthi V, et al. Large Follicular Odontogenic Keratocyst affecting Maxillary Sinus mimicking Dentigerous Cyst in an 8-year-old Boy: A Case Report and Review. *Int J Clin Pediatr Dent* 2018;11:349-51.
- Chaudhary S, Sinha A, Barua P, et al. Keratocystic odontogenic tumour (KCOT) misdiagnosed as a dentigerous cyst. *BMJ Case Rep* 2013;2013:bcr2012008741.
- Karikal A, Shetty T, Kudthadka A. Odontogenic keratocyst masquerading as a dentigerous cyst in the maxilla: A case report of an unusual presentation. *Eur J Ther* 2018;121-5.
- Gunasekaran N, Annasamy R, Jayant VS, Krishnan R. Orthokeratinized odontogenic cyst mimicking as dentigerous cyst – case report. *International Journal of Scientific Research* 2018;7:69-70.
- Misra D, Misra A, Rai S, Malik R. Cone-beam computed tomographic illustration of an unusual position of keratocystic odontogenic tumor mimicking a dentigerous cyst: A case report. *Journal of Indian Academy of Oral Medicine and Radiology* 2014;26:187.
- Shetty DC, Rathore AS, Jain A, et al. Orthokeratinized odontogenic cyst masquerading as dentigerous cyst. *Int J Appl Basic Med Res* 2016;6:297-9.
- Mengji AK, Yaga US, Besta R, et al. Keratocystic odontogenic tumor involving the maxillary antrum with displacement of the third molar: A rare case report. *Journal of Indian Academy of Oral Medicine and Radiology* 2014;26:335.
- Eryilmaz T, Ozmen S, Findikcioglu K, et al. Odontogenic keratocyst: an unusual location and review of the literature. *Ann Plast Surg* 2009;62:210-2.
- Giovacchini F, Bensi C, Paradiso D, et al. Factors influencing the recurrence of keratocysts: monocentric study. *J Oral Med Oral Surg* 2020;26:1.
- Stoelinga PJ. Long-term follow-up on keratocysts treated according to a defined protocol. *Int J Oral Maxillofac Surg* 2001;30:14-25.
- Tarakji B, Baroudi K, Hanouneh S, et al. Possible recurrence of keratocyst in nevroid basal cell carcinoma syndrome: A review of literature. *Eur J Dent* 2013;7:S126-34.
- Fidele NB, Yueyu Z, Zhao Y, et al. Recurrence of odontogenic keratocysts and possible prognostic factors: Review of 455 patients. *Med Oral Patol Oral Cir Bucal* 2019;24:e491-501.
- Vijayarangan S, Baskara Pandian V. Management of the Odontogenic Keratocyst - Six Cases with Conservative Management Supported by Chemical and Electrochemical Cauterization. *Cureus* 2019;11:e6260.
- Al-Moraissi EA, Dahan AA, Alwadeai MS, et al. What surgical treatment has the lowest recurrence rate following the management of keratocystic odontogenic tumor?: A large systematic review and meta-analysis. *J Craniomaxillofac Surg* 2017;45:131-44.
- Slusarenko da Silva Y, Stoelinga PJW, Naclério-Homem MDG. The presentation of odontogenic keratocysts in the jaws with an emphasis on the tooth-bearing area: a

- systematic review and meta-analysis. *Oral Maxillofac Surg* 2019;23:133-47.
24. Stoelinga PJ, Peters JH. A note on the origin of keratocysts of the jaws. *Int J Oral Surg* 1973;2:37-44.
25. Stoelinga PJ. Studies on the dental lamina as related to its role in the etiology of cysts and tumors. *J Oral Pathol* 1976;5:65-73.

doi: 10.21037/fomm-22-51

**Cite this article as:** Mohandas R, Shekatkar M, Yadahalli R, Kheur S. Wolf in sheep's clothing—an odontogenic keratocyst clinically masquerading as a dentigerous cyst: a case report. *Front Oral Maxillofac Med* 2024;6:20.