



Mediastinal lymph node dissection in open thoracic surgery

Nikolaos Kostoulas, Kostas Papagiannopoulos

Department of Thoracic Surgery, St. James's University Hospital, Leeds, UK

Contributions: (I) Conception and design: All authors; (II) Administrative support: All authors; (III) Provision of study materials or patients: All authors; (IV) Collection and assembly of data: All authors; (V) Data analysis and interpretation: All authors; (VI) Manuscript writing: All authors; (VII) Final approval of manuscript: All authors.

Correspondence to: Kostas Papagiannopoulos, MMED THORAX, MD, CTH. Department of Thoracic Surgery, St. James's University Hospital, Bexley Wing, Level 3, Beckett St, LS9 7TF, Leeds, UK. Email: k.papagiannopoulos@nhs.net.

Abstract: Nodal staging is well established in management of lung cancer. Hence, any lung resection should be combined with dissection of at least 3 nodal stations. Open access is gained via thoracotomy. The lymphadenectomy should precede lung resection. Station 2 is dissected by extending the planes from Station 4 superiorly. The left side demands special maneuvers and remains challenging. The recurrent nerve should be protected and therefore diathermy needs to be avoided in this position. Station 4 is routinely dissected on right side and rarely on left. Trachea, azygos vein and superior vena cava (SVC) define the dissection triangle. Special attention is required to tributaries from SVC and aberrant chyle duct branches to avoid complications when dissecting this nodal station. Station 5 is defined by the arch and main pulmonary artery roof. The commonest complication is recurrent nerve injury; hence, dissection should be gentle with no use of diathermy at the proximity of the vagus nerve close to the arch. Lateral dissection towards the arch, offers access to Station 6. Attention should be exercised to avoid injury to an aberrant superior intercostal vein. Station 7 becomes evident following the main bronchus to the carinal origin. Main attention to bronchial arteries should be exercised at the floor of the carina or descending aorta tributaries on the left to avoid disturbing bleeding. Clips and not diathermy should be used. Moderate bleeding is managed with packing and patience. Station 8 lies adjacent to esophagus. Gentle dissection is required to avoid esophageal and thoracic duct injuries. Station 9 is contained in the inferior pulmonary ligament and is dissected at hilar mobilisation. Attention to fat pad mediastinal vessel is mandatory.

Keywords: Lung cancer; lymphadenectomy; cancer staging

Received: 04 August 2017; Accepted: 16 August 2017; Published: 22 August 2017.

doi: 10.21037/shc.2017.08.09

View this article at: <http://dx.doi.org/10.21037/shc.2017.08.09>

Introduction

The importance of mediastinal lymph nodal involvement in lung cancer patients has been identified since 1978, when the first anatomic map for lymph node stations was published by Naruke. In 1997 an updated and detailed map was suggested by Mountain and Dresler and is the one that still remains in use, showing that there is a worldwide consensus on the nomenclature and the fact that they are an important descriptor in the staging process of lung cancer (1-3).

However, such consensus is not evident on the procedure that should be employed during lung resections, in order

to obtain the most possible information of lymph node involvement and provide an accurate, final, postoperative, pathological N stage for non-small cell lung cancer. There is an evident long term dispute in the literature between the supporters of complete lymphadenectomy versus sampling (4,5). Equally, discussions remain whether a surgeon should perform lymphadenectomy in every mediastinal station or should follow a lobe-dependent approach, in order to decrease the internal operative trauma (6). At the moment, the gold standard for the treatment of non-small cell lung cancer is lung resection combined with complete lymph node dissection of at least 3 mediastinal (N2) stations (7,8).

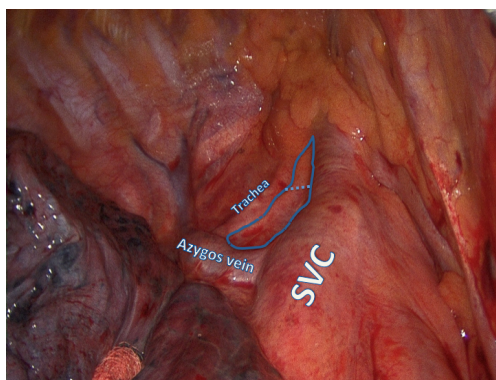


Figure 1 The dissection triangle containing the right paratracheal nodes is marked with the blue line. The dotted line defines arbitrary division between R2 and R4. Please note that the trachea, the SVC and the azygos vein are the boundaries of the nodal packet. The dissection should be cautious at SVC to avoid bleeding of tributaries and superiorly to avoid injury to the innominate artery. SVC, superior vena cava.

Operative technique

The traditional thoracotomy provides excellent access for an extensive lymph node dissection. The timing is a subject of discussion but we advocate lymphadenectomy prior to lung resection for the following reasons:

- (I) Suspected lymph nodes can be subjected to intra operative frozen section and alter the surgical management in certain Institutions (9);
- (II) Prior lymphadenectomy offers a superb dissection of the hilum with identification and separation of all hilar structures;
- (III) Provision of a ‘clean’ operating field for safe ligation and transection of hilar structures;
- (IV) Safeguards margins and eliminates disputes between surgeons and pathologists;
- (V) Allows *en bloc*, clean resection of nodes and fat pads providing the best specimens for pathological examination.

Lymphadenectomy

General aspects

The preparation of the patient, incision and access to hilum and mediastinum have already been described in other chapters.

For the sake of completeness, the following safety features apply to each patient undergoing lymphadenectomy:

- (I) Appropriate exposure with good lung isolation;
- (II) Prior complete adhesiolysis with exposure of hilum and mediastinum;
- (III) A ‘dry’ field with good prior hemostasis as blood pools in the most dependent areas which are perihilar and mediastinal;
- (IV) A sound knowledge of anatomy of mediastinum.

Technique description

Station 2

This station is also called “upper paratracheal” and it is usually dissected at the same time with Station 4 or by extending the dissection planes from Station 4 superiorly (Figure 1). For right sided resections the access is easier following the groove between the trachea and the superior vena cava (SVC), although on the left side the aortic arch obscures the surgeon’s view and special maneuvers need to be employed.

The assistant retracts the lung inferiorly. The pleura is incised lateral to the phrenic nerve and at the superior border of the azygos vein or aortic arch for right or left approach respectively. The fat tissue is grasped elegantly with fenestrated forceps or plain forceps and is dissected bluntly from the tracheal wall and surrounding structures. Diathermy is discouraged in this area as right sided dissection comes close to the right recurrent laryngeal nerve. Bleeding is avoided by clipping small arterial branches to the lymph nodal pad and avoiding injury to small draining veins that connect directly to the SVC on the right side. Small bleeds should be treated with simple gauze packing while other jobs are done in the chest. In the majority of cases no further action is required and hemostatic agents are available but rarely necessary.

Station 4

This station is also called “lower paratracheal”. For a right approach the access is easy, but on the left the exposure is obstructed completely by the aortic arch and dissection on the left side is not routinely performed.

The lung is retracted inferiorly. The pleura is incised around the anterior and superior hilum, so that the azygos vein is separated from the pulmonary artery, lying inferiorly. The lower margin of Station 4 is identified below the proximal segment of the azygos vein resting posterolaterally to the SVC. The lymph nodes are dissected bluntly with a peanut or the suction catheter away from the azygos vein and SVC and away from the right main

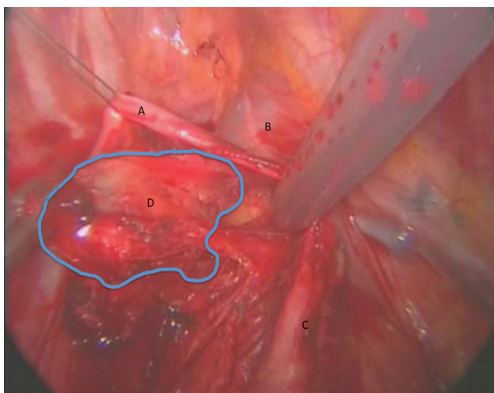


Figure 2 Another technique of retrieving right paratracheal nodes is dissection below the azygos vein. In this picture, the azygos has been retracted with a stitch through the chest wall to provide extra assistance and an obstructed view. (A) Azygos vein; (B) SVC; (C) phrenic nerve; (D) right paratracheal nodal tissue.

pulmonary artery (*Figure 2*).

The detachment from the artery may be facilitated by opening the arterial sheath, so at the same time the surgeon can assess any possible involvement of the pulmonary artery. The use of diathermy is not encouraged in this area, because of close proximity to major vascular structures. However, an energy device can facilitate the dissection without blood loss, maintaining clear dissection planes. This part of the station can be either removed at this stage or left aside and retracted from above the azygous vein for the next stage of dissection.

Hemostasis follows the same principles as described for station 2. Quite often these 2 stations are taken *en bloc* and an arbitrary division is performed by scissors. The specimens are placed in separate pots to be examined by a pathologist.

We generally advocate the use of clips and high energy devices to avoid injury to major vessels and the right recurrent nerve. Additionally, a clean dissection reduces the risk of an ‘annoying’ chyle leak, experienced when aberrant thoracic duct branches are disrupted but not ligated.

Station 5

We find this station only in the left chest cavity. It is also called “subaortic” and is located between the aortic arch and the left main pulmonary artery, just laterally to the ligamentum arteriosum (aortopulmonary window).

The assistant retracts the lung inferiorly while the surgeon opens the pleural reflection at the superior border

of the hilum. It is advisable to commence dissection by staying in close proximity of the left main pulmonary artery and identify the vagus nerve. The fat pad is gradually detached, vagal branches are clipped and no diathermy is used to avoid injury to the left recurrent laryngeal nerve. The dissection always keeps the roof of the vagus nerve as a pivot point and ascends as it comes to close proximity of the aortic arch. Quite often a ‘button’ of parietal pleura is sacrificed in order to perform a complete undisrupted dissection of the nodal fat pad.

Any minor bleeding is attended by gauze packing.

Station 6

It is also called “para-aortic” and is located adjacent to the lateral wall of the ascending aorta and aortic arch and its dissection is usually performed at the same time with the Station 5.

The dissection is a true continuation of the Station 5 lymph nodal pad. Injury to the left vagus should be avoided as it lies on the aortic arch and anterior dissection should protect the left phrenic nerve as well.

Station 7

This station is also called “subcarinal”.

Station 7 is deeply embedded in the posterior mediastinum and access is impossible or challenging without prior appropriate homework from the surgeon.

Regardless of side of operation the pleural reflection on the posterior hilum needs to be dissected. The vagus nerve is identified and all hilar branches are individually identified and ligated. This maneuver offers two advantages:

- (I) Prevents any bleeding from bronchial tributaries;
- (II) Allows the ligatures to retract the vagus with the posterior mediastinum offering a good exposure.

On the left side, the proximal descending aorta reduces further the operating field and at times it needs to be retracted.

The main bronchus remains the pivot point on both sides. As soon as the nodes are identified the dissection concentrates on the inferior aspect of the main bronchus. The retraction of the nodes should be gentle and they should not be disrupted. Anteriorly the nodal pad is dissected from the posterior pericardium. There are generally no vessels of concern in that territory.

At the posterior aspect, the nodal pad needs to be dissected from the esophagus (*Figure 3*). We advocate the use of clips and no diathermy as the esophagus is an elegant structure and thermal injuries should be avoided with the

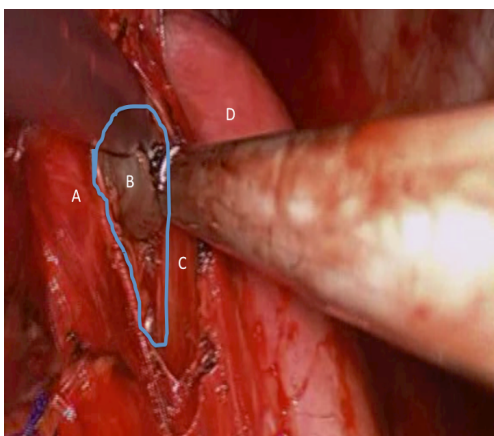


Figure 3 In this figure, the reader can appreciate the dissection for the subcarinal nodes from the left side. Please note that diathermy should be used with caution next to the esophagus to avoid injury. Large bronchial vessels directly from the descending aorta might cause significant bleeding and they should be clipped before the subcarinal nodes are detached from the surrounding tissues. Minor bleeding is best attended with initial packing and patience. (A) Bronchial stump; (B) subcarinal node; (C) esophagus; (D) descending aorta.

generous use of diathermy. If in doubt, the surgeon should ask the anesthetist to introduce a large bore nasogastric tube or an esophageal bougie. Such maneuver will stent and state better the esophagus in the operating field. Identification is then easier in case of significant fibrosis and difficulty in identifying the correct dissection planes.

As soon as the true subcarinal area is reached care should be taken to clip the subcarinal bronchial vessels. For dissections performed on the background of inflammatory disease or bulky lymphadenopathy such vessels can be large and significant bleed might be encountered which is difficult to control at times due to the proximity of the vessels to the carina.

The reader should remember that the subcarinal dissection exposes the membranous part of the airways. This is subject to injuries as pressure is also applied endobronchially with the double lumen tube.

In case of a wet field, gauze packing is the answer again. The worst mistake is to control bleeding in a confined space with limited dissection and visibility.

In extreme circumstances, a period of apnoea with the bronchial cuff deflated might offer the extra volume required in the operating field to take care of the bleeding.

The subcarinal space should be routinely packed for a few minutes while other jobs are done. The use of haemostatic agents is rarely necessary.

Station 8

This station is also called “paraesophageal” and is including the lymph nodes that lie adjacent to the esophagus in each side, between the level of the bronchus and the diaphragm.

This is again a continuation of the previously described dissection of the posterior mediastinum and subcarinal nodes. This time the dissection identifies the paraesophageal nodal pad just inferior to the subcarinal nodes and simply follows the esophagus until the pad is lifted off with gentle dissection and use if clips.

Again, the protection of the esophagus is of paramount importance. Additionally, the dissection should remain on the boundaries of the nodal pad to avoid injury to the thoracic duct leading to a chyle leak. For this reason, the separation of this nodal station from the mediastinum should ideally be performed mainly with blunt dissection and use of clips or ligation.

Station 9

This station is also called “inferior pulmonary ligament node”, as it is lying inside the attachment of the pulmonary ligament to the mediastinum, between the inferior pulmonary vein (IPV) and the diaphragm on each side.

The lung is retracted superiorly and the ligament is transected initially with diathermy or a high energy device. Blunt dissection will then reveal the nodes within the pleural reflection and these should be dissected with the fat pad and part of the inferior pulmonary ligament until the floor of the IPV is identified (*Figure 4*).

This area has limited blood supply and bleeds are rarely encountered except the posterior attachments with the mediastinum and the close proximity to the IPV. The reader should remember that clips at the floor of the IPV should be avoided as subsequent stapling of the vein during lung resection can lead to stapler failure and catastrophic bleed.

General comments and advice

A meticulous lymph node dissection does not cure cancer but streamlines cancer treatment by offering accurate staging. Evidence shows that there is significant upstaging in patients who underwent total lymphadenectomy in comparison to those who had lymph node sampling. Hence, these patients can be offered adjuvant treatment with potential improvement in their long-term prognosis. Taking this into consideration, surgeons should be capable of offering their patients a safe, complete lymph node

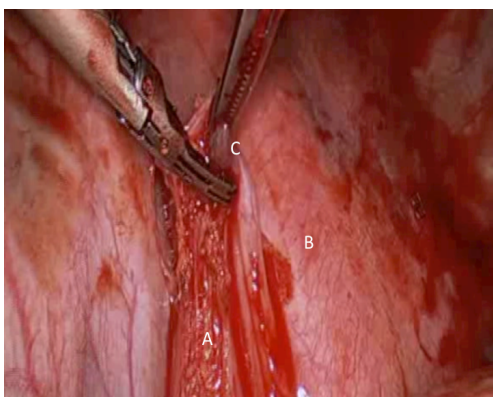


Figure 4 It is essential that the underlying mediastinum following dissection of the inferior pulmonary ligament should be checked for any bleeding prior to closing the thoracotomy. (A) Dissected inferior pulmonary ligament; (B) descending aorta; (C) left 9 lymph nodes.

dissection without compromising patient safety.

The reader should keep in mind the following tips:

- ❖ In any nodal station, the surgeon should follow the landmarks surrounding the nodes, to facilitate a dry dissection;
- ❖ The technique of ligation instead of diathermy dissection keeps the field dry, protects surrounding tissues from potential thermal injuries and reduces the incidence of postoperative chyle leak from lymphatic vessels;
- ❖ The recurrent laryngeal nerve should be protected in lymphadenectomy of Stations 2 in the right side and 5 in the left side, especially in cases that there are no preoperative findings suggestive of involvement in these stations, so that a potential injury can justify the final disability;
- ❖ In patients with mediastinal lymphadenopathy and neoadjuvant treatment, the operating field might be hostile. The dissection should follow natural reflections and the soft flat structures, i.e., esophagus will need to be identified with special maneuvers to avoid injury (use of bougie or large nasogastric tube);
- ❖ Metal clips are a good choice for ligating small feeding vessels at surgery. They assist in an accurate dissection but are future markers if adjuvant radiotherapy is required.

Acknowledgments

Funding: None.

Footnote

Provenance and Peer Review: This article was commissioned by the Guest Editors (Marco Scarci, Alan D.L. Sihoe and Benedetta Bedetti) for the series “Open Thoracic Surgery” published in *Shanghai Chest*. The article has undergone external peer review.

Conflicts of Interest: Both authors have completed the IC-MJE uniform disclosure form (available at <http://dx.doi.org/10.21037/shc.2017.08.09>). The series “Open Thoracic Surgery” was commissioned by the editorial office without any funding or sponsorship. The authors have no other conflicts of interest to declare.

Ethical Statement: The authors are accountable for all aspects of the work in ensuring that questions related to the accuracy or integrity of any part of the work are appropriately investigated and resolved.

Open Access Statement: This is an Open Access article distributed in accordance with the Creative Commons Attribution-NonCommercial-NoDerivs 4.0 International License (CC BY-NC-ND 4.0), which permits the non-commercial replication and distribution of the article with the strict proviso that no changes or edits are made and the original work is properly cited (including links to both the formal publication through the relevant DOI and the license). See: <https://creativecommons.org/licenses/by-nc-nd/4.0/>.

References

1. Harisinghani MG. Atlas of Lymph Node Anatomy. New York: Springer, 2013:31-56.
2. Watanabe S. Lymph node dissection for lung cancer: past, present, and future. *Gen Thorac Cardiovasc Surg* 2014;62:407-14.
3. El-Sherief AH, Lau CT, Wu CC, et al. International association for the study of lung cancer (IASLC) lymph node map: radiologic review with CT illustration. *Radiographics* 2014;34:1680-91.
4. Dong S, Du J, Li W, et al. Systematic mediastinal lymphadenectomy or mediastinal lymph node sampling in patients with pathological stage I NSCLC: a meta-analysis. *World J Surg* 2015;39:410-6.
5. Doddoli C, Aragon A, Barlesi F, et al. Does the extent of lymph node dissection influence outcome in patients with stage I non-small-cell lung cancer? *Eur J Cardiothorac*

- Surg 2005;27:680-5.
6. Adachi H, Sakamaki K, Nishii T, et al. Lobe-Specific Lymph Node Dissection as a Standard Procedure in Surgery for Non-Small Cell Lung Cancer: A Propensity Score Matching Study. *J Thorac Oncol* 2017;12:85-93.
 7. Lardinois D, De Leyn P, Van Schil P, et al. ESTS guidelines for intraoperative lymph node staging in non-small cell lung cancer. *Eur J Cardiothorac Surg* 2006;30:787-92.
 8. Whitson BA, Groth SS, Maddaus MA. Surgical assessment and intraoperative management of mediastinal lymph nodes in non-small cell lung cancer. *Ann Thorac Surg* 2007;84:1059-65.
 9. Li W, Yang XN, Liao RQ, et al. Intraoperative frozen sections of the regional lymph nodes contribute to surgical decision-making in non-small cell lung cancer patients. *J Thorac Dis* 2016;8:1974-80.

doi: 10.21037/shc.2017.08.09

Cite this article as: Kostoulas N, Papagiannopoulos K. Mediastinal lymph node dissection in open thoracic surgery. *Shanghai Chest* 2017;1:22.