



# Procedure of uniportal intercostal bullectomy for pneumothorax and its indications: a clinical practice review

Yuki Nishioka<sup>^</sup>, Daisuke Hokka, Yoshimasa Maniwa

Department of Thoracic Surgery, Kobe University Hospital International Clinical Cancer Research Center, Kobe, Hyogo, Japan

*Contributions:* (I) Conception and design: Y Nishioka; (II) Administrative support: None; (III) Provision of study materials or patients: None; (IV) Collection and assembly of data: None; (V) Data analysis and interpretation: None; (VI) Manuscript writing: All authors; (VII) Final approval of manuscript: All authors.

*Correspondence to:* Daisuke Hokka, MD, PhD. Department of Thoracic Surgery, Kobe University Hospital International Clinical Cancer Research Center, 1-5-1, Minatojima-Minamimachi, Chuo-ku, Kobe 650-0047, Hyogo, Japan. Email: dhokka@med.kobe-u.ac.jp.

**Abstract:** Uniportal video-assisted thoracoscopic surgery (VATS), which is predominantly performed with an intercostal approach, has been gaining popularity as a less invasive surgical treatment for bullectomy. With the widespread use of this procedure, the number of reports on surgical outcomes has increased. With the advent of the transareolar or subxiphoid approach, there is an increasing need to discuss the indications for these approaches in order to establish evidence. Therefore, we aimed to summarize the intercostal procedures of uniportal VATS for pneumothorax and discuss the favorable indications for this approach. In terms of indications, the pneumothorax size of the patients treated by surgery has not been elucidated and needs to be clarified for the indication. Considering the indications and outcomes of uniportal intercostal VATS, the presence of bullae may be a favorable indication for the procedure. Additionally, initial surgery for pneumothorax is the preferable indication, since pleural adhesion was an exclusion criterion for performing uniportal VATS. To reduce invasiveness, postoperative prolonged air leakage should be minimized, and the causes should be investigated. Each approach has its own advantages owing to anatomical differences. The distribution of the responsible lesions can be an indication for these approaches. Both the transareolar and intercostal approaches allow for resection of the apex of the lung. The intercostal approach can be superior to the other two approaches for resecting posterior lesions. From the perspective of cosmesis and invasiveness, a transareolar approach may reduce the involvement of the intercostal nerve and it can be performed without any recognizable scarring. The subxiphoid approach eliminates the involvement of the intercostal nerve and offers favorable access to the bilateral thoracic cavity. An intercostal approach can cause intercostal nerve involvement, but the incision used for the placement of the preoperative drain tube in the lateral thorax can also be used as an operative incision with this approach. Moreover, this approach allows for the easy exploration of the whole lung in order to avoid overlooking any bullae, and its lateral decubitus position is favorable when an additional incision is needed in the case of unexpected situations, such as adhesion.

**Keywords:** Pneumothorax; bullectomy; uniportal video-assisted thoracoscopic surgery; intercostal approach

Received: 31 March 2023; Accepted: 07 July 2023; Published online: 19 July 2023.

doi: 10.21037/vats-23-30

**View this article at:** <https://dx.doi.org/10.21037/vats-23-30>

<sup>^</sup> ORCID: 0000-0002-8324-4865.

## Introduction

### Background

As a surgical treatment for spontaneous primary pneumothorax, the British Thoracic Society Guidelines describe video-assisted thoracoscopic surgery (VATS) as acceptable because of the 5% recurrence rate when it is performed with pleurectomy compared to open thoracotomy (1). In 2018, the German S3 guidelines described VATS as the recommended surgical approach for pneumothorax (2). In search of procedures with reduced invasiveness, Yamamoto *et al.* first introduced uniportal VATS for pneumothorax in 1998 (3). Uniportal VATS has been performed via an intercostal approach. In 2016, to reduce invasiveness and improved cosmesis, other uniportal approaches, such as the subxiphoid and transareolar approaches, were introduced (4,5).

### Rationale and knowledge gap

There are no guidelines regarding the uniportal approach as a surgical approach for primary spontaneous pneumothorax. Uniportal VATS for pneumothorax has been reported to have comparable recurrence rates and surgical outcomes. A retrospective study on uniportal VATS for pneumothorax involving 351 patients indicated that the recurrence rate was 3.6% at 2 years of follow-up (6). A propensity-matched study and a prospective randomized trial of uniportal and multiportal VATS for pneumothorax indicated that uniportal VATS for pneumothorax was less invasive than multiportal VATS in terms of postoperative pain and cosmetic satisfaction (7,8).

A prospective study found that the transareolar approach resulted in comparable postoperative pain and better cosmetic satisfaction than the intercostal approach (9). Another study comparing the uniportal intercostal and subxiphoid approaches reported less postoperative pain in the subxiphoid group than in the intercostal group (10). On comparing the postoperative pain among uniportal intercostal VATS, three-port VATS, and a subxiphoid approach, the subxiphoid approach was associated with significantly lower levels of postoperative pain than the other approaches (11). A propensity score-matched study showed that arrhythmia occurred among the patients with the subxiphoid approach (12).

Three approaches are currently available for uniportal VATS: the intercostal, transareolar and subxiphoid approaches. The feasibility of each technique has been

reported previously. Among these approaches, the uniportal intercostal approach has long been used, but it has not yet been regarded as a standard approach. To establish evidence supporting the uniportal approach for pneumothorax, reviewing the procedure of the intercostal approach and current knowledge on both the surgical outcomes and indications is essential. With the advent of the subxiphoid and transareolar approaches, the need to discuss the indications of these approaches is increasing. Therefore, reconfirming the procedures and indications of this approach may help to clarify the differences in the indications for each approach.

To our knowledge, no review has discussed the indications for uniportal VATS for pneumothorax using these three approaches.

### Objective

The present report summarizes the intercostal procedures of uniportal VATS for pneumothorax and discusses favorable indications for this approach compared with the subxiphoid and transareolar approaches.

### Methods

A literature search was performed in the PubMed database (from 1995 to 2022). Articles on the intercostal approach, subxiphoid approach and transareolar approach were searched with the following keywords: [pneumothorax AND (“Video-assisted thoracoscopic surgery” OR “VATS” OR thoracoscopic) AND (uniportal OR “single-incision” OR “single-incisional” OR “single-port”)], [(subxiphoid) AND (pneumothorax)] and [(transareolar) AND (pneumothorax)].

The inclusion criteria were as follows: primary spontaneous pneumothorax treated by surgery; resection of the bullae and blebs by a stapler under VATS with or without additional treatment; uniportal VATS of the intercostal, subxiphoid, or transareolar approach; literature written in English; and literature provided as a full article. We excluded studies that were not relevant to this research, as well as case reports on the intercostal approach, letters, editorial comments, reviews and meta-analyses.

The data reviewed were as follows: the use of preoperative computed tomography (CT), the indication and exclusion criteria, and the operative outcome (resected part of the lung, incision size, port placement, additional procedure, conversion rate, complication, paresthesia and recurrence).

## Results

Among a total of 148 studies without duplication, 27, 6 and 3 studies used the intercostal, subxiphoid and transareolar approaches, respectively.

Among the studies on the intercostal approach, three included secondary spontaneous pneumothorax, which accounted for 3.5–25% of the cases (6,13,14). A study found that 3.5% of the population had catamenial pneumothorax (6). In two studies, bilateral pneumothorax was found in the population (3.7–5.4%) (15,16). One randomized trial was included (8).

The indications for uniportal VATS in the literature are shown in *Table 1*. The indications included one of the following: ipsilateral or contralateral recurrence, persistent air leakage (PAL), bilateral pneumothorax, hemothorax or abnormal findings in radiological exams, including the existence of bullae and blebs. The indications were not described in four studies (13,17,18,24). Bilateral pneumothorax was included as an indication in three studies (8,15,16). Three studies included age as an inclusion factor (19,21,29). Three studies included cases with collapsed lungs; however, but data on the extent of collapse were not available (29,31,34). The exclusion criteria for uniportal VATS included one of the following: trauma, prior thoracic surgery, suspicious pleural adhesion and underlying lung disease. In addition, one study excluded patients with no bullae (31).

The operative outcomes of the intercostal approach are shown in *Table 2*. The resected lesions in the upper lobe comprised 95.7–100%, and those in the lower lobe comprised 0–38.6% (6,7,13,15–17,21,23,25,26,28,33). The reason for the conversion included adhesion in all studies (6,16,18,21,23,34,36). In addition, the location and leakage after resection were mentioned in previous studies (16,34). In another study, endometriosis and empyema were included as reasons for conversion (6). Three studies mentioned that there was adhesion, but no conversion was required (16,17,26).

The surgical outcomes of the transareolar uniportal VATS are shown in *Table 3*. Among the three studies on the transareolar approach, two referred to the resected part of the lung (5,37). A prospective study reported the conversion rate, and there was no conversion among the transareolar group of patients (9). No report described the frequency of postoperative paresthesia.

Among the studies on the subxiphoid approach, three case reports, one of which was a case series on the subxiphoid approach and included one case of bilateral pneumothorax,

and all of the resected parts of the lungs were lesions in both upper lobes (4,38,39). Three other studies compared the subxiphoid approach with the intercostal approach (10–12). One of these was a randomized controlled trial of 43 patients (10); 6 bilateral pneumothorax patients were included in this study. A propensity score-matched study was included (12); 7 patients with bilateral pneumothorax patients were included in this study. A comparison of the surgical outcomes of the subxiphoid approach to intercostal uniportal VATS in the three comparative studies is shown in *Table 4*. No conversion was needed in two studies, which included 14 patients and 32 patients (11,12). None of these three comparative studies described the resected part. All studies reported that the subxiphoid approach required a longer operative time than the intercostal approach (10–12). The complication rate was 21.8%, consisting of arrhythmic events during surgery (12).

## Discussion

### *Surgical procedure for the intercostal approach*

The procedure was performed under general anesthesia and single-lung ventilation with the patient in the lateral decubitus position.

### Incision

In terms of the incision, the anterior axial line may be favorable based on the notion that the intercostal space (ICS) is broader in the anterior part of the chest wall than in the posterior part (7). In our experience in Japan, better maneuverability is obtained when the incision is placed in the 5th or 6th ICS, as the distance between the target lesion and the incision becomes closer when the incision is placed on the 4th ICS. Considering the sum of the diameters of each instrument (scope, grasper and stapler), an incision size of up to 2.5 cm appears to be an important criterion for selecting the uniportal VATS for pneumothorax. When the drainage tube is placed for drainage prior to surgery, extending the incision is thus an option to consider.

### Instruments

A wound protector was used to obtain a larger working space, to protect the surrounding tissue, including the nearby intercostal nerve, and avoid interfering with the view of the scope lens. This results in the shortening of the superfluous operative time. To minimize the size of the incision, a 5-mm thoracoscope is essential. In our experience, a 5-mm thoracoscope can provide a sufficient

**Table 1** Indications for uniportal VATS for pneumothorax in the literature

Author	Preoperative CT	Indications	Exclusions
Jutley, 2005 (13)	–	–	–
Salati, 2008 (17)	–	–	–
Berlanga, 2011 (18)	–	–	–
Chen, 2011 (19)	–	PAL, R, age [15–40]	L, S, T
Chen, 2012 (20)	–	PAL, R, H	–
Yang, 2013 (15)	Yes	PAL, R	–
Igai, 2014 (21)	–	Age ( $\leq 40$ )	L, S, H
Kang, 2014 (22)	Yes	PAL, R, B	–
Son, 2015 (23)	–	PAL, R, B	A, L, T
Tsuboshima, 2015 (24)	Yes	–	–
Yamazaki, 2015 (25)	–	PAL, R	–
Song, 2015 (16)	–	PAL, R, B, bilateral	L, S
Chong, 2016 (26)	Yes	PAL, R, B	A
Jeon, 2016 (27)	Yes	PAL, R, bilateral	S
Ocakcioglu, 2016 (28)	–	PAL, R, B	L, S, T
Masmoudi, 2017 (6)	Yes	PAL, R,	**
Jung, 2017 (29)	Yes	PAL, R, B, age (<30)	L, S
Al-Githmi, 2018 (30)	–	R	–
Nachira, 2018 (7)	–	PAL, R	–
Kutluk, 2018 (8)	–	PAL, R, bilateral*	Age (<18, >40), L, S, T
Akçay, 2019 (14)	Yes	PAL, R	S
Zhang, 2020 (31)	Yes	PAL, R, B	A, L, S***
Kapicibasi, 2020 (32)	Yes	PAL, R, B	L
Fiorelli, 2021 (33)	–	PAL, R	L, S, T
Yoshikawa, 2021 (34)	–	PAL, R, B	Age (>40), S****
Lee, 2022 (35)	–	PAL, R, B	–
Wang, 2022 (36)	–	PAL, R, H, B	L, S

Age was presented in years. \*, radiological findings; \*\*, large apical bullae; \*\*\*, the absence of the bullae on the preoperative chest computed tomography; \*\*\*\*, simultaneous bilateral surgery. VATS, video-assisted thoracoscopic surgery; CT, computed tomography; PAL, prolonged air leakage; R, recurrence; H, hemothorax; B, the existence of bullae on chest X-ray or computed-tomography; bilateral, bilateral pneumothorax; L, underlying lung diseases; S, prior thoracic surgery; T, trauma; A, adhesion.

view to perform the procedure, and is preferable for obtaining a broader space for incision or minimizing the length of the incision. A thoracoscope was placed at the upper edge of the incision, which provided a surgical overview from the top to the resected areas when the scope was lateralized (40). Instrument resistance may induce

inadvertent compression of the intercostal nerve and result in paresthesia. Therefore, sterile lubricant jelly should be applied to the instruments to increase the smoothness. Inserting the camera through the incision before the insertion of other instruments enables contamination of the scope lens with the superfluous jelly to be avoided.

**Table 2** Surgical outcomes of intercostal uniportal VATS for pneumothorax

Author, year	Case numbers	Location of the resected lesions		Incision size (cm)	Port placement (ICS, anatomical line)	Operative outcomes			
		Upper lobe	Lower lobe			Conversion rate (%)	Paresthesia (%)	Postoperative PAL (%)	Recurrence (%)
Jutley, 2005 (13)	16	100	0	2–2.5	5th*	–	14.0	0	0
Salati, 2008 (17)	28	100	0	2.5	5th, MAL	0	35.0	3.5	10.0
Berlanga, 2011 (18)	13	100	0	2.5	6th, MAL	7.7	23.1	0	–
Chen, 2011 (19)	10	–	–	2.5	4–6th**	–	–	–	–
Chen, 2012 (20)	36	–	–	1.5	5th, AAL or 6th, MAL	0	–	0	3.0
Yang, 2013 (15)	27	96.3	3.7	2.5	5th, MAL	0	33.3	3.8	3.8
Igai, 2014 (21)	44	97.7	38.6	2.5–3.0	5th or 6th, AAL	2.3	–	–	–
Kang, 2014 (22)	33	–	–	2.1	5th, AAL	0	9.0	–	–
Son, 2015 (23)	104	100	0	<2	4th or 5th, AAL	2.9	33.3	2.9	0.9
Tsuboshima, 2015 (24)	34	–	–	1.98	6th, MAL	–	–	–	11.8
Yamazaki, 2015 (25)	100	100	0	2	7th, MAL	0	–	1.0	4.0
Song, 2015 (16)	37	97.2	16.2	2.5	4–6th, MAL	0	–	5.4	5.4
Chong, 2016 (26)	52	100	5.8	–	6th, MAL	0	–	0.9	3.8
Jeon, 2016 (27)	40	–	–	1.15	5th, MAL	–	10.0	2.5	5.0
Ocakcioglu, 2016 (28)	37	100	0	2.0–2.5	5th or 6th, MAL	0	–	0	0
Masmoudi, 2017 (6)	351	100	0	1.5–2	6th, –	5.5	29.3	12.9	3.6
Jung, 2017 (29)	111	–	–	2	5th, MAL	–	–	–	12.6
Al-Githmi, 2018 (30)	22	–	–	2.5*	5th, AAL	–	–	0	0
Nachira, 2018 (7)	23	95.7	–	2–4	4–5th, MAL	0	0	0	0
Kutluk, 2018 (8)	45	–	–	2–2.5	5–7th, MAL	–	–	11.1	4.4
Akçay, 2019 (14)	29	–	–	2	7th, MAL	–	–	–	2.2
Zhang, 2020 (31)	79	–	–	1.5	–	0	–	3.8	0
Kapicibasi, 2020 (32)	46	–	–	–	5th, MAL	–	47.0	10	2.0
Fiorelli, 2021 (33)	21	100	0	2–2.5	5th, AAL	0	47.6	–	0.0
Yoshikawa, 2021 (34)	161	–	–	2.5–3	5th or 6th, AAL	2.5	–	0	2.5
Lee, 2022 (35)	139	–	–	1.5	5th, MAL	0	–	0	3.5
Wang, 2022 (36)	56	–	–	2.5	4th, AAL	3.6	28.6	3.6	3.4

\*, the length was originally described as 1 inch; \*\*, the wound for the preoperative chest tube. VATS, video-assisted thoracic surgery; ICS, intercostal space; PAL, prolonged air leakage; MAL, mid-axillary line; AAL, anterior axillary line.

**Table 3** Surgical outcomes of transareolar uniportal VATS for pneumothorax

Variables	Lin, 2016 (5)	Yazawa, 2020 (37)	Igai, 2021 (9)
Study design	T	T	T vs. I
Case numbers (T vs. I)	112, –	10, –	21 vs. 19
Location of the resected lesions (%)			
Upper lobe	100	100	–
Lower lobe	4.5	0.0	–
Operative time (minutes)	26.5	39.8±8.6	39±7.5 vs. 36±10**
Blood loss	–	Small amount	Minimal
Conversion rate (%)	0	–	0
Complications, n (%)	Pneumonia, 9 (8.0)	0 (0)	0 (0)
Duration of chest tube drainage (days)	3.6	1	1 vs. 1
Postoperative hospital stays (days)	2 or 3 (95.5%); 4 or 5 (4.5%)	2	2 vs. 2
Cosmetic satisfaction, mean ± SD	3.0±0.8, VRS on discharge	3.3, score <sup>†</sup> on POD7	3.5±0.6 vs. 2.9±0.9*, score <sup>†</sup> on POD7
Pain, mean ± SD	Mild (2.31±0.66) in 24 patients; moderate (5.66±0.57) in 2 patients, VAS on discharge	1.5, NRS on POD7	1.8±0.9 vs. 1.6±0.9**, NRS on POD7
Recurrence, n (%)	0 (0)	0 (0)	0 vs. 1 (5.3)
Key conclusion	Feasible	Feasible	T > I
Reasons	Cosmesis	Satisfaction with pain and cosmesis	Cosmetic satisfaction

<sup>†</sup>, cosmetic satisfaction score (1, poor; 2, not bad; 3, good; 4, excellent). \*, statistically significant (P<0.05); \*\*, statistically non-significant (P≥0.05). VATS, video-assisted thoracic surgery; T, the transareolar approach; I, the intercostal approach; VRS, verbal response scale (1, dissatisfied; 2, accepted; 3, satisfied; 4, perfect); NRS, numerical rating scale (0–10); POD, postoperative day; VAS, visual analog scale; SD, standard deviation.

The other instruments used included a curved grasper and a roticulating stapler. It is recommended that the two instruments be curved to avoid interference of the instruments inside and outside the thoracic cavity and to secure a good surgical view. After insertion of a thoracic scope, inspecting the whole lung is mandatory to ensure that the responsible bullae and blebs are not overlooked (41).

### Arrangement

Various techniques have recently been introduced in efforts to reduce invasiveness, achieve better cosmetic results, and to make uniportal VATS easier to adopt. Minimizing the incision length has been introduced to improve the invasiveness and cosmetic outcomes. As an alternative to a grasper, an additional suture was inserted at another ICS in addition to the initial incision. In six reports, a suture to retract the lung was inserted in addition to the initial incision. Son *et al.* reported that uniportal VATS with an

anchoring suture was feasible and safe (23). Chong *et al.* reported that their tower crane technique was feasible (26). Jeon *et al.* reported that pain was lessened the day after surgery in the uniportal group but it was not markedly different after discharge from the conventional group (27). Zhang *et al.* reported that a small (<2 cm) original incision with an anchoring suture was safe and feasible (31). Fiorelli *et al.* used additional sutures with sponges on the lung and reported that the technique reduced paresthesia compared to the conventional approach (33). Lee *et al.* used a spinal needle to retract the lung and reported that the technique was safe and easy (35).

Eliminating the insertion of the grasper into the incision also resulted in greater instrument maneuverability. Tsuboshima *et al.* reported a feasible technique that did not use a suture passed through the chest wall (24). This procedure is called the pulley for lung excision (pulLE) method. In this method, a suture was placed on the parietal pleura in the



**Table 4** Comparison of the surgical outcomes of the subxiphoid approach to intercostal uniportal VATS for pneumothorax

Variables	Li, 2016 (10)	Wang, 2016 (11)	Chen, 2019 (12)
Study design	S vs. I	S vs. I	S vs. I
Case numbers (S vs. I)	22 vs. 21	14 vs. 26	32 vs. 32
Bilateral pneumothorax, n (%)	6 (27.3) vs. 6 (28.6)	1 (7.1) vs. 0 (0)	7 (21.8) vs. 5 (15.6)
Operative time (minutes), mean $\pm$ SD	Unilateral: 44.38 $\pm$ 5.21 vs. 27.53 $\pm$ 3.77*; bilateral: 74.17 $\pm$ 5.81 vs. 51.18 $\pm$ 3.71*	61.07 $\pm$ 15.96 vs. 48.65 $\pm$ 10.37*	80.47 $\pm$ 27.04 vs. 57.31 $\pm$ 34.95*
Blood loss (mL)	–	10.00 $\pm$ 0.00 vs. 10.38 $\pm$ 1.96**	–
Conversion rate (%)	–	0 vs. 0	0 vs. 0
Complications, n (%)	–	0 vs. 1 (3.85)	7 (21.8) vs. 0 (0)*
Pain on POD 1, VAS scores, mean $\pm$ SD	Unilateral: 1.37 $\pm$ 0.50 vs. 3.0 $\pm$ 0.84*; bilateral: 1.66 $\pm$ 0.51 vs. 3.0 $\pm$ 0.63*	1.15 $\pm$ 0.69 vs. 1.64 $\pm$ 0.99*	–
Pain on POD 3, VAS scores, mean $\pm$ SD	Unilateral: 0.12 $\pm$ 0.34 vs. 0.66 $\pm$ 0.48*; bilateral: 0.33 $\pm$ 0.51 vs. 1.16 $\pm$ 0.40*	0.00 $\pm$ 0.00 vs. 0.00 $\pm$ 0.00	–
Duration of chest tube drainage, mean $\pm$ SD	2.86 $\pm$ 0.46 vs. 2.86 $\pm$ 0.47**	1.29 $\pm$ 0.47 vs. 1.50 $\pm$ 1.48**	–
Hospital stays (days), mean $\pm$ SD	4.59 $\pm$ 0.59 vs. 4.76 $\pm$ 0.54**	2.14 $\pm$ 0.53 vs. 2.38 $\pm$ 1.33**	5.53 $\pm$ 3.17 vs. 5.22 $\pm$ 3.23**
Recurrence, n (%)	1 (4.6)	–	1 (3.1) vs. 0
Key conclusions	S $\geq$ I	S > I	S $\geq$ I
Reasons	Pain	Pain	Bilateral surgery

In that study, three groups were compared, including the subxiphoid single port, the transthoracic single port and two transthoracic two ports. Therefore, the P values are those of the Krus-Wallis test (11). \*, statistically significant ( $P < 0.05$ ); \*\*, statistically non-significant ( $P \geq 0.05$ ). VATS, video-assisted thoracic surgery; S, the subxiphoid approach; I, the intercostal approach; POD, postoperative day; VAS, visual analog scale; SD, standard deviation.

third ICS, and the incision size was shortened. The operative time was 67.9 minutes in this group and 62.5 minutes in the conventional 3-port group, a non-significant difference.

At our institution, we use a needle grasper (Suture GrasperTM; Mediflex, Islandia, New York, USA) inserted into the 3rd ICS in addition to the initial incision. The grasper has a 14-gauge in outer diameter. The initial incision is placed at the 5th ICS. With this grasper, the caudal vicinity of the target bulla is retracted. After the lung was grasped, the parenchyma is compressed using the tissue forceps. The surgical view is shown in *Figure 1*.

#### Additional treatment

Additional treatment is recommended to reduce the postoperative recurrence in VATS for pneumothorax (41). Options includes mechanical pleurodesis (pleurectomy or pleural abrasion), chemical pleurodesis by talc poudrage and covering of the staple line with a material such as

polyglycolic acid sheet (42). However, the optimal surgical treatment remains controversial.

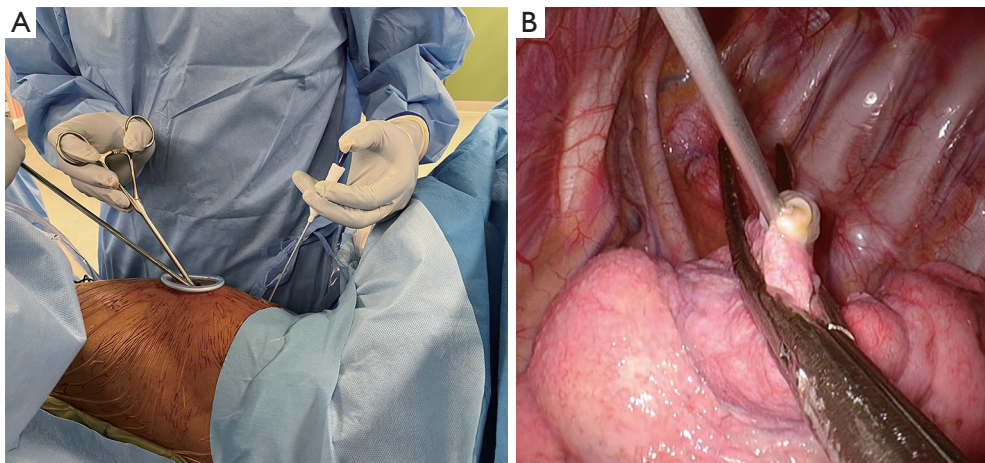
#### Learning curve

Uniportal VATS uses a different axis from multi-port VATS (43). Therefore, hand-eye coordination is required for both the operator and the assistant, who manipulates the thoracoscope. With the development of instruments and standardization of the procedure, a consensus was reached. For uniportal VATS lobectomy, at least 50 cases of experience are required (44).

#### Indications

#### Surgical treatment

The guidelines recommend that the extent of the collapse be considered to determine the subjects most suited for surgical treatment (2). Conservative treatment is reported to



**Figure 1** The procedure of uniportal VATS bullectomy: intercostal approach. (A) Surgical view: the incision is made in the 5th ICS at the anterior axial line. Tissue forceps is inserted through the incision. A needle grasper (Suture Grasper™; Mediflex, Islandia, New York, USA) is inserted in the 3rd ICS. The scope is placed at the upper edge of the incision. (B) The intrathoracic view: a needle grasper holds the caudal edge of the target bulla. The parenchyma is compressed with forceps before stapling. VATS, video-assisted thoracoscopic surgery; ICS, intercostal space.

be noninferior to interventional treatment (45). Our review found no literature describing the details of the extent of the collapse. This suggests that in the literature, such intervention, namely carrying out preoperative drainage with a chest tube, may have been performed based on different criteria described in the guidelines.

Routine CT for pneumothorax is not recommended, but abnormal findings in the lung, such as bullae and blebs, are regarded as factors associated with recurrence (2). A multicenter randomized trial concluded that the presence of bullae is a favorable indication for surgery compared with chest tube drainage (46). On preoperative CT, suspected bullae and blebs were detected, which were presumed to be the responsible lesions. Ten studies performed preoperative CT, one of which excluded patients who were candidates for uniportal VATS when no bullae were detected (31). In cases with PAL, the leakage point tends to be easily identified during surgery; however, but in cases of ipsilateral recurrence without intervention, preoperative information is needed. Therefore, the presence of suspicious blebs or bullae can be a useful indication for a uniportal approach among surgical candidates. In addition, preoperative confirmation of pleural adhesion eliminates the possibility of conversion, as the main cause of conversion was shown to be adhesion.

In the literature reviewed, postoperative PAL occurred in 0–12.9% of patients as a complication of uniportal VATS

for pneumothorax. The feasibility of uniportal VATS is widely reported to be similar to that of conventional VATS (47,48); however, this result prompts us to reconsider the indications. With adhesion and prior thoracic surgery being reasons to avoid the uniportal approach, the initial surgery is a favorable opportunity to practice the uniportal approach. Reducing complications, such as PAL, is essential for reducing invasiveness, whereas reducing postoperative pain and improving cosmesis are important aspects of a low invasiveness. We need to determine why PAL occurs using the uniportal approach in order to establish favorable indications. Uniportal VATS without postoperative PAL is an optimal, minimally invasive approach.

### Intercostal approach

The intercostal approach is performed with the patient in the lateral decubitus position. Thus, the main advantage of the intercostal approach is easier conversion to a multiportal approach because of unexpected thoracic findings (e.g., adhesion and difficulty in finding the point of leakage). The conversion rate was 0–7.7%, and the main reason for this was adhesion in the intercostal approach. VATS was performed with the intercostal approach. This universality of VATS results in safety in the surgical field and easier conversion in the uniportal approach. Moreover, this approach allows for the easy exploration of the whole lung to avoid overlooking any bullae. Third, the availability



of the prior incision used for chest tube drainage is another advantage of the intercostal approach. This may contribute to an acceptable cosmesis in patients with a preoperative drainage tube when surgery is performed with a slightly enlarged incision in the chest tube via the intercostal approach.

### Transareolar approach

Four anatomical advantages of this approach have been noted (5). The ICS is broader at the anterior chest wall than at the lateral chest wall, and the tissue around the areola is thin. This results in better maneuverability of the instruments. The intercostal nerves are scarce in the anterior chest wall, which may result in less postoperative paresthesia. Furthermore, the operative scar becomes unrecognizable. This leads to better satisfaction with the approach. With regard to the surgical procedure, surgery with this approach was performed in the semi-sitting position. Although no patients with bilateral pneumothorax were included in the study, the authors speculated that the application of this approach in bilateral bullectomy would be feasible.

Contraindications for this approach exist for to anatomical reasons: female patients due to the presence of mammary glands and obese patients due to the thickness of the subcutaneous fat tissue. Yazawa *et al.* noted that an insufficient view of the posterior portion is a disadvantage of this approach and thus improved it (37). With the patient in the lateral decubitus position, they used the original incision of the drainage tube in the 5th ICS as an access port for a thoracic scope to cover the insufficient posterior surgical view. The original transareolar approach was applied to resect lesions in the upper and lower lobes. The modified transareolar approach enabled the secure inspection of the lung; however, in that report, the resected lesions were located at the apex of the lung. These advantages of the transareolar approach overlap with those of the intercostal approach.

### Subxiphoid approach

A study that compared the uniportal intercostal and subxiphoid approaches showed that there was less postoperative pain in the subxiphoid group than in the uniportal intercostal group (10). In this study, approximately 30% of the patients had bilateral pneumothorax. They pointed out that the subxiphoid approach had the disadvantage of insufficient access to the posterior lesion. Bullae were often detected in the upper part of the lung,

including the lower lobe. Anatomically, the top of the lower lobe is located in the posterior part of the lung. However, they did not describe the localization of the resected lesions.

Regarding perioperative complications, no arrhythmic events were observed in that study (11). However, in another study comparing the subxiphoid and the three-port intercostal approaches, the patients treated with the subxiphoid approach experienced more arrhythmia events than those treated with the intercostal approach (12). In this procedure, the authors utilized a sternal retractor to lessen the compression of the heart and obtain a surgical space. Anatomically, the existence of the heart may cause restriction of the working space in the surgical treatment of left-sided pneumothorax (10-12). The pain on postoperative day 1 was less in the subxiphoid group than in the intercostal group; however, on postoperative day 3 and after, when the postoperative chest tube was removed, the pain was not different (11). The authors described that this decreased pain might be due to the lack of involvement of the intercostal nerve. Notably, in terms of the operative outcomes, the subxiphoid approach required a longer operative time for both unilateral surgery and bilateral surgery (10).

## Summary

The advantages and disadvantages of each approach are presented in *Table 5*. Anatomically, the intercostal, transareolar and subxiphoid approaches differ in terms of the involvement of the intercostal nerve. This may result in the discrepant frequencies of postoperative paresthesia among the approaches. In addition, the satisfaction with cosmesis may differ among the approaches. The intercostal approach is therefore advantageous in regard to patient safety.

### Strengths and limitations

No comprehensive review has discussed the indications for the uniportal approach. This review has several limitations. First, the literature was searched from one database; therefore, this was not a meta-analysis. Second, the studies were conducted at single institutions and had relatively small sample sizes. Third, all of these previous studies, except two, were retrospective: one compared the intercostal approach with the transareolar approach, while the other compared the intercostal approach with the subxiphoid approach.

**Table 5** Pros and cons of intercostal, transareolar and subxiphoid approaches for pneumothorax

Variables	Intercostal	Transareolar	Subxiphoid
Pros	Easy exploration of the whole lung	Pain	Bilateral pneumothorax
	Can avoid the oversight of the bullae/ blebs	Possibly less pain	Better access to the bilateral thoracic cavity
	Safety	Decreased involvement of the intercostal nerve	Pain
	Easier conversion when needed	Cosmesis	Possibly low pain
	Cosmesis	Possibly improved cosmesis for male patients	No involvement of the intercostal nerve
	Availability of the incision for chest tube drainage		
	Accessibility of the posterior part		
Can resect both the apex and the top of the lower lobe			
Cons	Inevitable involvement of the intercostal nerve	Only for male patients	Obstruction may exist because of the heart for left-sided surgery Possible arrhythmic events Unknown accessibility to the posterior portion

## Conclusions

This article summarized reports on the intercostal procedure of uniportal VATS for pneumothorax and its indications compared with the subxiphoid and transareolar approaches. To generalize the indications for uniportal VATS, the surgical indication of the pneumothorax size should be considered. The presence of bullae and the initial thoracic surgery may be favorable indications for uniportal VATS. In the uniportal intercostal approach, arrangements were performed to shorten the incision size. To further reduce invasiveness, eliminating or ameliorating postoperative air leakage appears to be the next challenge. Regarding the transareolar and subxiphoid approaches, reports are needed on the technical limitations and surgical outcomes, including resected lesions and complications. The technical feasibility, complications and cosmesis of each approach should be considered to determine the indications.

## Acknowledgments

*Funding:* None.

## Footnote

*Provenance and Peer Review:* This article was commissioned by the Guest Editor (Kenji Tsuboshima) for the series “Single-Port VATS for Pneumothorax” published in *Video-Assisted Thoracic Surgery*. The article has undergone external peer review.

*Peer Review File:* Available at <https://vats.amegroups.com/article/view/10.21037/vats-23-30/prf>

*Conflicts of Interest:* All authors have completed the ICMJE uniform disclosure form (available at <https://vats.amegroups.com/article/view/10.21037/vats-23-30/coif>). The series “Single-Port VATS for Pneumothorax” was commissioned by the editorial office without any funding or sponsorship. The authors have no other conflicts of interest to declare.

*Ethical Statement:* The authors are accountable for all aspects of the work in ensuring that questions related to the accuracy or integrity of any part of the work are appropriately investigated and resolved.

*Open Access Statement:* This is an Open Access article distributed in accordance with the Creative Commons Attribution-NonCommercial-NoDerivs 4.0 International License (CC BY-NC-ND 4.0), which permits the non-commercial replication and distribution of the article with the strict proviso that no changes or edits are made and the original work is properly cited (including links to both the formal publication through the relevant DOI and the license). See: <https://creativecommons.org/licenses/by-nc-nd/4.0/>.

## References

1. MacDuff A, Arnold A, Harvey J, et al. Management of spontaneous pneumothorax: British Thoracic Society Pleural Disease Guideline 2010. *Thorax* 2010;65 Suppl 2:ii18-31.
2. Schnell J, Beer M, Eggeling S, et al. Management of Spontaneous Pneumothorax and Post-Interventional Pneumothorax: German S3 Guideline. *Respiration* 2019;97:370-402.
3. Yamamoto H, Okada M, Takada M, et al. Video-assisted thoracic surgery through a single skin incision. *Arch Surg* 1998;133:145-7.
4. Liu CY, Lin CS, Liu CC. Subxiphoid single-incision thoracoscopic surgery for bilateral primary spontaneous pneumothorax. *Wideochir Inne Tech Maloinwazyjne* 2015;10:125-8.
5. Lin JB, Chen JF, Lai FC, et al. Transareolar pulmonary bullectomy for primary spontaneous pneumothorax. *J Thorac Cardiovasc Surg* 2016;152:999-1005.
6. Masmoudi H, Etienne H, Sylvestre R, et al. Three Hundred Fifty-One Patients With Pneumothorax Undergoing Uniportal (Single Port) Video-Assisted Thoracic Surgery. *Ann Thorac Surg* 2017;104:254-60.
7. Nachira D, Ismail M, Meacci E, et al. Uniportal vs. triportal video-assisted thoracic surgery in the treatment of primary pneumothorax—a propensity matched bicentric study. *J Thorac Dis* 2018;10:S3712-9.
8. Kutluk AC, Kocaturk CI, Akin H, et al. Which is the Best Minimal Invasive Approach for the Treatment of Spontaneous Pneumothorax? Uniport, Two, or Three Ports: A Prospective Randomized Trial. *Thorac Cardiovasc Surg* 2018;66:589-94.
9. Igai H, Kamiyoshihara M, Furusawa S, et al. A prospective comparative study of thoracoscopic transareolar and uniportal approaches for young male patients with primary spontaneous pneumothorax. *Gen Thorac Cardiovasc Surg* 2021;69:1414-20.
10. Li L, Tian H, Yue W, et al. Subxiphoid vs intercostal single-incision video-assisted thoracoscopic surgery for spontaneous pneumothorax: A randomised controlled trial. *Int J Surg* 2016;30:99-103.
11. Wang BY, Chang YC, Chang YC, et al. Thoracoscopic surgery via a single-incision subxiphoid approach is associated with less postoperative pain than single-incision transthoracic or three-incision transthoracic approaches for spontaneous pneumothorax. *J Thorac Dis* 2016;8:S272-8.
12. Chen L, Liu F, Wang B, et al. Subxiphoid vs transthoracic approach thoracoscopic surgery for spontaneous pneumothorax: a propensity score-matched analysis. *BMC Surg* 2019;19:46.
13. Jutley RS, Khalil MW, Rocco G. Uniportal vs standard three-port VATS technique for spontaneous pneumothorax: comparison of post-operative pain and residual paraesthesia. *Eur J Cardiothorac Surg* 2005;28:43-6.
14. Akçay O, Acar T, Cantay S, et al. Minimally invasive approach to pneumothorax: Single port or two ports? *Turk Gogus Kalp Damar Cerrahisi Derg* 2019;28:347-51.
15. Yang HC, Cho S, Jheon S. Single-incision thoracoscopic surgery for primary spontaneous pneumothorax using the SILS port compared with conventional three-port surgery. *Surg Endosc* 2013;27:139-45.
16. Song IH, Lee SY, Lee SJ. Can single-incision thoracoscopic surgery using a wound protector be used as a first-line approach for the surgical treatment of primary spontaneous pneumothorax? A comparison with three-port video-assisted thoracoscopic surgery. *Gen Thorac Cardiovasc Surg* 2015;63:284-9.
17. Salati M, Brunelli A, Xiumè F, et al. Uniportal video-assisted thoracic surgery for primary spontaneous pneumothorax: clinical and economic analysis in comparison to the traditional approach. *Interact Cardiovasc Thorac Surg* 2008;7:63-6.
18. Berlanga LA, Gıgırey O. Uniportal video-assisted thoracic surgery for primary spontaneous pneumothorax using a single-incision laparoscopic surgery port: a feasible and safe procedure. *Surg Endosc* 2011;25:2044-7.
19. Chen PR, Chen CK, Lin YS, et al. Single-incision thoracoscopic surgery for primary spontaneous pneumothorax. *J Cardiothorac Surg* 2011;6:58.
20. Chen CH, Lee SY, Chang H, et al. The adequacy of single-incisional thoracoscopic surgery as a first-line endoscopic approach for the management of recurrent primary spontaneous pneumothorax: a retrospective study.

- J Cardiothorac Surg 2012;7:99.
21. Igai H, Kamiyoshihara M, Ibe T, et al. Single-incision thoracoscopic surgery for spontaneous pneumothorax using multi-degrees of freedom forceps. *Ann Thorac Cardiovasc Surg* 2014;20:974-9.
  22. Kang DK, Min HK, Jun HJ, et al. Early outcomes of single-port video-assisted thoracic surgery for primary spontaneous pneumothorax. *Korean J Thorac Cardiovasc Surg* 2014;47:384-8.
  23. Son BS, Kim DH, Lee SK, et al. Small Single-Incision Thoracoscopic Surgery Using an Anchoring Suture in Patients With Primary Spontaneous Pneumothorax: A Safe and Feasible Procedure. *Ann Thorac Surg* 2015;100:1224-9.
  24. Tsuboshima K, Wakahara T, Matoba Y, et al. Single-incision thoracoscopic surgery using a chest wall pulley for lung excision in patients with primary spontaneous pneumothorax. *Surg Today* 2015;45:595-9.
  25. Yamazaki K, Haratake N, Shikada Y, et al. Initial Experience of Single-Incision Thoracoscopic Surgery for 100 Patients with Primary Spontaneous Pneumothorax. *Ann Thorac Cardiovasc Surg* 2015;21:513-6.
  26. Chong Y, Cho HJ, Kang SK, et al. Outcomes of the Tower Crane Technique with a 15-mm Trocar in Primary Spontaneous Pneumothorax. *Korean J Thorac Cardiovasc Surg* 2016;49:80-4.
  27. Jeon HW, Kim YD. Does 11.5 mm guided single port surgery has clinical advantage than multi-port thoracoscopic surgery in spontaneous pneumothorax? *J Thorac Dis* 2016;8:2924-30.
  28. Ocakcioglu I, Alpay L, Demir M, et al. Is single port enough in minimally surgery for pneumothorax? *Surg Endosc* 2016;30:59-64.
  29. Jung H, Oh TH, Cho JY, et al. Mid-Term Outcomes of Single-Port versus Conventional Three-Port Video-Assisted Thoracoscopic Surgery for Primary Spontaneous Pneumothorax. *Korean J Thorac Cardiovasc Surg* 2017;50:184-9.
  30. Al-Githmi I. Uniportal Video-Assisted Thoracoscopic Surgery and Outcomes for Recurrent Primary Spontaneous Pneumothorax: Single-Institution Experience. *Surgical Science* 2018;9:122-7.
  31. Zhang C, Zhang M, Wang H, et al. Next-day discharge following small uniportal thoracoscopic bullectomy assisted with an anchoring suture. *J Int Med Res* 2020;48:300060519896926.
  32. Kopicibasi HO. Uniportal VATS technique for primary spontaneous pneumothorax: An analysis of 46 cases. *Pak J Med Sci* 2020;36:224-8.
  33. Fiorelli A, Cascone R, Carlucci A, et al. Uniportal thoracoscopic surgical management using a suture traction for primary pneumothorax. *Asian Cardiovasc Thorac Ann* 2021;29:195-202.
  34. Yoshikawa R, Matsuura N, Igai H, et al. Uniportal approach as an alternative to the three-portal approach to video-assisted thoracic surgery for primary spontaneous pneumothorax. *J Thorac Dis* 2021;13:927-34.
  35. Lee SH, Lee SG, Cho SH, et al. Outcomes of Single-Incision Thoracoscopic Surgery Using the Spinal Needle Anchoring Technique for Primary Spontaneous Pneumothorax. *J Chest Surg* 2022;55:44-8.
  36. Wang P, Zhang L, Zheng H, et al. Comparison of single-port vs. two-port VATS technique for primary spontaneous pneumothorax. *Minim Invasive Ther Allied Technol* 2022;31:462-7.
  37. Yazawa T, Igai H, Ohsawa F, et al. Feasibility of thoracoscopic pulmonary bullectomy using a transareolar approach for treatment of primary spontaneous pneumothorax. *J Thorac Dis* 2020;12:5794-801.
  38. Liu CC, Shih CS, Liu YH, et al. Subxiphoid single-port video-assisted thoracoscopic surgery. *J Vis Surg* 2016;2:112.
  39. Fok M, Karunanantham J, Ali JM, et al. Subxiphoid approach for spontaneous bilateral pneumothorax: a case report. *J Vis Surg* 2017;3:146.
  40. Ismail M, Swierzy M, Nachira D, et al. Uniportal video-assisted thoracic surgery for major lung resections: pitfalls, tips and tricks. *J Thorac Dis* 2017;9:885-97.
  41. Muramatsu T, Nishii T, Takeshita S, et al. Preventing recurrence of spontaneous pneumothorax after thoracoscopic surgery: a review of recent results. *Surg Today* 2010;40:696-9.
  42. Lee S, Kim HR, Cho S, et al. Staple line coverage after bullectomy for primary spontaneous pneumothorax: a randomized trial. *Ann Thorac Surg* 2014;98:2005-11.
  43. Sihoe AD. The evolution of minimally invasive thoracic surgery: implications for the practice of uniportal thoracoscopic surgery. *J Thorac Dis* 2014;6:S604-17.
  44. Bertolaccini L, Batirel H, Brunelli A, et al. Uniportal video-assisted thoracic surgery lobectomy: a consensus report from the Uniportal VATS Interest Group (UVIG) of the European Society of Thoracic Surgeons (ESTS). *Eur J Cardiothorac Surg* 2019;56:224-9.
  45. Brown SGA, Ball EL, Perrin K, et al. Conservative versus Interventional Treatment for Spontaneous Pneumothorax. *N Engl J Med* 2020;382:405-15.

46. Olesen WH, Katballe N, Sindby JE, et al. Surgical treatment versus conventional chest tube drainage in primary spontaneous pneumothorax: a randomized controlled trial. *Eur J Cardiothorac Surg* 2018;54:113-21.
47. Yang Y, Dong J, Huang Y. Single-incision versus conventional three-port video-assisted surgery in the treatment of pneumothorax: a systematic review and meta-analysis. *Interact Cardiovasc Thorac Surg* 2016;23:722-8.
48. Xu W, Wang Y, Song J, et al. One-port video-assisted thoracic surgery versus three-port video-assisted thoracic surgery for primary spontaneous pneumothorax: a meta-analysis. *Surg Endosc* 2017;31:17-24.

doi: 10.21037/vats-23-30

**Cite this article as:** Nishioka Y, Hokka D, Maniwa Y. Procedure of uniportal intercostal bullectomy for pneumothorax and its indications: a clinical practice review. *Video-assist Thorac Surg* 2023;8:31.