

Simultaneous minimally invasive bilateral pulmonary metastasectomy: a narrative review

Shinji Yuhara^{1,2^}, Tadasu Kohno²

¹Department of Thoracic Surgery, The University of Tokyo Hospital, Tokyo, Japan; ²Department of Thoracic Surgery, New Tokyo Hospital, Matsudo, Japan

Contributions: (I) Conception and design: Both authors; (II) Administrative support: S Yuhara; (III) Provision of study materials or patients: S Yuhara; (IV) Collection and assembly of data: S Yuhara; (V) Data analysis and interpretation: S Yuhara; (VI) Manuscript writing: Both authors; (VII) Final approval of manuscript: Both authors.

Correspondence to: Shinji Yuhara, MD. Department of Thoracic Surgery, The University of Tokyo Hospital, 7-3-1, Hongo Bunkyo-ku, Tokyo, Japan; Department of Thoracic Surgery, New Tokyo Hospital, Matsudo, Japan. Email: shinji_teniburi@hotmail.co.jp.

Background and Objective: The integral role of pulmonary metastasectomy as one of the multimodal treatment options for oligometastatic cancer is widely recognized. Traditionally, thoracotomy with bimanual palpation was considered the standard surgical approach for pulmonary metastasectomy. However, many studies have demonstrated the intraoperative and postoperative benefits of the minimally invasive approach in thoracoscopic pulmonary metastasectomy without compromising oncologic outcomes. These studies concluded that the minimally invasive approach could be an alternative to conventional metastasectomy through thoracotomy. Before the advent of thoracoscopic surgery, there was a trend to avoid one-stage surgery via bilateral thoracotomy, sternotomy, or bilateral anterior sternothoracotomy (clamshell incision) for simultaneous bilateral pulmonary metastases due to its intolerable invasiveness. For the last decades, thoracic surgeons have been trying to overcome this limitation by utilizing simultaneous thoracoscopic bilateral pulmonary metastasectomy, taking advantage of its minimal invasiveness. Simultaneous thoracoscopic bilateral pulmonary metastasectomy has various advantages for both patients and hospitals. However, there are currently few summaries or reviews of the safety and feasibility of simultaneous thoracoscopic bilateral pulmonary metastasectomy. In this review, we discuss the state of the art of simultaneous thoracoscopic bilateral pulmonary metastasectomy.

Methods: We conducted a literature search on PubMed using the terms “bilateral pulmonary metastases”, “bilateral lung metastases”, “bilateral pulmonary nodules”, “bilateral lung nodules”, “bilateral pulmonary resections”, and “bilateral lung resections”, including case series, research articles, and reviews.

Key Content and Findings: We cover the following topics and discuss our experiences: the advantages and disadvantages of simultaneous minimally invasive thoracoscopic bilateral pulmonary metastasectomy compared to staged surgeries and thoracotomy; surgical approaches, including intraoperative management.

Conclusions: Simultaneous minimally invasive bilateral pulmonary metastasectomy appears promising but lacks a comprehensive discussion of surgical criteria, metastasis count, primary lesion histology, and long-term results. Further research is needed to assess indications, compare outcomes, and establish efficacy against staged procedures.

Keywords: Pulmonary metastasectomy; minimally invasive surgery; thoracoscopic surgery; simultaneous bilateral surgery

Received: 30 April 2023; Accepted: 24 August 2023; Published online: 11 September 2023.

doi: 10.21037/vats-23-40

View this article at: <https://dx.doi.org/10.21037/vats-23-40>

[^] ORCID: 0000-0003-3085-3744.

Introduction

The integral role of pulmonary metastasectomy as one of the multimodal treatment options for oligometastatic cancer is widely recognized. Traditionally, thoracotomy with bimanual palpation was considered the standard surgical approach for pulmonary metastasectomy (1,2). However, since 2000s, more and more cases of thoracoscopic pulmonary metastasectomy has been reported (1-7). Most of the literature demonstrated the intraoperative and postoperative benefits of the minimally invasive approach in thoracoscopic pulmonary metastasectomy without compromising oncologic outcomes. These studies concluded that the minimally invasive approach could be an alternative to conventional metastasectomy through thoracotomy (1-3,6,8). In 2008, a survey conducted by the European Society of Thoracic Surgeons (ESTS) revealed that only 28% of ESTS members performed thoracoscopic surgery for unilateral pulmonary metastases. Among the respondents, 65% considered bimanual palpation essential for pulmonary metastasectomy, 40% performed thoracoscopic surgery with therapeutic intent, and 7.6% opted for simultaneous thoracoscopic bilateral surgeries for bilateral pulmonary metastases (9). However, according to an overview of surgical practices for pulmonary metastases among ESTS members in 2019, the proportion of thoracoscopic surgery in pulmonary metastasectomy had increased to over 50% in 2019 from 15% in 2007. This rapid adoption of thoracoscopic surgery for pulmonary metastases may be resulted from improvements in preoperative imaging accuracy, broad acceptance of thoracoscopic surgery for primary lung cancer, and the lack of significant differences in local control, long-term survival, and recurrent rates between thoracoscopic surgery and thoracotomy (10).

Before the advent of thoracoscopic surgery, there has been a trend to avoid one-stage surgery via bilateral thoracotomy, sternotomy, or clamshell incision for simultaneous bilateral pulmonary metastases due to its intolerable invasiveness (1). For the last decades, thoracic surgeons have been trying to overcome this limitation by utilizing simultaneous thoracoscopic bilateral pulmonary metastasectomy, taking advantage of its minimal invasiveness (5-7,11-13). However, there are currently few summaries or reviews of the safety and feasibility of simultaneous thoracoscopic bilateral pulmonary metastasectomy.

In our department, simultaneous thoracoscopic bilateral pulmonary metastasectomy has been the standard approach

for the treatment of bilateral pulmonary metastases. In this review, we discuss the state of the art of simultaneous thoracoscopic bilateral pulmonary metastasectomy. We cover the following topics and discuss our experiences: the advantages and disadvantages of simultaneous minimally invasive thoracoscopic bilateral pulmonary metastasectomy compared to staged surgeries and thoracotomy, as well as the surgical approaches and intraoperative management. We present this article in accordance with the Narrative Review reporting checklist (available at <https://vats.amegroups.com/article/view/10.21037/vats-23-40/rc>).

Methods

We conducted a literature search on PubMed using the terms “bilateral pulmonary metastases”, “bilateral lung metastases”, “bilateral pulmonary nodules”, “bilateral lung nodules”, “bilateral pulmonary resections”, and “bilateral lung resections”, including case series, research articles, and reviews. The search strategy is outlined in *Table 1*. We identified 629 manuscripts and selected 40 for inclusion. Some of these literature sources included cases of simultaneous bilateral pulmonary resections for primary lung cancer. Due to the limited availability of the literature focusing solely on simultaneous thoracoscopic bilateral pulmonary metastasectomy, we included literature on primary lung cancer only when discussing intraoperative or immediate perioperative outcomes, as the targeted disease may not have a significant impact. We excluded articles that did not mention the laterality or surgical approach (thoracotomy or thoracoscopic surgery).

The advantages of simultaneous bilateral pulmonary resections

Simultaneous bilateral pulmonary resections can provide significant benefits compared to staged surgeries (4,11,14-26). Patients undergoing the second surgery in staged surgeries tend to experience more physical and psychological stress than when they were undergoing the first surgery. They may physically and psychologically still be in the process of recovering from the first surgery. With combining the two separate hospital stays and two separate operations into one admission and one surgery, we may be able to reduce the patients' physical and psychological burden. Moreover, patients may also benefit financially due to the reduction of total length of hospital stay (3,11,15,18,27). Some studies also have shown no

Table 1 The search strategy summary

Items	Specification
Date of search	2022/9/16–2023/7/8
Database searched	PubMed
Search terms used	“bilateral pulmonary metastases” “bilateral lung metastases” “bilateral pulmonary nodules” “bilateral lung nodules” “bilateral pulmonary resections” “bilateral lung resections”
Timeframe	1996–2023
Inclusion and exclusion criteria	We conducted a selection of case series, research articles, and reviews in English focusing on bilateral pulmonary resections; excluded from consideration were articles lacking information regarding laterality and surgical approach (thoracotomy or thoracoscopic surgery)
Selection process	S.Y. conducted the initial selection; subsequently, both authors discussed the literature selection, leading to a consensus
Additional considerations	We incorporated literature concerning primary lung cancer only when addressing intraoperative or immediate perioperative outcomes

significant difference in postoperative pain between bilateral simultaneous pulmonary resections and unilateral surgery (11,20). Avoiding staged surgeries can lead to more efficient utilization of medical resources for hospitals as well as patients (18,20).

From a surgical perspective, there is a risk that an unexpectedly prolonged recovery after the first surgery may delay the timing of the second surgery and lead to the progression of the contralateral disease. This risk can be avoided with simultaneous bilateral pulmonary resections (16,18,19). Additionally, simultaneous bilateral pulmonary resections may shorten the time lag between the first surgery and the initiation of postoperative adjuvant therapy.

Numerous articles have suggested that the thoracoscopic surgery is superior to thoracotomy in terms of postoperative pain, recovery, and preservation of respiratory function due to its minimal invasiveness (1-3,6,8). However, the standard surgical approach for pulmonary metastases was thoracotomy for a long time, which allowed surgeons to explore all portions of the lung through bimanual palpation and remove all nodules, including those too small to be detected by preoperative imaging. In the past, bilateral posterolateral thoracotomy, median sternotomy, and clamshell incision were attempted for bilateral pulmonary

metastasectomy. Bilateral posterolateral thoracotomy and sternotomy require large incisions in the chest, which can result in significant postoperative pain and a high risk of postoperative respiratory complications. Clamshell incisions are also known to increase postoperative complications and mortality (1). Even though the sternotomy can reduce the chest wall damage, it only allows limited access to the posterior lungs, especially the posterior lower lobes (1,2).

While thoracoscopic surgery allows for easy access to all parts of the lung and decreases postoperative pain, complications, and mortality compared to thoracotomy, there has been a long-standing debate about the risk of missing small-sized pulmonary metastases during thoracoscopic surgery which required bimanual palpation for localization. A study of confirmatory thoracotomy after thoracoscopic exploration reported a 56% occurrence of missed pulmonary metastases (28). However, in recent years, novel techniques such as computed tomography (CT)-guided localization have emerged (29), and many studies suggest no significant difference in prognosis between thoracoscopic surgery and thoracotomy (1,3,8). Also, it is considered that even if pulmonary metastases which is too small to be detected by preoperative imaging are missed during thoracoscopic surgery, there may

be no significant prognostic impact (1). Furthermore, thoracoscopic surgery may lead to reduced postoperative pleural adhesions compared to thoracotomy, which could be advantageous when performing repeated metastasectomy on the ipsilateral side (1,2).

The disadvantages of simultaneous bilateral pulmonary resections

Although there are disadvantages associated with bilateral simultaneous pulmonary resections, these can be mitigated through minimally invasive surgery and appropriate preoperative cardiopulmonary evaluation, making simultaneous bilateral surgeries more feasible.

Bilateral surgeries generally require longer operative durations than unilateral surgery (14,15,17). However, the operative time for bilateral simultaneous pulmonary resections has been reported to be significantly shorter than the sum of the staged surgeries (14,20,24), and the amount of blood loss is comparable to twice that of unilateral surgery (15). Intraoperatively, simultaneous bilateral surgeries require meticulous anesthesia management (6,14,29). Repositioning a patient can cause hemodynamic instability, and one-lung ventilation with the resected lung on the contralateral side can elevate intra-airway pressure. Preceding lung resection can cause air leaks, and the lateral position can compromise the drainage of air leaks, potentially affecting oxygenation and causing tension pneumothorax. To prevent these complications, we start with the side that requires a smaller (less complicated) lung resection (4,17,22-25,27).

Simultaneous bilateral surgeries also have a significant impact on postoperative recovery. There are conflicting reports regarding the duration of chest tube placement and hospitalization periods for simultaneous bilateral pulmonary resections compared to unilateral surgery. Some reports suggest no significant difference (15), while others indicate that simultaneous bilateral pulmonary resections have prolonged air leaks and hospitalization periods (14). However, simultaneous bilateral pulmonary resections result in significantly shorter hospitalization periods compared to the sum of staged bilateral pulmonary resections (6,14,20,24,30). The postoperative pain management is more crucial in bilateral surgeries than in unilateral surgery to prevent respiratory complications (19,20,23-26,31). Feldman *et al.* (20) emphasized the importance of pain control under the enhanced recovery after surgery (ERAS) protocol after simultaneous bilateral pulmonary resections.

There was no significant difference in the average postoperative pain in the recovery room, on postoperative day (POD) 1, POD2, and POD3 between patients who underwent simultaneous bilateral pulmonary resections and those who underwent staged surgeries. Regarding morphine equivalents per hospitalization, there was no significant difference between the two groups. However, the total morphine equivalents administered to patients undergoing simultaneous surgeries were significantly lower compared to the sum administered to patients undergoing staged surgeries. The use of minimally invasive thoracoscopic surgery may reduce postoperative pain, and especially, the subxiphoid approach may have significant benefits due to the bypass of intercostal spaces (5,7,30,32-35).

Surgical approaches

Traditionally, multiportal thoracoscopic surgery in the lateral position with changing sides to access the bilateral pleural spaces has been the standard approach for simultaneous bilateral thoracoscopic pulmonary resections. Over the last decade, there has been a growing number of reports of simultaneous thoracoscopic bilateral pulmonary resections, and new innovative surgical approaches have been also adopted recently. The clinical features of each surgical approaches were summarized in *Table 2*.

An increasing number of intercostal uniportal thoracoscopic bilateral pulmonary resections have been reported (4,22,24-26,31). In most of the literature, the patient is placed in the lateral decubitus position, and a change of position is required for contralateral surgery. A 3 to 4 cm incision is made on the anterior to midaxillary line between the fourth or fifth intercostal space. After completing the surgery on one side, some surgeons insert a cushion under the patient's body to avoid kinking of the drainage tube and ensure proper drainage during the contralateral surgery (22,27). In cases where postoperative air leaks are less of a concern, it is recommended to use a thinner drainage tube to reduce postoperative pain (24).

Liang *et al.* reported a case series of simultaneous bilateral pulmonary resections for unpalpable nodules using image-guided uniportal surgery in a hybrid operating room (29). All procedures, including intraoperative CT-guided localization, can be completed in the same hybrid operating room. Surgery can be safely performed for bilateral unpalpable nodules even when the localization is complicated by bilateral pneumothorax or hemothorax, as there is no need to transfer patients to an operating room after localization,

Table 2 Clinical features of surgical approaches for bilateral pulmonary nodules

Surgical approaches	Patient's position	Changing patient's position	Number of incisions	Maximal size of incisions	Approach to the posterior lung	Compression of the heart	Connection of bilateral thoracic cavities
Conventional multiportal	Lateral decubitus	Yes	Four or more	N/A	Easy	No	No
Intercostal uniportal	Lateral decubitus	Yes	Two	3 to 4 cm	Easy	No	No
Subxiphoid uniportal with intercostal ports	Supine	No	Two or more	3 to 4 cm	Less difficult	Yes	Yes
Subxiphoid uniportal	Supine	No	One	3 to 4 cm	Difficult	Yes	Yes

N/A, not applicable.

such as percutaneous image-guided injection of a dye and image-guided placement of hook wires or micro coils. As another approach for unpalpable nodules, Kawada *et al.* reported the intrathoracic stamping method, which avoids puncturing the lung (36). In Japan, virtual-assisted lung mapping (VAL-MAP) using three-dimensional images and bronchoscopic dye injection has been widely accepted as a safe and reproducible procedure (37).

Recently, there have been more and more reports of using the subxiphoid approach, either alone or with an intercostal approach, for resecting bilateral pulmonary nodules in a supine position (5,7,30-33). In 1999, Mineo *et al.* reported intercostal thoracoscopic surgery for bilateral pulmonary metastases with a hand-assisted subxiphoid approach (12), while Taniguchi *et al.* reported intercostal thoracoscopic bilateral pulmonary metastasectomy with a subxiphoid access port and sternal suspension in 2005 (13). The subxiphoid approach eliminates the need to change the patient's position, potentially reducing operative time and the risk of compromising intraoperative hemodynamics. Additionally, the subxiphoid approach may reduce postoperative pain by avoiding intercostal space injuries and have aesthetic benefits due to the reduced incisions. Compared with intercostal uniportal bilateral pulmonary resections, the subxiphoid approach resulted in less postoperative pain. However, operative time and blood loss were significantly increased in the subxiphoid group (31).

There are several caveats to subxiphoid uniportal bilateral pulmonary metastasectomy (7,35). Firstly, patients undergoing subxiphoid uniportal bilateral pulmonary resections should be selected carefully due to the difficulty of accessing the posterior lung (5,7). Sometimes an additional port in the intercostal space may be necessary for assistance. Mohammed *et al.* reported that an additional

port for the scope in the intercostal space, separately from the subxiphoid incision, reduces the size of the subxiphoid incision, facilitates insertion of instruments, and is useful for manipulation near the posterior mediastinum and for dissection of adhesions (32). Secondly, there is a concern that the subxiphoid approach may induce arrhythmia and hypotension during left-sided surgery, particularly in patients with cardiac hypertrophy, due to compression of the heart by the surgical instruments (7,31,33,35). Extending the skin incision by 1 to 2 cm along the left-sided rib arch may improve the operative field (31). Lastly, it should be noted that in subxiphoid bilateral pulmonary resections, the left and right thoracic cavities are connected, so postoperative air leaks or malignant pleural effusions on one side may affect the contralateral side (35).

There have been a few reports of thoracoscopic contralateral pulmonary resections performed in the lateral decubitus position by approaching the contralateral side through the anterior mediastinum (38,39). However, this surgical approach is only applicable to the selected cases, as it requires the absence of pleural adhesion on the contralateral side and the location of nodules in the anterior and mediastinal regions of the lung (8).

Extent of lung resection

The indication of simultaneous bilateral pulmonary metastasectomy should be judged on a case-by-case basis, considering the location of the metastasis, the extent of lung resection, and the patient's respiratory function. Generally, the number of pulmonary metastases and the histology of the primary lesion are considered to have a significant impact on the prognosis of patients with pulmonary metastases. However, many studies have suggested that

the number and histology themselves may not be the sole independent factors limiting pulmonary metastasectomy (2,9,11,15).

While surgeons often select wedge resections for pulmonary metastasectomy, anatomical resections such as segmentectomy and lobectomy may be necessary for large and/or centrally-located tumors (8,40). Some studies have suggested that patients who need only wedge resections on at least one side may be suitable for simultaneous bilateral pulmonary resections (17). However, other reports suggest that the maximum resection range could be extended to lobectomy and contralateral segmentectomy (19,21,31). The occurrence of postoperative pneumonia was reported to be significantly higher in patients who underwent uniportal thoracoscopic simultaneous lobectomy and contralateral sublobar resections compared to those who underwent uniportal simultaneous bilateral sublobar resections (4). In this study, despite the high incidence of postoperative pneumonia, there was no significant difference in postoperative length of stay between the two groups, and the authors recommended considering simultaneous bilateral pulmonary resections for patients with a performance status of 0 or 1 and percent predicted forced expiratory volume in one second (FEV1%) greater than 75%.

It is widely accepted that the simultaneous bilateral lobectomy is extremely high risk and should be avoided due to its high mortality, even when patients are carefully selected (21). Yao *et al.* reported that a patient who underwent simultaneous multiportal thoracoscopic bilateral lobectomy required four days of postoperative ventilator management (27). Xu *et al.* reviewed 40 cases of simultaneous intercostal uniportal thoracoscopic bilateral pulmonary metastasectomy. They recommended that the criteria for the indication of simultaneous bilateral surgeries should exclude bilateral lobectomy, except for the right middle lobe, and the extent of resection should be limited to a total of 10 segments or less (24). However, in recent years, there have been increasing reports of simultaneous bilateral lobectomy due to the minimally invasive nature of thoracoscopic surgery (34).

Minimally invasive thoracoscopic surgery may increase the acceptable extent of lung resection with minimizing the chest wall disruption. However, the existing literature regarding the feasibility of simultaneous bilateral metastasectomy includes cases of thoracotomy. Therefore, further research is needed to clarify the acceptable extent of lung resection specifically with

regard to thoracoscopic surgery.

Our experience

In our institution, we prefer to perform simultaneous thoracoscopic bilateral pulmonary metastasectomy for patients who have adequately maintained cardiopulmonary functions without significant comorbidities. Our selection criteria allow for a maximum lung resection volume of a lobectomy and a contralateral segmentectomy, with or without wedge resections. We typically perform three-port thoracoscopic surgery with a 12 mm incision for the surgeon's right hand, 5–10 mm for the scope, and 3–7 mm for the surgeon's left hand. The surgeon stands on the patient's right side, regardless of the operating side of the patients, and the scope assistant stands on the patient's left side. The incision for the surgeon's right hand is placed on the midaxillary line of the 5th or 6th intercostal space. For right-sided surgery, the incision for the surgeon's left hand is placed on the posterior axillary line of the 4th or 5th intercostal space, and the incision for the scope is placed on the anterior axillary line of the 3rd or 4th intercostal space. For left-sided surgery, the two incisions are reversed. Patients are placed in a lateral decubitus position. After successful lung resection, we usually place a 20-French chest tube from the anterior edge of the incision of surgeon's right hand, which is usually located on the mid axillary line. When performing simultaneous bilateral surgeries, a drainage tube is inserted through the incision on the anterior axillary line to avoid the patient lying on the chest tube, which can compromise the drainage of air leaks during contralateral surgery (*Figure 1A*). After changing the patient's position, we examine the tidaling of water seal in the chest tube drainage system before starting the surgery on the contralateral side. For the second surgery, a drainage tube is inserted through the incision on the mid axillary line as usual (*Figure 1B*).

Between 2019 and 2022, we performed eight cases of simultaneous thoracoscopic bilateral pulmonary metastasectomy. Among the patients, six patients underwent bilateral wedge resections, one underwent lingulectomy and contralateral wedge resection, and the other underwent right superior segmentectomy and contralateral wedge resections. During this period, no patient underwent bilateral metastasectomy via thoracotomy. The median operative duration was 176 min (range, 119 to 317 min). The median length of postoperative stay was 5 days (range, 3 to 6 days), and the median postoperative drainage period

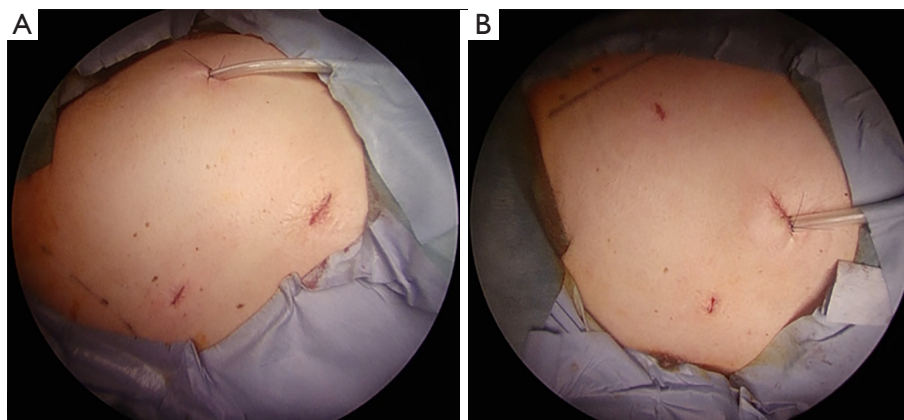


Figure 1 The incisions of three-port thoracoscopic surgery for bilateral pulmonary metastases. (A) For the first surgery on the right side, a drainage tube is inserted through the incision for the scope on the anterior axillary line. (B) For the second surgery on the left side, a drainage tube is inserted through the incision of the surgeon's right hand on the mid axillary line.

was 1 day (range, 1 to 3 days). There were no significant postoperative morbidities or mortalities. Our perioperative outcomes were comparable to those reported in the literature.

Conclusions

Simultaneous minimally invasive thoracoscopic bilateral pulmonary metastasectomy may be safe and feasible and may gain wider acceptance soon. However, the surgical indications, including the number of pulmonary metastases and the histology of the primary lesion, as well as long-term outcomes, were not extensively discussed in the reviewed articles. Further studies are necessary to evaluate the surgical indications and assess the long-term oncological outcomes, including a comparison of simultaneous and staged thoracoscopic bilateral pulmonary metastasectomy.

Acknowledgments

The authors would like to express their sincere gratitude to Dr. Takashi Harano (University of Southern California, Los Angeles, CA, USA) for his assistance in preparing the manuscript.

Funding: None.

Footnote

Provenance and Peer Review: This article was commissioned by the Guest Editors (Anthony W. Kim and Takashi Harano) for the series “The Role of Minimally Invasive

Approaches in the Pulmonary Oligometastases” published in *Video-Assisted Thoracic Surgery*. The article has undergone external peer review.

Reporting Checklist: The authors have completed the Narrative Review reporting checklist. Available at <https://vats.amegroups.com/article/view/10.21037/vats-23-40/rc>

Peer Review File: Available at <https://vats.amegroups.com/article/view/10.21037/vats-23-40/prf>

Conflicts of Interest: Both authors have completed the ICMJE uniform disclosure form (available at <https://vats.amegroups.com/article/view/10.21037/vats-23-40/coif>). The series “The Role of Minimally Invasive Approaches in the Pulmonary Oligometastases” was commissioned by the editorial office without any funding or sponsorship. The authors have no other conflicts of interest to declare.

Ethical Statement: The authors are accountable for all aspects of the work in ensuring that questions related to the accuracy or integrity of any part of the work are appropriately investigated and resolved. Written informed consent was obtained from the patient for the publication of this case report and accompanying images. A copy of the written consent is available for review by the editorial office of this journal.

Open Access Statement: This is an Open Access article distributed in accordance with the Creative Commons Attribution-NonCommercial-NoDerivs 4.0 International

License (CC BY-NC-ND 4.0), which permits the non-commercial replication and distribution of the article with the strict proviso that no changes or edits are made and the original work is properly cited (including links to both the formal publication through the relevant DOI and the license). See: <https://creativecommons.org/licenses/by-nc-nd/4.0/>.

References

- Hornbech K, Ravn J, Steinbrüchel DA. Current status of pulmonary metastasectomy. *Eur J Cardiothorac Surg* 2011;39:955-62.
- Mangiameli G, Cioffi U, Alloisio M, et al. Lung Metastases: Current Surgical Indications and New Perspectives. *Front Surg* 2022;9:884915.
- Rusidanmu A, Chin W, Xu J, et al. Does a thoracoscopic approach provide better outcomes for pulmonary metastases? *J Thorac Dis* 2021;13:2692-7.
- Lin S, Yang C, Guo X, et al. Simultaneous Uniportal video-assisted thoracic surgery of bilateral pulmonary nodules. *J Cardiothorac Surg* 2021;16:42.
- Suda T, Ashikari S, Tochii S, et al. Single-incision subxiphoid approach for bilateral metastasectomy. *Ann Thorac Surg* 2014;97:718-9.
- Han KN, Kang CH, Park IK, et al. Thoracoscopic approach to bilateral pulmonary metastasis: is it justified? *Interact Cardiovasc Thorac Surg* 2014;18:615-20.
- Elkhayat H, Hamza HM, Elshoieby MH, et al. Role of subxiphoid uniportal video-assisted thoracoscopic surgery in pulmonary metastasectomy. *Kardiochir Torakochirurgia Pol* 2022;19:232-9.
- Higashiyama M, Tokunaga T, Nakagiri T, et al. Pulmonary metastasectomy: outcomes and issues according to the type of surgical resection. *Gen Thorac Cardiovasc Surg* 2015;63:320-30.
- Internullo E, Cassivi SD, Van Raemdonck D, et al. Pulmonary metastasectomy: a survey of current practice amongst members of the European Society of Thoracic Surgeons. *J Thorac Oncol* 2008;3:1257-66.
- Gonzalez M, Brunelli A, Szanto Z, et al. Report from the European Society of Thoracic Surgeons database 2019: current surgical practice and perioperative outcomes of pulmonary metastasectomy. *Eur J Cardiothorac Surg* 2021;59:996-1003.
- Liu YW, Chou A, Chou SH. Experience of Simultaneous Bilateral Open Surgery and VATS for Pulmonary Metastasectomy. *Thorac Cardiovasc Surg* 2023;71:121-9.
- Mineo TC, Pompeo E, Ambrogi V, et al. Video-assisted approach for transxiphoid bilateral lung metastasectomy. *Ann Thorac Surg* 1999;67:1808-10.
- Taniguchi Y, Suzuki Y, Suda T, et al. Video-assisted thoracoscopic bilateral lung metastasectomy with a subxiphoid access port. *J Thorac Cardiovasc Surg* 2005;130:916-7.
- Lan L, Qiu Y, Zhang C, et al. Comparison of single-stage and two-stage bilateral video-assisted thoracic surgery. *J Int Med Res* 2020;48:300060520967558.
- Mizuno Y, Iwata H, Shirahashi K, et al. One-stage bilateral pulmonary resections for pulmonary metastases. *Gen Thorac Cardiovasc Surg* 2014;62:53-7.
- Xu G, Fu X. One-stage video-assisted thoracic surgery for bilateral multiple pulmonary nodules. *J Thorac Dis* 2019;11:535-41.
- Matsubara T, Toyokawa G, Kinoshita F, et al. Safety of Simultaneous Bilateral Pulmonary Resection for Metastatic Lung Tumors. *Anticancer Res* 2018;38:1715-9.
- Kao CN, Liu YW. Simultaneous bilateral pulmonary metastasectomy: A cost-effective surgery. *J Surg Oncol* 2022;125:310-1.
- Huang C, Sun Y, Wu Q, et al. Simultaneous bilateral pulmonary resection via single-utility port VATS for multiple pulmonary nodules: A single-center experience of 16 cases. *Thorac Cancer* 2021;12:525-33.
- Feldman HA, Zhou N, Antonoff MB, et al. Simultaneous versus staged resections for bilateral pulmonary metastases. *J Surg Oncol* 2021;123:1633-9.
- Mun M, Kohno T. Single-stage surgical treatment of synchronous bilateral multiple lung cancers. *Ann Thorac Surg* 2007;83:1146-51.
- Shi W, Hu Y, Chang G, et al. Application of bilateral simultaneous sequential single-incision video-assisted thoracic surgery in multiple nodules both lungs: a single-center experience of 10 cases. *BMC Surg* 2022;22:386.
- Zhang Y, Wang Y, Lv C, et al. Clinical analysis of 56 cases of simultaneous bilateral video-assisted thoracoscopic surgery for bilateral synchronous multiple primary lung adenocarcinoma. *J Thorac Dis* 2018;10:6452-7.
- Xu G, Wang G, Mei X, et al. Sequential pulmonary resections by uniportal video-assisted thoracic surgery for bilateral multiple pulmonary nodules. *Front Oncol* 2022;12:961812.
- Zheng H, Peng Q, Xie D, et al. Simultaneous bilateral thoracoscopic lobectomy for synchronous bilateral multiple primary lung cancer-single center experience. *J Thorac Dis* 2021;13:1717-27.
- Qu R, Hao Z, Zhang Y, et al. Single-center experience

- of simultaneous bilateral uni-portal video-assisted thoracoscopic surgery for multiple ground-glass opacities. *J Cardiothorac Surg* 2020;15:69.
27. Yao F, Yang H, Zhao H. Single-stage bilateral pulmonary resections by video-assisted thoracic surgery for multiple small nodules. *J Thorac Dis* 2016;8:469-75.
 28. McCormack PM, Bains MS, Begg CB, et al. Role of video-assisted thoracic surgery in the treatment of pulmonary metastases: results of a prospective trial. *Ann Thorac Surg* 1996;62:213-6; discussion 216-7.
 29. Liang CC, Liao CH, Cheng YF, et al. Bilateral lung nodules resection by image-guided video-assisted thoracoscopic surgery: a case series. *J Cardiothorac Surg* 2020;15:203.
 30. Wang L, Ge L, Yang X. Combination of subxiphoid and intercostal uniportal video-assisted thoracoscopic surgery for bilateral lung lesions: report of two cases and review of the literature. *Postgrad Med* 2017;129:513-6.
 31. Cai H, Xie D, Al Sawalhi S, et al. Subxiphoid versus intercostal uniportal video-assisted thoracoscopic surgery for bilateral lung resections: a single-institution experience. *Eur J Cardiothorac Surg* 2020;57:343-9.
 32. Mohammed I, Bernd L, Matthias S. Feasibility and Advantages of a Modified Subxiphoidal Video-Assisted Thoracoscopy Procedure Compared to Established Traditional Video-Assisted Thoracoscopy Procedures in Intercostal Access. *Int J Surg Res Pract* 2021;8:127-35.
 33. Negi T, Suda T, Tochii S, et al. Subxiphoid uniportal bilateral lung wedge resection. *Eur J Cardiothorac Surg* 2020;58:i100-2.
 34. Harris CG, James RS, Tian DH, et al. Systematic review and meta-analysis of uniportal versus multiportal video-assisted thoracoscopic lobectomy for lung cancer. *Ann Cardiothorac Surg* 2016;5:76-84.
 35. Yang X, Wang L, Zhang C, et al. The Feasibility and Advantages of Subxiphoid Uniportal Video-Assisted Thoracoscopic Surgery in Pulmonary Lobectomy. *World J Surg* 2019;43:1841-9.
 36. Kawada M, Okubo T, Poudel S, et al. A new marking technique for peripheral lung nodules avoiding pleural puncture: the intrathoracic stamping method. *Interact Cardiovasc Thorac Surg* 2013;16:381-3.
 37. Sato M, Kuwata T, Yamanashi K, et al. Safety and reproducibility of virtual-assisted lung mapping: a multicentre study in Japan. *Eur J Cardiothorac Surg* 2017;51:861-8.
 38. Wohlgemut JM, Salami M, Buchan K. Bilateral pulmonary metastasectomy through right thoracotomy. *Ann Thorac Surg* 2013;96:323-5.
 39. Kodama K, Higashiyama M, Yokouchi H, et al. Transmediastinal approach to exploring the lung contralateral to the thoracotomy site. *Jpn J Thorac Cardiovasc Surg* 2001;49:267-72.
 40. Kondo H, Okumura T, Ohde Y, et al. Surgical treatment for metastatic malignancies. Pulmonary metastasis: indications and outcomes. *Int J Clin Oncol* 2005;10:81-5.

doi: 10.21037/vats-23-40

Cite this article as: Yuhara S, Kohno T. Simultaneous minimally invasive bilateral pulmonary metastasectomy: a narrative review. *Video-assist Thorac Surg* 2024.