

Spontaneous ventilation with double-lumen tube intubation for video-assisted thoracic surgery thymectomy: a pilot study

József Furák^{1^}, Tibor Németh¹, Krisztina Budai¹, Attila Farkas², Judit Lantos³, Jennifer Romy Glenz¹, Csongor Fabó⁴, Ali Shadmanian⁵, András Buzás¹

¹Department of Surgery, University of Szeged, Szeged, Hungary; ²Department of Surgery, Vas County Markusovszky Hospital, Szombathely, Hungary; ³Department of Neurology, Bács-Kiskun County Hospital, Kecskemét, Hungary; ⁴Department of Anaesthesiology and Intensive Therapy, University of Szeged, Szeged, Hungary; ⁵Department of Cardiac Surgery, University of Szeged, Szeged, Hungary

Contributions: (I) Conception and design: J Furák, A Buzás; (II) Administrative support: A Farkas, J Lantos; (III) Provision of study materials or patients: K Budai, A Shadmanian; (IV) Collection and assembly of data: T Németh, JR Glenz; (V) Data analysis and interpretation: J Furák, C Fabó; (VI) Manuscript writing: All authors; (VII) Final approval of manuscript: All authors.

Correspondence to: József Furák, MD, PhD, med.habil. Department of Surgery, University of Szeged, H-6725, Semmelweis Str. 8., Szeged, Hungary. Email: jfurak@gmail.com.

Background: Spontaneous ventilation is considered the most physiological anaesthesia method in thoracic surgery; however, this procedure is controversial because of the potential risk of an unsafe airway. We conducted a retrospective, monocentric, interventional cohort study, which was a pilot evaluation of Spontaneous Ventilation using a double-lumen tube Intubation (SVI) technique for video-assisted thoracic surgery (VATS) thymectomy.

Methods: Fifteen patients underwent SVI VATS thymectomy in two groups: myasthenia gravis (MG) group (n=11) and non-MG group (n=4), with a mean age of 34.6 and 41.1 years, respectively. The mean body mass index (BMI) was 24.6 (range, 15.9–33.7) kg/m². SVI VATS thymectomy was performed with a short relaxation period for intubation, local anaesthesia for the right incision, and vagal and intercostal nerve blockade. After the relaxant effect, the patient breathed spontaneously, and a thymectomy was performed. Sufficient oxygenation was achieved with positive end-expiratory pressure (PEEP) and pressure support ventilation (PSV).

Results: SVI VATS thymectomy was performed without conversion to sternotomy, thoracotomy, or mechanical ventilation. The patients breathed spontaneously for 77.56% of the operative time. The median minimal arterial oxygen tension, median maximal arterial carbon dioxide tension, and median operative time were 82.4 (range, 56.1–247.2) mmHg, 59.2 (range, 44.8–67.8) mmHg, and 75 (range, 60–120) min, respectively. The median chest tube duration and length of postoperative hospital stay were 1 and 4 days, respectively. In one patient with MG, reintroduction of a chest tube was necessary because of pneumothorax. In two patients with MG, myasthenic symptoms progressed postoperatively and required neurological admittance, although no myasthenic crisis occurred. Histological analysis in the MG group revealed persistent thymus in seven cases, persistent thymus and follicular hyperplasia in three cases, and fatty tissue with lymphoid infiltration in one case. In the non-MG group, a persistent thymus was observed in two cases, while follicular hyperplasia and micronodular thymoma were reported in one case.

Conclusions: The SVI VATS approach is safe and feasible for thymectomy. However, further studies are required to verify the advantages of spontaneous ventilation during thymectomy for MG.

[^] ORCID: 0000-0002-7224-1642.

Keywords: Spontaneous ventilation; intubation; video-assisted thymectomy; myasthenia gravis (MG)

Received: 24 April 2023; Accepted: 31 October 2023; Published online: 09 November 2023.

doi: 10.21037/vats-23-37

View this article at: <https://dx.doi.org/10.21037/vats-23-37>

Introduction

The surgical approach for thymectomy has evolved considerably over the last century, from radical, open trans-sternal approaches originating from the beginning of the twentieth century to the first less invasive thoracoscopic approach in 1993 (1-4). Since the millennium, multiple minimally invasive approaches have been considered for this operation, such as multiportal and uniportal lateral approaches, subxiphoid video-assisted thoracic surgery (VATS), and the latest uniportal robotic-assisted thoracoscopic surgery (RATS), which is performed in numerous institutes throughout Europe and worldwide (5). Currently, radical thymectomy is predominantly performed using either VATS or RATS, with varying anatomical approaches and different anaesthesiologic methods (6-9).

In addition to the evolution of surgical approaches for thymectomies, especially for myasthenia gravis (MG), the challenges in anaesthesia management during and after surgery should be addressed. Postoperative respiratory complications, especially the development of postoperative myasthenic crisis (MC), can occur in approximately 34%

of patients who use the most common double-lumen tube intubation [Spontaneous Ventilation using a double-lumen tube Intubation (SVI)] method with relaxation and subsequent mechanical ventilation (10-12). Muscle relaxation and controlled mechanical ventilation contribute to the postoperative stress response after surgical trauma and may trigger MC (13,14). In such cases, the effects of relaxants can be unpredictable, possibly causing residual neuromuscular blockade. Regional anaesthetic techniques are prioritised in MG; however, when general anaesthesia is used for surgeries such as thymectomy, prudent anaesthetic management is mandatory. In addition to the use of short-acting relaxants or even the avoidance of muscle relaxants (15,16), neuromuscular blockade monitoring (e.g., train-of-four) with reduced doses of neuromuscular blocking agents (NMBAs) is necessary to minimise the incidence of postoperative pulmonary complications and the development of residual neuromuscular blockade or even MC.

To minimise the risk of postoperative neurological complications, innovations in general anaesthesia have resulted in the application of non-intubated thoracic surgery (NITS) techniques (17). Awake thoracoscopic thymectomy, another approach that does not require general anaesthesia, was experimentally performed in 2004 by Tsunetzuka *et al.* In their study, they performed an extended thymectomy on a fully awake patient under thoracic epidural anaesthesia using a median transsternal approach without opening the mediastinal pleura (18). Furthermore, in 2008, Matsumoto *et al.* developed a subxiphoid approach with sternal lifting for awake thymectomy without pleural damage (19).

The main concerns with NITS are a potentially unsafe airway and the possibility of a complicated conversion. To eliminate the issue of an unsafe airway while maintaining spontaneous ventilation, we developed a technique that combines spontaneous ventilation with SVI (20,21). In this study, we present early clinical experiences and results, as well as the advantages, of SVI in VATS thymectomy. We present this article in accordance with the STROBE reporting checklist (available at <https://vats.amegroups.com/article/view/10.21037/vats-23-37/rc>).

Highlight box

Key findings

- Double-lumen tube intubation technique [Spontaneous Ventilation using a double-lumen tube Intubation (SVI)] for video-assisted thoracic surgery thymectomy is a safe and feasible approach.

What is known and what is new?

- Thymectomy is the surgical treatment for myasthenia gravis, which is predominantly performed using minimally invasive techniques. The application of muscle relaxants can lead to serious postoperative complications such as myasthenic crisis or residual neuromuscular blockade.
- The SVI technique for myasthenia gravis provides a very short relaxant period followed by a long spontaneous ventilation time.

What is the implication, and what should change now?

- SVI is a safe technique which can reduce or eliminate the risk of postoperative neuromuscular complications after thymectomy for myasthenia gravis.

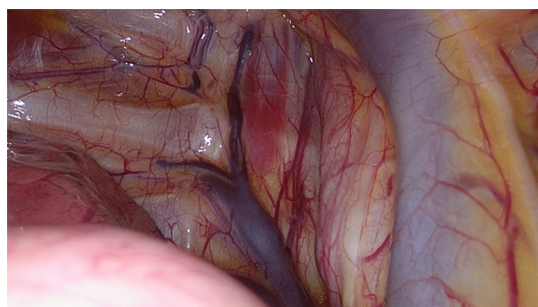


Figure 1 Identification of the right vagal nerve.

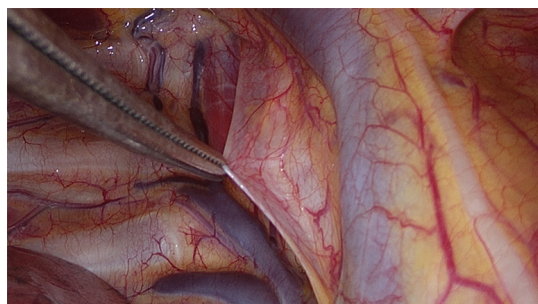


Figure 2 Lifting the pleura above the of the right vagal nerve.

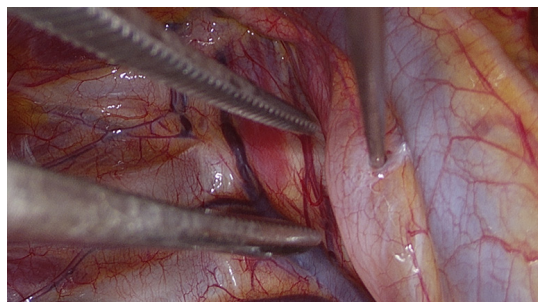


Figure 3 Administration of bupivacaine near the vagal nerve.

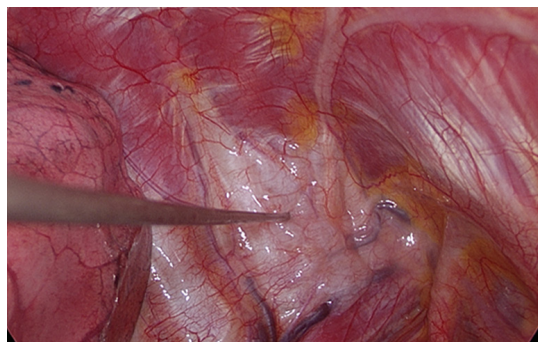


Figure 4 Paravertebral blockade.

Methods

Study design

All patients who underwent SVI VATS thymectomy in the Department of Surgery, University of Szeged, Hungary, between October 9, 2020 and December 31, 2022 were included in this study. Patient characteristics (sex and age), indications for surgery, intraoperative and postoperative data, and results were analysed. The follow-up period ended on March 31, 2023, so the median follow-up period was 13.5 months (range, 4–29 months).

Patient selection

The only exclusion criterion for SVI surgery was a body mass index (BMI) of $>30 \text{ kg/m}^2$. In some cases, a BMI of $>30 \text{ kg/m}^2$ was accepted for the SVI technique if the fatty tissue of the patient was located in the lower part of the body, away from the chest or abdomen.

Surgical methodology of SVI VATS thymectomy

The SVI VATS procedure has been previously published (20). This section briefly summarises the procedure. First, a short-acting muscle relaxant (mivacurium) was introduced, to insert the double-lumen endotracheal tube. During the relaxation period, surgical incisions were made on the right side, as per routine practice, after local infiltration with 2% lidocaine. Subsequently, the following surgical incisions were made: a 3-cm utility incision in the mid-axillary line, a 1-cm submammary fold incision for the camera, and a 5-mm incision for the instrument between the submammary fold and sternum. To block the cough reflex, 5 mL of 0.5% bupivacaine was administered near the right vagus nerve (*Figures 1–3*), and 4–5 mL was administered between two and five intercostal nerves close to the spine (paravertebral blockade) (*Figure 4*). After elimination of the short-acting muscle relaxant (mivacurium), the patient breathed spontaneously without coughing, and in some cases, 4–6 positive end-expiratory pressure (PEEP) was administered to maintain perfect oxygenation. During MG, complete thymectomy was performed by removing the thymus and perithymic fatty tissues. As a routine procedure, the right pericardium-diaphragm angle fat, aortocaval groove, and aortopulmonary window fat were removed. Phrenic nerves were identified on both sides. The innominate vein was visualised, and all horns of the thymus were dissected immediately into the neck. Additionally,

accessory horns, commonly under the innominate vein, were routinely examined and were not overlooked. The thymus was then dissected up to the left phrenic nerve, which was identified after opening the left pleura using a 30° viewing-angle optical camera. Anaesthesia provided pressure support ventilation (PSV) when the left side was opened, although inspiration and expiration were managed by the spontaneous ventilation of the patient alone (20). The specimen was placed in an Endobag and removed from the thoracic cavity through an axillary incision. At the end of the operation, a 28-Fr chest tube was inserted through a 10-mm port into the operated area.

Regarding the contraindications of the SVI technique, a BMI of $>30 \text{ kg/m}^2$ was the only exclusion criterion for SVI surgeries, and the other exclusion criteria of the NITS were not considered contraindications for SVI procedures (21).

Anaesthesiologic methodology of SVI VATS thymectomy

Here, we briefly summarise the anesthesiological arrangements for the SVI technique, the steps of which have been thoroughly explained in our previously published papers and are used in our clinical routine for VATS thymectomies (20,21). Midazolam and fentanyl were administered preoperatively. Anaesthesia was induced and maintained using propofol. After induction, muscle relaxation with mivacurium chloride was required for intubation and mechanical ventilation. Spontaneous breathing was allowed as soon as short-acting non-depolarising NMBAs were eliminated. During this period, vagal blockade was performed to prevent the cough reflex; therefore, when spontaneous breathing returned, the patient did not cough despite the double-lumen tube being inserted into the trachea. Oxygen saturation and pCO_2 were maintained within or close to the normal ranges, with higher FiO_2 and 3–5 PEEP applied to the dependent lung. In some cases, PSV was administered to maintain gas exchange within the normal range. Every patient was observed in our post-anaesthesia care unit for at least 2 h, and the visual analogue scale score was <3 . If required, oxygen was administered through a face mask at 2–4 L/min to exceed 94% of blood oxygen saturation (20). None of the patients required oxygen supplementation or advanced noninvasive respiratory support in the post-anaesthesia care unit or later during the postoperative period.

Statistical analysis in this study was not applied, because this paper is a pilot study to show the feasibility of the process, only. Comparative analysis will be in alter period of

the study, with more patients,

The study was conducted in accordance with the Declaration of Helsinki (as revised in 2013). The study was approved by the Ethics Committee of the Human Investigation Review Board of the University of Szeged (No. 4703/2020.01.20) and individual consent for this retrospective analysis was waived.

Results

In total, 155 surgeries were performed using the SVI technique. Among these, 58, 82, and 15 were SVI VATS lobectomies, sublobar resections, and SVI VATS thymectomies, respectively.

Fifteen patients with symptoms of MG ($n=11$) or radiologically suspected thymoma (non-MG) ($n=4$) who underwent SVI VATS resection for thymectomy were retrospectively included in this study.

Four patients without symptoms or a clinical diagnosis of MG were included in the non-MG group, three of whom had a preoperative diagnosis of thymoma, and one patient had a post-COVID accidental chest computed tomography (CT) scan diagnosis of persistent thymus without myasthenia.

The mean preoperative American Society of Anesthesiologists (ASA) score was 2.067, and three patients had ASA grade III. Patient characteristics are listed in *Table 1*.

No conversion to sternotomy/thoracotomy or mechanical ventilation was required in any patient. At the beginning of the operation, during an average of 22.44% of the operative time, the patients underwent mechanical one-lung ventilation, whereas for the remaining 77.56% of the operative time after the return of spontaneous ventilation, the patients breathed spontaneously. The perioperative results and patient data are summarised in *Table 2*.

The postoperative course was generally uneventful for all patients, and postoperative chest radiography revealed no signs of serious pulmonary complications, except in the aforementioned case where re-introduction of a chest tube was necessary. However, five days later, the patient was discharged without further complications.

Two patients were transferred to the neurology department. In one case of MG, the patient experienced proximal paresis of the upper limbs and impairment of ocular movement after surgery and was discharged after 5 days of neurological observation. In the other case, the patient's sensation of general fatigue progressed, and additional steroid therapy with pyridostigmine was required.

Table 1 Clinical details of the patients

Patient characteristics	Data
Females/males	10/5
Age (year)	38.9 [19–74]
BMI (kg/m ²)	24.6 [15.9–33.7]
Osserman classification of MG (n=11)	
I	3
IIa	4
IIb	3
III	0
IV	1
Preoperative treatment of MG (n=11)	
No pharmaceutical treatment	1
PB alone	7
PB + CS + AZA	1
PB + CS + AZA + IVIG	1
AC + RIX	1
TPE	0

Data are presented as mean [range] in age and BMI, and as No. in females/males, Osserman classification of MG, and preoperative treatment of MG. BMI, body mass index; MG, myasthenia gravis; PB, pyridostigmine bromide (Mestinon); CS, corticosteroid; AZA, azathioprine (Imuran); IVIG, intravenous immunoglobulin; AC, ambenonium chloride (Mytelase); RIX, rituximab; TPE, therapeutic plasma exchange (also known as plasmapheresis).

The patient was discharged within one week. None of the patients experienced MC, and the progression of MG symptoms after SVI VATS thymectomy was observed in only 9% of the patients (1/11). Residual neuromuscular blockade did not develop in any patient.

Discussion

VATS thymectomy is considered a standard minimally invasive surgical procedure, particularly for the treatment of MG. However, postoperative complications and the possibility of residual neuromuscular blockade remain concerns in patients with MG symptoms. According to Liu *et al.*, the incidence of postoperative MC is 5.88 times greater after thoracotomy compared to that in operations conducted after VATS (12,22).

Table 2 Perioperative results

Perioperative characteristics	Results
Operative time (min)	75 [60–120]
Chest tube duration (days)	1 [1–5]
Hospital stays (days)	4 [4–7]
Abnormality in the radiological results of the chest X-ray	
Fluid (no required intervention)	5/15
Pneumothorax (no required intervention)	2/15
Pneumothorax (required intervention)	1/15
Atelectasis (no required intervention)	3/15
Infiltration	0/15
Minimal arterial oxygen tension (mmHg)	82.4 [56.1–247.2]
Maximal arterial carbon-dioxide tension (mmHg)	59.2 [44.8–67.8]
Histology (n=15)	
Persistent thymus	9
Follicular hyperplasia	4
Micronodular thymoma	1
Lobulated fatty tissue + lymphoid infiltration	1

Data are presented as median [range] in operative time, chest tube duration, hospital stays, minimal arterial oxygen tension, maximal arterial carbon-dioxide tension; and as No. in abnormality in the radiological results of the chest X-ray, and histology cases.

To avoid the aforementioned adverse postoperative neuromuscular reactions in patients with MG, the NITS technique was applied to VATS thymectomies without the need for the administration of any type of muscle relaxant (23,24). A special risk can occur after neoadjuvant treatment of a thymoma when spontaneous ventilation during thymectomy is helpful (25).

However, the NITS approach has many important disadvantages, which limit the wide application this spontaneous ventilation method. First, careful selection of patients included criteria such as BMI <28 kg/m² and ASA grade I–II, and the lack of the following conditions: sleep apnoea, deranged preoperative blood gases, preoperative evidence of pleural adhesions, bleeding disorders or anticoagulation treatment, insufficient forced expiratory volume in 1 s, forced vital capacity, and potentially difficult

airway for intubation (6-8,17). Comparatively, in cases that used the SVI approach, the only exclusion criterion was BMI >30 kg/m².

Second, an unsafe airway that may occur during NITS increases the risk of conversion to intratracheal intubation for technical or anaesthetic reasons (10). However, the need for conversion in everyday practice is limited, and intubation can be performed relatively easily with the patient in prone. In SVI cases, this conversion is straightforward and requires only a few seconds for completion. Anaesthesia induces muscle relaxation, and no further action is necessary.

Third, spontaneous ventilation may occur when both pleural cavities are open (10). Although no difficulties are mentioned with oxygenation in previously published studies on this method, the use of PEEP has potential risks. In cases in which PEEP is required on both sides of the lungs through a laryngeal mask to support ventilation, surgeons may face technical difficulties because of the inflated lungs. According to Jiang *et al.*, NITS VATS thymectomy does not require vagus blockade; however, 6 mL of 2% lidocaine is sprayed onto the lung surface to reduce the cough reflex (11). However, they did not mention any problems with the gas exchange. In our SVI VATS thymectomy cases, no difficulties with gas exchange were observed because oxygenation was managed with PEEP or PSV through the tube.

Regarding some postoperative surgical results, no relevant differences were observed in the chest tube duration (1 *vs.* 1.9 and 3.5 days) and hospitalisation duration (4 *vs.* 2.66, 2.5, and 4.7 days) between our SVI results and data from previously published literature that employed NITS technique (6-8).

In our SVI cases, the patients received relaxants for a short time at the beginning of surgery, and the duration of mechanical ventilation under the effect of the muscle relaxant was only 22.44% of the total surgery duration. During the remaining period (77.56%), surgeries were performed under spontaneous ventilation. This method helps to prevent residual neuromuscular blockade.

This pilot study has some limitations. First, this was a retrospective, monocentric, interventional cohort study. Second, the small number of patients, as the most important limitation, is the key to many further limitations. In this pilot study, we aimed to demonstrate a new and safe method for spontaneous ventilation VATS thymectomy which is applicable in MG cases. Third, the small sample size of this study prevented a broad statistical analysis of the data, which were mainly reported descriptively. Fourth, owing

to the lack of a control group, the results of the SVI VATS thymectomy cases were not compared with those of the relaxed series. In the future, with an extended number of SVI VATS thymectomy cases, a comparison between SVI VATS thymectomy and the standard techniques will be presented.

Conclusions

The SVI method for VATS thymectomy is a safe and feasible procedure that reduces the amount of relaxant drug administered and its possible adverse effects on postoperative neurological complications in patients with MG.

During the spontaneous ventilation period of SVI surgery, patients with MG should be closely monitored for the development of a possible residual neuromuscular blockade, in which a 'biological test' provides a safe postoperative period.

Acknowledgments

Funding: None.

Footnote

Reporting Checklist: The authors have completed the STROBE reporting checklist. Available at <https://vats.amegroups.com/article/view/10.21037/vats-23-37/rc>

Data Sharing Statement: Available at <https://vats.amegroups.com/article/view/10.21037/vats-23-37/dss>

Peer Review File: Available at <https://vats.amegroups.com/article/view/10.21037/vats-23-37/prf>

Conflicts of Interest: All the authors have completed the ICMJE uniform disclosure form (available at <https://vats.amegroups.com/article/view/10.21037/vats-23-37/coif>). J.F. serves as an unpaid editorial board member of *Video-Assisted Thoracic Surgery* from July 2022 to June 2024. The other authors have no conflicts of interest to declare.

Ethical Statement: The authors are accountable for all aspects of the work in ensuring that questions related to the accuracy or integrity of any part of the work are appropriately investigated and resolved. The study was conducted in accordance with the Declaration of Helsinki

(as revised in 2013). The study was approved by the Ethics Committee of the Human Investigation Review Board of the University of Szeged (No. 4703/2020.01.20) and individual consent for this retrospective analysis was waived.

Open Access Statement: This is an Open Access article distributed in accordance with the Creative Commons Attribution-NonCommercial-NoDerivs 4.0 International License (CC BY-NC-ND 4.0), which permits the non-commercial replication and distribution of the article with the strict proviso that no changes or edits are made and the original work is properly cited (including links to both the formal publication through the relevant DOI and the license). See: <https://creativecommons.org/licenses/by-nc-nd/4.0/>.

References

- Kaufman AJ, Palatt J, Sivak M, et al. Thymectomy for Myasthenia Gravis: Complete Stable Remission and Associated Prognostic Factors in Over 1000 Cases. *Semin Thorac Cardiovasc Surg* 2016;28:561-8.
- Zieliński M. Surgical Approaches to Myasthenia Gravis: Perspective of Anatomy and Radicality in Surgery. *Thorac Surg Clin* 2019;29:159-64.
- Ashour M. Prevalence of ectopic thymic tissue in myasthenia gravis and its clinical significance. *J Thorac Cardiovasc Surg* 1995;109:632-5.
- Sugarbaker DJ. Thoracoscopy in the management of anterior mediastinal masses. *Ann Thorac Surg* 1993;56:653-6.
- Gonzalez-Rivas D, Ismail M. Subxiphoid or subcostal uniportal robotic-assisted surgery: early experimental experience. *J Thorac Dis* 2019;11:231-9.
- Liu Z, Yang R, Sun Y. Nonintubated Uniportal Thoracoscopic Thymectomy with Laryngeal Mask. *Thorac Cardiovasc Surg* 2020;68:450-6.
- Liu Z, Yang R, Sun Y. Non-intubated subxiphoid uniportal video-assisted thoracoscopic thymectomy. *Interact Cardiovasc Thorac Surg* 2019;29:742-5.
- Liu Z, Zhang L, Tang W, et al. Non-intubated uniportal subxiphoid thoracoscopic extended thymectomy for thymoma associated with myasthenia gravis. *World J Surg Oncol* 2021;19:342.
- O'Sullivan KE, Kreaden US, Hebert AE, et al. A systematic review of robotic versus open and video assisted thoracoscopic surgery (VATS) approaches for thymectomy. *Ann Cardiothorac Surg* 2019;8:174-93.
- Pompeo E, Elkhoully AG. Spontaneous ventilation thoracoscopic thymectomy: attractive or exceptionable? *J Thorac Dis* 2018;10:S3981-3.
- Jiang L, Depypere L, Rocco G, et al. Spontaneous ventilation thoracoscopic thymectomy without muscle relaxant for myasthenia gravis: Comparison with "standard" thoracoscopic thymectomy. *J Thorac Cardiovasc Surg* 2018;155:1882-1889.e3.
- Liu C, Liu P, Zhang XJ, et al. Assessment of the risks of a myasthenic crisis after thymectomy in patients with myasthenia gravis: a systematic review and meta-analysis of 25 studies. *J Cardiothorac Surg* 2020;15:270.
- Collins S, Roberts H, Hewer I. Anesthesia and Perioperative Considerations for Patients With Myasthenia Gravis. *AANA J* 2020;88:485-91.
- Blichfeldt-Lauridsen L, Hansen BD. Anesthesia and myasthenia gravis. *Acta Anaesthesiol Scand* 2012;56:17-22.
- Brull SJ, Kopman AF, Naguib M. Management principles to reduce the risk of residual neuromuscular blockade. *Curr Anesthesiol Rep* 2013;3:130-8.
- Neuman A, Granlund B. Anesthesia for Patients With Myasthenia Gravis. 2022 Jul 18. In: StatPearls [Internet]. Treasure Island (FL): StatPearls Publishing; 2023.
- Liang H, Liu J, Wu S, et al. Nonintubated Spontaneous Ventilation Offers Better Short-term Outcome for Mediastinal Tumor Surgery. *Ann Thorac Surg* 2019;108:1045-51.
- Tsunezuka Y, Oda M, Matsumoto I, et al. Extended thymectomy in patients with myasthenia gravis with high thoracic epidural anesthesia alone. *World J Surg* 2004;28:962-5: discussion 965-6.
- Matsumoto I, Oda M, Watanabe G. Awake endoscopic thymectomy via an infrasternal approach using sternal lifting. *Thorac Cardiovasc Surg* 2008;56:311-3.
- Furák J, Szabó Z. Spontaneous ventilation combined with double-lumen tube intubation in thoracic surgery. *Gen Thorac Cardiovasc Surg* 2021;69:976-82.
- Furák J, Barta Z, Lantos J, et al. Better intraoperative cardiopulmonary stability and similar postoperative results of spontaneous ventilation combined with intubation than non-intubated thoracic surgery. *Gen Thorac Cardiovasc Surg* 2022;70:559-65.
- Geng Y, Zhang H, Wang Y. Risk factors of myasthenia crisis after thymectomy among myasthenia gravis patients: A meta-analysis. *Medicine (Baltimore)* 2020;99:e18622.
- Rieth A, Lazar G, Kovacs T, et al. Do we even need to

- relax? Evolution of non-intubated video assisted thoracic surgery thymectomy for myasthenia gravis—a narrative review. *AME Surg J* 2022;2:16.
24. AlGhamdi ZM, Ahn S, Kim KC, et al. Non-intubated uniportal VATS surgery is feasible approach. *J Thorac Dis* 2020;12:1147-50.
25. Patelli G, Bencardino K, Tosi F, et al. Chemotherapy-induced myasthenic crisis in thymoma treated with primary chemotherapy with curative intent on mechanical ventilation: a case report and review of the literature. *J Med Case Rep* 2021;15:32.

doi: 10.21037/vats-23-37

Cite this article as: Furák J, Németh T, Budai K, Farkas A, Lantos J, Glenz JR, Fabó C, Shadmanian A, Buzás A. Spontaneous ventilation with double-lumen tube intubation for video-assisted thoracic surgery thymectomy: a pilot study. *Video-assist Thorac Surg* 2023;8:37.