

# Soft Bandage Contact Lenses in Management of Early Bleb Leak Following Trabeculectomy

Zhenggen Wu\*, Chukai Huang, Yuqiang Huang, Wanqi Zhang, Di Ma

The Joint Shantou International Eye Center (JSIEC) of Shantou University and the Chinese University of Hong Kong, Shantou 515041, China

## Abstract

**Purpose:** To investigate the efficacy of a soft bandage contact lens in the management of early bleb leak following trabeculectomy.

**Methods:** Between October 2011 and April 2013, 11 patients with early bleb leak following fornix-based trabeculectomy were instructed to wear a soft bandage contact lens 14 mm in diameter continuously for 1-2 weeks. The daily visual acuity, intraocular pressure (IOP), anterior chamber situation, and healing condition were measured at 1, 3, and 7 d, after contact lens removal, and 3 months after trabeculectomy. The conditions of blebs, sensation of wearing contact lens, and adverse events were recorded.

**Results:** Bleb leaks were observed at 2–8 d after surgery, ( $4.09 \pm 1.10$  d on average). The daily LogMAR visual acuity did not significantly differ before and after contact lens wear ( $P > 0.05$ ). The IOP was significantly raised after at 1, 3, and 7 d after lens wear (all  $P < 0.05$ ). The IOP at 3 months after lens wear did not significantly differ from that measured at lens removal ( $t = 1.191$ ,  $P = 0.089$ ). At 1 d after lens wear, 6 cases had deeper anterior chambers. All patients presented with a significantly deepened anterior chamber at 3 d after lens wear, and were restored to the preoperative conditions. The bleb leakage was successfully treated at 7 d after lens removal in 10 patients, while 1 patient had to wear the contact lens for another 7 d for full healing of the bleb leak. No ocular infection was noted throughout the management.

**Conclusion:** A soft bandage contact lens of 14 mm diameter is a safe and efficacious therapy for an early bleb leak following fornix-based trabeculectomy. (*Eye Science* 2015; 30: 13–17)

**Keywords:** contact lens; trabeculectomy; early bleb leak

## Introduction

One common complication early after trabeculectomy is a bleb leak, which can cause adverse effects such as low intraocular pressure (IOP) and intraocular infection. Bleb leaks are currently treated mainly by surgical sutures, bandages, and wearing bandage contact lenses of 17.5 or 20.5 mm diameter<sup>1–3</sup>. Soft bandage contact lenses of 14 mm diameter are mainly applied to protect the cornea, accelerate corneal healing, and mitigate irritative symptoms<sup>4</sup>. This clinical trial used a 14 mm diameter contact lens to treat early bleb leaks after fornix-based trabeculectomy. The lenses showed relatively high clinical efficacy, with outcomes as reported below.

## Materials and methods

### Clinical data

From October 2011 to April 2013, 11 patients (four males and seven females) aged 16–66 years ( $49 \pm 16$  years on average) presented with early bleb leak after undergoing trabeculectomy at our hospital. Among them, six cases were additionally treated with trabeculectomy combined with the administration of mitomycin C, while five underwent trabeculectomy alone. Subsequently, they were instructed to wear soft bandage contact lenses (14 mm in diameter). The clinical efficacy of the lenses was evaluated. Inclusion criteria: Patients undergoing fornix-based trabeculectomy combined with/without use of mitomycin, those with no surgical complications intraoperatively, those presenting with postoperative bleb leak (positive outcomes by the Seidel test), and those with a grade I shallow anterior chamber (Spaeth classification) were enrolled<sup>5</sup>. Exclusion criteria: Patients with alternative intraoperative or post-

DOI: 10.3969/j.issn.1000-4432.2015.01.003

**Funding:** This study was supported by Fund for Medical Sciences of Guangdong Province (Grant: B2012264)

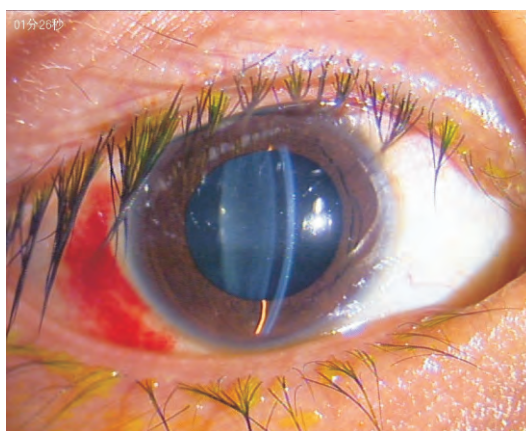\* **Corresponding author:** Zhenggen Wu, E-mail: wzg@jsiec.org

operative complications, those with grade II/III shallow anterior chamber, those who failed to pay a timely return visit, and those who were followed up for <3 months were excluded from this clinical trial. All patients underwent a fornix-based conjunctival flap procedure, the sclera and conjunctival flap were intermittently sutured, the conjunctival flap was kept watertight, and no bleb leak was noted after surgery.

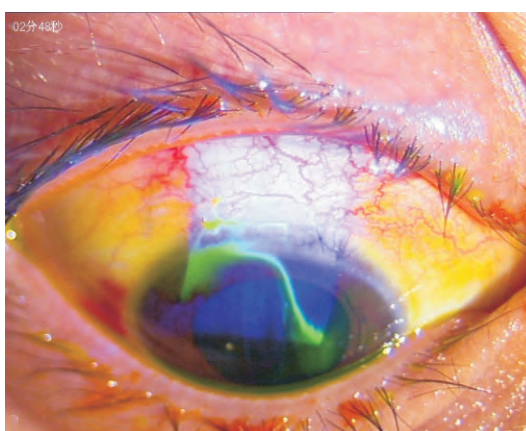
### Methods

A standard visual acuity chart was used to examine the visual acuity. A non-contact tonometer (TX-F, Canon, Japan) was employed for IOP measurement. The anterior segment of eye was examined by slit-lamp examination (Haag-Streit-BQ900, Switzerland) and anterior segment OCT (Visante OCT, Carl Zeiss, Germany). The presence of a bleb leak was confirmed by fluorescence staining. Those with positive outcomes by the Seidel test had bleb leakage (Figures 1 and 2). Patients' daily visual acuity was measured. Daily visual acuity was referred to as the visual acuity measured when the patients were wearing lenses. Those without lens wear before examination requires no visual correction test. The visual acuity, IOP, anterior chamber condition, time of bleb leak, time of contact lens wear, time of lens removal, and the degree of ocular comfort were recorded. After diagnosis of a bleb leak, all patients wore soft bandage contact lenses (Pure Vision, BC=8.6, refractive power=-0.5D, 14 mm in diameter), as illustrated in Figure 3. The visual acuity, IOP, and anterior chamber depth were measured at 1, 3, and 7 d, after lens removal, and 3 months after surgery, as shown in Figures 4 and 5. The patients with bleb leak were required to wear contact lenses for another 7 d and were subsequently examined for the incidence of bleb leak. The visual acuity, IOP, and slit-lamp examination were performed by one single physician. During the measurement of anterior chamber depth, the included angle between the slit-lamp light source and ocular lens was set at 30 degrees. The ratio of the distance between the central corneal endothelium and the anterior lens capsule to the central corneal thickness (CCT) was used as an index for comparison (Figure 1).

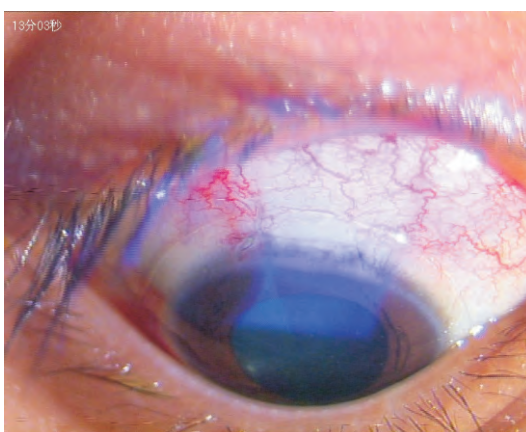
The patients wore the contact lens in a supine position. First, an aseptic forceps was used to clamp the



**Figure 1** Slit-lamp examination revealing the shallowing of the anterior chamber before contact lens wear

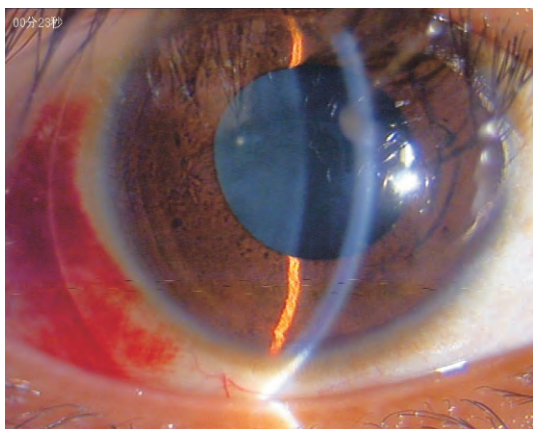


**Figure 2** The eye with a positive Seidel test prior to contact lens wear

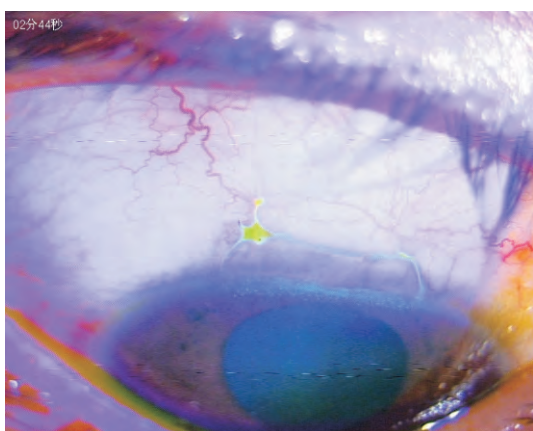


**Figure 3** The contact lens was kept in a central position and covered the incision

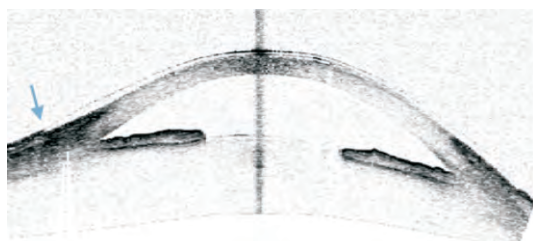
contact lens, which was then gently placed into the patient's eye and then the patient was told to gently close the eye. The central position of the contact lens was confirmed by slit-lamp examination. The con-



**Figure 4** The deepening of the anterior chamber at 1 d after contact lens wear



**Figure 5** Wound healing after contact lens removal



**Figure 6** Conjunctival wound healing after contact lens wear by anterior segment OCT

cave surface should be attached to the cornea when wearing the contact lens. Drug administration after contact lens wear included 0.3% levofloxacin and 1% prednisolone acetate eye drops administered 4 times daily, compound tropicamide eye drops twice daily, and 0.3% tobramycin dexamethasone ointment was given daily in the evening.

### Statistical analysis

SPSS 17.0 statistical software was used for data analysis. Visual acuity test results were converted to logarithm of minimal angle of resolution (logMAR)<sup>6</sup>. General data and each parameter were expressed as means $\pm$ s. The visual acuity, IOP, and anterior chamber depth measured at different time points were statistically compared by ANOVA for repeated measurement. If the data did not conform to the test of sphericity, Greenhouse-Geisser degree of freedom was utilized for adjustment. Paired comparison at different time points was statistically analyzed by the Bonferroni method.  $P < 0.05$  was considered as statistically significant.

### Results

The bleb leaks were found between 2 to 8 d after surgery ( $4.09 \pm 1.10$  d on average). All patients were required to wear contact lenses beginning on the day the bleb leak was noted.

Daily visual acuity: the median visual acuity was 0.2 (HM-0.6) before contact lens wear, 0.25 (HM-0.6) at 1 d, 0.3 (HM-0.8) at 3 d, 0.4 (HM-0.6) at 7 d, and 0.4 (HM-1.0) at 3 months after lens wear. After contact lens wear, visual acuity tended to improve, and did not significantly differ from that before lens wear ( $F = 2.642$ ,  $P = 0.119$ ).

IOP: The IOP significantly differed before and af-

**Table 1** Comparison of the changes in visual acuity, IOP, and anterior chamber depth before and after bandage contact lens wear (means $\pm$ s)

	Visual acuity (LogMAR)	Intraocular pressure (mmHg)	Anterior chamber depth (CCT)
Bleb leak	0.94 $\pm$ 0.87	6.88 $\pm$ 1.10	1.55 $\pm$ 0.52
At 1 d after contact lens wear	0.93 $\pm$ 0.88	10.15 $\pm$ 4.59	1.96 $\pm$ 0.57
At 3 d after contact lens wear	0.92 $\pm$ 0.88	11.99 $\pm$ 4.35	2.50 $\pm$ 0.50
At 7 d after contact Lens wear	0.86 $\pm$ 0.88	12.25 $\pm$ 3.26	3.05 $\pm$ 0.65
Contact lens removal	0.86 $\pm$ 0.88	12.34 $\pm$ 3.20	3.05 $\pm$ 0.65
3 months after surgery	0.76 $\pm$ 0.94	13.44 $\pm$ 4.36	3.05 $\pm$ 0.65
<i>F</i>	2.642	7.459	100.143
<i>P</i>	0.119	0.004	0.000

ter lens wear ( $F=7.459$ ,  $P=0.004$ ). The IOP levels at 1, 3, and 7 d after lens wear were significantly enhanced compared with that prior to lens wear ( $tD1=3.264$ ,  $P=0.038$ ;  $tD3=5.109$ ,  $P=0.002$ ;  $tD7=5.364$ ,  $P=0.000$ ). The IOP at 3 months following lens wear did not significantly differ from that measured at lens removal ( $t=1.191$ ,  $P=0.089$ ).

**Anterior chamber depth:** The mean anterior chamber depth was  $1.55\pm 0.52$  mm when bleb leakage was found. At 24 h after bandage contact lens wear, the mean anterior chamber depth was  $1.96\pm 0.57$  mm and six cases had deepening anterior chamber. At 3 d after lens wear, all patients presented with significantly deepening anterior chamber with mean value of  $2.50\pm 0.50$  mm; the anterior chamber depth was restored to preoperative levels at 1 week after lens wear. Anterior chamber depth significantly differed before and after bandage lens wear ( $F=100.143$ ,  $P=0.000$ ). The anterior chamber depths measured at 1, 3, and 7 d after lens wear were significantly larger than that prior to lens wear ( $tD1=0.409$ ,  $P=0.011$ ;  $tD3=0.955$ ,  $P=0.000$ ;  $tD7=1.500$ ,  $P=0.000$ ). The anterior chamber depth at 7 d after lens wear was almost equivalent to the preoperative depth.

All participants had good tolerability of the bandage contact lens and reported no incidence of ophthalmalgia or severe sensation of foreign bodies. In all cases, the contact lens was centered during follow-up. No lens dislocation was noted. The incision of the bleb leak was well healed. Ten patients had wound healing at 7 d after lens wear. One patient had recurrent bleb leak after lens removal, and was told to wear the contact lens for another 7 d, and the wound was healed. No ocular adverse events were noted.

## Discussion

Bleb leak is a common early complication of trabeculectomy, and may lead to low IOP, choroidal detachment, and macular lesions, as well as increased risk of intraocular infection. Poor wound healing is likely to result in filtering bleb dysfunction, *etc*<sup>1</sup>. Early bleb leaks are frequently caused by sutures loosening or gap formation after conjunctival edema is alleviated. In addition, use of mitomycin could inhibit the healing of the conjunctival incision

and increase the risk of a conjunctival bleb leak. Conventional management of bleb leaks includes bandage wraps and surgical sutures<sup>2</sup>. A bandage compression wrap affects visual acuity, aggravates the severity of pain, and is inconvenient for conducting eye examinations. Improper wrapping can also aggravate the shallowing of the anterior chamber. Surgical suturing requires two operations, which increases surgical expense and the psychological burden on the patients. The fragility of the conjunctiva after surgery also increases the possibility of surgical failure.

The bandage contact lens is designed with an ideal arc that matches the corneal shape, which yields good ocular surface contact and supplies favorable support. In addition, it does not affect the patient's visual acuity or increase the sense of discomfort. It is convenient for examining the anterior chamber; hence, it is a quite suitable approach<sup>3,4</sup>. Previous studies used bandage contact lenses with large diameters of 17.5 or 20.5 mm to treat bleb leaks<sup>2,3</sup>. This size is difficult to apply in clinical practice due to demanding production techniques and high price. In contrast, Pure Vision is a type of gas permeable soft contact lens made of silicon-hydrogel with a gas permeability of  $110\times 10^{-9}$  unit, a base curve of 8.6, refractive power -0.5D, and a diameter of 14 mm<sup>4</sup>. It is readily obtainable by clinics at a low price. The incision of a fornix-based conjunctival flap is made at the corneoscleral limbus so a bandage contact lens with a diameter of 14 mm could completely cover this type of incision. Therefore, we used this lens for the treatment of bleb leak in the present study.

In this clinical trial, the conjunctival incision was completely covered by the contact lens. The conjunctiva and sclera were in full contact. A slight filtering bleb bulge was noted, but no dislocation or tilt of the contact lens was observed. Anterior segment OCT examination revealed that the conjunctival incision was well healed. After bandage contact lens wear, the wound was well healed and the anterior chamber was gradually deepened in all cases. The bandage contact lens attached well to the cornea, while the ocular surface tension promoted the attachment of the conjunctival incision, providing an interface for conjunctival growth. Inhibiting the aqueous

humor leak accelerated the functional recovery of anterior chamber.

The bandage contact lens is made of hydrophilic materials and could be worn for as long as 3 months<sup>3,4</sup>. In this study<sup>11</sup>, patients were administered topical antibiotics and hormone eye drops during bandage contact lens wear. At 7 d after lens wear, 10 cases had good wound healing, and the remaining patient had to wear the contact lens for another week, by which time the wound was well healed. No infectious events occurred. The bandage contact lens was therefore confirmed as a safe and efficacious therapy for bleb leak that does not intervene the use of ocular medication.

Hormone eye drops inhibits the growth of the conjunctival flap, so that discontinued use probably increases the risk of postoperative scarring. Patients in this study were administered hormone eye drops with dose reduction. No adverse events were observed after night use of ointment. One male patient, aged 60 years, had to continue to wear the contact lens for a recurrent bleb leak after undergoing trabeculectomy combined with use of mitomycin, probably because the use of mitomycin inhibited the growth of conjunctival flap. Elderly patients generally have to wear contact lenses for longer times due to their relatively slow healing. The other 10 patients undergoing the same therapy were much younger. After 7 d of lens wear, no statistically significant difference was noted in the conjunctival healing of different patients.

In this study, daily visual acuity was not significantly influenced by bandage contact lens wear, and no evident ocular discomforts were reported, probably because the conjunctival incision was completely covered by the contact lens, thereby easing any eye irritation. The bandage contact lenses were well tolerated by the patients. Compared with conventional compression wrap, the lens neither affects visual acuity nor aggravates ocular pain of the patients. It is also convenient for conducting eye examinations,

and IOP measurements are not affected when the patients are wearing bandage contact lenses<sup>7</sup>. In the present study, the IOP could be measured during contact lens wear. During the 3 months of follow-up, the IOP was properly controlled in all patients, suggesting that bandage contact lens wear would not increase the risk of filtering bleb failure in patients with bleb leak, which is consistent with the findings of Alwitry et al<sup>1</sup>.

The results of this study confirm that wearing a bandage contact lens with a diameter of 14 mm is a safe and efficacious treatment for bleb leak after trabeculectomy. The lens does not affect the visual acuity, anterior chamber observation, or IOP measurement. However, the clinical outcomes should be further investigated by subsequent investigations with a larger sample size.

## References

- 1 Alwitry A, Rotchford A, Patel V, et al. Early bleb leak after trabeculectomy and prognosis for bleb failure. *Eye (Lond)*, 2009, 23(4): 858–863.
- 2 Leung DY, Tham CC. Management of bleb complications after trabeculectomy. *Semin Ophthalmol*, 2013, 28 (3): 144–156.
- 3 Shoham A, Tessler Z, Finkelman Y, et al. Large soft contact lenses in the management of leaking blebs. *CLAO J*, 2000, 26(1): 37–39.
- 4 Arora R, Jain S, Monga S, et al. Efficacy of continuous wear PureVision contact lenses for therapeutic use. *Cont Lens Anterior Eye*, 2004, 27(1): 39–43.
- 5 Spaeth GL. *Ophthalmic surgery: Ophthalmic Surgery: Principles and Practice*. Ind. ed. Philadelphia: WB Saunders Co 1990: 241–245.
- 6 Wang QM, Wang CX. Standardization of national visual acuity chart. *Chinese Journal of Optometry Ophthalmology and Visual Science*, 2013, 15(10): 577–580.
- 7 Anton A, Neuburger M, Böhringer D, et al. Comparative measurement of intraocular pressure by Icare tonometry and Airpuff tonometry in healthy subjects and patients wearing therapeutic soft contact lenses. *Graefes Arch Clin Exp Ophthalmol*, 2013, 251(7): 1791–1795.