

Meta-analysis of the effect of perioperative injection of Lucentis on intraoperative bleeding in patients with proliferative diabetic retinopathy

Guoqi Guan¹, Jing Zang²

¹Jinan University, Guangzhou 510632, China; ²Department of Ophthalmology, The First Affiliated Hospital of Guangdong Pharmaceutical University, Guangzhou 510080, China

Contributions: (I) Conception and design: J Zang; (II) Administrative support: J Zang; (III) Provision of study materials or patients: J Zang; (IV) Collection and assembly of data: G Guan; (V) Data analysis and interpretation: G Guan; (VI) Manuscript writing: All authors; (VII) Final approval of manuscript: All authors.

Correspondence to: Jing Zang, Department of Ophthalmology, The First Affiliated Hospital of Guangdong Pharmaceutical University, Guangzhou 510080, China. Email: zang62@yahoo.com.

Background: The effect of perioperative injection of Lucentis on intraoperative bleeding in patients with proliferative diabetic retinopathy (PDR) was systematically evaluated using a meta-analysis.

Methods: Reports of surgical eye treatment with and without perioperative intravitreal injection of Lucentis in Medline, the Cochrane Library, PubMed, the Chinese Biomedical Literature Database, and China Academic Journals Full-text Database were included in the study. A meta-analysis was performed on all included literature. A computerized search was performed in the above databases. In addition, relevant books, journals, and conference proceedings and their bibliographies were manually searched. Published literature was screened according to the inclusion and exclusion criteria. Data extraction was performed on included studies. RevMan5.2 software was used for the statistical analyses. Dichotomous variables are presented as odds ratios (ORs) and 95% confidence intervals (CIs). The major indicator was the occurrence of intraoperative retinal hemorrhaging during vitrectomy.

Results: A total of seven studies were included in the analysis. The treatment group included 159 eyes and control group included 149 eyes. The amount of intraoperative bleeding in the treatment group (perioperative Lucentis injection) was significantly lower than that in the control group (OR, 56.93; 95% CI: 21.81-148.57, $P < 0.01$).

Conclusions: Intravitreal Lucentis injection before a vitrectomy significantly reduced intraoperative bleeding in PDR patients.

Keywords: Perioperative; Lucentis; proliferative diabetic retinopathy (PDR); vitrectomy; retinal hemorrhage; diabetic retinopathy (DR)

Submitted Oct 20, 2015. Accepted for publication Nov 24, 2015.

doi: 10.3978/j.issn.1000-4432.2015.11.14

View this article at: <http://dx.doi.org/10.3978/j.issn.1000-4432.2015.11.14>

Introduction

Proliferative diabetic retinopathy (PDR) presents in the late stage of diabetic retinopathy (DR). The most important sign of this condition is angiogenesis, which usually causes vitreous hemorrhages, neovascular membrane formation, traction retinopathy, macular exudate, and edema, resulting

in blindness and severe vision loss (1,2).

The most effective treatment method for PDR is vitrectomy. A vitrectomy can clear vitreous hemorrhages caused by PDR and relieve retinal traction caused by the vitreous body. However, the proliferative fibrovascular membrane of PDR patients is closely adhered to the retina;

therefore, pulling or stripping the membrane during surgery can cause massive hemorrhaging, which is difficult to stop. Massive hemorrhaging definitely influences the surgical field and results in the extension of surgical time and the development of complications such as iatrogenic retinal damage (3). A current focus of international research involves solving the issue of hemorrhaging during vitrectomy. Intraocular injection of Lucentis, developed by Genentech (USA), has become a new trend and a focus of research for the treatment of ocular vascular diseases. Currently, several studies have shown that intraocular injection of Lucentis into patients could promote degeneration and atrophy of new blood vessels and vitreous hemorrhage absorption (4-6). To determine whether perioperative administration of Lucentis can relieve intraoperative hemorrhaging and facilitate surgery, we performed this meta-analysis to evaluate the influence of perioperative injection of Lucentis on intraoperative hemorrhaging in PDR patients.

Material and methods

Search strategy

A computerized search of Medline, the Cochrane Library, PubMed, the Chinese Biomedical Literature Database, and China Academic Journals Full-text Database was performed. The Chinese search terms included perioperative, ranibizumab, Lucentis, vitrectomy, retinal hemorrhage, DR, PDR, and anti-VEGF. The English search terms consisted of perioperative, Lucentis, bevacizumab (avastin), anti-VEGF, DR, PDR, vitrectomy, hemorrhage, and bleeding. The search period was between January 1978 and October 2014. No limitation was placed on the language type or publication status. In addition, relevant books, journals, and conference proceedings and their bibliographies were manually searched.

Literature inclusion and exclusion criteria

The literature inclusion criteria consisted of the following: studies of vitrectomies performed on PDR patients; prospective studies in which the treatment group received preoperative intravitreal injection of Lucentis and the control group did not receive this drug; a follow-up time of at least 6 months; and observation indicators that included the number of patients with severe intraoperative bleeding. Conference abstracts, repeated publications, case reports,

reviews, and letters were excluded.

Literature evaluation and data extraction

The relevance of all research papers was confirmed by two researchers based on the titles and abstracts. The full articles were then evaluated to determine whether they should be included for analysis. All data were independently extracted by two researchers using standard data extraction forms. The extracted data included the authors, research location, publication time, follow-up time, sample sizes, characteristics of the study subjects, intervention measures, and endpoint data. If the opinions of the two researchers differed, a consensus was reached by discussion.

Statistical methods

A meta-analysis was performed using RevMan5.2 software. Dichotomous variables are presented as odds ratios (ORs) and 95% confidence intervals (CIs). The heterogeneity among all studies was examined using Q-statistics. In addition, the level of heterogeneity was evaluated using the I² quantitative analysis. The method for data combination was selected based on the heterogeneity examination results. Data combination was performed with the fixed effects model if the heterogeneity among the research results was not significant. If significant heterogeneity existed among the research results, the random effects model was used. Factors that might show heterogeneity such as the disease course of diabetes mellitus and the control condition of diabetes mellitus were subjected to sub-group analysis or sensitivity analysis. An inverted funnel plot was used to evaluate publication bias. A value of $P < 0.05$ indicated a statistically significant difference.

Results

Literature search results and characteristics of included studies

According to the planned search strategy, seven studies (5,7-12) were included in the meta-analysis. The seven included studies consisted of a total of 308 PDR patients; among these patients, 159 eyes received preoperative intravitreal injection of Lucentis and were included in the treatment group, and 149 eyes did not receive this treatment and were included in the control group. The follow-up time was 6 months. The surgical methods, DR diagnosis

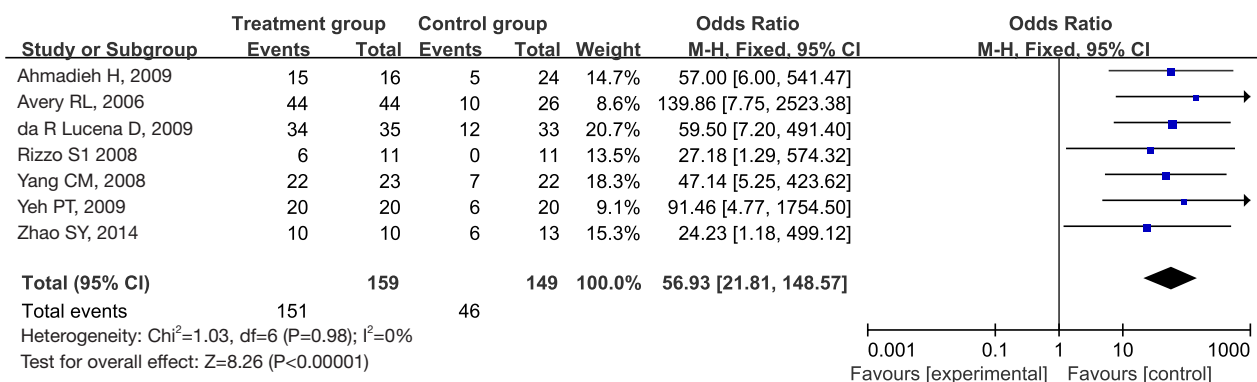


Figure 1 Comparison of bleeding during surgery between eyes in the treatment and control groups.

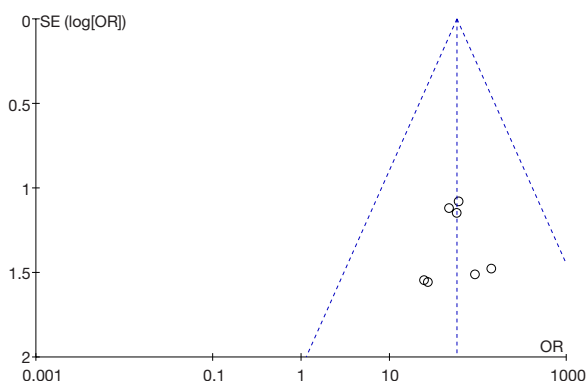


Figure 2 The inverted funnel plot of the seven studies of intraoperative bleeding. OR, odds ratio.

classification criteria, and DR progression determination methods were all similar.

Retinal hemorrhaging during vitrectomy

The seven studies all showed a difference between the treatment and control groups in the occurrence of retinal hemorrhaging during vitrectomy in PDR patients. *Figure 1* shows the ORs and 95% CIs of each study. The examination of the heterogeneity among all studies did not show statistically significant differences (I²=0%, P=0.98). The fixed effects model was used for data combination. After data combination, the OR was 56.93 (95% CI: 21.81-148.57, P<0.01). The difference was statistically significant. *Figure 2* shows the absence of significant publication bias.

Discussion

We used a meta-analysis to systemically evaluate the

influence of perioperative injection of Lucentis on intraoperative bleeding in PDR patients. The analytical results showed that intraoperative bleeding in the treatment group was significantly reduced compared to that of the control group; in addition, the surgical time was significantly shortened. Six months of follow-up showed that PDR patients who received intravitreal injection of Lucentis before a vitrectomy exhibited reduced postoperative complications, greater increases in corrected visual acuity after surgery, vitreous hyperplasia, and reduced rebleeding.

The occurrence and progression of angiogenesis in PDR patients is currently a difficult clinical issue because bleeding of new blood vessels can cause a loss of integrity of the vitreous body, result in the formation of vitreous and retinal organizational membranes, induce traction retinal detachment, damage visual function, and increase the risks of massive hemorrhaging and difficult hemostasis. Massive hemorrhaging will influence the surgical field, can cause the extension of surgical time, and can induce complications such as iatrogenic retinal damage.

In recent years, with the development of molecular and cell biology technology, the role of cytokines in DR has received increased attention. Application of Lucentis for DR (especially PDR) treatment in clinical practice has increased. Studies have shown that treatment of PDR patients with Lucentis could cause a significant decrease or disappearance of new blood vessels and inhibit angiogenesis by suppressing the formation of vascular buds of new blood vessels, thus reducing fundus bleeding and exudate in PDR patients, relieving retinal edema, reducing the risk of bleeding during membrane detachment, shortening surgical time, decreasing the occurrence of postoperative complications,

and increasing visual acuity (6,13-19). This study examined the effects of Lucentis application on the elimination of new blood vessels in seven studies. These studies showed that preoperative injection of Lucentis into PDR patients could cause a significant decrease or disappearance of new blood vessels. During the surgery, most proliferative membranes in patients became thinner, little bleeding occurred, the surgical field was clear, the surgical time was shortened, and the occurrence of iatrogenic retinal breaks was reduced. In addition, because retinal edema was reduced and the exudate was decreased, the proliferative membrane could easily be removed, and retinal photocoagulation could be performed; therefore, postoperative rebleeding and proliferation were significantly reduced.

The inclusion of randomized controlled trials would provide the strongest evidence for our study. However, it is difficult to select two groups of patients with similar conditions, such as diabetes and hypertension, as well as with similar degrees of DR. In addition, in a randomized controlled trial, if patients were assigned to a control group for follow-up for 6 months, treatment of their postoperative complications might be delayed, which does not conform to the principle of ethics. Although the current study method includes subjects with different degrees of deficits, it still produces persuasive research evidence.

In summary, perioperative injection of Lucentis can significantly decrease intraoperative bleeding in PDR patients, shorten surgical time, reduce surgical complications, and decrease the incidence of postoperative vitreous hyperplasia and hemorrhage. However, this study was limited by the small sample size and short follow-up time; therefore, the strength of our argument is limited. A large amount of data, more samples, and prospective randomized controlled trials are needed to study the exact effects of the reduction of intraoperative bleeding in PDR patients by perioperative injection of Lucentis, and the optimal injection time needs to be determined. However, our study is still encouraging for PDR patients and shows excellent application prospects.

Acknowledgements

None.

Footnote

Conflicts of Interest: The authors have no conflicts of interest to declare.

References

1. Ciardella AP, Klancnik J, Schiff W, et al. Intravitreal triamcinolone for the treatment of refractory diabetic macular oedema with hard exudates: an optical coherence tomography study. *Br J Ophthalmol* 2004;88:1131-6.
2. Micelli Ferrari T, Sborgia L, Furino C, et al. Intravitreal triamcinolone acetate: valuation of retinal thickness changes measured by optical coherence tomography in diffuse diabetic macular edema. *Eur J Ophthalmol* 2004;14:321-4.
3. Nicholson BP, Schachat AP. A review of clinical trials of anti-VEGF agents for diabetic retinopathy. *Graefes Arch Clin Exp Ophthalmol* 2010;248:915-30.
4. Minnella AM, Savastano CM, Ziccardi L, et al. Intravitreal bevacizumab (Avastin) in proliferative diabetic retinopathy. *Acta Ophthalmol* 2008;86:683-7.
5. Avery RL, Pearlman J, Pieramic DJ, et al. Intravitreal bevacizumab (Avastin) in the treatment of proliferative diabetic retinopathy. *Ophthalmology* 2006;113:1695.e1-15.
6. Spaide RF, Fisher YL. Intravitreal bevacizumab (Avastin) treatment of proliferative diabetic retinopathy complicated by vitreous hemorrhage. *Retina* 2006;26:275-8.
7. Yang CM, Yeh PT, Yang CH, et al. Bevacizumab pretreatment and long-acting gas infusion on vitreous clear-up after diabetic vitrectomy. *Am J Ophthalmol* 2008;146:211-7.
8. Ahmadi H, Shoeibi N, Entezari M, et al. Intravitreal bevacizumab for prevention of early postvitrectomy hemorrhage in diabetic patients: a randomized clinical trial. *Ophthalmology* 2009;116:1943-8.
9. Yeh PT, Yang CM, Lin YC, et al. Bevacizumab pretreatment in vitrectomy with silicone oil for severe diabetic retinopathy. *Retina* 2009;29:768-74.
10. Zhao SY, Liang XJ, Lin YJ, et al. Pars plana vitrectomy assisted with lucentis for proliferative diabetic retinopathy. *J Clin Ophthalmol* 2014;22:237-40.
11. Rizzo S, Genovesi-Ebert F, Di Bartolo E, et al. Injection of intravitreal bevacizumab (Avastin) as a preoperative adjunct before vitrectomy surgery in the treatment of severe proliferative diabetic retinopathy (PDR). *Graefes Arch Clin Exp Ophthalmol* 2008;246:837-42.
12. da R Lucena D, Ribeiro JA, Costa RA, et al. Intraoperative bleeding during vitrectomy for diabetic tractional retinal detachment with versus without preoperative intravitreal bevacizumab (IBeTra study). *Br J Ophthalmol* 2009;93:688-91.
13. Oshima Y, Sakaguchi H, Gomi F, et al. Regression

- of iris neovascularization after intravitreal injection of bevacizumab in patients with proliferative diabetic retinopathy. *Am J Ophthalmol* 2006;142:155-8.
14. Moradian S, Ahmadi H, Malihi M, et al. Intravitreal bevacizumab in active progressive proliferative diabetic retinopathy. *Graefes Arch Clin Exp Ophthalmol* 2008;246:1699-705.
 15. Chen E, Park CH. Use of intravitreal bevacizumab as a preoperative adjunct for tractional retinal detachment repair in severe proliferative diabetic retinopathy. *Retina* 2006;26:699-700.
 16. Messias A, Ramos Filho JA, Messias K, et al. Electroretinographic findings associated with panretinal photocoagulation (PRP) versus PRP plus intravitreal ranibizumab treatment for high-risk proliferative diabetic retinopathy. *Doc Ophthalmol* 2012;124:225-36.
 17. Arevalo JF, Wu L, Sanchez JG, et al. Intravitreal bevacizumab (Avastin) for proliferative diabetic retinopathy: 6-months follow-up. *Eye (Lond)* 2009;23:117-23.
 18. Salam A, Mathew R, Sivaprasad S, et al. Treatment of proliferative diabetic retinopathy with anti-VEGF agents. *Acta Ophthalmol* 2011;89:405-11.
 19. Ishikawa K, Honda S, Tsukahara Y, et al. Preferable use of intravitreal bevacizumab as a pretreatment of vitrectomy for severe proliferative diabetic retinopathy. *Eye (Lond)* 2009;23:108-11.

Cite this article as: Guan G, Zang J. Meta-analysis of the effect of perioperative injection of Lucentis on intraoperative bleeding in patients with proliferative diabetic retinopathy. *Eye Sci* 2015;30(4):171-175. doi: 10.3978/j.issn.1000-4432.2015.11.14