

## Case Report

# Late-onset Lens Particle Glaucoma as a Consequence of Posterior Capsule Rupture after Pars Plana Vitrectomy

Yihua Su<sup>1</sup>, Zhen Mao<sup>2</sup>, Yi Liu<sup>2</sup>, Yuxia Yang<sup>2</sup>, Xing Liu<sup>2\*</sup>

1.The First Affiliated Hospital of Sun Yat-sen University, Guangzhou 510080, China

2.State Key Laboratory of Ophthalmology, Zhongshan Ophthalmic Center, Sun Yat-sen University, Guangzhou 510060, China

## Abstract

**Purpose:** To report the treatment of late-onset lens particle glaucoma associated with posterior capsule rupture during pars plana vitrectomy.

**Methods:** Case report.

**Results:** A 33-year-old man had severe pain and impaired vision in the left eye after vitrectomy, associated with white fleck-like particles circulating in the anterior chamber. The intraocular pressure (IOP) was 38 mmHg. The anterior lens capsule was intact, however, lens particle glaucoma was diagnosed by the slit-lamp examination, B-mode ultrasonography and ultrasound biomicroscopy (UBM). The lens material was removed by irrigation-aspiration after the patient remained face down for two hours to facilitate precipitation of the lens material from the vitreous into the anterior chamber. IOP after the procedure was 21 mmHg.

**Conclusion:** Posterior lens capsule may be disrupted during vitrectomy. Although the anterior lens capsule is intact, lens particle glaucoma should be considered when IOP increases with particulate matter circulating in the anterior chamber. Surgical removal of this material may be sufficient to control IOP without the need for additional glaucoma surgery. (*Eye Science* 2012; 27:47–49)

**Keywords:** lens particle glaucoma; pars plana vitrectomy; intraocular pressure

**L**ens particle glaucoma occurs when liberation of lens material obstructs the trabecular meshwork and increases the resistance of aqueous outflow<sup>1</sup>. This disorder may be precipitated by penetrating lens injury, cataract extraction, or Nd:YAG laser posterior capsulotomy<sup>2</sup>. In most reported cases, lens particle

was released into the anterior chamber through the rupture of anterior capsule. The present paper reports a case of lens particle glaucoma that was caused by posterior capsule rupture after pars plana vitrectomy (PPV).

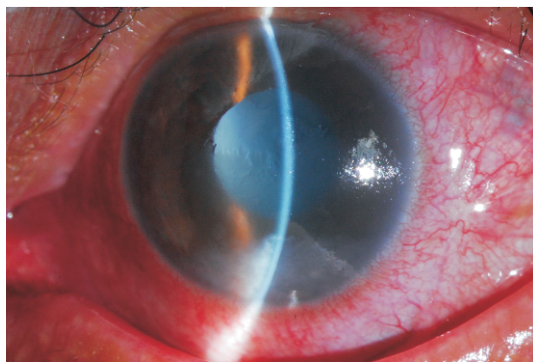
A 33-year-old man made complaints of severe pain and redness in the left eye for three months. The patient was diagnosed with glaucoma secondary to uveitis and received clinical treatment at local clinics for two months with no improvement. Seven months before clinical presentations, he had received PPV in the left eye because of vitreous hemorrhage in another hospital. His visual acuity was improved to 20/50 post-operatively; but this was only maintained for one week. Thereafter, blurred vision increased generally; however, the patient did not consult doctors any more. He denied having had any recent trauma or laser procedure on his left eye.

His best corrected visual acuity was hand movement before the left eye, and 20/20 in the right eye. The IOP, measured by applanation tonometry, was 38 mmHg in the left eye and 18 mmHg in the right eye. There was severe circumcorneal and diffuse conjunctival injection in the left eye; the corneal edema was also noted. The anterior chamber was deep with heavy cells(+++) and no hypopyon. Numerous large white flecks were observed circulating in the aqueous and the white floccule, deposited in the inferior of the anterior chamber. The lens was entirely white-opaque with an intact anterior capsule (Figure 1). The posterior capsule, the vitreous, and the retina were invisible because of lens opacification.

B-mode ultrasonography showed vitreous opacities and mass-like high-level echo in the left eye (Figure

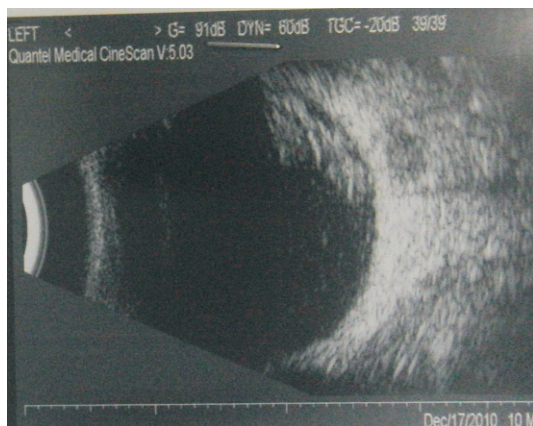DOI: 10.3969/j.issn.1000-4432.2012.01.011

\*Corresponding author: Xing Liu, E-mail: liuxing@mail.sysu.edu.cn

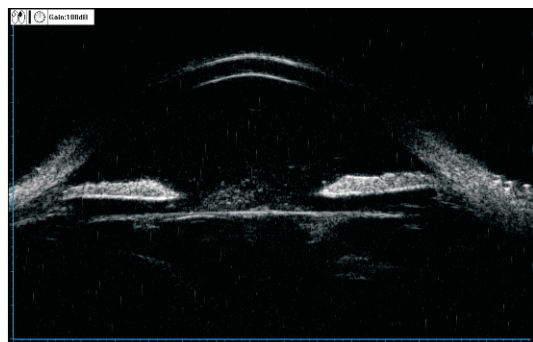


**Figure 1** The slit lamp photograph of the left eye showed white floccule in the anterior chamber.

2). UBM examination of the left eye displayed open anterior chamber angle, that the echo of the lens anterior capsule was intact, and that abundant particles were located in the inferior angle and posterior to the iris (Figure 3). Although the lens anterior capsule was intact, lens particle glaucoma was diagnosed according to the operation history, the anterior cham-



**Figure 2** Type-B ultrasound showed vitreous opacities and mass-like high-level echo in the left eye.

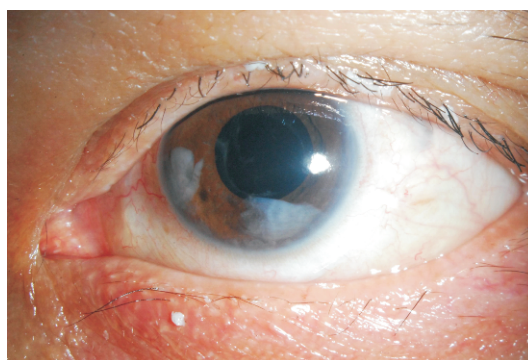


**Figure 3** UBM of left eye showed presence of wide-open angles, and echo of the lens was not intact. There was abundant exudation around the back of iris and inferior angle.

ber particles, lens opacity, B-mode ultrasonography, and UMB outcomes.

Intensive medical treatments, including systemic and topical anti-glaucomatous medications, and steroid eyedrops, were administered. However, the IOP remained  $> 30$  mm Hg even after adequate anti-glaucomatous therapy with systemic and local medications for two days. Cataract extraction was completed with irrigation-aspiration techniques, which lowered the IOP to 8 mm Hg, and a 0.2 ml sample of the white material in the aqueous was obtained. A posterior lens capsule rupture from 5 o'clock to 11 o'clock was confirmed intra-operatively. Though mobile white flecks in the posterior vitreous were investigated during the operation, PPV was not performed simultaneously because the patient had received PPV seven months ago. Histological examination of the aqueous aspirate revealed macrophages and free lens cortical material. The diagnosis of lens particle glaucoma was proved.

On the first day post-operatively, the IOP was 11 mmHg. However, white lens material originally located in the posterior vitreous migrated into the anterior chamber 1 week after operation again (Figure 4). To entirely remove the residual lens material and to avoid repeated PPV, we asked the patient to remain prostrated for two hours to ensure all lens material in the vitreous body deposited into the anterior chamber, which turned out to be effective; all the residual material was cleared after twice irrigation-aspiration operations. At a one-month follow-up, the best corrected visual acuity was finger counting  $> 4$  cm, and the IOP was 21 mmHg with no anti-glaucomatous eye drops. The cornea was clear, and no



**Figure 4** One week after operation, some cortical matter was seen in the anterior chamber.

cortical matter was seen in the anterior chamber or vitreous cavity.

## Discussion

In most cases, lens particle glaucoma is hard to be misdiagnosed when the precipitating event is obvious, such as a history of penetrating surgery or cataract extraction. These precipitating events tend to cause anterior lens capsule disruption, and lens material is liberated into the anterior chamber, which blocks the trabecular meshwork<sup>3</sup>.

The authors report a case that developed late onset lens particle glaucoma three months after PPV. The patient's anterior lens capsule was intact, which explained why it took a long time to develop secondary glaucoma. The lens material was released into the posterior chamber and vitreous cavity first. The migration of the lens particles from the posterior chamber to the anterior chamber could be induced by subclinical damages to zonular, the anterior, or the equatorial capsule. The patient was misdiagnosed as glaucoma secondary to uveitis (which also presented with ciliary injection, anterior chamber inflammation, and high IOP) at a local clinic. However, in uveitis, the particles of the anterior chamber were much smaller than the lens particles. Surgical history and B-mode ultrasonography assisted the differential diagnosis.

The lens material should be surgically removed immediately to control the IOP. PPV is a necessary procedure to eliminate the lens particles in the vitreous<sup>4,5</sup>. For the patients with a history of PPV and anterior and posterior capsular ruptures, irrigation-aspiration operation combined with prostrated position is feasible to clear the lens material and avoid vitrectomy complications.

## References

- 1 Kee C, Lee S. Lens particle glaucoma occurring 15 years after cataract surgery. *Korean J Ophthalmol*, 2001; 15: 137–139.
- 2 Lim MC, Doe EA, Vroman DT, et al. Late onset lens particle glaucoma as a consequence of spontaneous dislocation of an intraocular lens in pseudoexfoliation syndrome. *Am J Ophthalmol*, 2001; 132: 261–263.
- 3 Nadia A. Hassan, Margaret A. Late Occurrence of Lens Particle Glaucoma Due to an Occult Glass Intralenticular Foreign Body. *Middle East Afr J Ophthalmol*, 2009 Apr–Jun; 16(2): 97–99.
- 4 Schaal S, Barr CC. Management of retained lens fragments after cataract surgery with and without pars plana vitrectomy. *J Cataract Refract Surg*, 2009; 35 (5): 863–867.
- 5 Ho LY, Doft BH, Wang L, et al. Clinical predictors and outcomes of pars plana vitrectomy for retained lens material after cataract extraction. *Am J Ophthalmol*, 2009; 147(4): 587–594.