

# Hydrophobic Acrylic Intraocular Lens in Both Eyes

Shengli Hao<sup>1,\*</sup>, Hong Zhang<sup>2</sup>

*1 Department of Ophthalmology, Tianjin Binhai New Area Dagang Hospital, Affiliated Hospital of Tianjin Medical University, School of Clinical Medicine, Tianjin 300270, China*

*2 Tianjin Medical University Eye Centre, Tianjin 300070, China*

## Abstract

**Purpose:** To report on the clinical findings of a case of late opacification of the hydrophobic acrylic intraocular lens (IOLs) in both eyes after cataract surgery.

**Methods:** A 79-year-old man with a history of decreased visual acuity and complaints of glare and blurred vision in both eyes over the past 3 years. He had received an uneventful phacoemulsification combined with posterior chamber IOL implantation for senile cataract in both eyes 13 years ago, and had undergone neodymium:YAG (Nd:YAG) laser posterior capsulotomy on both eyes 6 years ago, for posterior capsular opacification (PCO). The optical portion of the IOLs showed uniform gray haze. Binocular posterior capsular laser holes were clearly noted.

**Results:** IOL exchange was performed by the same surgeon on both eyes, three days apart. Postoperatively, the patient's visual acuity was elevated to 6/12 (OD) and 6/9 (OS) at 6 months, and intraocular pressure (IOP) reached 16.8 mmHg (OD) and 18.4 mmHg (OS). Neither glare or blurred vision were observed in either eye.

**Conclusion:** IOL exchange can be used to effectively manage clinically significant optic opacification. (*Eye Science 2012; 27:158–160*)

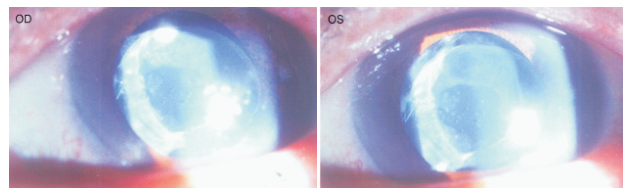
**Keywords:** hydrophobic acrylic; intraocular lens; opacification

Phacoemulsification with IOL implantation is a commonly performed procedure. IOL opacification is a potential complication of IOL implantation. In the past decade, previous studies have reported the formation of calcium deposits on IOL intraoperative-

ly, during the early or late postoperative periods<sup>1,2</sup>. IOL exchange surgery is sometimes the only solution<sup>2</sup>. Our case reports late opacification of the hydrophobic acrylic IOL in both eyes and its exchange.

## Case report

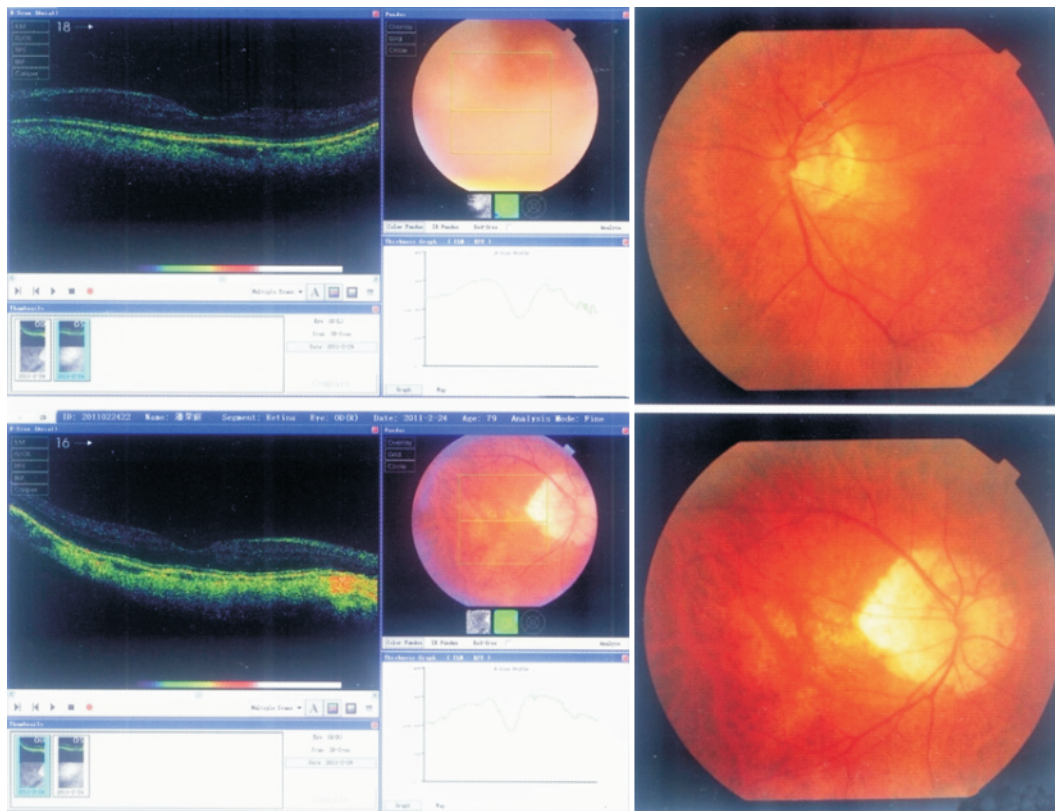
A 79-year-old male had suffered a significant decrease in visual acuity and complained about glare and blurred vision in both eyes over the past 3 years. He underwent uneventful phacoemulsification combined with posterior chamber IOL implantation for senile cataract in both eyes 13 years ago, and Nd:YAG laser posterior capsulotomy on both eyes for PCO 6 years ago. He had no special medical history and his body state was in good condition. He received complete ophthalmic examinations. The best corrected visual acuity (BCVA) in both eyes was 6/60. The IOP on non-contact tonometry was 15.1 mmHg (OD) and 13.7 mmHg (OS) respectively. Clear corneas and white conjunctiva were observed. Bilateral anterior chambers with normal depth revealed no cells or flare. Bilateral pupils were round, 3 mm in diameter, light reflex (+). Optical portion of the IOL showed uniform gray haze in a fully dilated pupil. Bilateral posterior capsular laser holes were clear (Figure.1). Fundus examination and optical coherence tomography (OCT, 3D OCT-2000, TOP-



**Figure 1** Slit-lamp photograph showing the optic portion of the IOL displayed uniform gray haze in a fully dilated pupil in both eyes. Binocular posterior capsular laser holes were clear.

DOI:10.3969/j.issn.1000-4432.2012.03.010

**Corresponding author:** Shengli Hao. Department of Ophthalmology, Tianjin Binhai New Area Dagang Hospital, Affiliated Hospital of Tianjin Medical University, School of Clinical Medicine, Binhai New Area, Tianjin 300270, China. E-mail: taishanmaple@126.com



**Figure 2** The fundus photograph and optical coherence tomography (OCT, 3D OCT-2000, TOPCON, Japan) scan showed binocular leopard fundus, parapapillary choroidal atrophy arc.

CON, Japan) scan showed binocular leopard fundus, parapapillary choroidal atrophy arc (Figure.2). The patient was diagnosed with bilateral IOL opacification and post-Nd: YAG posterior capsulotomy.

IOL exchange was performed on one eye and on the fellow eye 3 days later by the same surgeon. During surgery, the IOL optic adhered to the capsular bag in both eyes, then the IOL was divided into two pieces through its optic and each piece was removed through the corneal incision using forceps. The posterior capsular laser holes were observed intraoperatively. Anterior vitrectomy was performed and a new hydrophilic acrylic posterior chamber IOL (Aqua-Sense, SN: 11040-1326, Aaren Scientific Inc, Ontario, USA) was placed in the ciliary sulcus. The explanted IOL showed complete optic opacification. The patient's visual acuity was improved to 6/12 (OD) and 6/9(OS) at 6 months after IOL exchange surgery, and the IOP was 16.8 mmHg (OD), 18.4 mmHg (OS). Glare and blurred vision were observed in neither eye.

## Discussion

IOL opacification is one of the rare complications following cataract surgery. In spite of a number of clinical reports regarding postoperative opacified IOL, including polymethyl methacrylate (PMMA), silicone, and hydrophilic acrylic IOL, few reports referring to opacification of hydrophobic acrylic IOL have been conducted<sup>1,3</sup>. In this paper, we reported late opacification of hydrophobic acrylic IOL in both eyes and followed by IOL exchange.

The symptoms of IOL opacification include blurred vision, glare and haloes, monocular diplopia and decreased contrast sensitivity<sup>4</sup>. IOL opacification frequently occurs at 3 periods: prior to surgery, at the early and late postoperative stages.

Histopathological studies using light microscopy, scanning electron microscopy, energy-dispersive x-ray spectroscopy showed that opacification was caused by granular deposits composed of calcium phosphate hydroxide, hydroxyapatite, protein, inorganic salt,

et al on/in the surface of both anterior and posterior IOLs<sup>2,3,5,6,7</sup>.

Various pathologic processes may lead to clinically significant opacification or discoloration of the optic component of IOL manufactured from different biomaterials and in different designs. A serial of factors, such as, the patient's systemic and ocular conditions (diabetes mellitus, hypertension, ischemic heart disease, and uveitis), the manufacturing process, the method of IOL storage, the surgical technique and adjuvants (viscoelastic devices and mitomycin C) or combined factors may be involved<sup>1,3,5,7</sup>. The patient in our case had no history of diabetes, hypertension and others systemic diseases or other ocular lesions. Binocular IOL opacification occurred at 13 years postoperatively, belonging to long-term post-operative opacification. There was no relationship between IOL opacification and the operation of substance used or protein deposits. Since binocular implantation of the same type of IOL, it was speculated that the opacification of hydrophobic acrylic IOL was caused by trace water molecules that infiltrated the optic and visible light scatter<sup>1</sup>.

The failure to recognize the process of IOL opacification or discoloration may prompt surgeons to perform unnecessary surgical procedures, such as Nd: YAG laser posterior capsulotomy or vitrectomy, since the opacification is located in the IOL itself rather than in the posterior capsule or the vitreous<sup>6</sup>. Several factors seem to affect the patients' need for IOL explantation, including the magnitude of the opacity

and the effect on visual acuity and contrast sensitivity function and the patient's lifestyle<sup>4,7</sup>. IOL exchange is the most effective management for clinically significant optic opacification.

## References

- 1 Werner L, Dornelles F, Hilgert CR, et al. Early opacification of silicone intraocular lenses; Laboratory analyses of 6 explants. *J Cataract Refract Surg*, 2006; 32 (3): 499–509.
- 2 Dhital A, Spalton DJ, Goyal S, et al. Calcification in Hydrophilic Intraocular Lenses Associated With Injection of Intraocular Gas. *Am J Ophthalmol*, 2012; 153 (6): 1154–1160.
- 3 Lim AK, Goh PP, Azura R, et al. Opacification of AcriFlex 50CSE hydrophilic acrylic intraocular lenses. *J Cataract Refract Surg*, 2011; 37(4): 655–659.
- 4 Blundell MS, Mayer EJ, Knox Cartwright NE, et al. The effect on visual function of Hydroview intraocular lens opacification; a cross-sectional study. *Eye (Lond)*, 2010; 24(10): 1590–1598.
- 5 Park DH, Shin JP, Kim HK, et al. Hydrophilic acrylic intraocular lens (Akreos AO MI60) optic opacification in patients with diabetic retinopathy. *Br J Ophthalmol*, 2010; 94(12): 1688–1689.
- 6 Haymore J, Zaidman G, Werner L, et al. Misdiagnosis of hydrophilic acrylic intraocular lens optic opacification; report of 8 cases with the MemoryLens. *Ophthalmology*, 2007; 114(9): 1689–1695.
- 7 Altaie RW, Costigan T, Donegan S, et al. Investigation and management of an epidemic of Hydroview intraocular lens opacification. *Graefes Arch Clin Exp Ophthalmol*, 2005; 243(11): 1124–1133.