

# In vivo Implantation of Hydrophobic Acrylic Intraocular Lenses with Surface Modification

Guiqin Wang<sup>1</sup>, Liqun Cao<sup>1</sup>, Na Li<sup>1</sup>, Xiujun Peng<sup>1</sup>, Huiqin Tang<sup>2</sup>, Rongxin Wan<sup>2</sup>, Hanqing Gu<sup>2,\*</sup>

<sup>1</sup> Department of Ophthalmology, the Naval General Hospital, Beijing 100048, China

<sup>2</sup> Tianjin Medical University, Tianjin Institute of Urological Surgery, Tianjin 300211, China

## Abstract

**Purpose:** To assess the surface properties of modified hydrophobic acrylic intraocular lenses (IOL) implanted in rabbits.

**Methods:** The hydrophobic acrylic IOLs were modified with monomer vinyl pyrrolidone by surface modification technique. Phacoemulsification combined with IOL implantation was conducted in 9 rabbits (18 eyes). Postoperative responses were observed by slit-lamp microscope at 3, 7, 15, 30, 90 days after surgery.

**Results:** During the early stage after IOL implantation, corneal edema and anterior chamber fibrin exudation were observed. The exudate fluid was almost absorbed at the 15th day postoperatively. At 7th day, the anterior chamber exudation in the modification group was significantly less severe than that in non-modification group ( $P < 0.05$ ). Posterior capsular opacification occurred at 30th day after surgery and was aggravated 90 days later. IOL dislocation was seen in 5 eyes and occlusion of pupil in 3 eyes.

**Conclusion:** The hydrophobic acrylic IOLs with surface modification have improved surface properties and higher uveal biocompatibility. (*Eye Science* 2013; 28:176–179)

**Keywords:** intraocular lenses; surface modification; surface property; *in vivo* experiment

## Introduction

Intraocular lens (IOL) implantation is the most effective treatment of cataract patients. The materials of IOL determine the development of IOL and cap-

tivate widespread attention. Albeit hydrophobic acrylic IOL is the primary choice for most physicians, it presents with multiple problems. Hydrophobic surface property is likely to induce static electricity. The air dusts and metabolites in the eyes are inclined to attaching to the IOL surface, which affect the transparency and light transmittance after IOL implantation and the long-term efficacy<sup>1,2</sup>. Consequently, surface modification technique was adopted to modify the hydrophobic properties of hydrophobic acrylic IOLs using vinyl pyrrolidone monomer, and the modified IOLs were implanted into rabbit eyes to evaluate their surface properties.

## Materials and methods

### Study group

Nine rabbits were randomly divided into two groups.

Non-modification group: phacoemulsification combined with lens extraction was performed and the untreated hydrophobic acrylic IOLs were implanted.

Modification group: phacoemulsification combined with lens extraction was conducted and the hydrophobic acrylic IOLs treated with vinyl pyrrolidone monomer was implanted in rabbit eyes.

### Surgical methods

Compound tropicamide was prepared for mydriasis. A mixture of 2 ml (0.1 g) ketamine hydrochloride and 1.5 ml xylazine hydrochloric acid were prepared at 1:1 ratio for muscular anesthesia. The anesthesia dose was 0.22 ml/kg. After conventional disinfection, corneal limbus incision was made, viscoelastic agent was injected, capsulorhexis was conducted using needles, viscoelastic agents were injected after phacoemulsification and viscoelastic agents were removed following posterior chamber IOL im-

DOI: 10.3969/j.issn.1000-4432.2013.04.002

Funding: National Natural Science Foundation of China (Grant No.8107 0716)

\* Corresponding author: Hanqing Gu. E-mail: cjbmee@263.net

plantation. If wound closure failure was noted, the wound was further closed by 10-0 nylon sutures and treated with tobramycin and dexamethasone until the surgery was concluded.

**Postoperative observation**

Postoperative responses including corneal edema, anterior chamber exudation and posterior capsular opacification were observed under slit-lamp microscope at 3, 7, 15, 30 and 90 days postoperatively.

**Grade classification**

The severity of corneal edema was graded as follows: (-) transparent cornea, (+) slight corneal edema, ruffled Descemet’s membrane, (++) partial corneal epithelial and stromal layer edema, (+++) corneal full-thickness opacity and edema.

The severity of anterior chamber fibrin exudation was graded as follows: (-) normal anterior chamber, (+) lamellae exudates seen in the anterior chamber, (++) one layer of exudates and a small mass of exudates in the anterior chamber, (+++) a large mass of exudates in the anterior chamber.

The severity of posterior capsular opacification was graded as follows: (-) transparent, (+) mild opacity, (++) moderate opacity and (+++) serious opacity.

**Statistical analysis**

The data were statistically analyzed by non-parameter rank sum test (*H* test) and *t*-test.

**Results**

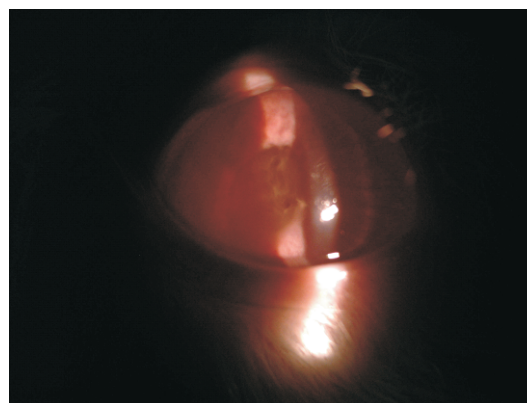
The most severe corneal edema was observed at postoperative 3 days and gradually alleviated at postoperative 15 days. At the postoperative 7 days, the severity of corneal edema in the modification group was less serious compared with that in the non-modification group with no statistical significance, as shown in Table 1 and Figures 1–6.

The exudation in the anterior chamber was the most severe at the postoperative 3 days, and almost absorbed at the postoperative 15 days. At the 7<sup>th</sup> day postoperatively, the severity of anterior chamber exudation in the modification group was significantly less severe than that in the non-modification group ( $P < 0.05$ ), as illustrated in Table 2 and Figures 1–6.

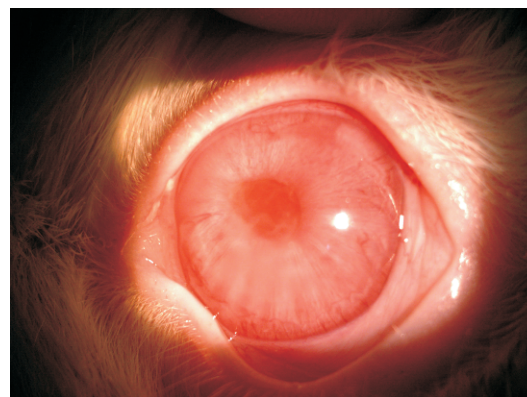
Posterior capsular opacification was observed at the 30<sup>th</sup> day and gradually aggravated at the postop-

**Table 1** Comparison of corneal edema between two groups

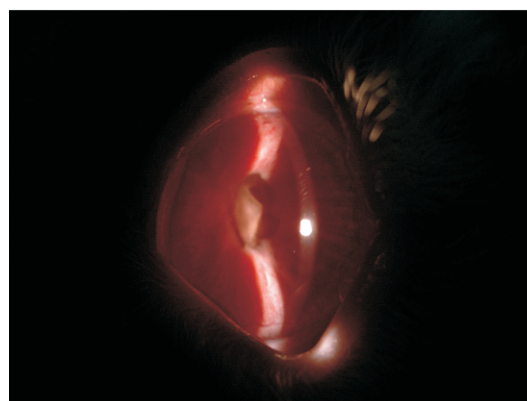
Postoperative days	Non-modified					Modified					<i>H</i>	<i>P</i>
	-	+	++	+++	<i>n</i>	-	+	++	+++	<i>n</i>		
3 d	5	1	2	1	9	7	0	2	0	9	0.89	>0.05
7 d	5	2	2	0	9	7	2	0	0	9	1.39	>0.05
15 d	5	3	0	0	8	7	1	0	0	8	1.26	>0.05
30 d	7	0	0	0	7	7	0	0	0	7	0	>0.05
90 d	6	0	0	0	6	6	0	0	0	6	0	>0.05



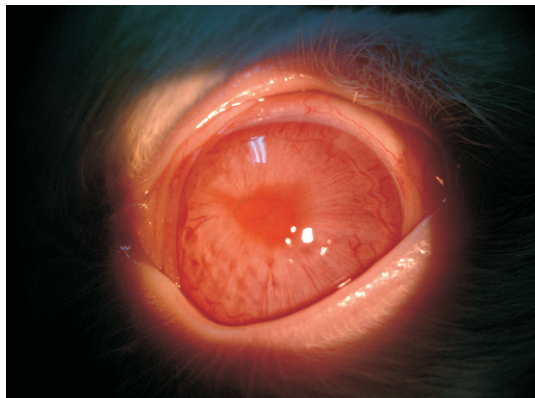
**Figure 1** Clinical observation at 3 days postoperatively in the non-modification group



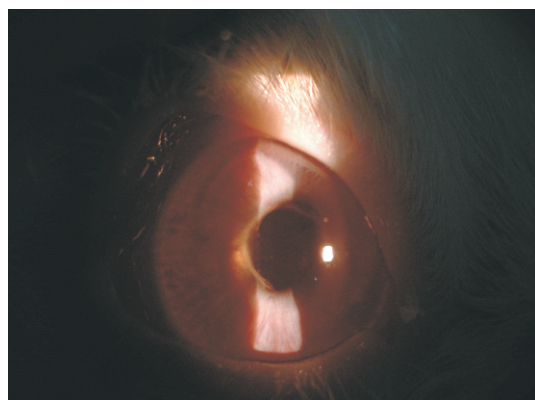
**Figure 2** Clinical observation at 3 days postoperatively in the modification group



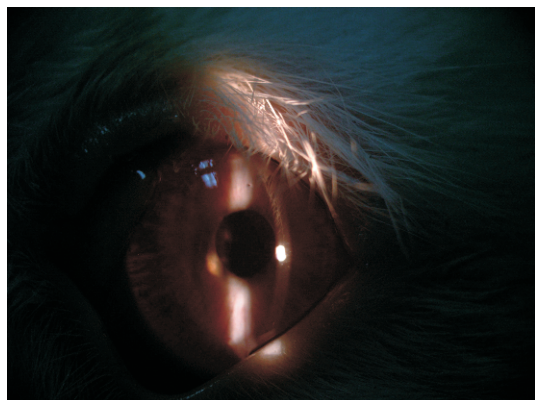
**Figure 3** Clinical observation at 7 days postoperatively in the non-modification group



**Figure 4** Clinical observation at 7 days postoperatively in the modification group



**Figure 5** Clinical observation at 15 days postoperatively in the non-modification group



**Figure 6** Clinical observation at 15 days postoperatively in the modification group

**Table 2** Comparison of anterior chamber exudation between two groups

Postoperative days	Non-modified					Modified					H	P
	-	+	++	+++	n	-	+	++	+++	n		
3d	0	3	4	2	9	0	3	6	0	9	0.33	>0.05
7d	1	4	3	1	9	5	3	1	0	9	4.39	<0.05
15d	4	3	1	0	8	6	2	0	0	8	1.21	>0.05
30d	6	1	0	0	7	7	0	0	0	7	1.00	>0.05
90d	6	0	0	0	6	6	0	0	0	6	0	>0.05

erative 90 days. No statistical significance was noted between two groups.

Intraoperatively, posterior capsule rupture and vitreous loss were observed in one eye. At 90 days post-surgery, IOL dislocation occurred in 5 eyes and occlusion of pupil in 3 eyes.

## Discussion

At present, no biological materials including IOLs can satisfy all demands in clinical setting or completely mimic the physiological functions of human organs. Two categories of studies related to IOL materials have been conducted. First, it focused on material modification and invention of new materials. Second, it centered on the techniques of surface modification to improve material biocompatibility<sup>3</sup>. The surface properties of IOL materials are the most vital factor affecting IOL biocompatibility<sup>4-6</sup>. Consequently, how to improve the surface properties of IOL becomes a main task in clinical practice.

Along with the integration of multiple disciplines, such as medicine, chemistry and bioengineering, the technique of surface modification has been steadily applied into the IOL studies, which aims to improve IOL properties and properly resolve the problem of biocompatibility without altering IOL shape, rigidity and optics property<sup>7</sup>. Hydrophobic IOL has strong surface adhesion, which can inhibit the proliferation of lens epithelium. After hydrophobic IOL implantation, the incidence of after-cataract is relatively low. Hydrophobic IOL shows good capsular biocompatibility. However, hydrophobic IOL is likely to adhere to cells and metabolites and affect uveal biocompatibility<sup>8,9</sup>. In this study, we modified hydrophobic acrylic IOL using surface modification technique to form permanent hydrophile layer and prevent adhesion to cells and bacteria, *etc.* Meantime, the opposite side of IOL surface remained hydrophobic. Vinyl pyrrolidone has been frequently used for membrane synthesis with no toxicity. It can effectively alter the surface properties, making it smooth to decrease cellular adhesion. After obtaining free radicals using harmless plasma method, chemical grafting of vinyl pyrrolidone was conducted for surface modification. No free radical initiators were utilized to ensure safety. In preliminary *in vitro* research, static contact

angle measurement, scanning electron microscope and UV spectrophotometer were utilized to validate whether the modified hydrophobic IOLs showed enhanced hydrophilicity<sup>10</sup>. The experiment revealed that rabbits implanted with surface modified IOL had significantly less severe anterior chamber exudation compared with those with non-modified IOL. In addition, the severity of corneal edema in the modification group was equally less serious than that in the non-modification group. Following IOL implantation, the anterior uveal may be irritated, probably leading to postoperative inflammatory response, anterior chamber exudation and blood-aqueous barrier destruction. The leaked protein might adhere to the IOL surface and form exudation membrane. The hydrophobic IOLs had hydrophilicity after treated by surface modification technique, which alleviated postoperative corneal reaction and anterior chamber exudation, and enhanced uveal biocompatibility. The untreated surface of the modified IOL remained hydrophobic and its severity of posterior capsular opacification did not differ from non-modified IOL. The hydrophobic property of the posterior surface was maintained and the capsular biocompatibility was also high. Due to the large size of rabbit eyeballs, IOL dislocation was seen in 5 eyes. No postoperative medication treatment was delivered for surgical eyes, therefore, occlusion of pupil was observed in 3 eyes.

The biocompatibility after IOL implantation mainly refers to uveal and lens capsular biocompatibility. How to balance them is one of the main goals of IOL implantation. This study was designed to both maintain the high biocompatibility of hydrophobic acrylic IOL and enhance uveal biocompatibility. The technique of single surface modification has been adopted in this experiment, whereas pathological and immune functional detection remain to be conducted.

To sum up, hydrophobic acrylic IOL processed with surface modification technique have improved

uveal biocompatibility. The IOL surface performance is closely correlated with the incidence of postoperative complications. Understanding the IOL materials and surface properties provides reference for IOL selection and experimental evidence for inventing a novel type of IOL.

## References

- 1 Abela-Formanek C, Amon M, Schild G, et al. Uveal and capsular biocompatibility of hydrophilic acrylic, hydrophobic acrylic, and silicone intraocular lenses. *J Cataract Refract Surg*, 2002, 28(1): 50–61.
- 2 Heatley CJ, Spalton DJ, Kumar A, et al. Comparison of posterior capsule opacification rates between hydrophilic and hydrophobic single-piece acrylic intraocular lenses. *J Cataract Refract Surg*, 2005, 31(4): 718–724.
- 3 Niu GG, Zhu SQ, Zheng YD, et al. Progress of Materials of Intracocular Lenses and their Surface Modification. *Chemistry*, 2008, 1: 10–16.
- 4 Werner L. Biocompatibility of intraocular lens materials. *Curr Opin Ophthalmol*, 2008, 19(1): 41–49.
- 5 Ladan E, Shameema S, Majid M. Softec HD hydrophilic acrylic intraocular lens: biocompatibility and precision. *Clin Ophthalmol*, 2011, 5: 65–70.
- 6 Yuen C, Williams R, Batterbury M, et al. Modification of the surface properties of a lens material to influence posterior capsular opacification. *Clin Experiment Ophthalmol*, 2006, 34(6): 568–574.
- 7 Zheng F, Weng JN. Study on Properties of Surface Modified Artificial Lenses. *Medical recapitulate*, 2007, 13(9): 710–712.
- 8 Wang GQ, Cao LQ, Gu HQ. Biocompatibility of artificial lens. *Chinese journal of dialysis and artificial organs*, 2006, 17(1): 8–11.
- 9 Roesel M, Heinz C, Heimes B, et al. Uveal and capsular biocompatibility of two foldable acrylic intraocular lenses in patients with endogenous uveitis—a prospective randomized study. *Graefes Arch Clin Exp Ophthalmol*, 2008, 246(11): 1609–1615.
- 10 Tang HQ, Wang GQ, Gu HQ. Study on the surface modification of hydrophobic polyacrylate intraocular lens. *Chinese J. Biomed. Eng (English Edition)*, 2013, 22(1): 29–36.