

## Case Report

# Utilization of Gene Mapping and Candidate Gene Mutation Screening for Diagnosing Clinically Equivocal Conditions: A Norrie Disease Case Study

Vasiliki Chini<sup>1</sup>, Danai Stambouli<sup>2</sup>, Florina Mihaela Nedelea<sup>2</sup>, George Alexandru Filipescu<sup>3</sup>, Diana Mina<sup>4</sup>, Marios Kambouris<sup>1,5</sup>, Hatem El-Shanti<sup>1,6,\*</sup>

1 Qatar Biomedical Research Institute(QBRI)-Medical Genetics Center, Doha, Qatar

2 Cytogenomic Medical Laboratory, Bucharest, Romania

3 Elias University Emergency Hospital, Bucharest, Romania

4 University of Iowa, Internal Medicine, Iowa City, IA, USA

5 Yale University School of Medicine, Genetics, New Haven CT, USA

6 University of Iowa, Pediatrics, Iowa City, IA, USA

## Abstract

Prenatal diagnosis was requested for an undiagnosed eye disease showing X-linked inheritance in a family. No medical records existed for the affected family members. Mapping of the X chromosome and candidate gene mutation screening identified a c.C267A[p.F89L] mutation in *NPD* previously described as possibly causing Norrie disease. The detection of the c.C267A[p.F89L] variant in another unrelated family confirms the pathogenic nature of the mutation for the Norrie disease phenotype. Gene mapping, haplotype analysis, and candidate gene screening have been previously utilized in research applications but were applied here in a diagnostic setting due to the scarcity of available clinical information. The clinical diagnosis and mutation identification were critical for providing proper genetic counseling and prenatal diagnosis for this family. (*Eye Science* 2014; 29: 104–107)

**Keywords:** gene mapping; mutation screening; norrie disease

## Introduction

The successful application of molecular genetic testing in a diagnostic setting depends on the availability of accurate clinical information including family history. However, in some instances, the clin-

ical information is scarce, making the application of appropriate diagnostic molecular testing either impossible or cost-prohibitive. Genetic disorders presenting as infantile onset blindness are numerous and usually demonstrate remarkable heterogeneity, especially when it comes to the choice of an appropriate molecular genetic test<sup>1,2</sup>.

We report the application of a gene mapping and haplotype analysis approach for the effective choice of a molecular genetic diagnostic test that was then applied for prenatal diagnosis in a family presenting with an inherited form of congenital blindness.

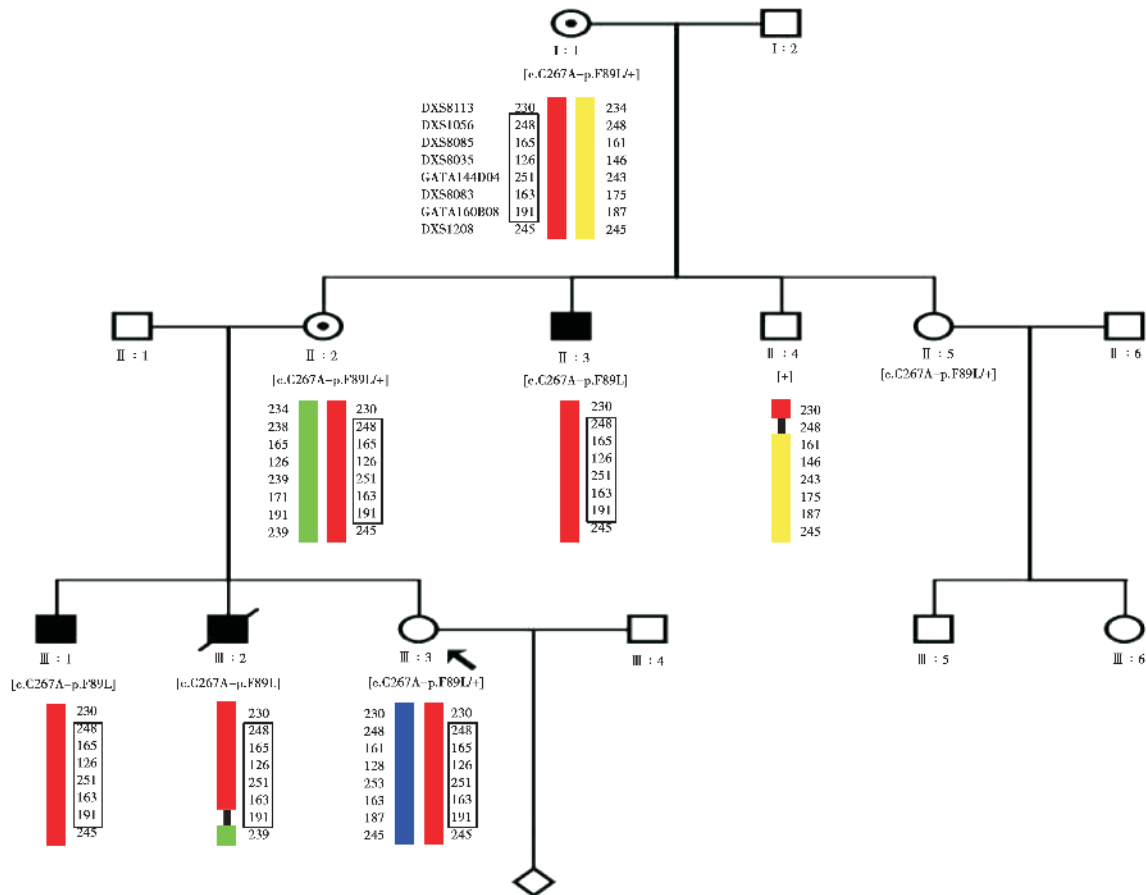
## Materials and methods

A pregnant female (Figure 1, III:3) presented at the CytoGenomics Laboratory in Bucharest, Romania requesting prenatal diagnosis for an eye disease causing blindness in her family. No medical records were available for any of the affected individuals and all efforts by the CytoGenomics Laboratory staff to contact various hospitals where affected individuals received care, including eye surgery, were fruitless. The obtained family history described a three-generation family of Romanian ethnic origin with only males affected, suggestive of an X-linked pattern of inheritance (Figure 1).

The older affected individual, II:3 (Figure 1), was born in 1967. The family reports him to be blind

DOI: 10.3969/j.issn.1000-4432.2014.02.009

\* **Corresponding author:** Hatem El-Shanti, QBRI-Medical Genetics Center, 69 Lusail Street, West Bay Area, P.O.Box: 33123, Doha, Qatar. E-mail: elshantih@smgc.org.qa



**Figure 1** Pedigree of the family harboring a Norrie disease mutation. Genotypes of eight microsatellite DNA markers within the critical interval (Xp11.23–11.4) are shown. The haplotype shared by the affected individuals and the carrier mothers is enclosed within the rectangle.

since birth, due to congenital bilateral optic nerve atrophy, bilateral microphthalmia, nystagmus, and leukocoria. He has had morbid obesity since early life. Individual III :1 (Figure 1) was born in 1985, with reportedly congenital blindness, bilateral congenital cataracts, bilateral optic nerve atrophy, and unilateral left microphthalmia. Individual III :2 (Figure 1) was born in 1989 with the severest clinical picture among all affected relatives. He was reportedly born blind, with retinal detachment of the left eye, which was removed surgically at nine months of age due to an apparent retinoblastoma. He had moderate mental and motor retardation, recurrent seizures that started at the age of seven years, hyperkinesia, and aggressive behavior. He died at the age of 21 years after an epileptic seizure with status epilepticus. During the last two years of his life, he

was weak, underweight, and showed generalized atrophy of his muscles and contractures of the joints of his upper and lower limbs.

The present study was conducted in accordance with the provisions of the Declaration of Helsinki and was approved by the Shafallah Medical Genetics Center Institutional Review Board.

**Results**

Comparative haplotype analyses identified a 10 Mb critical region on the short arm of the X chromosome [Xp11.23–11.4], defined by markers DXS1056 and GATA160B08 and shared by all affected males and obligate carrier females, but not by the unaffected male (Figure 1). A total of 81 protein-coding genes are contained within the critical region. Only two genes with known ocular associations were pre-

sent, *BCOR*, the *BCL6* co-repressor gene responsible for Oculofaciocardiodental (OFCD) and Lenz microphthalmia<sup>3</sup>, and *NDP*, responsible for the Norrie disease<sup>4,6</sup>.

Resequencing analysis of the *BCOR* did not show any variations. In contrast, resequencing *NDP* showed the presence of a C to A substitution at nucleotide 267 in the third exon, c.267C>A, leading to a Phenylalanine to Leucine substitution at amino acid 89 [p.F89L]. The three affected males are hemizygous for the mutation and the two carrier females are heterozygous, while the unaffected male is hemizygous for the wild-type allele. The woman seeking consultation is a carrier of the mutation. The variant has been reported as a novel variation “likely to cause Norrie Disease”<sup>7</sup>.

## Discussion

The clinical presentation and the scarce medical record information did not hint or give the impression of Norrie disease as a firm diagnosis. Affected males had undergone multiple surgeries, making the disease unrecognizable at the clinical level at the time of current evaluation. The only constant feature among all three affected family members was microphthalmia, so genes within the linkage interval were queried for association with microphthalmia. The reported “retinoblastoma” is not among the clinical symptoms of Norrie disease, complicating the issue even further, but was probably a pseudoglioma, a known sign of Norrie disease that can mimic retinoblastoma.

Norrie disease [OMIM# 310600] is a rare X-linked recessive genetic disorder characterized by congenital blindness, mental retardation, and in about one third of patients sensorineural hearing loss<sup>6</sup>. Norrie disease usually presents at birth, has a progressive course, and shows remarkable variable expression including retinopathy, psychotic features, and seizures<sup>6,8</sup>. Eye manifestations include microphthalmia and pseudoglioma, a condition that occurs at birth or soon thereafter, caused by the accumulation of fibrovascular masses behind the lens due to a maldeveloped retina<sup>5</sup>. In the first decade of life, the intraocular pressure can be lost progressively and/or the globe can shrink (phthisis bulbi).

Norrie disease is caused by mutations in *NDP*, which encodes Norrin. Most mutations in *NDP* result in Norrie disease, while some mutations cause X-linked Familial Exudative Vitreoretinopathy [FEVR; OMIM# 133780]<sup>7</sup>. Norrin is a 133 amino acid protein, expressed in the retina, choroid, and fetal brain<sup>6</sup> and is a member of the cystine knot growth factor family<sup>9</sup> that activates the Wnt/beta-catenin pathway. This signaling pathway plays an important role in eye organogenesis and angiogenesis<sup>7</sup>. Norrin is a cysteine-rich secreted protein that consists of two parts: a signal peptide at the amino terminus, which plays a role in the localization of the protein, and six cysteine regions (at positions 39, 65, 69, 96, 126 and 128), which form a cysteine knot required for binding to the receptor and subsequent signal transduction<sup>10</sup>.

The presence and the conservation of the cysteines in the peptide chain, as well as the cysteine knot motif, which is critical for the action of the protein, indicate the important role of cysteines in the protein structure and function. A study of 109 children with various vitreoretinopathies for mutations in *NDP* confirms the important role of the cysteine rich region, as mutations disturbing the cysteine-knot motif were apparent in cases with more severe retinopathies<sup>11</sup>. The mutation described in the present family is related to the cysteine-knot domain, since it affects a Phenylalanine at position 89 that interacts with the Cysteine at position 96 and participates in the knot motif.

The c.267C>A [p.F89L] mutation was previously described in a single family of Dutch origin as “likely to cause Norrie disease”<sup>7</sup>. This missense mutation is located in the highly-conserved cysteine-knot domain 7 and this amino acid position is considered as one of those participating in Norrin dimerization<sup>10</sup>.

Gene mapping and haplotype analyses, followed by candidate gene mutation screening, were previously utilized exclusively in research applications. In the present instance, these tools were applied in a diagnostic setting and were essential in deciphering the offending molecular defect. The lack of proper medical records, as well as a poor and misleading clinical history, precluded a correct diagnosis of Norrie disease in this family. The only available in-

formation came from the three-generation pedigree, which emphasizes the critical importance of obtaining a family history. The family history may indicate the mode of inheritance for a condition, offer guidance for genetic testing, and also help in genetic counseling by identifying at-risk relatives and calculating the risks of other members of the family<sup>12</sup>. However, clinical diagnosis and mutation identification are essential prerequisites for providing proper genetic counseling and prenatal diagnosis for this family. This diagnosis would not have been achieved except for the application of gene mapping and haplotype analysis.

### Acknowledgments

The research study was funded by the Shafallah Medical Genetics Center, a non-profit governmental institution.

### References

- 1 Stone EM. Genetic testing for inherited eye disease. *Arch Ophthalmol*, 2007, 125: 205–212.
- 2 Drack AV, Lambert SR, Stone EM. From the laboratory to the clinic: molecular genetic testing in pediatric ophthalmology. *Am J Ophthalmol*, 2010, 149: 10–17.
- 3 Ng D, Thakker N, Corcoran CM, et al. Oculofaciocardiodental and Lenz microphthalmia syndromes result from distinct classes of mutations in BCOR. *Nat Genet*, 2004, 36: 411–416.
- 4 Meindl A, Berger W, Meitinger T, et al. Norrie disease is caused by mutations in an extracellular protein resembling C-terminal globular domain of mucins. *Nat Genet*, 1992, 2: 139–143.
- 5 Berger W, Meindl A, van de Pol TJ, et al. Isolation of a candidate gene for Norrie disease by positional cloning. *Nat Genet*, 1992, 1: 199–203.
- 6 Berger W, van de Pol D, Warburg M, et al. Mutations in the candidate gene for Norrie disease. *Hum Mol Genet*, 1992, 1: 461–465.
- 7 Nikopoulos K, Venselaar H, Collin RWJ, et al. Overview of the mutation spectrum in familial exudative vitreoretinopathy and Norrie disease with identification of 21 novel variants in FZD4, LRP5, and NDP. *Hum Mutat*, 2010, 31: 656–666.
- 8 Allen RC, Russell SR, Streb LM, et al. Phenotypic heterogeneity associated with a novel mutation (Gly112Glu) in the Norrie disease protein. *Eye*, 2006, 20: 234–241.
- 9 Riveiro-Alvarez R, Trujillo-Tiebas MJ, Gimenez-Pardo A, et al. Genotype-phenotype variations in five Spanish families with Norrie disease or X-linked FEVR. *Mol Vis*, 2005, 11: 705–712.
- 10 Meitinger T, Meindl A, Bork P, et al. Molecular modelling of the Norrie disease protein predicts a cystine knot growth factor tertiary structure. *Nat Genet*, 1993, 5: 376–380.
- 11 Wu WC, Drener K, Trese M, et al. Retinal phenotype – genotype correlation of pediatric patients expressing mutations in the Norrie disease gene. *Arch Ophthalmol*, 2007, 125: 225–230.
- 12 Stroh E. Taking the family history in genetic disease: a guide for ophthalmologists. *Curr Op Ophthalmol*, 2011, 22: 340–346.