

Comparison of Postoperative Pain Following Laser-assisted Subepithelial Keratectomy and Transepithelial Photorefractive Keratectomy: a Prospective, Random Paired Bilateral Eye Study

Dongmei Wang*, Guangsheng Chen, Liusong Tang, Qiaoling Li

Liuzhou Red Cross Hospital, Eye Hospital of Liuzhou City, Liuzhou 545000, China

Abstract

Purpose: To compare postoperative pain following laser-assisted subepithelial keratectomy (LASEK) and transepithelial photorefractive keratectomy (T-PRK, two-step surgery) and alleviate postoperative subjective pain.

Methods: Thirty patients (60 eyes) with myopia or myopic astigmatism were consecutively recruited into this prospective, randomized paired study. Patients underwent LASEK in one eye, and T-PRK in the other. The degree of pain was rated on a scale of 0–10 on postoperative days 1, 2 and 3. Uncorrected visual acuity (UCVA) and subepithelial corneal haze were assessed at postoperative 1 and 3 months.

Results: The pain was relieved on the 4th postoperative day in all patients, healing of corneal epithelium was observed at 4–5 days after surgery and contact lenses were removed promptly. At postoperative 1 day, the mean subjective pain score in the LASEK group was 3.2 ± 1.88 and 4.43 ± 1.61 in T-PRK group ($P=0.008$). No significant difference was found between two groups on postoperative 2 and 3 days. At postoperative 3 months, the percentage of UCVA ≥ 0.8 in the LASEK group was 100% and 96.7% in the T-PRK group ($P=0.24$), 93.3% of patients in the LASEK with UCVA ≥ 1.0 and 90% in the T-PRK group ($P=0.64$). In the LASEK group, the value of corneal haze was 0.26 ± 0.21 and 0.27 ± 0.25 in the T-PRK group ($P=0.877$).

Conclusion: Good visual acuity was obtained in both groups at postoperative 3 months. Compared with those in the T-PRK

group, patients undergoing had less discomfort in the LASEK group, which may be associated with corneal epithelial activity. The changing curve of subjective pain in the T-PRK group was relatively flat and stable at postoperative 3 days. (*Eye Science* 2014; 29:155–159)

Keywords: postoperative pain; laser-assisted subepithelial keratectomy; transepithelial photorefractive keratectomy

Introduction

Corneal surface ablation averts the incidence of corneal flap complications and saves corneal thickness. It can be applied to the patients with thin cornea, curvature abnormality and ocular socket, who are unable to undergo LASIK, those with corneal flap complications and intense occupation¹. However, it may also cause topical discomforts and slow recovery of visual acuity. Consequently, the development of corneal surface ablation depends upon the processing of corneal epithelia to decrease corneal injuries and irritation.

During LASEK, diluted ethanol is utilized to separate corneal epithelia from anterior Bowman's membrane to create corneal epithelial flap. The corneal flap is reattached after laser ablation. LASEK has been widely applied during 1990s. Clinch TE et al² introduced the application of phototherapeutic keratectomy (PTK) and then performed PRK, demonstrating this combined method was safe and efficacious^{3–5}. Recently, along with the widespread application of surface ablation, T-PRK (one- and two-step surgery) is gradually captivating much attention

DOI: 10.3969/j.issn.1000-4432.2014.03.006

Funding: Self-financing Fund for Scientific Research Projects of Guangxi Zhuang Autonomous Region (No.Z2012547)

* **Corresponding author:** Dongmei Wang, E-mail: wdm_gx@163.com

from ophthalmologists.

This prospective paired study aims to statistically compare changes in postoperative pain between LASEK and T-PRK (two-step surgery).

Materials and methods

Study subjects

In this prospective comparative study, a total of 30 patients (60 eyes) undergoing excimer laser refractive surgery were consecutively enrolled, 14 males and 16 females, aged (23 ± 4.59) years on average (18–33 years). All participants were labelled in number. Those with odd number received LASEK in their right eyes and T-PRK in the other eye. Patients with even number underwent T-PRK in their right eyes and LASEK in the left.

All patients were followed up on postoperative 1, 2 and 3 days. Wong-Banker Faces Pain Scale (FPS)⁶ was adopted to score postoperative pain intensity on the widely accepted 0-to-10 metric including 11 facial expressions to describe the pain intensity. Each patient selected one facial expression to illustrate the sensation of pain. The results were recorded with signature.

Corneal haze was evaluated based on Fantes classification criteria; complete corneal transparency under slit-lamp examination was regarded as 0; mild punctate opacity under slit-lamp microscope as 0.5; corneal opacity under slit-lamp microscope as 1; opacity of the cornea slightly influenced iris texture as 2; obvious corneal opacity affected observation of iris texture to moderate extent as 3; unable to observe iris texture due to severe corneal opacity as 4.

Inclusion criteria: aged ≥ 18 years, stable refraction for 1 year, bilateral spherical equivalent difference $< 1D$, normal corneal topography, not wearing soft contact lens within 2 weeks before the surgery and 3 weeks for those wearing hard contact lens until refraction was stable.

Exclusion criteria: those with unstable refraction, strabismus, corneal diseases, glaucoma, keratoconus or collagenous diseases.

This research was approved by the Ethic Committee of our hospital. Informed consents were signed by all patients. This study has been registered at Chinese Clinical Trial Registry (ChiCTR-TRC-

12002849).

Surgical approach

The surgery was conducted on bilateral eyes simultaneously. Conventional disinfection was performed, and topical anesthesia was conducted by administration of 0.5% alcaïn eye drops twice, every 5 min.

T-PRK group: The corneal epithelia were removed according to PTK procedures. Based upon preoperative corneal thickness and diameter, the width of corneal epithelia removal was 8 mm and the depth was approximately 50–55 μm . The procedure was controlled by monitoring the absence of blue fluorescence and then refraction ablation was performed.

LASEK group: The cover was soaked in the 20% ethyl alcohol for 20–25 s. The eyes were fully irrigated by balanced salt solution. The corneal epithelia were gently separated along with the ring-shaped trace and the pedicle was retained at 12 o'clock position. The corneal epithelia were reattached after refraction ablation. Corneal contact lenses were replaced postoperatively (Bausch Lomb).

All patients underwent myopia or myopic astigmatism correction using SCHWIND Esiris laser system. All surgeries were successfully performed by the same physician and assistants.

Postoperative processing

Levofloxacin, tobramycin dexamethasone and diclofenac sodium eye drops were administered after the surgery. At postoperative 3 d, diclofenac sodium was given 4 times/day. From postoperative 2 d, tobramycin dexamethasone was administered 4 times/day and replaced by 0.1% fluorometholone 3 times/day. The dose of fluorometholone was adjusted according to corneal haze and intraocular pressure. Artificial tears were given postoperatively. Corneal contact lenses were removed at postoperative 4–7 d according to corneal healing and follow-up time. The return visit was performed at 1 week, 1 and 3 months. UCVA was measured and recorded and the subepithelial corneal haze was observed under slit-lamp examination.

Statistical analysis

Preoperative visual acuity (logMAR), diopter, corneal thickness, corrected visual acuity, optical zone were analyzed by paired t-test. The pain inten-

Table 1 Comparison of multiple preoperative parameters between two groups (60 eyes)

	LASEK	T-PRK	t	P
Spherical equivalent refraction (D)	-6.27±2.30	-6.32±2.21	0.086	0.932
Corneal thickness (µm)	524.5±24.86	525.03±24.24	0.082	0.935
Optical zone (mm)	6.37±0.21	6.36±0.20	0.183	0.856
Preoperative visual acuity (logMAR)	1.08±0.26	1.09±0.26	0.255	0.801
Preoperative corrected visual acuity (logMAR)	0.23±0.05	-0.02±0.04	-0.151	0.881
Planned ablation depth (µm)	96.97±27.37	97.3±26.72	0.047	0.963

sity at postoperative 3 d was subject to variance analysis. The percentage of postoperative visual acuity at different time points was analyzed by chi-square test. $P < 0.05$ was considered as statistical significance.

Results

Comparison of preoperative general data between two groups

No statistical difference was observed in visual acuity, diopter, corneal thickness and corrected visual acuity between LASEK and T-PRK groups, as shown in Table 1.

Comparison and changing tendency of pain intensity at postoperative 3 d between two groups

All patients' pain was gradually mitigated at postoperative 4 d. corneal epithelial injury was healed at postoperative 4-5 d and the contact lenses were removed timely. At postoperative 1 d, subjective pain score in the LASEK group was lower compared with that in the T-PRK group, and slightly increased at postoperative 2-3 d, whereas it did not differ from that in the T-PRK group, as shown in Table 2 and Figure 1.

Table 2 Comparison of pain intensity at postoperative 3 d between two groups (60 eyes, $\bar{x} \pm s$)

	LASEK	T-PRK	F	P
Postoperative 1 d	3.2±1.883	4.43±1.612	7.428	0.008
Postoperative 2 d	4.87±2.46	4.2±2.325	1.164	0.285
Postoperative 3 d	5.27±2.638	4.4±2.343	1.810	0.184

Corneal haze between two groups

In the LASEK group, corneal haze was (0.26±0.21) at postoperative 3 months and (0.27±0.25) in the T-PRK group. No statistical significance was found between two groups ($t=0.155$, $P=0.877$).

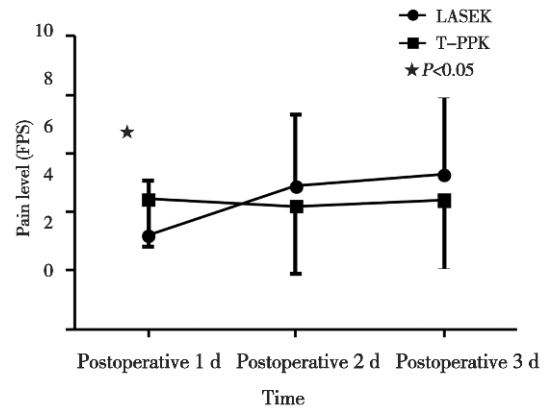


Figure 1 Changes in the curve of pain intensity at postoperative 3 d between two groups

Table 3 Comparison of visual acuity at postoperative 1 and 3 months between two groups (60 eyes)

Time	Visual acuity	LASEK (%)	T-PRK (%)	χ^2	P
Postoperative 1 month	≥ 0.8	86.7	80	0.480	0.49
	≥ 1.0	76.7	73.3	0.089	0.766
Postoperative 3 months	≥ 0.8	100	96.7	1.403	0.236
	≥ 1.0	93.3	90	0.220	0.639

Discussion

Postoperative pain is a challenging problem after corneal surface ablation. LASEK has been proven to cause less pain and corneal haze and accelerate the healing of corneal epithelia compared with PRK⁷. In this research, postoperative discomforts of LASEK was significantly less than that of T-PRK, probably because active corneal epithelial flap of LASEK could prevent the incidence of healing reactions induced by inflammatory mediators and cells in the tear fluid. However, active corneal epithelia may be absent in LASEK possibly due to the followings factors: 1. Concentration and time of ethanol The diluted ethanol (usually 20%) should be used and contact with the cornea for 20-30 s. Otherwise⁹, corneal

epithelia will be inactive and pain intensity will be relatively aggravated. Zhou et al¹⁰. reduced the infiltration time of ethanol to 10 s and the painless rate achieved up to 91.32% (285 eyes). 2. Construction of corneal epithelial flap Kornilovsky et al¹¹. analyzed the difficulty of constructing corneal epithelial flap in 12 patients with high myopia and found that easy operation was observed in 41.7% of cases, moderate difficulty in 33.3% and relatively difficult in 25% with a painless rate of 50% , indicating that construction of corneal epithelial flap was associated with individual difference, surgeons' experience and corneal epithelial flap activity. Zhou et al. suggested that laser epithelial keratomileusis and water reduction could maintain the activity of corneal epithelia. Consequently, ethanol contact time and surgeons' expertise, excluding objective factors (individual difference), play a pivotal role in reducing postoperative stimulatory symptoms.

Some physicians suggested use of diluted ethanol or alternative methods of removing corneal epithelia during PRK^{3,12} and obtained relatively good visual acuity. However, we considered that surface ablation could yield short-term epithelial protection, which acted as an important factor alleviating postoperative pain intensity.

In this study, patients had no severe pain starting from postoperative 4 d, probably correlated with the corneal epithelial healing on postoperative 3 d. Although pain intensity did not significantly differ at postoperative 2–3 d between two groups, it had an increasing tendency in the LASEK group, whereas flat and stable pain intensity in the T-PRK group. At postoperative 2–3 d, the new corneal epithelial cells covered the surface of old ones and aroused evident sensation of foreign body. In the T-PRK group, laser ablation yielded even and smooth surface and no corneal epithelial coverage. The changing tendency of postoperative pain was relatively steady. Further cytological studies are urgently needed for subsequent observation.

In this study, 3-month follow up demonstrated that no significant difference was observed in corneal haze between two groups. At postoperative 1 and 3 months, the incidence of visual acuity of 0.8 and 1.0 in the LASEK group was slightly higher compared

with that in the T-PRK group, suggesting that patients in the LASEK group restored visual acuity slightly faster than those in the T-PRK group with no statistical significance.

Taken together, desirable visual acuity was obtained in both groups at postoperative 3 months. Compared with their counterparts in the T-PRK group, patients undergoing had less discomforts in the LASEK group, which may be associated with corneal epithelial activity. The changing curve of subjective pain in the postoperative T-PRK group was relatively flat and stable at postoperative 3 days.

References

- 1 Dastjerdi MH, Soong HK. LASEK (laser subepithelial keratomileusis). *Current Opinion in Ophthalmology*, 2002, 13(4):261–263.
- 2 Clinch TE, Moshirfar M, Weis JR, et al. Comparison of mechanical and transepithelial debridement during photorefractive keratectomy. *Ophthalmology*, 1999, 106(3): 483–489.
- 3 Fadlallah A, Fahed D, Khalil K, et al. Transepithelial photorefractive keratectomy: clinical results. *Journal of Cataract and Refractive Surgery*, 2011, 37(10):1852–1857.
- 4 Wang DM, Du Y, Chen GS, et al. Transepithelial photorefractive keratectomy mode using SCHWIND-ESIRIS excimer laser: initial clinical results. *International Journal of Ophthalmology*, 2012, 5(3):334–337.
- 5 Camellin M, Arba Mosquera S. Simultaneous aspheric wavefront-guided transepithelial photorefractive keratectomy and phototherapeutic keratectomy to correct aberrations and refractive errors after corneal surgery. *Journal of Cataract and Refractive Surgery*, 2010, 36(7):1173–1180.
- 6 Kim EJ, Buschmann MT. Reliability and validity of the Faces Pain Scale with older adults. *International Journal of Nursing Studies*, 2006, 43(4):447–456.
- 7 Saleh TA, Almasri MA. A comparative study of post-operative pain in laser epithelial keratomileusis versus photorefractive keratectomy. The surgeon. *Journal of the Royal Colleges of Surgeons of Edinburgh and Ireland*, 2003, 1(4):229–232.
- 8 Chen CC, Chang JH, Lee JB, et al. Human corneal epithelial cell viability and morphology after dilute alcohol exposure. *Investigative Ophthalmology & Visual Science*, 2002, 43(8):2593–2602.
- 9 Dreiss AK, Winkler von Mohrenfels C, Gabler B, et al. Laser epithelial keratomileusis (LASEK): histological investigation for vitality of corneal epithelial cells after alcohol exposure. *Klinische Monatsblätter für Augen-*

- heilkunde, 2002, 219(5):365–369, discussion 9.
- 10 Zhou XT, Chu RY, Wang XY, et al. The clinical study of the epithelial flap of painless LASEK and Epi-LASIK. *Zhonghua Yanke Zazhi* (Chinese Journal of Ophthalmology), 2005, 41(11): 977–980.
 - 11 Kornilovsky IM. Clinical results after subepithelial photorefractive keratectomy (LASEK). *Journal of Refractive Surgery*, 2001, 17(2 Suppl):S222–223.
 - 12 Aslanides IM, Padroni S, Arba Mosquera S, et al. Comparison of single-step reverse transepithelial all-surface laser ablation (ASLA) to alcohol-assisted photorefractive keratectomy. *Clinical Ophthalmology*, 2012, 6:973–980.