

Favorable Outcome in Open Globe Injuries with Low OTS Score

Cillino Giovanni¹, Ferraro Lucia¹, Casuccio Alessandra², Cillino Salvatore^{1,*}

1 Department of Experimental Biomedicine and Clinical Neuroscience, Ophthalmology Section, University of Palermo (Italy), via Liborio Giuffrè, 13, 90127-Palermo, Italy

2 Department of Sciences for Health Promotion and Mother-Child Care, University of Palermo (Italy), via del Vespro, 133, 90127-Palermo, Italy

Abstract

Purpose: Open globe eye injuries can have profound social and economic consequences. Here, we describe two cases of war and outdoor activity open globe eye injury where, despite a low OTS score, current microsurgical technology allowed for a favorable outcome.

Case report 1: A 33-year-old Libyan soldier had been treated for an open-globe grenade blast trauma to his left eye, which showed light perception and OTS score 2. He had undergone a lensectomy and PPV with silicone oil tamponade. Surgical treatment included scleral buckling, cornea trephination, temporary Eckardt keratoprosthesis, PPV revision, intraocular lens (IOL) implantation, and corneal grafting. Six months later, his VA was improved to 20/70.

Case report 2: A 35-year-old man presented with a corneal laceration in his left eye from a meat skewer, with marked hypotony and LP. After primary corneal wound closure, B-scan ultrasonography revealed massive vitreous hemorrhage (OTS score 2). The patient underwent open cataract extraction with IOL implantation, 23 gauge PPV, laser photocoagulation of the retinohoroidal laceration, and a gas tamponade. After three weeks, the patient underwent a 2nd 23G PPV due to a fibrinous reaction. Six month later, the patients exhibited 20/25 VA.

Conclusion: These cases confirm that even for patients with a low OTS and poor visual prognosis, an up-to-date surgery protocol may achieve visual results adequate for leading an autonomous daily life. (*Eye Science 2014; 29:170–173*)

Keywords: ocular trauma; open globe injury; penetrating keratoplasty; ocular trauma score; perforating trauma

Introduction

War ocular injuries represent a high risk of permanent and significant visual impairment, despite considerable progress achieved in their treatment. Technological progress, with the introduction of high-velocity projectiles as well as explosive devices, has changed the nature of contemporary armed warfare and has increased the number of eye injuries, mostly among combat soldiers. This is often associated with the preferential exposure of the face in modern warfare and the exceptional vulnerability of the eye to small particles that would have minimal effect on other parts of the body¹⁻².

Open globe eye injuries can have profound social and economic consequences, since patients often become unfit for many occupations, even when they do not evolve to complete blindness. This is especially true for those injuries with a low Ocular Trauma Score (OTS) and a poor visual prognosis³.

The OTS index allows prediction of the visual outcome in ocular trauma according to the initial visual acuity, type of injury, and associated findings. Certain numerical values rendered for the OTS variables (visual acuity, rupture, endophthalmitis, perforating injury, retinal detachment, and afferent pupillary defect) at presentation are summed and converted into OTS categories. The likelihood of the final visual acuities (NLP, LP/HM, 1/200 to 19/200, 20/200 to 20/50, and \geq 20/40) in the OTS categories (1

DOI: 10.3969/j.issn.1000-4432.2014.03.009

* **Corresponding author:** Prof. Salvatore Cillino, Department of Experimental Biomedicine and Clinical Neuroscience, Ophthalmology Section, University of Palermo (Italy), via Liborio Giuffrè, 13, 90127-Palermo, Italy. Phone +39916553929. Fax: +39 91 6261438. E-mail: salvatore.cillino@unipa.it

through 5) in the patients are then calculated and compared with those in the OTS study group.

In the present study, we describe two cases of war and outdoor activity open globe eye injury where, despite a low OTS score, current microsurgical technology allowed for favorable outcomes.

Case report 1

A 33-year-old Libyan soldier came to our observation on July 2013, under the auspices of a humanitarian program sponsored by the Italian Foreign Minister, in which our University Hospital participated. Three months previously, he had undergone a bilateral eye injury due to a grenade blast. He was transferred to the Eye Clinic of Alexandria in Egypt and presented with right eye phthisis with no light perception and an open-globe penetrating trauma with intraocular foreign body and vitreous hemorrhage in his left eye; his visual acuity (VA) was light perception with RAPD and the raw score sum was 46 (OTS score 2). An early primary closure was performed and 7 days later, he underwent removal of intraocular foreign body, lensectomy, and pars plana vitrectomy (PPV) with a silicone oil tamponade. Slit-lamp examination of the left eye revealed many corneal scars with a subtotal opacity, traumatic irregular mydriasis with multiple anterior synechiae, a six o'clock basal iridectomy, and aphakia (Figure 1). The intraocular pressure (IOP) was 10 mm Hg. The fundus could not be seen due to corneal scarring, yet a red reflex was present; VA was 2/200. Biometry showed an axial length of 31.9 mm; this length was emphasized by the amount of silicone oil filling the vitreous chamber. B-scan ultrasonography showed widespread low-intensity echoes in the vitreous chamber like those seen with blood clots. A CT scan localized a millimeter-sized intraocular metallic foreign body in the same eye and confirmed the presence of blood clots in the vitreous chamber. The pre-operative clinical data seemed to indicate that a high percentage of the low visual acuity was due to corneal clouding and crystalline absence; therefore, we decided to stabilize the retina and to restore the anterior segment optical properties. To reach this goal, after obtaining informed consent from the patient, we performed a scleral buckling utilizing a sil-

icone encircling band. During this procedure, a foreign body that had been embedded in the superior rectus muscle was identified and removed. A flieringa ring was sutured to the sclera and four iris hooks were used to enlarge the pupil, after anterior synechiolysis. A 7.5 mm cornea trephination was then performed and a temporary Eckardt keratoprosthesis was sutured in place. A revision of PPV, foreign body extraction, silicone oil removal, liquid perfluoro carbon (PFCL) injection, endolaser for peripheral 360 degrees, and gas tamponade (Sulfur hexafluoride-Air 50%) were then performed. Finally, the temporary Eckardt keratoprosthesis was removed, an intraocular lens (IOL) was placed in the ciliary sulcus, and a 7.75 mm corneal graft was sutured with a double no torque running suture. Ten days after surgery, VA was 40/200. The corneal graft was clear with some folds of the Descemet membrane, a moderate anterior chamber reaction and irregular mydriasis were detected, and the IOL was correctly located in the posterior chamber (Figure 2). IOP was 10 mmHg. The retina was entirely attached. Six months later, the corneal graft remained clear and the VA was improved to 20/70. The patient is again able to write and read, to use a computer and cellular phone, and to take care of all his personal needs on his own.

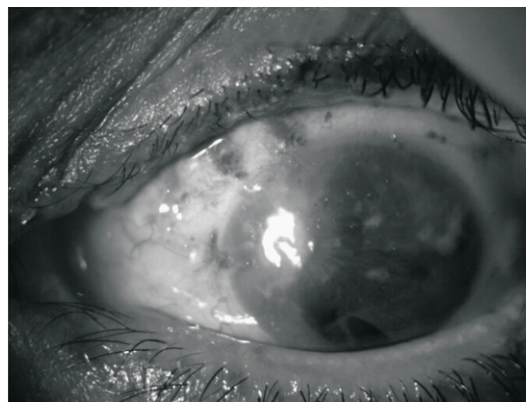


Figure 1 Case 1. Slit lamp picture of grenade blast trauma at presentation

Case report 2

A 35-year-old man came to our emergency room in November 2012. He had injured his left eye with a small metal meat skewer while eating dinner. Slit lamp examination showed a limbal superior nasal,

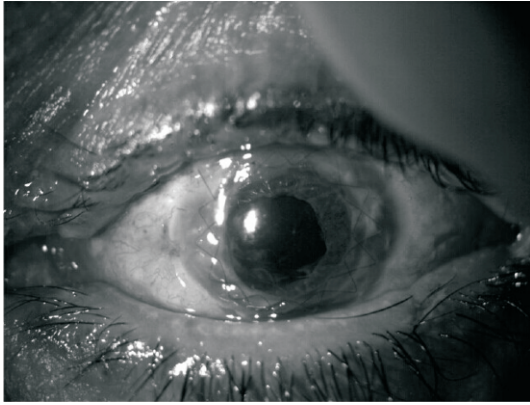


Figure 2 Case 1. Grenade blast trauma 10 days after surgery

partially stellate corneal laceration with iris prolapse, negative Seidel test probably due to stromal swelling and iris incarceration, wide hyphema, and swelling cataract. A marked hypotony with light perception VA were present. After obtaining informed consent, the patient underwent mechanical iris reposition and primary corneal wound closure. The following day, a B-scan ultrasonography indicated massive vitreous hemorrhage without retinal detachment. A CT scan excluded intraocular FB and confirmed the vitreous hemorrhage (raw score 56; OTS score 2). The absence of retinal detachment prompted us to apply all the procedures necessary to reconstruct the anterior and posterior segment, with a better probability for a good prognosis. The patient underwent 23 gauge PPV, preceded by automated AC blood clot aspiration via limbal temporal access, with a finding of a sector iris sphincter rupture, a disrupted anterior capsule of the lens with swelling, and cortical material in the anterior chamber. After enlargement of the capsulotomy and linear aspiration of the cataractous material, a wide posterior superior capsule rupture was found and a 3-piece IOL was implanted in the sulcus. During the 23G vitrectomy, a profusely bleeding retinochoroidal laceration in the superior temporal quadrant with bare sclera was found, clearly due to the tip of the skewer. This was treated by endolaser surrounding the laceration, after a bleeding tamponade with PFCL, followed by PFCL-gas exchange (Sulfur hexafluoride-Air 50%). A bandage soft contact lens was applied. After three weeks, the patient underwent a second 23G PPV due to a fibrinous anterior chamber reaction and pupillary

membrane with persistent blood-filled vitreous cavity. A Balanced Salt Solution (BSS) with vancomycin was used to clear the anterior chamber and to perform posterior capsulectomy and accurate removal of the vitreous base with hemorrhagic-exudative remnants. A huge clot masking the retinal lesion and the posterior pole was carefully removed with a vitrectomy probe and forceps, endolaser under PFCL was again applied, and PFCL-hexafluoroethane(20% C2F6) exchange was carried out. As of June 2013, the patient exhibits a 20/25 VA, with a scarred retinochoroidal extramacular lesion well surrounded by laser scars (Figure 3 and Figure 4).

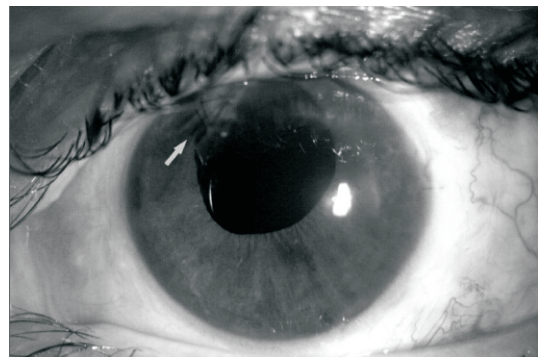


Figure 3 Case 2. Metal meat skewer trauma 6 months after surgeries; slit lamp picture. The arrow indicates the site of primary closure

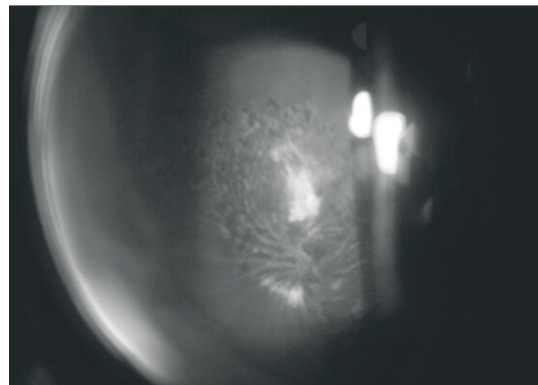


Figure 4 Case 2. Metal meat skewer trauma 6 months after surgeries; a scarred retinochoroidal extramacular lesion well surrounded by laser scars

Discussion

The use of an Eckardt temporary keratoprosthesis in the first case, which showed corneal opacification

and posterior segment pathology, provides a good view of the peripheral retina and pars plana. In our patient, the maintenance of a closed pressure system allowed us to perform posterior segment surgery and penetrating keratoplasty in a single operation, without major intraoperative complications⁴. Many authors have agreed that better results are attained in these complicated ocular injury cases when silicone oil removal precedes keratoplasty or when the latter is performed at the time of silicone oil removal¹. In fact, corneal transplant failure often occurs due to ciliary body malfunction with ocular hypotony and silicone oil-endothelial contact^{5,6}. Moreover, performing keratoplasty soon after a severe ocular trauma runs a higher risk of rejection due to alteration of the hemato-ophthalmic barrier.

We may then conclude that a combined procedure of keratoprosthesis, PPV, and penetrating keratoplasty is a safe and efficacious way of managing complicated posterior segment disease, even in the presence of corneal opacities. In the second case, the I-OL implantation during the first 23G PPV could be questionable, even if it did not significantly interfere with the following procedures, but it could have been responsible for the late uveal reaction. The noticeable auspiciousness of the patient, despite the severity of the trauma, was clearly helped by the delicacy and accuracy of the minimally invasive 23G technique.

An OTS score of 2 should allow an estimated probability of 13% for VA between 20/200 and 20/50 and of 15% for VA \geq 20/40³. In a previous retrospective study⁷, we found that the likelihood of a good final VA with a low OTS score exhibits a tendency towards higher values with respect to the OTS Study Group⁸. This could reflect the continuous evolution of techniques and instruments. Current microsurgical procedures that use high-speed, delicate, microinvasive vitrectors and devices, high quality prostheses, viscoelastics and implants, and well balanced air-gas mixtures, together with increasing knowledge of eye tissue physiopathology, might account for these favorable outcomes. These cases

seem to confirm that even a patient with a low Ocular Trauma Score and therefore a poor visual prognosis can undergo a correct modern surgery protocol that avoids major intraoperative complications, and thereby may attain visual results more than adequate for leading an autonomous daily life. This can be of value in terms of patient counseling, treatment, rehabilitation, and research.

Acknowledgment

No author has a financial or proprietary interest in any material or method mentioned.

References

- 1 Barak A, Elhalel A, Pikkal J, et al. Incidence and severity of ocular and adnexal injuries during the Second Lebanon War among Israeli soldiers and civilians. *Graefes Arch Clin Exp Ophthalmol*, 2011, 249:1771–1774.
- 2 Colyer MH, Weber ED, Weichel ED, et al. Delayed intraocular foreign body removal without endophthalmitis during Operations Iraqi Freedom and Enduring Freedom. *Ophthalmology*, 2007, 114:1439–1447.
- 3 Kuhn F, Maisiak R, Mann L, et al. The Ocular Trauma Score (OTS). *Ophthalmol Clin North Am*, 2002, 15:163–165.
- 4 Dong X, Wang W, Xie L, et al. Long-term outcome of combined penetrating keratoplasty and vitreoretinal surgery using temporary keratoprosthesis. *Eye (Lond)*, 2006, 20:59–63.
- 5 Roters S, Hamzei P, Szurman P, et al. Combined penetrating keratoplasty and vitreoretinal surgery with silicone oil: a 1-year follow-up. *Graefes Arch Clin Exp Ophthalmol*, 2003, 241:24–33.
- 6 Garcia-Valenzuela E, Blair NP, Shapiro MJ, et al. Outcome of vitreoretinal surgery and penetrating keratoplasty using temporary keratoprosthesis. *Retina*, 1999, 19:424–429.
- 7 Cillino S, Casuccio A, Di Pace F, et al. A five-year retrospective study of the epidemiological characteristics and visual outcomes of patients hospitalized for ocular trauma in a Mediterranean area. *BMC Ophthalmol*, 2008, 8:6.
- 8 Pieramici DJ, Sternberg P Jr, Aaberg TM Sr, et al. Stout T: A system for classifying mechanical injuries of the eye (globe). The Ocular Trauma Classification Group. *Am J Ophthalmol*, 1997, 123:820–831.