doi: 10.3978/j.issn.1000-4432.2022.04.03
View this article at: https://dx.doi.org/10.3978/j.issn.1000-4432.2022.04.03

·“眼科再生医学”专题·

导读：再生医学是应用生命科学、材料科学、临床医学、计算机科学和工程学等学科的原理和方法，研究和开发用于修复、再生人体各种组织器官的理论和技术的前沿交叉学科，再生医学新材料、新技术、新方法可应用到眼科相关疾病的临床治疗中。为了更好地指导我国眼科再生医学基础与临床研究，宣扬我国眼科医务及科技工作者的整体风貌，展现我国眼科前沿研究的综合实力，《眼科学报》邀请了一批权威专家撰稿，组织“眼科再生医学”专题。文章将陆续在《眼科学报》上发表，向国内读者展示优秀的原创性研究成果。

生物工程角膜应用于感染性角膜炎的临床观察

康黔，杨雨昆，姚晓明

(成都爱迪眼科医院角膜病专科，成都 610072)

[摘　要]　**目的：**观察生物工程角膜应用于感染性角膜炎的治疗效果。**方法：**对成都爱迪眼科医院19例采用生物工程角膜治疗的感染性角膜病角膜植片存活状况、术后视力变化及并发症进行回顾性分析。与同期22例人来源供体角膜移植行术后排异对比。**结果：**在19例患者中，女9例(47.37%)，平均年龄53.32岁；病因中细菌性角膜炎7例(36.84%)，真菌性角膜炎8例(42.11%)，病毒性角膜炎4例(21.05%)。术前裸眼视力检查：光感3例(光定位准)，手动5例，眼前指数4例，3.0~3.9者7例。随访1~14个月未发生原发感染复发；植片成活18例(94.74%)，1例1月内植片溶解再手术(5.26%)。裸眼视力4.0~4.5者15例(78.95%)，3.0~4.0者3例(15.79%)，数指1例(5.26%)。远期(6~12个月以上)生物工程角膜移植术后角膜缘新生血管更易侵入，以植片缘环形浑浊为主。两组间排异差异无统计学意义(Mann-Whitney检验，P=0.736)。**结论：**生物工程角膜具有较好的人角膜结构替代功能，对未累及全层的感染性角膜疾病起到较好的结构和功能重建作用，恢复有用视力，缓解角膜供体来源不足，有一定推广意义。

[关键词]　生物工程角膜；板层角膜移植；感染性角膜病；排斥反应；预后

Clinical observation of bioengineered cornea in infectious keratitis

KANG Qian, YANG Yukun, YAO Xiaoming

(Department of Cornea, Chengdu Aidi Eye Hospital, Chengdu 610072, China)

Abstract　**Objective:** To observe the outcomes of bioengineered cornea for lamellar keratoplasty in the infectious keratitis. **Methods:** A total of 19 cases with infectious keratitis treated by bioengineered cornea in Chengdu Aidi Eye

收稿日期 (Date of reception)：2021–07–19
通信作者 (Corresponding author)：康黔，Email: 516263569@qq.com

Hospital were analyzed retrospectively. The results of graft survival, visual acuity and complications were collected. Rejection reaction was compared with 22 cases of human donor corneal lamellar keratoplasty during the same period. **Results:** In the 19 cases patients, 9 cases were women (47.37%) with the average age of 53.32 years. Among the pathogenic factors, 7 cases were bacterial keratitis (36.84%), 8 cases were fungal keratitis (42.11%) and 4 cases were viral (21.05%). The results of preoperative uncorrected visual acuity (UCVA) showed that 3 cases were light perception (accurate light positioning), 5 cases were hand moving, 4 cases were counting finger, and 7 cases were in the range of 3.0–3.9. In the follow-up, no case of primary infection recurrence occurred; 18 grafts survived except one case dissolved end with re-transplant by human donor. The postoperative UCVA of 15 cases (78.95%) were in the range of 4.0–4.5, 3 cases were in the range of 3.0–4.0 (15.79%), and 1 case of counting finger (5.26%). There was no significant difference in rejection action (P=0.736). In the follow-up more than 6–12 months, the limbal neovascularization of the biological engineering cornea is more likely to invade with the result of ring shape opacity at the graft edge. **Conclusion:** The biological engineering cornea can play a good role in the reconstruction for the cases with infectious keratitis. It provides another way to solve the shortage of corneal grafts.

Keywords bioengineered cornea; lamellar keratoplasty; infectious keratopathy; rejection; prognosis

感染性角膜炎是一大类致盲率极高的角膜病变。针对该类疾病较多采用角膜移植进行救治。及时的角膜移植可以有效控制感染，甚至部分恢复患者视力。角膜供体严重缺乏是限制急诊角膜移植手术开展的主要原因。寻求一种在一定程度上能替代人供体角膜的材料，让严重的角膜炎患者能及时接受角膜移植治疗，挽救眼球及视力，是角膜移植医师所非常期望的。生物工程角膜(脱细胞猪角膜基质)于2005年开始临床试用，后经全国多中心研究，在155名患者知情同意的情况下，经过5年完成生物工程角膜移植的临床试验，研究证实其有效率达到94.4%，并于2015年获得了我国食品药品管理局的上市批准[1]。

四川省位于我国西南部，气候潮湿，又是西部农业大省，每年农忙季节均有大量的感染性角膜炎患者发病。很多患者因供体材料缺乏而无法及时行治疗性角膜移植，导致视力严重受损甚至眼球不保。为了对感染性角膜病患者进行急诊角膜移植手术治疗，缓解供体材料的匮乏。成都爱迪眼科医院自2018年9月至2021年2月使用生物工程角膜(脱细胞猪角膜基质，艾欣瞳)为19例感染性角膜病患者实施板层移植手术并取得较好疗效。

1 对象与方法

1.1 对象

本研究经成都爱迪眼科医院医学伦理委员会批准，按照赫尔辛基宣言执行，患者均签署知情同意书，确认所有操作和信息。术前询问患者病史，行裂隙灯显微镜、激光扫描共焦显微镜、前节光学相干断层扫描(optical coherence tomography，OCT)扫描以及角膜刮片检查。纳入标准：药物保守治疗1~2周以上，病灶继续扩大或者病情无法控制者，相关检查提示角膜病灶深度大于角膜厚度1/2以上，未累计全层者。排除标准：病灶累计角膜全层或穿孔、视网膜脱离。实验组使用猪角膜脱细胞基质生物工程角膜(艾欣瞳，艾尼尔角膜工程有限公司，深圳)。同期因感染性角膜炎而使用捐献角膜行板层角膜移植的案例作为对照组。

1.2 方法

1.2.1 手术方法

所有手术由同一名术者完成(康黔)。采用表面麻醉及2%利多卡因球后阻滞麻醉。根据角膜病变范围确定植床大小，选用合适环钻(多为7.25~7.5 mm)

划界，标示出病变角膜切除范围。取出4 ℃保存的冻干艾欣瞳，厚度为400 μm，4 ℃复方生理盐水复水15 s左右，采用与植床等大的环钻钻取艾欣瞳植片备用。手法湿剥切除包括角膜病变区及病变边缘外约0.25 mm范围的正常角膜组织，制作植床。剖切植床过程中，用林格液滴淋植床，通过剖切界面上的水层，易于观察感染灶是否被彻底剖除干净。将艾欣瞳植片置于植床，10-0尼龙线间断缝合植片。缝合深度达植片厚度的4/5以上。线头埋藏至植床层间[2]。结膜下注射5%头孢唑林钠0.4 mL。单眼包扎，眼罩保护。对照组术式相同，仅角膜来源差异。

1.2.2 术后治疗

术后3 d内针对原发病病原体分别给予静脉滴注头孢唑林钠或伏立康唑、局部滴用左氧氟沙星眼液(可乐必妥)、普罗纳克眼液、他克莫司眼液和表皮生长因子眼液等。根据感染控制情况静脉给药5~7 d，术后2~4周开始眼部滴用皮质类固醇眼液、他克莫司眼液及人工泪液，并逐渐减量维持6~12个月。依植片愈复情况、角膜全景图及医学验光结果，术后2个月开始分次拆除缝线。

术后第1年每个月复诊1次，行眼前节照相、前节OCT、眼压、视力检查及验光检查。

1.2.3 排斥反应评分标准

1)上皮愈合不良(面积大小)：无为0分，<1/3植片范围为1分，1/3~1/2植片范围为2分，>1/2植片范围为3分。2)早期植片水肿(裂隙灯下观察)：不明显为0分，轻度为1分，中度为2分，重度为3分。3)植片溶解(面积大小)：无为0分，<1/3植片范围为1分，1/3~1/2植片范围为2分，>1/2植片范围为3分。4)角膜缘新生血管(象限分布)：无为0分，<1个象限为1分，1~2个象限为2分，>2个象限为3分。5)远期植片透明度(裂隙灯下通过角膜植片观察虹膜)：虹膜纹理清晰为0分，虹膜纹理模糊窥见为1分，虹膜纹理完全窥不清仅见虹膜颜色为2分，完全窥不见虹膜颜色为3分。

1.3 统计学处理

采用SPSS 10.0统计学软件进行数据分析，行Mann-Whitney检验，$P<0.05$为差异有统计学意义。

2 结果

2.1 术前资料

在19例患者中，女9例(47.37%)，男10例(52.63%)。70岁以上1例，>60~70岁5例，>50~60岁5例，>40~50岁6例，>30~40岁1例，20~30岁1例，平均年龄53.32岁。术前诊断：细菌性角膜炎7例(36.84%)，真菌性角膜炎8例(42.11%)，病毒性角膜炎4例(21.05%)。术前视力检查：光感3例(光定位准确)，手动5例(光定位准确)，数指4例，3.0~3.9者7例。外眼及眼附属器正常。

2.2 术后角膜炎症控制情况及角膜愈合程度

术后2~3 d，患眼眼表炎症明显减轻，睫状充血逐步消退，术前伴有的角膜内皮斑或者无菌性积脓均消失。术后第2天，角膜上皮开始进入生物工程角膜植片缘，大部分患者在术后4~7 d时上皮修复。1周后，角膜荧光染色可见角膜上皮完全覆盖角膜植片。随访1~14个月，所有病例术后围手术期均未发生原发感染复发。植片成活18例(94.74%)，1个月内植片溶解再手术1例(5.26%)。

2.3 视力变化(以患者最近1次复查视力为术后视力)

裸眼视力4.0~4.5者15例(78.95%)，3.0~4.0者3例(15.79%)，数指1例(并发白内障，5.26%；表1)。

2.4 术后植片透明度及有无排斥反应发生

生物工程角膜排异反应早期表现有急性睫状充血、植片水肿、上皮愈合不良及植片溶解等。中长期表现为角膜缘新生血管侵入，植片透明度缓慢减退，视力逐渐下降等，与人来源角膜排斥表现类似。本试验组病例在上皮修复后植片透明度逐渐提高，3~6个月时植片透明度最好，6个月后，部分患者可见慢性排异反应，新生血管侵入角膜缘进入角膜层间或者围绕植片缘生长，植片缘呈半透明状改变。局部强化他克莫司、百力特眼液可使新生血管萎缩消退、植片透明度改善。排斥预后与对照组间差异无统计学意义($P=0.736$，表2)。但中长期观察(6~12个月及以上)发现生物工

程角膜缘新生血管更明显、植片透明度降低比例较人供体角膜高。远期生物工程角膜植片缘可发生环形玉白色半透明状浑浊，但中央区透明度良好，对视力影响不大。

2.5 典型病例

图1~4所示为4例行生物工程角膜板层角膜移植术的典型病例。

表1 术前术后裸眼视力对比

Table 1 Comparison of uncorrected visual acuity before and after operation

裸眼视力	光感/例	手动/例	数指/例	3.0~4.0/例	4.0~4.5/例
术前	3	5	4	7	0
术后	0	0	1	3	15

表2 生物工程角膜与人供体角膜术后排异反应评分

Table 2 Rejection score of bioengineered and human donor corneal transplantation

序号	评分
生物角膜组	
1	4
2	2
3	3
4	3
5	3
6	2
7	2
8	5
9	7
10	4
11	6
12	4
13	3
14	7
15	2
16	3
17	3
18	3
19	4

续表2

序号	评分
人角膜组	
1	2
2	3
3	3
4	6
5	3
6	4
7	4
8	3
9	2
10	7
11	3
12	2
13	6
14	3
15	4
16	3
17	4
18	6
19	2
20	4
21	4
22	5

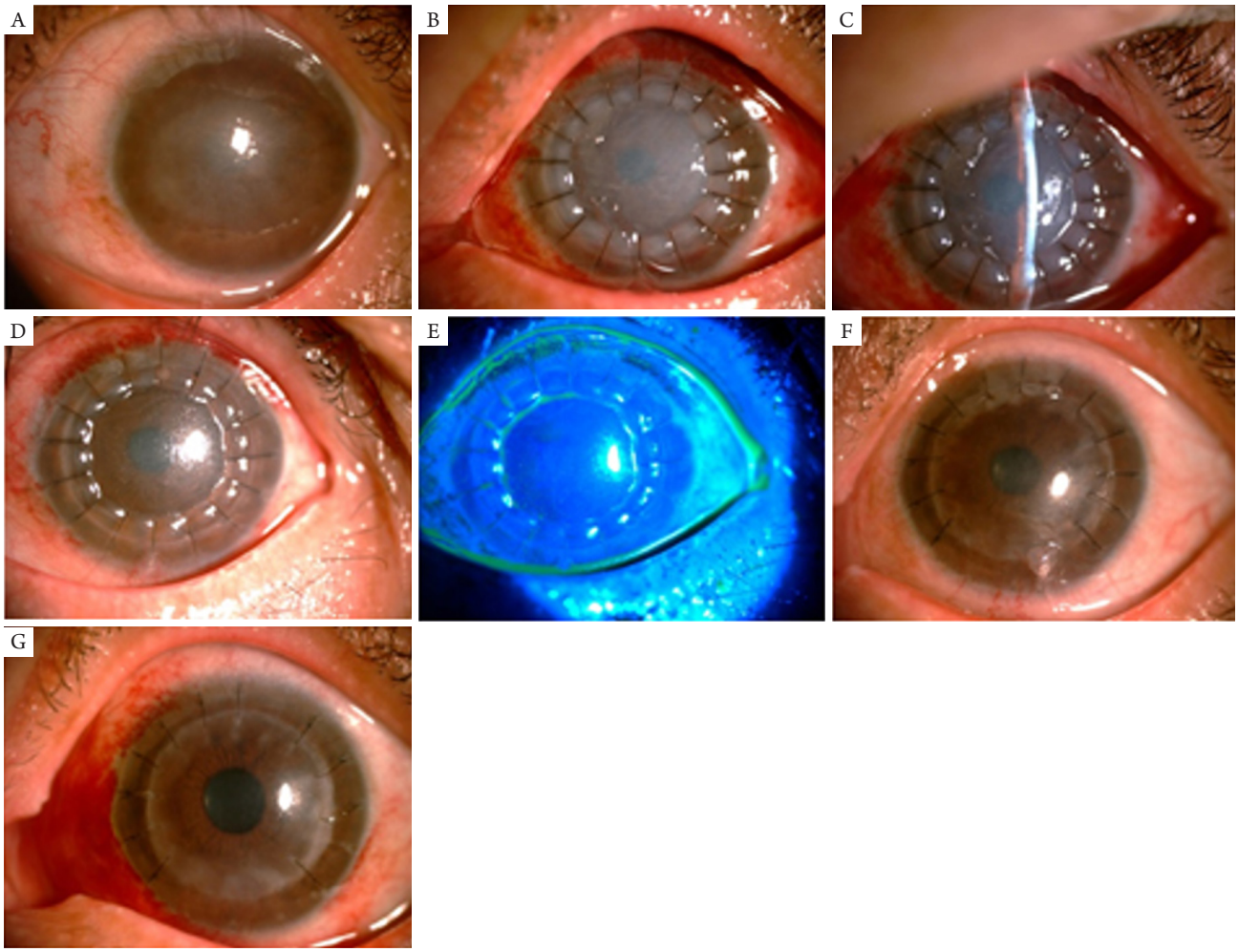

图1 病例1：患者女，49岁，左眼病毒性角膜炎，行生物工程角膜板层角膜移植术

Figure 1 Case 1: A 49-year-old female patient with viral keratitis in her left eye underwent bioengineered lamellar keratoplasty

(A)术前见角膜中央区灰白色浑浊6 mm，瞳孔窥不清，视力手动(hand moving，HM)。(B、C)术后2 d，视力HM，植片灰白色水肿，层间未见积液。给予常规预防感染，局部他克莫司眼液、百立特眼液、玻璃酸钠眼液治疗。(D、E)术后10 d，视力3.7，植片水肿基本消退，透明度改善，缝线未见松脱。继续抗排斥及人工泪液治疗，并口服阿昔洛韦片0.2 g，5次/d，持续3个月。(F)术后1个月，视力4.2，矫正视力4.5。植片中央区透明，部分缝线松脱，拆除松脱缝线。局部给予他克莫司眼液、氯替泼诺眼液、玻璃酸钠眼液治疗。(G)术后3个月，视力4.3，矫正视力4.6。部分缝线松弛，给予拆除缝线处理。局部他克莫司眼液及氯替泼诺眼液减量到每天2次。其余治疗同前。

(A) The corneal opacity was 6 mm in diameter with unclear pupil and vision of HM. (B, C) 2 days after operation, the UCVA was hand moving (HM), the corneal graft was gray and edema, and there was no effusion between layers. Routine infection prevention, topical tacrolimus eye fluid, Prednisolone eye fluid, and sodium hyaluronate eye fluid were given. (D, E) 10 days after surgery, visual acuity was 3.7, graft edema basically subsided, transparency improved, and suture line did not loosen. Continue anti-rejection and artificial tear therapy. Acyclovir 0.2 g were taken orally 5 times a day for 3 months. (F) 1 month after surgery, visual acuity was 4.2 and corrected visual acuity was 4.5. The central area of the graft is transparent, and some sutures are loose. Remove loose sutures, and tacrolimus, loteprednol and sodium hyaluronate were administered locally. (G) 3 months after surgery, visual acuity was 4.3 and corrected visual acuity was 4.6. Some stitches are slack. Suture removal was given. Topical tacrolimus and loteprednol were reduced to twice daily. The rest of the treatment is the same.

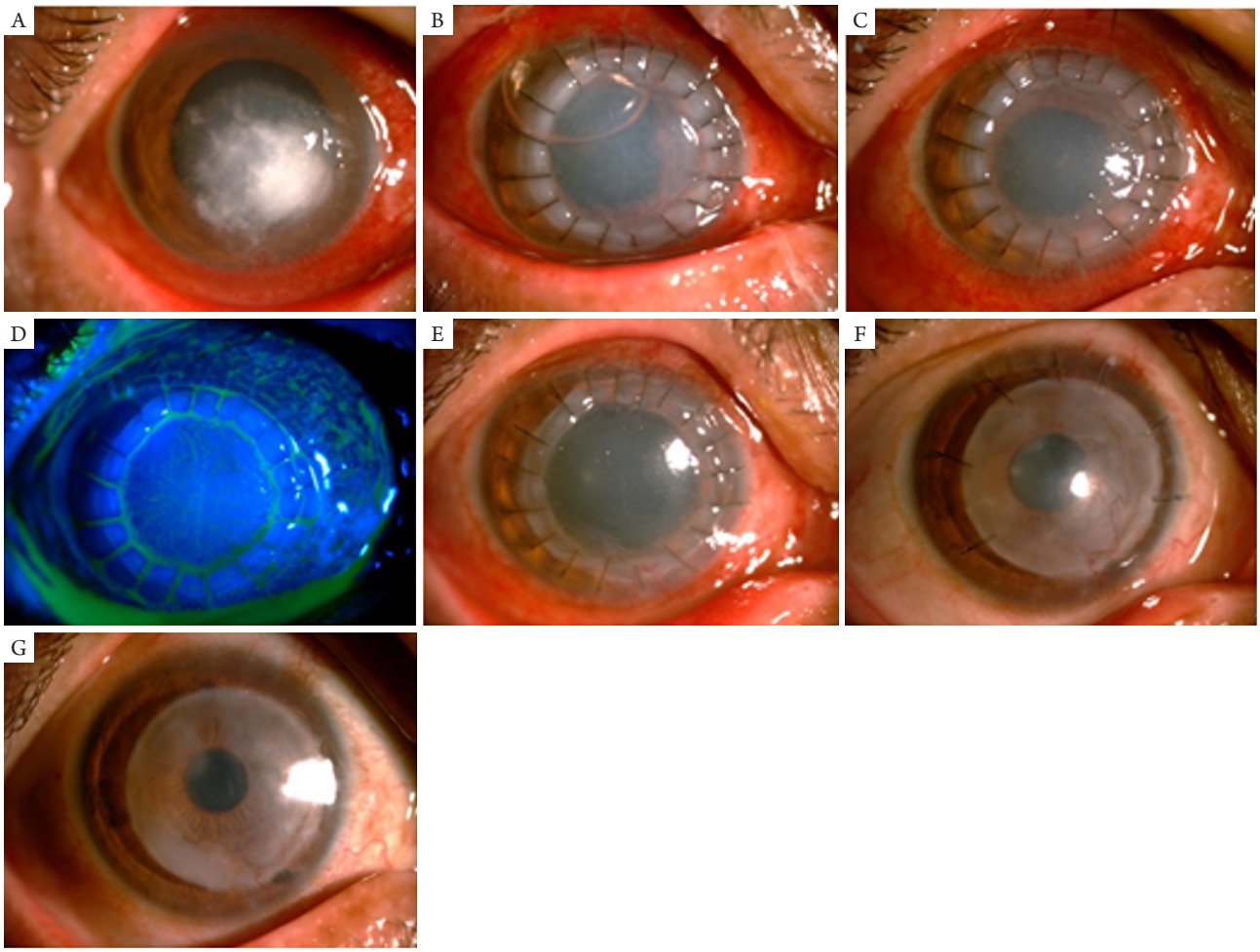

图2 病例2：患者男，50岁，右眼真菌性角膜炎，行生物工程角膜行板层角膜移植

Figure 2 Case 2: A 50-year-old male patient with fungal keratitis of the right eye underwent bioengineered and lamina corneal transplantation

(A)右眼视力HM，角膜中央溃疡约6 mm，边缘羽毛状，苔被形成。(B)术后2 d，视力HM，植片水肿，层间无积液，前房术中所注气泡部分吸收。给予他克莫司眼液、溴芬酸钠眼液、玻璃酸钠眼液，伊曲康唑0.2 g，1次/d，持续3周。(C、D)术后10 d，视力数指(counting fingers，CF)，水肿减轻，上皮修复，层间无积液，继续治疗同前。(E)术后1个月，视力3.7，透明度良好，缝线未见松脱。角膜缘5:30钟点位新生血管侵入角膜层间。停溴芬酸钠眼液，加用氯替泼诺眼液。(F)术后3个月，视力4.0，矫正视力4.4，植片中央区透明度良好，部分缝线拆除。瞳孔直径3 mm，对光反射稍迟钝。拆除所有缝线，继续抗排斥治疗。(G)术后18个月，视力4.5，矫正视力4.7。瞳孔区植片透明度良好。植片缘轻度灰白色浑浊，角膜缘5:30钟点位新生血管变细，部分萎缩。继续他克莫司眼液，2次/d。

(A) Visual acuity HM of the right eye, central corneal ulcer about 6 mm, feathery edge, moss formation. (B) 2 days after surgery, visual acuity HM, implant edema, no interlaminar effusion, bubble injection during anterior chamber partially absorbed. Tacrolimus eye fluid, bromfenac sodium eye fluid, sodium hyaluronate eye fluid, itraconazole 0.2 g, once a day, for 3 weeks. (C, D) 10 days after surgery, visual acuity was counting fingers (CF), edema was relieved, the epithelium was repaired, and there was no interlaminar effusion. The treatment was continued as before. (E) One month after surgery, visual acuity was 3.7, transparency was good, and no loosening of sutures was observed. 5:30 o'clock location of the limbus cornea Limbal neovascularization invades intercorneal layer. Stop bromfenac sodium eye fluid, add loteprednol eye fluid. (F) 3 months after surgery, visual acuity was 4.0 and corrected visual acuity was 4.4. The central area of the implant was transparent and some sutures were removed. The pupil is 3 mm in diameter and slightly insensitive to light reflex. Remove all sutures and continue anti-rejection therapy. (G) 18 months after surgery, visual acuity was 4.5 and corrected visual acuity was 4.7. The pupil area implant has good transparency. 5:30 o'clock location of the limbus cornea, the neovascularization became thinner and some atrophy. Continue tacrolimus eye fluid, 2 times per day.

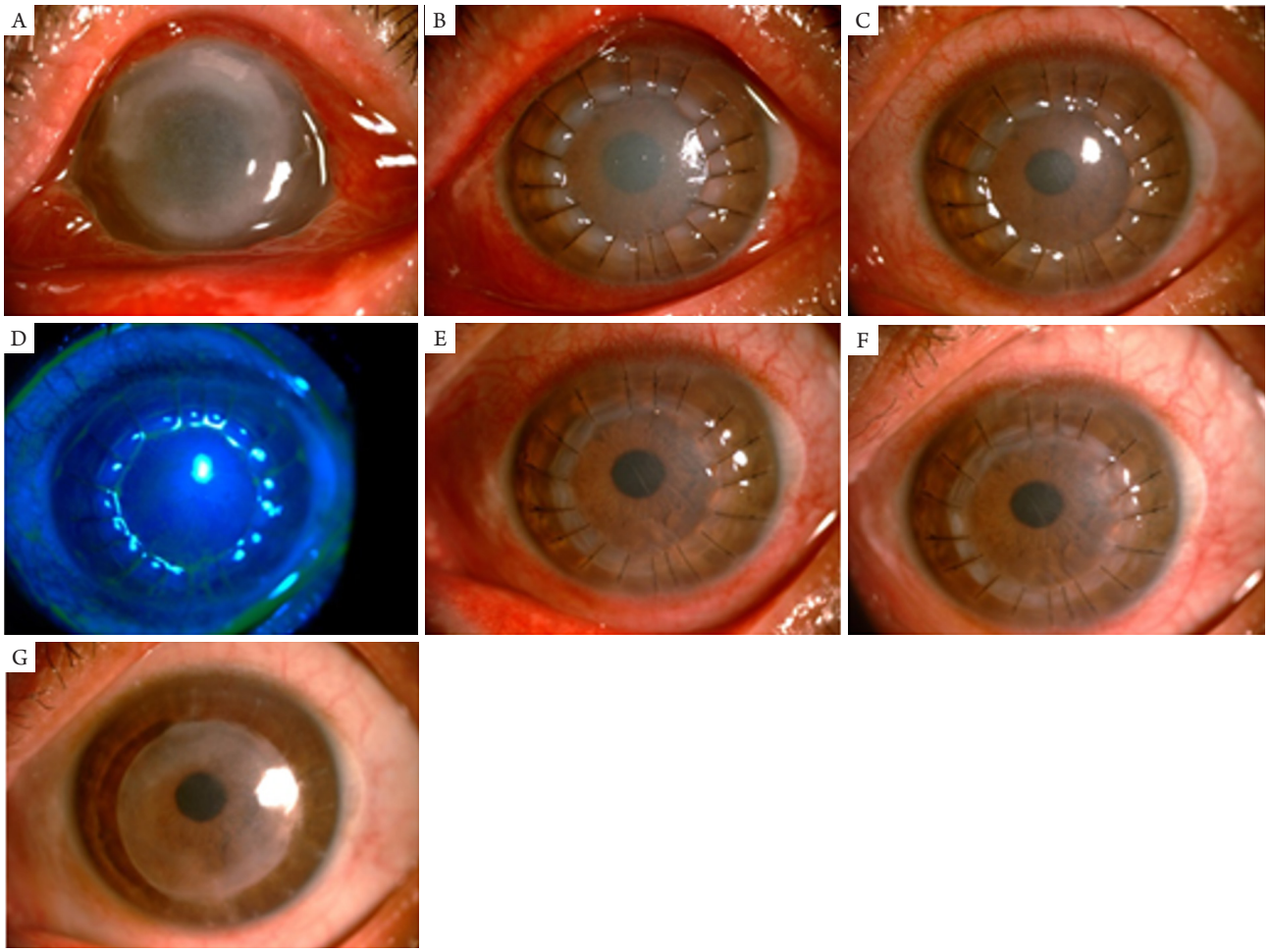

图3 病例3：患者男，67岁，左眼红痛视力下降2 d，铜绿假单胞菌溃疡，行生物工程角膜行板层角膜移植术，术后全身静脉滴注阿米卡星治疗3 d，局部妥布霉素眼液1次/h，他克莫司眼液点眼4次/d，溴芬酸钠眼液点眼2次/d，玻璃酸钠眼液点眼4次/d

Figure 3 Case 3: The patient is a 67-year-old male, with the left eye eyesight decline in 2 d, pseudomonas aeruginosa ulcer, biological engineering corneal andante layer corneal transplantation, postoperative systemic intravenous drip 3 days amikacin therapy, local tobramycin eye drops 1 time per hour, tacrolimus eyedrops eye 4 times per day, bromfenac sodium eye drops eye for 2 times per day, the sodium hyaluronate drops eye 4 times per day

(A)术前视力HM，左眼球结膜高度充血水肿，角膜中央区灰白色溃疡面，直径约6 mm，基质溶解变薄，脓性分泌物附着。(B)术后3 d，视力CF，植片灰白色水肿，层间未见积液。继续治疗同前。(C、D)术后14 d，视力4.1，植片透明，上皮修复良好。对位愈合良好，缝线未见松脱。停用抗生素，继续抗排异治疗。(E)术后1个月，视力4.2，矫正视力4.5，缝线未见松脱。继续抗排异治疗。(F)术后3个月，视力4.2，矫正视力4.5，缝线未见松脱。拆除缝线，继续抗排异治疗。(G)术后14个月，视力4.4，矫正视力4.6。植片缘可见灰白色轻度浑浊。建议他克莫司眼液点眼2次/d，门诊随访。

(A) Preoperative vision HM, the conjunctiva of the left eye was highly hyperemic and edema, the gray and white ulcerated surface of the central cornea was about 6 mm in diameter, the matrix was dissolved and thin, and purulent secretions were attached. (B) 3 days after the operation, the visual acuity was CF, the implant was gray and white with edema, and no interlayer effusion was observed. Continue treatment as before. (C, D) 14 days after surgery, visual acuity was 4.1, the graft was transparent, and the epithelium was well repaired. The sutures did not come loose. Antibiotics were stopped and anti-rejection therapy continued. (E) 1 month after surgery, visual acuity was 4.2, corrected visual acuity was 4.5, and no loosening of sutures was observed. Continue anti-rejection therapy. (F) 3 months after surgery, visual acuity was 4.2, corrected visual acuity was 4.5, and no loosening of sutures was observed. The sutures were removed and anti-rejection therapy continued. (G) 14 months after surgery, visual acuity was 4.4 and corrected visual acuity was 4.6. The phytophilic margin is pale and slightly cloudy. Tacrolimus eye drops were recommended for 2 times per day and outpatient follow-up.

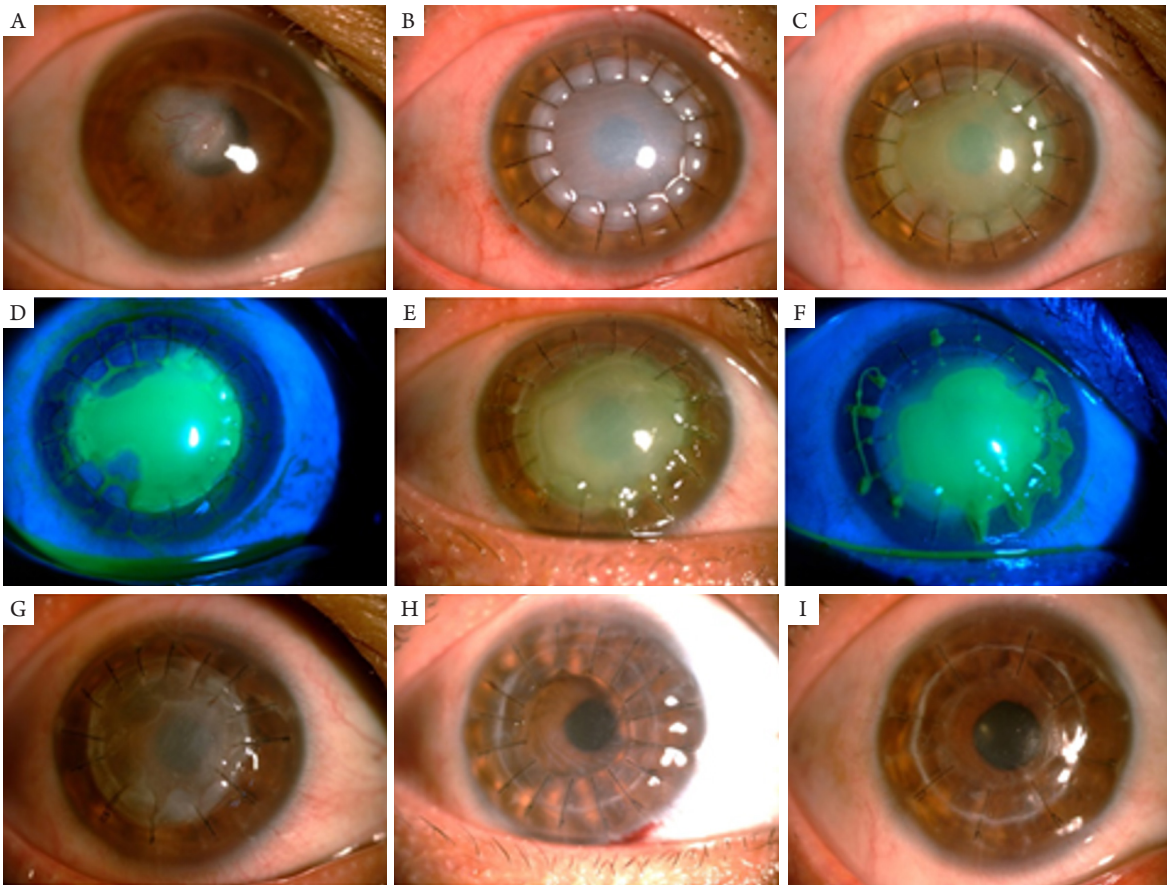

图4 病例4：患者女，39岁，行右眼病毒性角膜炎行生物工程角膜板层角膜移植术

Figure 4 Case 4: A 39-year-old female patient with right eye viral keratitis underwent bioengineered lamellar keratoplasty

(A)术前视力CF，角膜瞳孔区灰白色浑浊直径约3.5 mm。(B)术后2 d，视力HM，植片灰白色水肿，层间未见积液。他克莫司眼液点眼4次/d，泼尼松龙眼液点眼2次/d，玻璃酸钠眼液点眼4次/d。(C、D)术后10 d，视力CF，植片水肿减轻，上皮大部分未修复。对位愈合良好，缝线未见松脱。加用小牛血清眼用凝胶点眼4次/d。(E、F)术后1个月，视力HM，植片上皮广泛缺失，基质部分溶解变薄。拆除松弛缝线，重新缝合。治疗同前。(G)术后2个月，视力CF，缝线未见松脱，植片上皮修复，基质部分溶解变薄，灰白色斑翳形成。去除生物工程角膜植片，更换同种异体人植片。继续抗排异治疗。(H)2次术后1个月，视力4.2，矫正视力4.4。继续抗排异治疗。(I)2次术后3个月，视力4.5，矫正视力4.8。植片透明，部分缝线拆除。

(A) Preoperative visual acuity was CF, and the diameter of the corneal pupil area was about 3.5 mm. (B) 2 days after the operation, the visual acuity was HM, the implant was gray and white with edema, and no interlayer effusion was observed. Tacrolimus eye infusion 4 times per day, prednisolone eye infusion 2 times per day, sodium hyaluronate eye infusion 4 times per day. (C, D) 10 days after surgery, the visual acuity was CF, the graft edema was reduced, and most of the epithelium was not repaired. The sutures did not come loose. Calf serum eye gel was applied 4 times per day. (E, F) 1 month after surgery, visual acuity HM, extensive loss of graft epithelium, partial dissolution and thinning of matrix. Remove loose sutures and resuture. The treatment is the same. (G) 2 months after surgery, the visual acuity was CF, no loosening of the suture was observed, the graft epithelium was repaired, the matrix was partially dissolved and thinned, and gray pall was formed. Bioengineered corneal grafts were removed and allogeneic human grafts replaced. Continue anti-rejection therapy. (H) One month after the second operation, visual acuity was 4.2 and corrected visual acuity was 4.4. Continue anti-rejection therapy. (I) 3 months after the second operation, visual acuity was 4.5 and corrected visual acuity was 4.8. The graft was transparent and some sutures were removed.

3 讨论

我国是世界上盲人最多的国家之一(双眼人盲达600万~700万)，其中因角膜病致盲的患者为200万~300万，而且每年以10%的比率增加[2-4]。治疗角膜盲的第一位方案就是角膜移植，而感染性角膜炎是我国目前角膜移植手术的主要适应证[5]。角膜来源匮乏使得我国无法为感染性角膜病提供

急诊手术所需[2-5]。

2010年武汉协和医院眼科首次将由猪角膜制成的人工生物角膜“艾欣瞳”应用于人类角膜移植。2015年“艾欣瞳”通过国家食品药品监督管理总局注册并应用于临床，成为全球首个生物工程角膜产品。有研究团队[6-10]使用人工生物角膜移植治疗真菌性角膜炎患者，通过最少6个月的随访证实了人工生物角膜应用在人角膜移植中的安全性和有效性。

本组病例中植片成活率达到94.74%，大部分患者保全眼球的同时恢复了有用视力。艾欣瞳植片成活的关键在于早期上皮化。术后3 d，在植片边缘线结处，角膜上皮生长；术后10 d，角膜水肿基本消退，角膜上皮细胞跨过植片边缘，向中心生长，逐步完成角膜上皮化，但是荧光素染色仍能观察到点状染色；术后1个月，植片透明度逐渐恢复，角膜上皮化良好。猪脱细胞角膜基质能够与角膜上皮细胞形成紧密结合，上皮细胞黏附稳定[11-13]。本研究显示：术后2~3 d，角膜上皮开始进入生物工程角膜植片缘，大部分在4~7 d上皮修复并逐渐排列规则。

对照组植片上皮术后1~3 d能修复，且上皮完整修复后可出现良好透明度。而生物工程角膜组透明度随上皮修复逐渐改善，术后1~2周时逐渐透明，1个月左右趋于稳定，且上皮修复越快，后期植片透明度更佳。研究[12,14-15]报道：约术后5个月，在共焦显微镜下可观察到植片上皮下有少量神经纤维长入，提示上皮愈合后要持续注意上皮情况。此外，远期观察(6~12个月及以上)部分生物工程角膜植片缘有新生血管侵入，基质呈环形玉白色半透明状浑浊，透明度较同期移植的人供体板层角膜植片低(病例1~3)。

本组1例病毒性角膜炎患者(病例4)于术后1个月出现植片溶解，可能与复水过度、缝线松紧不一、植片-植床尺寸设计不当等多重因素有关，进而导致术后2周缝线松脱，植片上皮化延迟，甚至基质溶解。重新缝合后，虽然植片透明度一度得到改善，但因溶解的植片结构难以修复。更换人角膜板层移植3个月后，矫正视力达4.8。

本研究结果显示：与脱水保存的人角膜植片相比，艾欣瞳植片复水需时大大缩短，复水后植片迅速膨大，可能与其异种生物属性有关。植片复水开始后用食指和拇指捏持植片，感知植片由“硬”变“韧”且稍可弯曲即停止复水，同时及时将植片的水分吸净，整个复水时间不应超过15 s。植片直径应与植床相同，否则植片极易超过植缘形成“植片骑跨”而导致植片-植床无法良好对合，影响缝合及上皮愈复。此外，与同种异体角膜植片相比，艾欣瞳植片的缝线易于松动，会导致上皮难以愈合，基质溶解。因此术后需严密观察，一旦缝线松动即行拆除，必要时可重新缝合，但缝针应避开原有线道以防止针孔扩大、豁开植片。我们自术后2个月起即逐步拆线，比同种异体角膜移植拆线早1~2个月，这将有助于减少因松线引起的炎性反应和植片溶解[14,16-17]。

综上，生物工程角膜在上皮修复时间、植片透明度、植片远期稳定性等方面不及新鲜同种异体角膜植片，但生物工程角膜基质具有较好的结构替代功能，移植后能够在人眼长期存活，部分治疗性角膜移植患者的视力得到一定程度的改善。在紧急情况下，生物工程角膜可作为同种异体角膜的替代材料，对患者进行急诊角膜移植。尽管该材料的适用范围较窄，仅用于药物治疗无效的尚未穿孔的角膜溃疡，但仍有望在一定程度上缓解角膜供体的缺乏。有学者[18-20]观察到移植的猪脱细胞基质内并未出现基质细胞，推测猪角膜基质本身并不适合人角膜基质细胞的生长，不能排除猪角膜脱细胞基质存在某些缺陷。由于目前同类研究观察的样本量较少，观察时间较短，其围手术期并发症的处理以及远期预后及安全性评价还需更大样本量的长期观察和研究。

开放获取声明

参考文献

1. 史伟云, 高华. 中国角膜病诊疗技术70年发展回顾[J]. 中华眼科杂志, 2020, 56(6): 401-408.
SHI Weiyun, GAO Hua. A summary of China's 70 years of development in diagnosis and treatment targeting corneal diseases[J].

Chinese Journal of Ophthalmology, 2020, 56(6): 401-408.

2. 刘志玲, 高明宏, 陈颖欣. 生物工程角膜与人供体角膜治疗真菌性角膜溃疡的比较[J]. 中国组织工程研究, 2020, 24(10): 1563-1569.
LIU Zhiling, GAO Minghong, CHEN Yingxin. Bio-engineering cornea versus human donor cornea in the treatment of fungal corneal ulcer[J]. Chinese Journal of Tissue Engineering Research, 2020, 24(10): 1563-1569.
3. 史伟云. 以生物工程角膜为供体的板层角膜移植术治疗真菌性角膜炎[J]. 中华眼科杂志, 2019, 55(6): 463.
SHI Weiyun. Lamellar keratoplasty with bioengineering cornea as donor in the treatment of fungal keratitis[J]. Chinese Journal of Ophthalmology, 2019, 55(6): 463.
4. 刘全坤, 李恒, 杨旭苟, 等. 生物工程角膜移植对真菌性角膜溃疡的临床疗效及其对组 织形态学的影响[J]. 中国医学前沿杂志(电子版), 2021, 13(11): 102-106.
LIU Quankun, LI Heng, YANG Xugou, et al. The clinical effect of bioengineered corneal transplantation on fungal corneal ulcer and its influence on histomorphology[J]. Chinese Journal of the Frontiers of Medical Science. Electronic Version, 2021, 13(11): 102-106.
5. 林莉. 生物工程角膜移植治疗感染性角膜炎[J]. 国际眼科杂志, 2019, 19(10): 1728-1732.
LIN Li. Bioengineered keratoplasty for infectious keratitis[J]. International Eye Science, 2019, 19(10): 1728-1732.
6. 曲晓瑜, 储昭节, 马强, 等. 生物工程角膜移植治疗病毒性角膜炎疗效观察[J]. 海南医学, 2019, 30(21): 2805-2807.
QU Xiaoyu, CHU Zhaojie, MA Qiang, et al. Effect of bioengineered corneal transplant for treatment of herpes simplex keratitis[J]. Hainan Medical Journal, 2019, 30(21): 2805-2807.
7. 范祥雨, 黄霏霏, 张朝然, 等. 利用猪角膜脱细胞基质行板层角膜移植手术治疗感染性 角膜炎的临床研究[J]. 中国眼耳鼻喉科杂志, 2021, 21(5): 330-334.
FAN Xiangyu, HUANG Feifei, ZHANG Chaoran et al. Clinical study on the treatment of infectious keratitis with lamellar keratoplasty using porcine corneal acellular stroma[J]. Chinese Journal of Ophthalmology and Otorhinolaryngology, 2021, 21(5): 330-334.
8. Zheng J, Huang X, Zhang Y, et al. Short-term results of acellular porcine corneal stroma keratoplasty for herpes simplex keratitis[J]. Xenotransplantation, 2019, 26(4): e12509.
9. Chen Y, Zhang L, Liu Z, et al. Efficacy of lamellar keratoplasty with acellular porcine corneal stroma in treatment for infectious central and peripheral corneal ulcers[J]. Ther Clin Risk Manag, 2021, 17: 623-634.
10. Zheng Q, Zhang Y, Ren Y, et al. Deep anterior lamellar keratoplasty with cross-linked acellular porcine corneal stroma to manage fungal keratitis[J]. Xenotransplantation, 2021, 28(2): e12655.
11. Li S, Deng Y, Tian B, et al. Healing characteristics of acellular porcine corneal stroma following therapeutic keratoplasty[J]. Xenotransplantation, 2020, 27(2): e12566.
12. 段虎成, 陈瑞, 罗嘉婧. 猪脱细胞角膜基质人板层角膜移植术后植片上皮化的临床观察[J]. 眼科学报, 2019, 34(2): 85-89.
DUAN Hucheng, CHEN Rui, LUO Jiajing. Clinical observation of the epithelization of grafts after human lamellar keratoplasty with acellular porcine corneal stroma[J]. Eye Science, 2019, 34(2): 85-89.
13. Li H, Zhao L, Wang F, et al. Natural cross-linker-stabilized acellular porcine corneal stroma for lamellar keratoplasty[J]. Acta Biomater, 2020, 114: 270-284.
14. 程燕, 吴洁, 朱海峰, 等. 生物工程角膜移植术后排斥反应的临床及免疫病理观察: 附5例报告[J]. 国际眼科杂志. 2021, 21(9): 1661-1664.
CHENG Yan, WU Jie, ZHU Haifeng, et al. Clinical and immunopathological study of rejection after bioengineered keratoplasty: a report of 5 cases[J]. International Eye Science, 2021, 21(9): 1661-1664.
15. Li H, Dong M, Zhou Q, et al. Corneal calcification of acellular porcine corneal stroma following lamellar keratoplasty[J]. Acta Ophthalmol, 2022, 100(2): 164-174.
16. Zhang K, Ren XX, Li P, et al. Construction of a full-thickness human corneal substitute from anterior acellular porcine corneal matrix and human corneal cells[J]. Int J Ophthalmol, 2019, 12(3): 351-362.
17. Li S, Xiao P, Deng Y, et al. Acellular porcine corneal stroma may not be optimal for peripheral keratoplasty: reports of 2 cases[J]. Cornea, 2021, 40(4): 502-505.
18. Zhang Y, Hu Z, Qu J, et al. Tissue-engineered corneal endothelial sheets using ultrathin acellular porcine corneal stroma substrates for endothelial keratoplasty[J]. ACS Biomater Sci Eng, 2022, 8(3): 1301-1311.
19. Li S, Li M, Gu L, et al. Risk factors influencing survival of acellular porcine corneal stroma in infectious keratitis: a prospective clinical study[J]. J Transl Med, 2019, 17(1): 434.
20. Xiao YT, Zhao XY, Liu X, et al. Ten-year follow-up of lamellar keratoplasty treatment with acellular porcine corneal stroma: a case report[J]. Cornea, 2022, 41(5): 623-626.

本文引用： 康黔, 杨雨昆, 姚晓明. 生物工程角膜应用于感染性角膜炎的临床观察[J]. 眼科学报, 2022, 37(4): 271-280. doi: 10.3978/j.issn.1000-4432.2022.04.03

Cite this article as: KANG Qian, YANG Yukun, YAO Xiaoming. Clinical observation of bioengineered cornea in infectious keratitis[J]. Yan Ke Xue Bao, 2022, 37(4): 271-280. doi: 10.3978/j.issn.1000-4432.2022.04.03