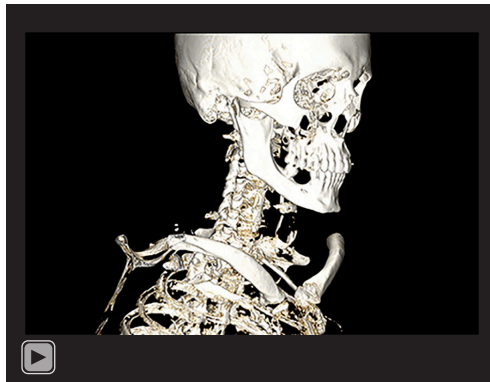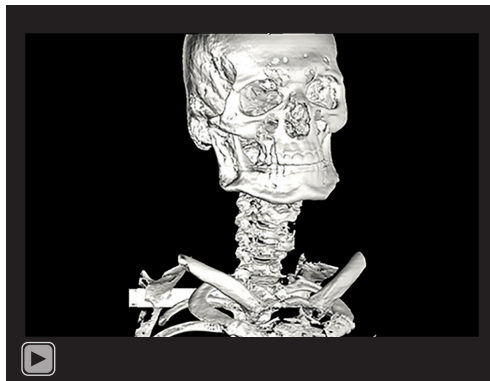


Video S1 Three-dimensional computed tomography reconstruction of an elongated styloid process.



Video S2 Three-dimensional computed tomography reconstruction of a calcified stylohyoid ligament.