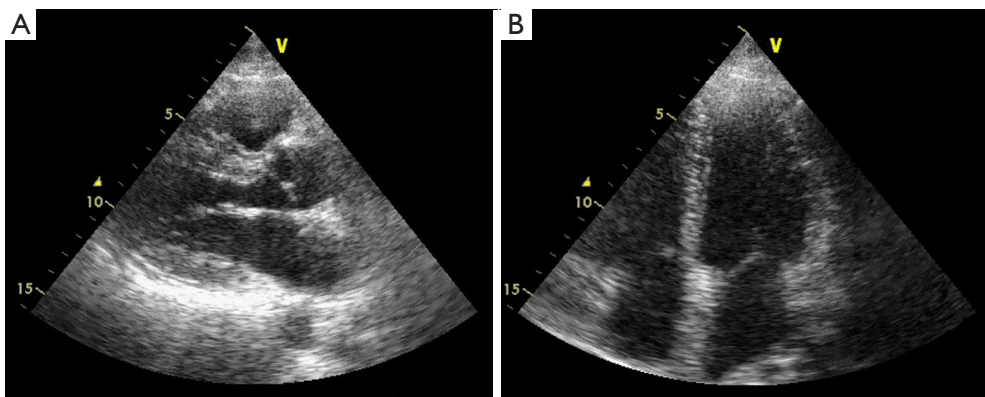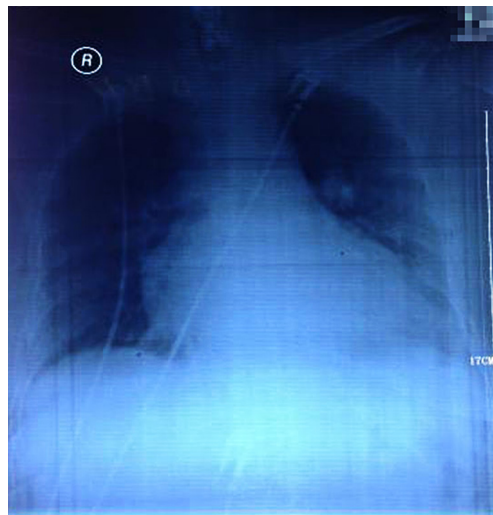


**Figure S1** TTE on 4 months after onset. TTE revealed left atrial enlargement (41 mm), normal left ventricle (48 mm), uneven thickening of the interventricular septum (11–14 mm), slight mitral valve regurgitation, ejection fraction of 59%, and fair coordination of left ventricular wall motion. TTE, transthoracic echocardiography.



**Figure S2** Chest X-ray on the 8th day of onset. A Chest X-ray showed bilateral pulmonary congestion and enlarged heart shadow with the possibility of an enlarged left ventricle.