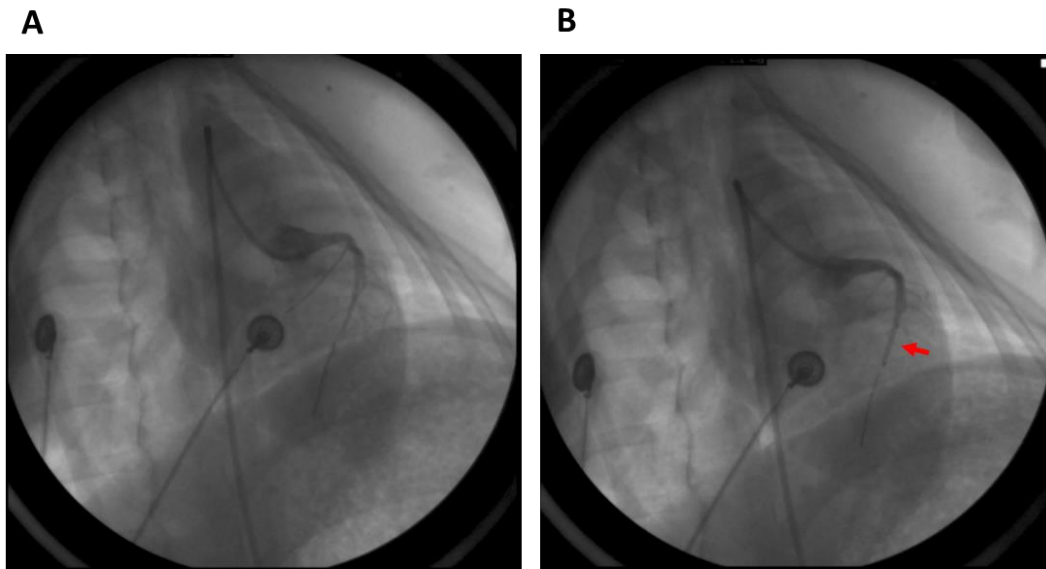


## Supplementary



**Figure S1** Balloon occlusion of the left anterior descending branch was used to establish a porcine model of acute myocardial infarction. (A) The anterior descending coronary artery of a pig; (B) the arrow shows the location of the balloon occlusion.