

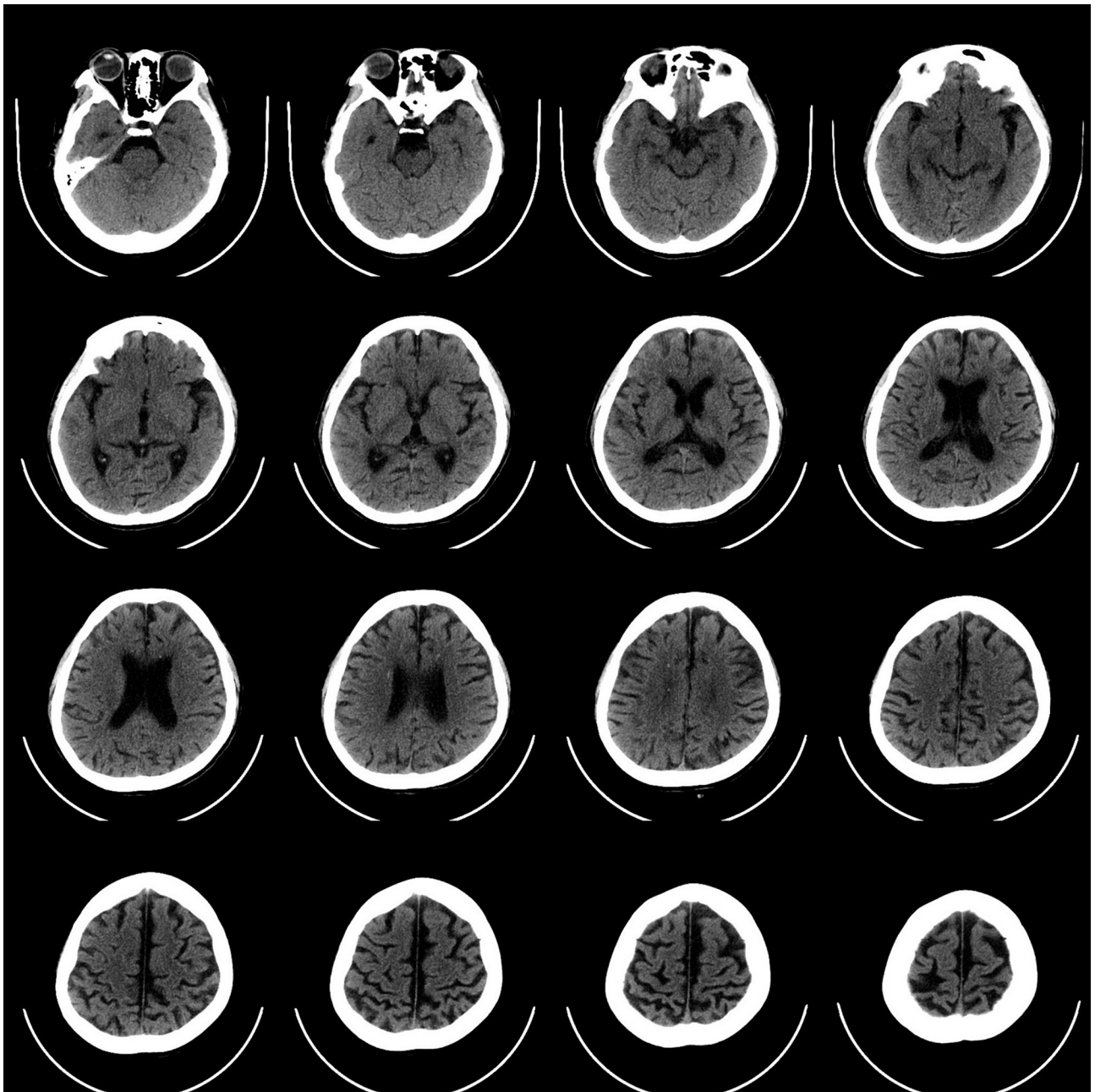Figure S1 Brain CT images of patient 4. Calcifications are located at the frontal horns of the lateral ventricles, periventricular region and centrum semiovale.

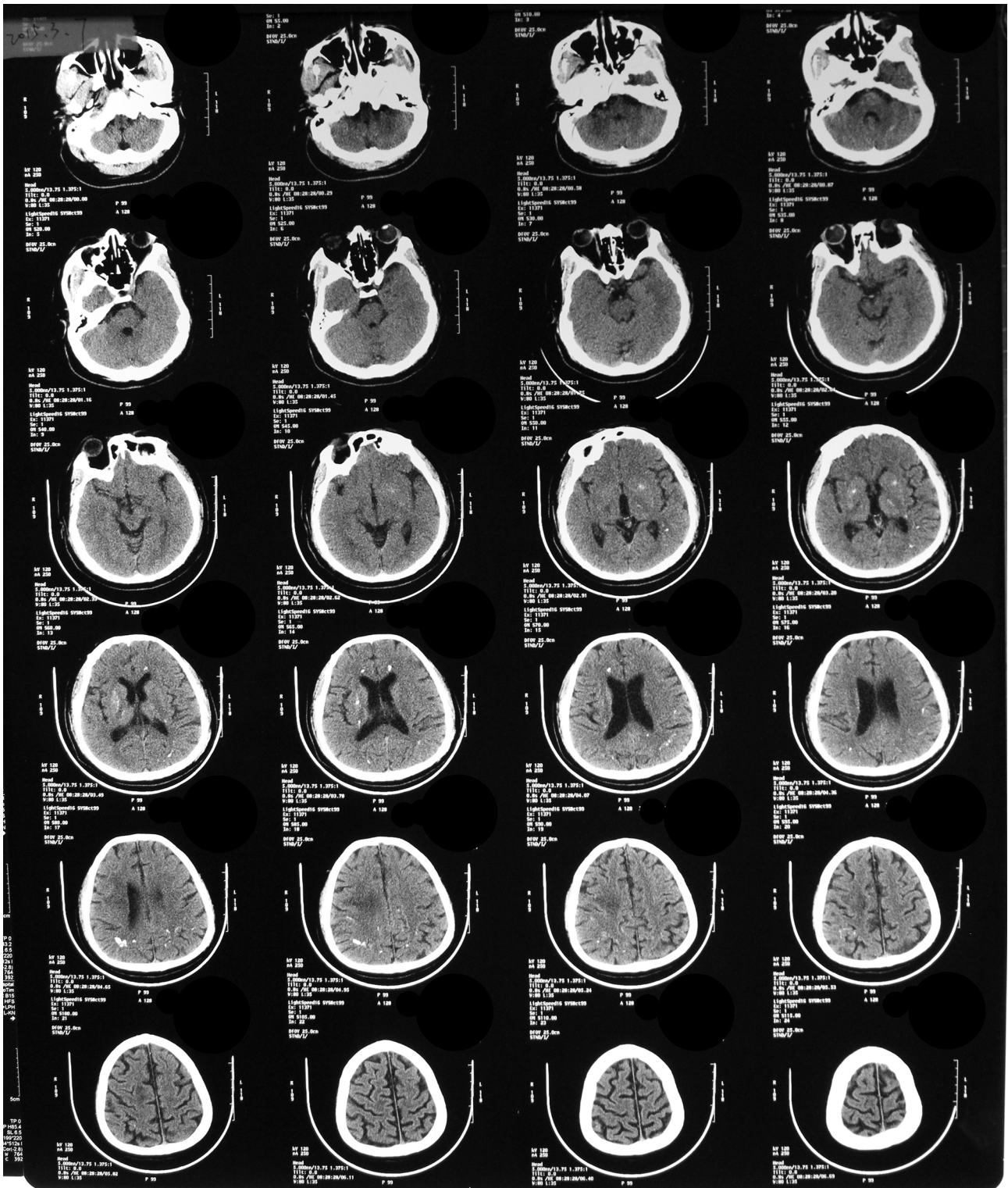


Figure S2 Brain CT images of patient 7. Predominant calcifications are located at extensive white matter regions including the frontal/posterior horns of the lateral ventricles, periventricular and subcortical regions.