

Case 1

Pre-operation

Postoperation

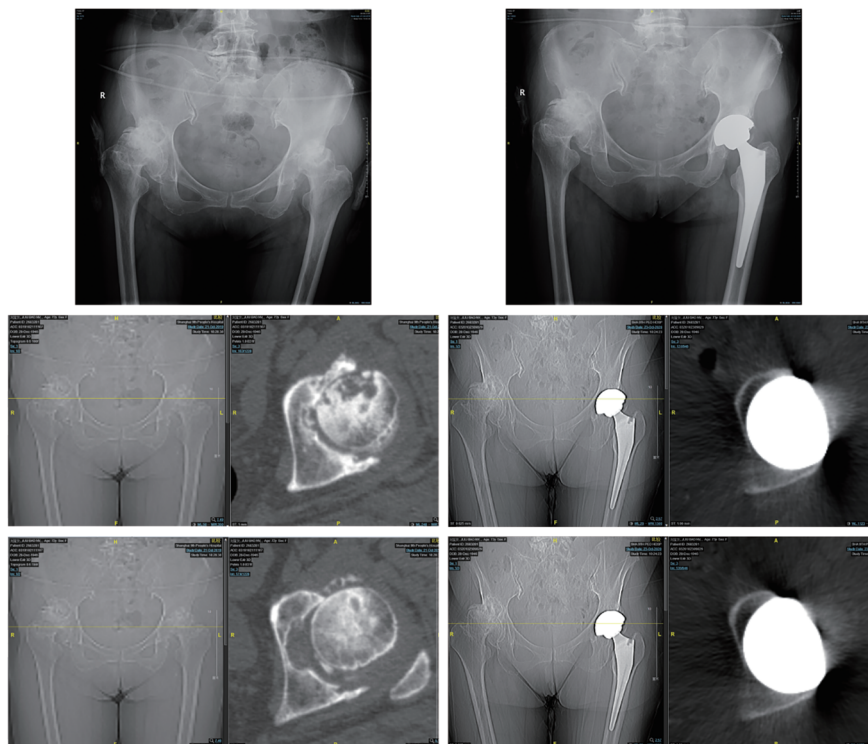


Figure S1 Radiographs of patient 1 in the acetabular edge file group postoperatively.

Case 2

Pre-operation

Postoperation

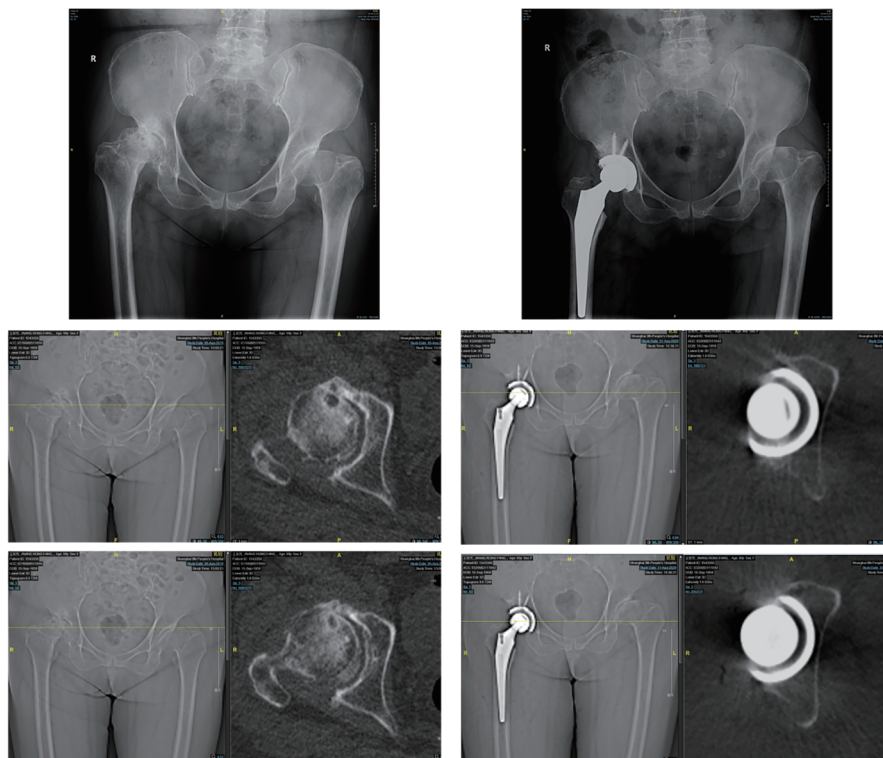


Figure S2 Radiographs of patient 2 in the acetabular edge file group postoperatively.