

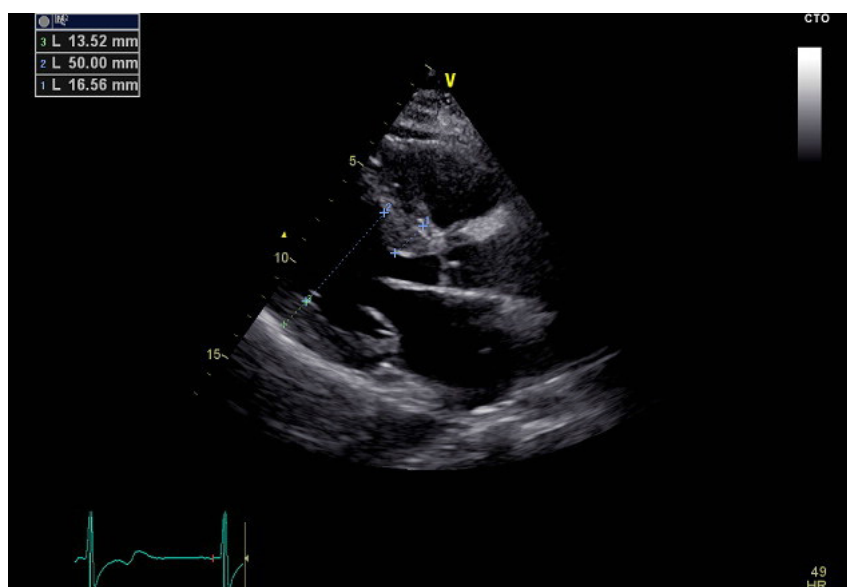Figure S1 Ventricular septal hypertrophy.

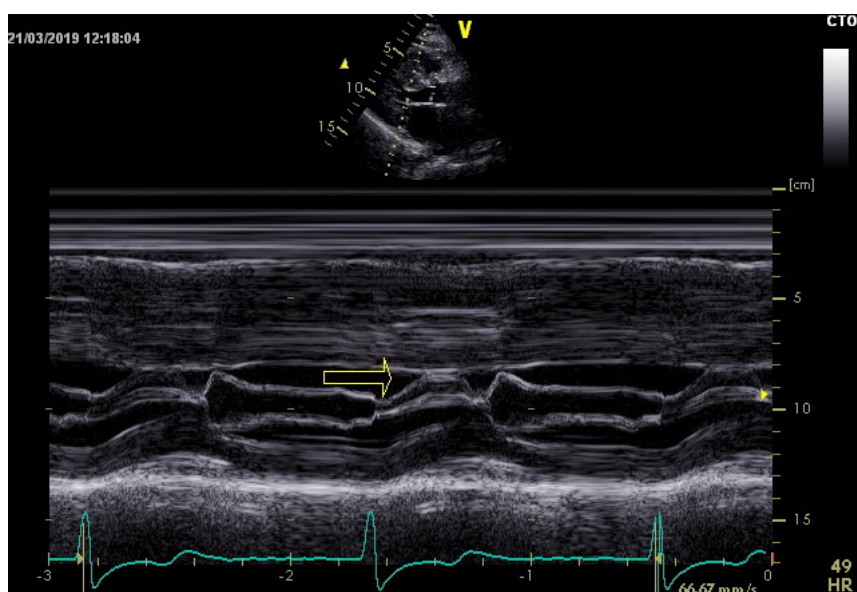


Figure S2 SAM of the mitral valve (arrow) before ablation. SAM, systolic anterior motion.

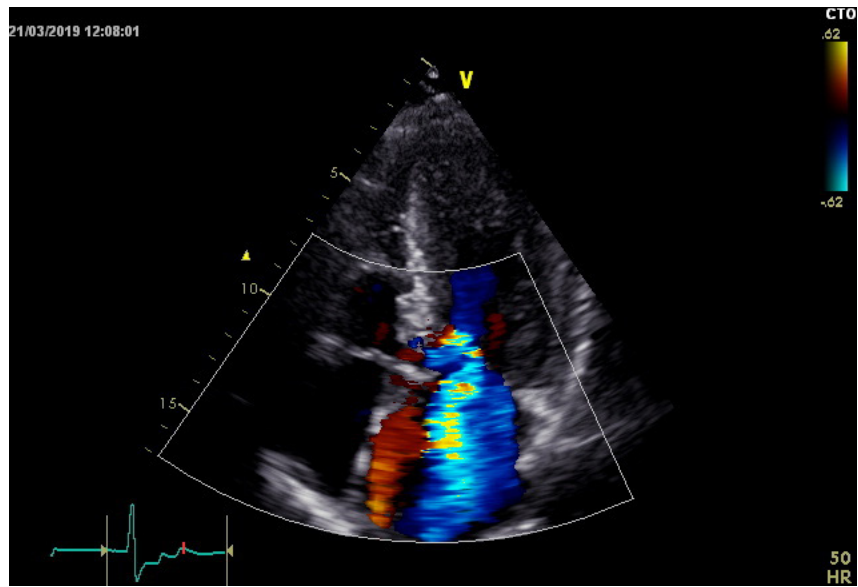


Figure S3 Severe mitral regurgitation before ablation.

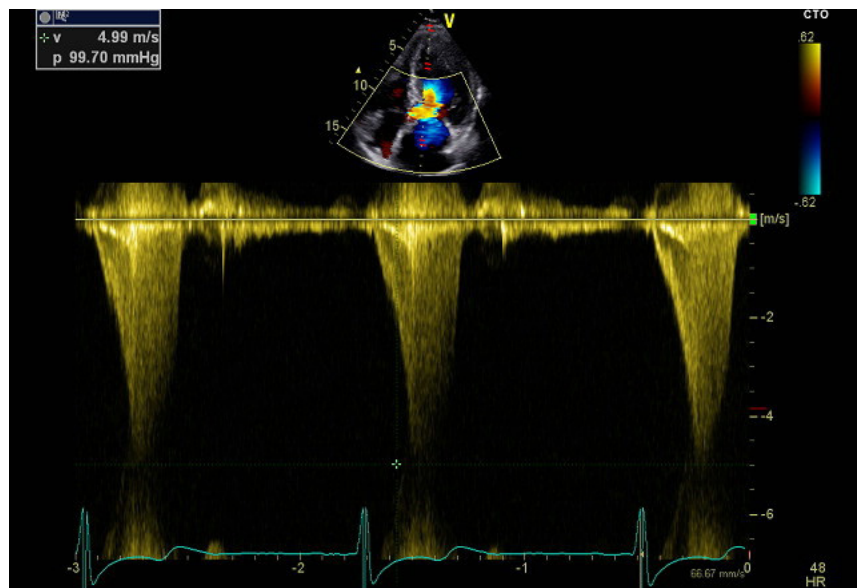


Figure S4 Left ventricular outflow tract obstructions before ablation.

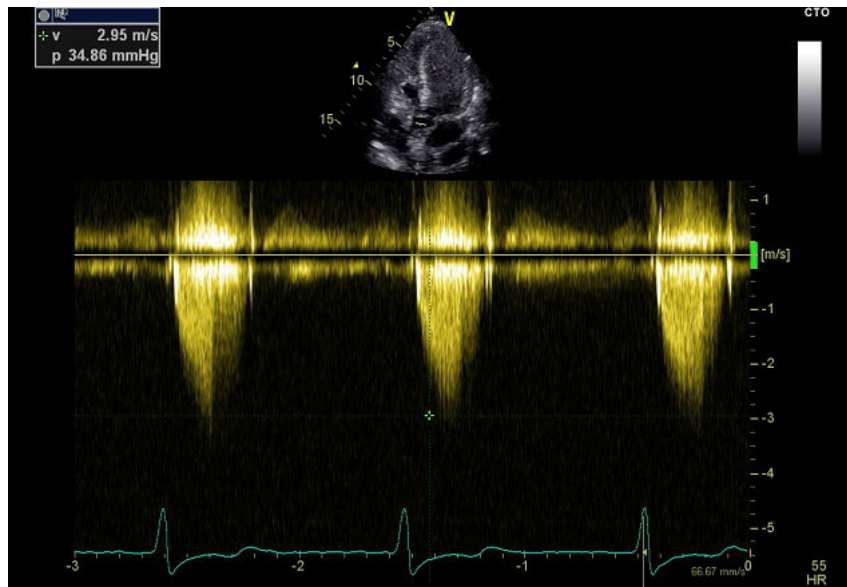


Figure S5 Left ventricular outflow tract obstructions relief after ablation.

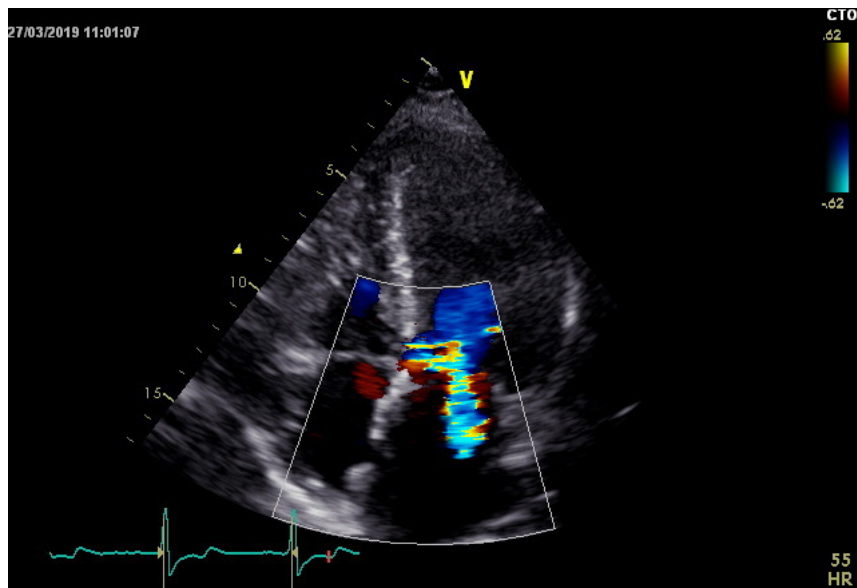


Figure S6 Mild mitral regurgitation before ablation.

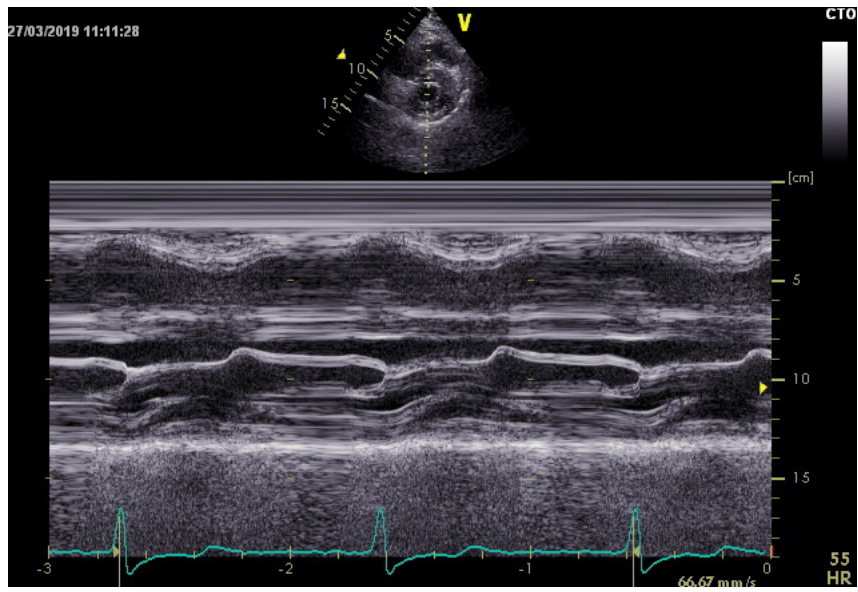


Figure S7 SAM sign relief after ablation. SAM, systolic anterior motion.