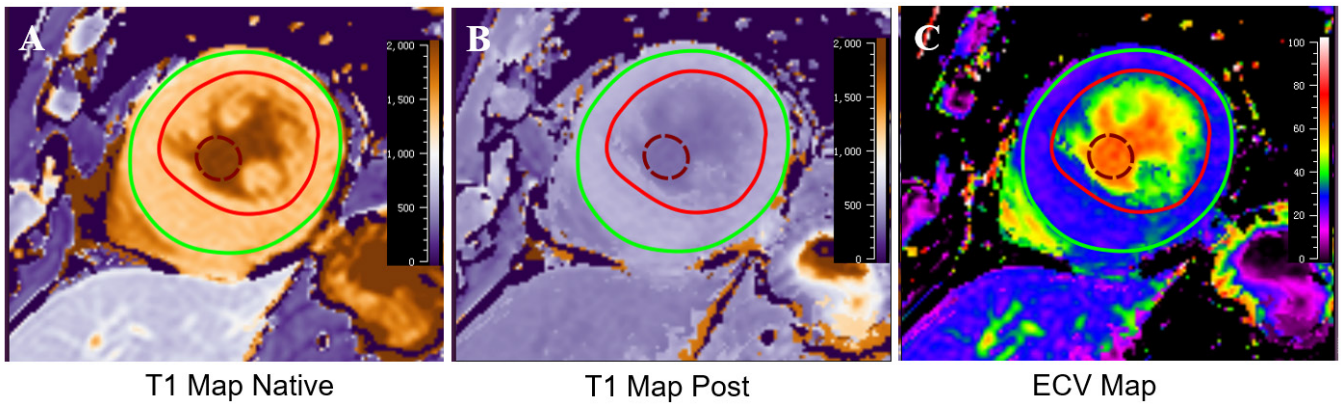

Figure S1 Measurements of native T1, post T1 and ECV mapping images in a patient with severe AS. The region of interest was drawn manually at the endo- and epi-cardial border of the mid-ventricular myocardium (red and green circles), and n at the LV cavity (red dotted circle). (A) Native T1 map with a color scale ranging from 0 (lavender) to 2000ms (brown). (B) Post contrast T1 map with color scale ranging from 0 (lavender) to 2000ms (brown). (C) ECV map ranging from 0 (purple) to 100% (red). ECV, extracellular volume.

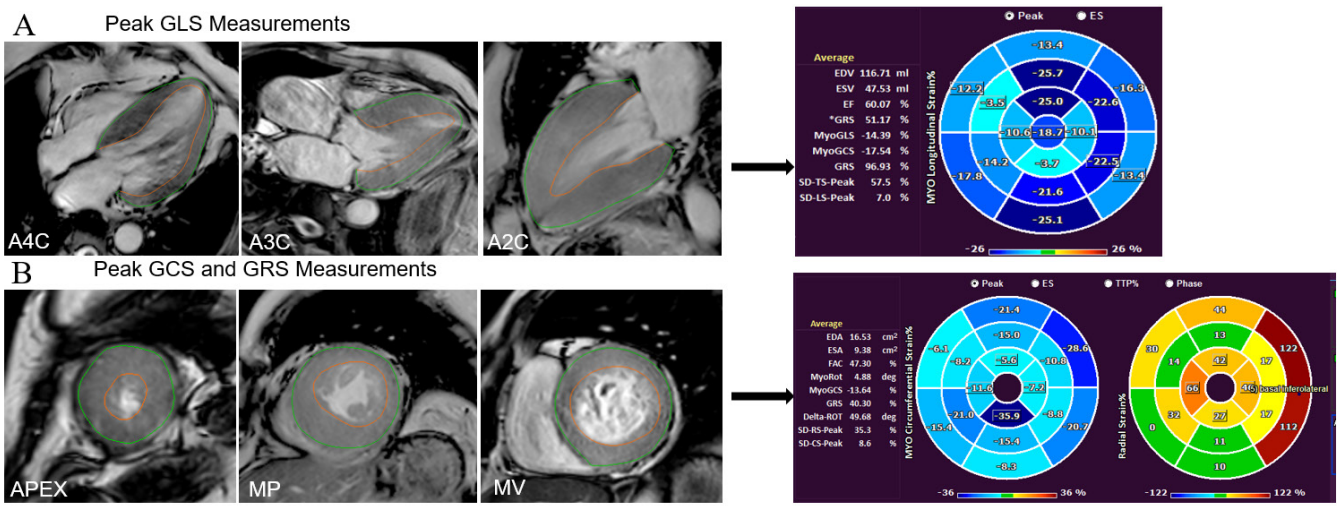

Figure S2 Measurements of feature tracking by CMR in a patient with severe AS. (A) Peak GLS was acquired by delineating endocardial and epicardial contour of A4C, A3C, and A2C in systolic and diastolic phases. (B) Peak GCS and GRS were acquired by delineating endocardial and epicardial contour of Apex, MP and MV slices in systolic and diastolic phase. A4C, apical 4 chamber; A3C, apical 3 chamber; A2C, apical 2 chamber; MP, mid plane; MV, mitral valve; GLS, global longitudinal strain; GCS, global circumferential strain; GRS, global radial strain.

http://dx.doi.org/10.21037/cdt-20-803

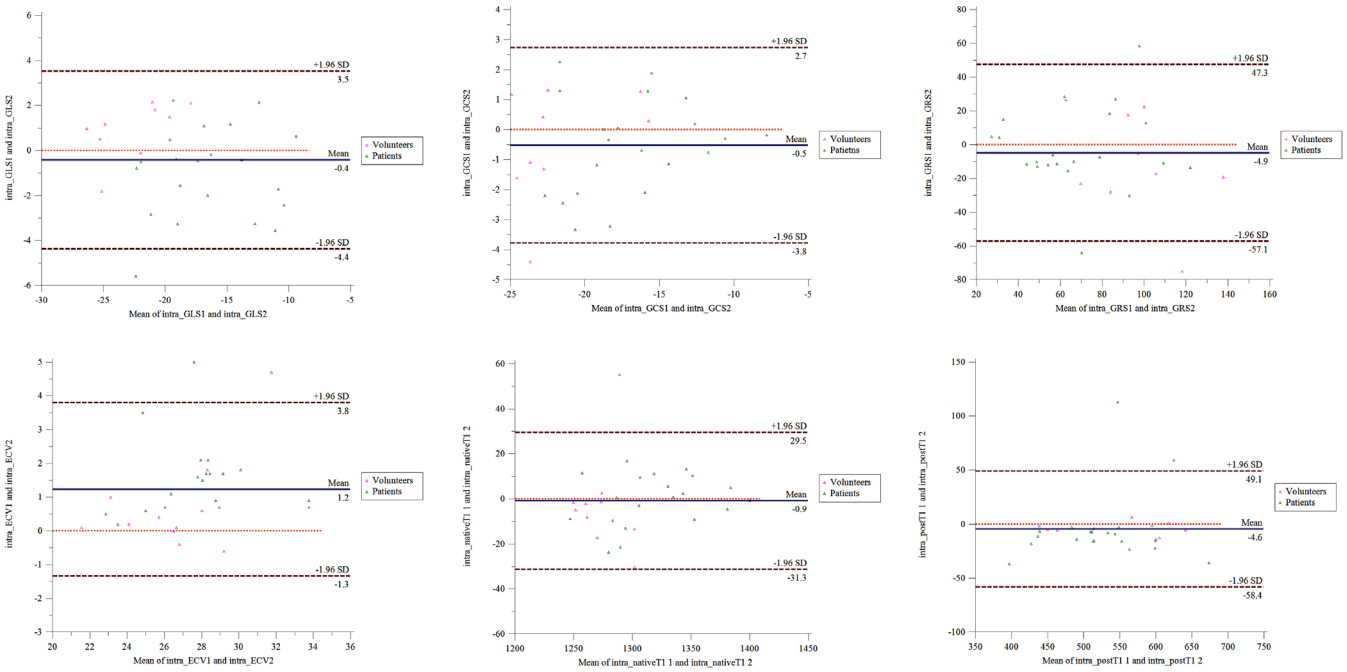

Figure S3 Reproducibility of CMR-FT and T1 mapping parameters. Bland-Altman plots showed intra-observer agreement for CMR-FT derived GLS, GCS, and GRS parameters, and for T1-derived ECV, native T1, and post T1 parameters in selected participants (n= 30). Abbreviations are shown in Supplemental Figures 1 and 2.

http://dx.doi.org/10.21037/cdt-20-803