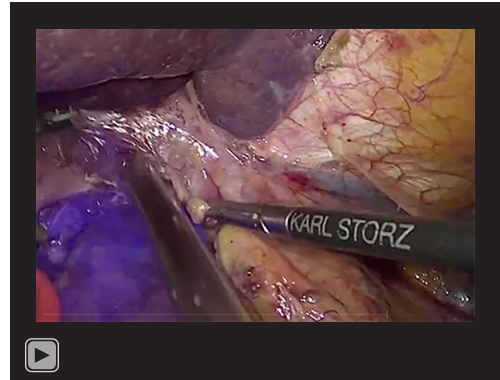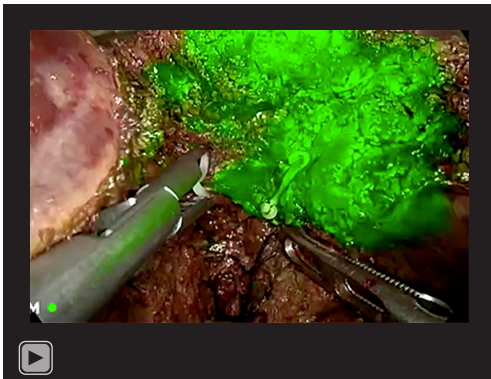




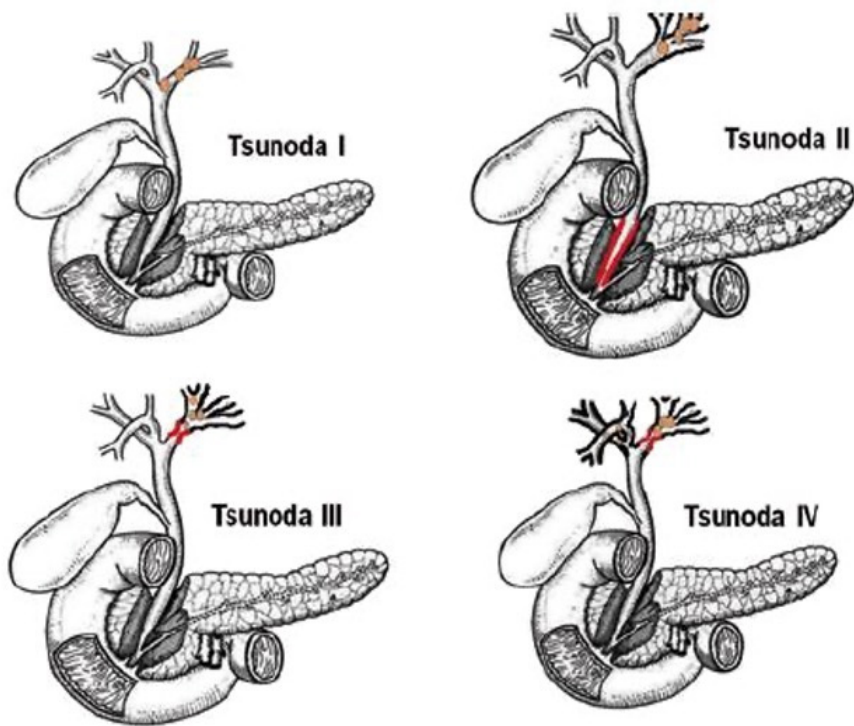
**Video S1** NIF-guided laparoscopic hepatectomy via positive biliary approach staining. NIF, near-infrared fluorescence.



**Video S3** NIF-guided laparoscopic hepatectomy via negative biliary approach (puncturing the CBD) staining. NIF, near-infrared fluorescence; CBD, common bile duct.



**Video S2** NIF-guided laparoscopic hepatectomy via negative biliary approach (ENBD tube) staining. NIF, near-infrared fluorescence; ENBD, endoscopic nasobiliary drainage.



Tsunoda I: Unilateral intrahepatic lithiasis without conduct dilatation or stenosis  
 Tsunoda II: Unilateral intrahepatic lithiasis with conduct dilatation and choledochus stenosis  
 Tsunoda III: Unilateral intrahepatic lithiasis with stenosis and conduct dilatation  
 Tsunoda IV: Bilateral intrahepatic lithiasis with stenosis and conduct dilatation

**Figure S1** Tsunoda type of hepatolithiasis.